

University of Groningen

Squamous cell carcinoma antigen concentration in fine needle aspiration samples

van Schaik, Jeroen E; Muller Kobold, Anna C; van der Laan, Bernard F A M; van der Vegt, Bert; van Hemel, Bettien M; Plaat, Boudewijn E C

Published in:

Head and Neck: Journal of the Sciences and Specialties of the Head and Neck

DOI:

[10.1002/hed.25733](https://doi.org/10.1002/hed.25733)

IMPORTANT NOTE: You are advised to consult the publisher's version (publisher's PDF) if you wish to cite from it. Please check the document version below.

Document Version

Publisher's PDF, also known as Version of record

Publication date:

2019

[Link to publication in University of Groningen/UMCG research database](#)

Citation for published version (APA):

van Schaik, J. E., Muller Kobold, A. C., van der Laan, B. F. A. M., van der Vegt, B., van Hemel, B. M., & Plaat, B. E. C. (2019). Squamous cell carcinoma antigen concentration in fine needle aspiration samples: A new method to detect cervical lymph node metastases of head and neck squamous cell carcinoma. *Head and Neck: Journal of the Sciences and Specialties of the Head and Neck*, 41(8), 2561-2565. <https://doi.org/10.1002/hed.25733>

Copyright

Other than for strictly personal use, it is not permitted to download or to forward/distribute the text or part of it without the consent of the author(s) and/or copyright holder(s), unless the work is under an open content license (like Creative Commons).

The publication may also be distributed here under the terms of Article 25fa of the Dutch Copyright Act, indicated by the "Taverne" license. More information can be found on the University of Groningen website: <https://www.rug.nl/library/open-access/self-archiving-pure/taverne-amendment>.






Take-down policy

If you believe that this document breaches copyright please contact us providing details, and we will remove access to the work immediately and investigate your claim.

Downloaded from the University of Groningen/UMCG research database (Pure): <http://www.rug.nl/research/portal>. For technical reasons the number of authors shown on this cover page is limited to 10 maximum.

ORIGINAL ARTICLE

Squamous cell carcinoma antigen concentration in fine needle aspiration samples: A new method to detect cervical lymph node metastases of head and neck squamous cell carcinoma

Jeroen E. van Schaik BSc¹  | Anna C. Muller Kobold PhD²  |
Bernard F. A. M. van der Laan MD, PhD¹  | Bert van der Vegt MD, PhD³  |
Bettien M. van Hemel MD, PhD³ | Boudewijn E. C. Plaat MD, PhD¹ 

¹Department of Otorhinolaryngology, Head and Neck Surgery, University of Groningen, University Medical Center Groningen, Groningen, The Netherlands

²Department of Laboratory Medicine, University of Groningen, University Medical Center Groningen, Groningen, The Netherlands

³Department of Pathology and Medical Biology, University of Groningen, University Medical Center Groningen, Groningen, The Netherlands

Correspondence

Jeroen E. van Schaik, Department of Otorhinolaryngology, Head and Neck Surgery, University of Groningen, University Medical Center Groningen, Hanzeplein 1, 9700RB Groningen, The Netherlands.
Email: j.e.van.schaik@umcg.nl

Abstract

Background: The purpose of this study was to determine the additional diagnostic value of squamous cell carcinoma antigen (SCC-Ag) in cervical lymph node fine needle aspiration (FNA) samples for the detection of regional metastases of head and neck squamous cell carcinoma (HNSCC).

Methods: In 149 FNA samples of 114 patients, SCC-Ag concentration was retrospectively analyzed and associated with diagnosis to establish a cutoff concentration in relation to sensitivity and specificity of HNSCC detection.

Results: SCC-Ag was elevated in lymph nodes from patients with HNSCC compared to lymph nodes from other patients ($P < 0.01$). With 0.3 $\mu\text{g/L}$ as the cutoff concentration, SCC-Ag has 96% sensitivity for detecting HNSCC.

Conclusions: SCC-Ag in FNA is a reliable test for detecting HNSCC in cervical lymph nodes.

KEYWORDS

FNA, HNSCC, lymph node, SCC-Ag, tumor marker

1 | INTRODUCTION

Lymph node metastasis of head and neck squamous cell carcinoma (HNSCC) is associated with poor overall survival.¹ Accurate detection of lymph node metastasis is of utmost importance for adequate tumor staging and choice of treatment accordingly. Current diagnostic methods for detecting lymph nodes are palpation, CT, PET-CT, MRI, sentinel node biopsy, and ultrasound (US)-guided fine needle aspiration cytology (FNAC).² FNAC has a sensitivity of 80%-92% and a specificity of 98%, and US-guided FNAC has proven to be a valuable method for the detection of lymph node metastasis.^{3,4} The

measurement of squamous cell carcinoma antigen (SCC-Ag), originally purified from SCC of the human uterine cervix,⁵ could improve the detection of regional HNSCC lymph node metastases in addition to FNAC. Although SCC-Ag is used as a prognostic serum tumor marker in cervical cancer and non-small-cell lung cancer,⁶⁻⁸ in HNSCC, the serum SCC-Ag level showed no significant relation to lymph node metastasis and overall survival.^{9,10} To our knowledge, SCC-Ag in FNA samples has not previously been studied. The aim of this study is to investigate SCC-Ag as a novel diagnostic modality in the detection of HNSCC lymph node metastasis in FNA samples.

This is an open access article under the terms of the Creative Commons Attribution-NonCommercial-NoDerivs License, which permits use and distribution in any medium, provided the original work is properly cited, the use is non-commercial and no modifications or adaptations are made.

© 2019 The Authors. *Head & Neck* published by Wiley Periodicals, Inc.

2 | PATIENTS AND METHODS

The study was composed of 165 US-guided fine needle aspiration samples from 128 consecutive patients with a neck mass suspicious for enlarged lymph nodes. Samples were collected between April 2015 and January 2016 at the University Medical Center Groningen. FNA samples were collected in 25 mL Cytolyt (Hologic, Marlborough, Massachusetts). After cytological evaluation, samples were stored at -20°C until SCC-Ag measurement. SCC-Ag analysis was performed using the SCC-Ag assay on a fully automated immune assay analyzer (Architect, Abbott, Abbott Park, Illinois), with an inter-assay coefficient of variation $<5\%$ and an analytical sensitivity of $0.1\ \mu\text{g/L}$.

Retrospectively, demographics of all patients, relevant medical history and related treatment history, human papillomavirus (HPV), and smoking status were collected (Table 1). Radiology, cytology, and histology information was collected concerning lymph node location (neck level), size, morphology as seen on US, and diagnosis based on cytology and/or histology (Table 2). The results of the histological or cytological examination were present in 157 of 165 samples. There was no definitive diagnosis in eight samples, corresponding to six patients, because of insufficient cell material or blood contamination, and these samples were excluded. Neck masses suspected for enlarged lymph nodes but diagnosed as branchial cleft cysts on US examination were excluded ($n = 8$) as well. The total number of samples and patients available for further analyses were therefore 149 and 114, respectively. Based on diagnosis, groups were formed dividing the samples into HNSCC ($n = 30$), other carcinomas ($n = 22$), lymph nodes with a diagnosis other than carcinoma ($n = 93$), and branchial cleft cysts ($n = 4$) (Table 1). As branchial cleft cysts had high SCC-Ag concentrations, a separate group was formed to prevent confounding. Two patients, diagnosed with cutaneous squamous cell carcinoma and esophageal squamous cell carcinoma, respectively, were placed in the group with other carcinomas, as the primary tumor did not originate from a mucosal HNSCC subsite. Histology was taken as the gold standard. However, as histology results were present in only 33 of 149 samples, cytological examination was taken as the most reliable diagnostic tool after histology.

The Institutional Review Board of the University Medical Center Groningen assessed this retrospective study and judged that there was no need for approval based on the Dutch Medical Research Law (Wet medisch-wetenschappelijk onderzoek met mensen [WMO]).

2.1 | Statistical analysis

Groups were compared using the Mann-Whitney U test for nonparametric data, considering $P < 0.05$ to be statistically significant.

TABLE 1 Demographic and clinical data of 114 patients and their corresponding 149 fine needle aspiration samples

Characteristics	Total number (%)
Sex	
Male	69 (61)
Female	45 (39)
Age	
Mean, y	62
Range, y	16–94
FNA sample	
Total number	149 (100)
Sample diagnosis	
HNSCC	30 (20)
Other carcinomas	22 (15)
Adenocarcinoma	9 (6)
Papillary thyroid carcinoma	4 (3)
Cutaneous SCC	3 (2)
Other carcinomas	6 (4)
No carcinoma	93 (62)
Other malignancies	
Malignant lymphoma	11 (7)
Melanoma	2 (1)
Other	4 (3)
Normal lymph nodes	
Inflammation	4 (3)
Reactive lymph node	3 (2)
Other	2 (1)
No malignancy NOS	67 (45)
Cyst	4 (3)

Abbreviations: FNA, fine needle aspiration; HNSCC, head and neck squamous cell carcinoma; SCC, squamous cell carcinoma; NOS, not otherwise specified.

Spearman's rank correlation was used for estimating correlations between continuous variables. For analysis of sensitivity and specificity, only one sample per patient was included. In case of multiple samples per patient, the sample with the highest SCC-Ag concentration was included. Receiver operating characteristic (ROC) curves were constructed in order to examine the relation between SCC-Ag concentration, sensitivity, and specificity of detecting HNSCC lymph node metastasis.

Statistical analyses were performed using SPSS (version 23 for Windows; IBM Corp., Armonk, New York).

3 | RESULTS

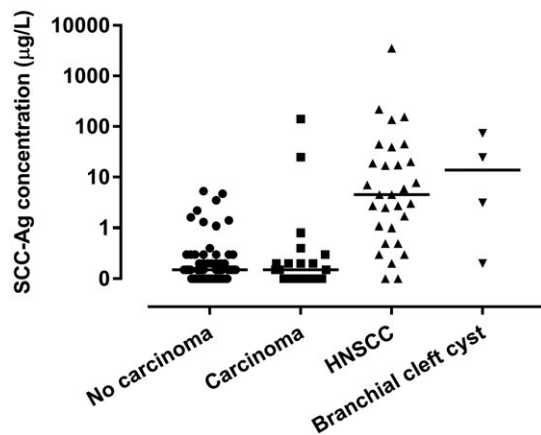
The total number of patients was 114, of which 69 were male (61%) and 45 female (39%) (Table 1). The median age

TABLE 2 Characteristics of HNSCC samples

HNSCC characteristics	Number of tumors (%)
T classification	
T0	3 (10)
T1	6 (20)
T2	12 (40)
T3	3 (10)
T4	6 (20)
N classification	
N0 or N1	12 (40)
N2 or N3	16 (53)
Differentiation grade	
Well	4 (13)
Moderately	14 (47)
Poorly	4 (13)
Severe dysplasia	3 (10)
Tumor location	
Hypopharynx	2 (7)
Oropharynx	4 (13)
Oral cavity	17 (57)
Larynx	3 (10)
Nasal vestibulum	1 (3)
HPV status	
Positive	3 (10)
Negative	1 (3)
Follow-up (months)	25.7 (1.8-32.9)

Abbreviation: HNSCC, head and neck squamous cell carcinoma; HPV, human papillomavirus.

was 62 (range 16-94). The SCC-Ag concentrations were not normally distributed in the four groups. For HNSCC, the median SCC-Ag concentration was 4.5 $\mu\text{g/L}$ (SD = 642.8,

**FIGURE 1** Distribution of SCC-Ag in the various groups. SCC-Ag, squamous cell carcinoma antigen

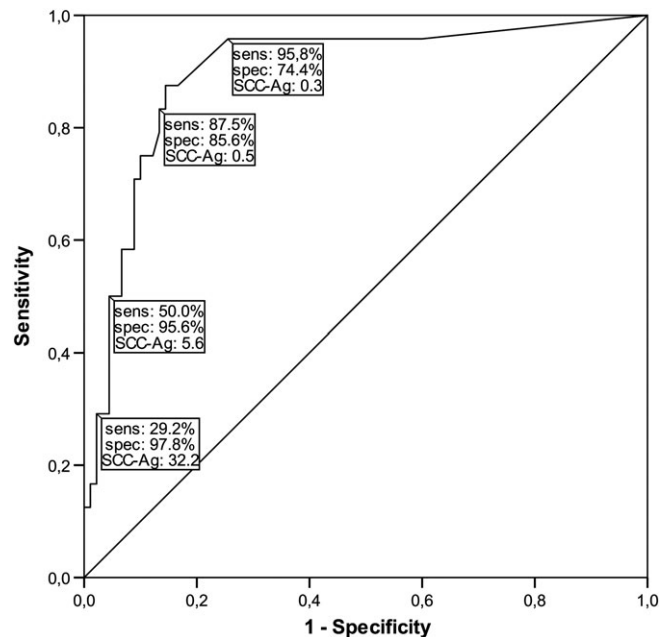
range 0.0-3535.4), for other carcinomas 0.1 $\mu\text{g/L}$ (SD = 30.5, range 0.0-142.1), for lymph nodes without carcinoma 0.1 $\mu\text{g/L}$ (SD = 0.9, range 0.0-5.3), and for cysts 13.8 $\mu\text{g/L}$ (SD = 34.0, range 0.2-73.8) (Figure 1).

The SCC-Ag concentration of HNSCC was significantly elevated compared to lymph nodes without carcinoma ($P < 0.01$) and other carcinomas ($P < 0.01$), but did not significantly differ from the four branchial cleft cysts ($P = 0.29$).

Differentiation grade of the HNSCC did not correlate with SCC-Ag concentration: well-differentiated tumors did not significantly differ from moderately differentiated ($P = 0.20$) or poorly differentiated tumors ($P = 0.26$). SCC-Ag did not correlate with lymph node size ($P = 0.22$).

3.1 | Sensitivity, specificity, and calculation of cutoff values

To evaluate the optimal concentration of SCC-Ag as a diagnostic test for the detection of HNSCC lymph node metastasis in FNA samples, an ROC curve was plotted to determine sensitivity, and specificity of SCC-Ag concentration compared to HNSCC metastasis detection, cytological, or histological diagnosis was used as ground truth. A low SCC-Ag cutoff concentration would result in a sensitivity of over 90%; however, this would lead to a specificity of under 80%, as shown in Figure 2. Choosing a higher SCC-Ag cutoff concentration would lead to a lower sensitivity, yet higher specificity.

**FIGURE 2** ROC curve for sensitivity and specificity of SCC-Ag for detection of HNSCC. All SCC-Ag concentrations in $\mu\text{g/L}$. HNSCC, head and neck squamous cell carcinoma; ROC, receiver operating characteristic; SCC-Ag, squamous cell carcinoma antigen; Sens, sensitivity; Spec, specificity

As SCC-Ag could function as a screening tool to FNAC (least possible false-negative results), we chose to set the cutoff SCC-Ag concentration at 0.3 $\mu\text{g/L}$, resulting in a sensitivity of 95.8% and specificity of 74.4%. At this cutoff concentration, one patient would have been missed due to false-negative results (4.2%).

4 | DISCUSSION

This is the first report, to our knowledge, to demonstrate the diagnostic value of the SCC-Ag concentration in US-guided FNA samples in relation to HNSCC lymph node metastasis. With a sensitivity of 95.8% and specificity of 74.4%, at a SCC-Ag cutoff concentration of 0.3 $\mu\text{g/L}$, it could serve as the first screening step to FNAC in the detection of HNSCC lymph node metastases by making a selection prior to cytological examination. This could assist in diagnosing HNSCC regional metastasis more efficiently, which is relevant for proper therapy choice and hence prognosis.

To use the SCC-Ag concentration as a reliable diagnostic test for HNSCC, it needs to be elevated in case HNSCC is present in the FNA sample, which determines the sensitivity rate. Additionally, it should not be elevated in samples of patients without HNSCC, which corresponds with the specificity rate. We plotted an ROC curve to determine sensitivity and specificity rates, resulting in low SCC-Ag cutoff concentrations for high sensitivity at the cost of specificity, and higher SCC-Ag cutoff concentrations for high specificity rates at the cost of sensitivity. At a high sensitivity rate, the SCC-Ag test could lead to a more accurate diagnosis of HNSCC, but, due its low specificity, would also result in many false positives. Choosing for higher specificity rates would lead to fewer false positives, but the test would increasingly miss true-positive HNSCC cases.

Ideally, one would choose to set the cutoff concentration at the point where sensitivity and specificity are both at the highest, leading to the best accuracy for the test. To make the SCC-Ag concentration most beneficial as an addition to FNAC, however, which has a sensitivity of 80%-92% and a specificity of 98%,^{3,4} we decided to set the cutoff concentration at the highest sensitivity, relying on the high specificity of FNAC in case of false positives. We therefore determined the cutoff concentration at 0.3 $\mu\text{g/L}$. If SCC-Ag was measured with a cutoff concentration of 0.3 $\mu\text{g/L}$ before cytological examination, costly and time-consuming cytological examinations could have been avoided in 95 of all 119 non-HNSCC samples. This will speed up the diagnostic process, as SCC-Ag concentration can be measured within hours and pathologists only need to examine the samples selected by the SCC-Ag test. Moreover, there are economic advantages. The measurement of SCC-Ag in our institute is 8.5% of the costs of a cytological examination and could therefore lead

to substantial cost savings. Radiologists may also save time by taking the aspirate from several lymph nodes at once and let SCC-Ag analysis select which nodes have to be cytologically examined, instead of waiting for cytological examination in between each puncture, as may be the procedure in some institutions.

Additionally, the SCC-Ag measurement could prove useful in FNA samples unsuitable for reliable cytological examination due to blood contamination or insufficient material. In the six patients corresponding to the eight samples that were excluded from further analysis because of insufficient material for cytological examination or blood contamination, no HNSCC was diagnosed and the samples had SCC-Ag concentrations under the cutoff concentration of 0.3 $\mu\text{g/L}$.

One case of HNSCC was missed by the SCC-Ag examination, which was a T1N1M0 oral cavity carcinoma with an SCC-Ag concentration of <0.1 $\mu\text{g/L}$. As this study is limited by its retrospective design and the relatively small number of HNSCC samples, a prospective study with a larger amount of samples needs to be performed in order to establish sensitivity and specificity more accurately.

The FNA puncture needle was aspirated in 25 mL Cytolyt. Theoretically, if aspirated in 5 mL instead of 25 mL, the analytical sensitivity will increase by a factor of 5 and could contribute to more accurate sensitivity and specificity rates.

Since the use of SCC-Ag in FNA in routine patient care in Europe requires European Conformity (CE) marking extensive laboratory validation is mandatory. Therefore, in our laboratory, SCC-Ag validation according to CLSI (Clinical Laboratory Standards Institute) guidelines is currently under way.

Although in our analysis no significant difference was found in SCC-Ag concentrations between tumor differentiation grades, Saidak et al. found on gene expression level a significantly lower expression of the SERPINB3 gene in high-grade (G2/G3/G4) compared to low-grade (G1) tumors.¹¹

SCC-Ag showed to be valuable as a prognostic serum tumor marker in cervical cancer and non-small-cell lung carcinoma,⁶⁻⁸ but not so in HNSCC.¹⁰ Because the diagnostic value of SCC-Ag in FNA is a new finding, it would be of interest to see whether the SCC-Ag concentration has any prognostic value. In this retrospective study, we had insufficient data on the relevant clinical factors to run a multivariate analysis to evaluate its prognostic value. This may be done in future studies in which clinical factors such as tumor stage, tumor site, treatment, HPV status, and comorbidities are recorded.

Based on our findings, a different approach could be proposed for accurate, reliable, and easy detection of HNSCC lymph node metastasis. Due to the great heterogeneity of diagnoses in our study population, this approach should first be confirmed in prospectively collected FNA samples in only patients with HNSCC with suspected lymph node metastasis. We estimated that roughly 200 patients with suspected HNSCC lymph node metastasis would be required to confirm

our findings in a prospective study, which we already have commenced.^{12,13} Given the prevalence in our cohort, this could best be executed in a multicenter study design. However, the sensitivity rate is not the only relevant outcome of future studies. The measurement of the SCC-Ag concentration is faster and cheaper than cytological analysis. These future studies, with relevant outcomes to the diagnostic process of patients with HNSCC, would possibly require a smaller study population.

In case of confirmation of the results of our retrospective study, the results should be evaluated in a randomized controlled trial comparing SCC-Ag concentration-based FNAC with FNAC alone.

5 | CONCLUSION

This is the first study to demonstrate a new promising approach of measuring SCC-Ag concentration in lymph nodes by US-guided FNA that is highly sensitive to detect HNSCC lymph node metastasis in FNA samples. These findings could precede an even more accurate detection of HNSCC lymph node metastasis when used in addition to FNAC.


ACKNOWLEDGMENTS

We kindly thank Mr. T. Ruitenbeek, pathological technician at the Department of Pathology, and Mrs. K. Koerts, technician at the Laboratory of Binding Analysis, Department of Laboratory Medicine, for performing the SCC-Ag measurements.

ORCID

Jeroen E. van Schaik  <https://orcid.org/0000-0001-6003-7524>

Anna C. Muller Kobold  <https://orcid.org/0000-0003-3457-4179>

Bernard F. A. M. van der Laan  <https://orcid.org/0000-0002-5016-2871>

Bert van der Vegt  <https://orcid.org/0000-0002-2613-1506>

Boudewijn E. C. Plaat  <https://orcid.org/0000-0001-8631-7727>

REFERENCES

- Layland MK, Sessions DG, Lenox J. The influence of lymph node metastasis in the treatment of squamous cell carcinoma of the oral cavity, oropharynx, larynx, and hypopharynx: N0 versus N+. *Laryngoscope*. 2005;115:629-639.
- Paleri V, Urbano TG, Mehanna H, et al. Management of neck metastases in head and neck cancer: United Kingdom National Multidisciplinary Guidelines. *J Laryngol Otol*. 2016;130:S161-S169.
- Tandon S, Shahab R, Benton JI, Ghosh SK, Sheard J, Jones TM. Fine-needle aspiration cytology in a regional head and neck cancer center: comparison with a systematic review and meta-analysis. *Head Neck*. 2008;30:1246-1252.
- de Bondt RBJ, Nelemans PJ, Hofman PAM, et al. Detection of lymph node metastases in head and neck cancer: a meta-analysis comparing US, USgFNAC, CT and MR imaging. *Eur J Radiol*. 2007;64:266-272.
- Kato H, Torigoe T. Radioimmunoassay for tumor antigen of human cervical squamous cell carcinoma. *Cancer*. 1977;40:1621-1628.
- Charakorn C, Thadanipon K, Chaijindaratana S, Rattanasiri S, Numthavaj P, Thakkestian A. The association between serum squamous cell carcinoma antigen and recurrence and survival of patients with cervical squamous cell carcinoma: a systematic review and meta-analysis. *Gynecol Oncol*. 2018;150:190-200.
- Markovina S, Wang S, Henke LE, et al. Serum squamous cell carcinoma antigen as an early indicator of response during therapy of cervical cancer. *Br J Cancer*. 2018;118:72-78.
- Cao L, Wang X, Li S, et al. PD-L1 is a prognostic biomarker in resected NSCLC patients with moderate/high smoking history and elevated serum SCCA level. *J Cancer*. 2017;8:3251-3260.
- Barak V, Meirovitz A, Leibovici V, et al. The diagnostic and prognostic value of tumor markers (CEA, SCC, CYFRA 21-1, TPS) in head and neck cancer patients. *Anticancer Res*. 2015;35:5519-5524.
- Travassos DC, Fernandes D, Massucato EMS, Navarro CM, Bufalino A. Squamous cell carcinoma antigen as a prognostic marker and its correlation with clinicopathological features in head and neck squamous cell carcinoma: systematic review and meta-analysis. *J Oral Pathol Med*. 2018;47:3-10.
- Saidak Z, Morisse MC, Chatelain D, et al. Squamous cell carcinoma antigen-encoding genes SERPINB3/B4 as potentially useful markers for the stratification of HNSCC tumours. *Anticancer Res*. 2018;38:1343-1352.
- Hajian-Tilaki K. Sample size estimation in diagnostic test studies of biomedical informatics. *J Biomed Inform*. 2014;48:193-204.
- Malhotra RK, Indrayan A. A simple nomogram for sample size for estimating sensitivity and specificity of medical tests. *Indian J Ophthalmol*. 2010;58:519-522.

How to cite this article: van Schaik JE, Muller Kobold AC, van der Laan BFAM, van der Vegt B, van Hemel BM, Plaat BEC. Squamous cell carcinoma antigen concentration in fine needle aspiration samples: A new method to detect cervical lymph node metastases of head and neck squamous cell carcinoma. *Head & Neck*. 2019;1–5. <https://doi.org/10.1002/hed.25733>