

University of Groningen

## Surgical techniques for mesenteric lengthening in ileoanal pouch surgery

Zwakman, Marije; Hentzen, Judith E.K.R.; Jonker, Jara E.; Krikke, Christina; Lange, Johan F.M.; Hofker, Sijbrand H.S.

*Published in:*  
Colorectal Disease

*DOI:*  
[10.1111/codi.16498](https://doi.org/10.1111/codi.16498)

**IMPORTANT NOTE: You are advised to consult the publisher's version (publisher's PDF) if you wish to cite from it. Please check the document version below.**

*Document Version*  
Publisher's PDF, also known as Version of record

*Publication date:*  
2023

[Link to publication in University of Groningen/UMCG research database](#)

*Citation for published version (APA):*  
Zwakman, M., Hentzen, J. E. K. R., Jonker, J. E., Krikke, C., Lange, J. F. M., & Hofker, S. H. S. (2023). Surgical techniques for mesenteric lengthening in ileoanal pouch surgery: a systematic review. *Colorectal Disease*, 25(6), 1079–1089. <https://doi.org/10.1111/codi.16498>

### Copyright

Other than for strictly personal use, it is not permitted to download or to forward/distribute the text or part of it without the consent of the author(s) and/or copyright holder(s), unless the work is under an open content license (like Creative Commons).

The publication may also be distributed here under the terms of Article 25fa of the Dutch Copyright Act, indicated by the "Taverne" license. More information can be found on the University of Groningen website: <https://www.rug.nl/library/open-access/self-archiving-pure/taverne-amendment>.

### Take-down policy

If you believe that this document breaches copyright please contact us providing details, and we will remove access to the work immediately and investigate your claim.

*Downloaded from the University of Groningen/UMCG research database (Pure): <http://www.rug.nl/research/portal>. For technical reasons the number of authors shown on this cover page is limited to 10 maximum.*



# European Colorectal Congress

3 – 6 December 2023, St.Gallen, Switzerland

## OVERVIEW

Sun, 3 Dec 2023

MASTERCLASS

PROCTOLOGY DAY

ROBOTIC COURSE

DAVOSCOURSE@ECC

## SCIENTIFIC PROGRAMME

Mon, 4 Dec – Wed, 6 Dec 2023

### DIVERTICULAR DISEASE

#### Gut microbiome and surgery

Phil Quirke, Leeds, UK

#### Diet in diverticular disease

Pamela Buchwald, Lund, SE

#### Decision making in the management of acute complicated Diverticulitis beyond the guidelines

Seraina Faes, Zurich, CH

#### Diverticular Abscess – Always drainage or who benefits from Surgery?

Johannes Schultz, Oslo, NO

#### Perforated Diverticulitis: Damage Control, Hartmann's Procedure, Primary Anastomosis, Diverting Loop

Reinhold Kafka-Ritsch, Innsbruck, AT

#### When to avoid protective stoma in colorectal surgery

Antonino Spinelli, Milano, IT

### ENDOMETRIOSIS

#### Endometriosis – what is the role of the abdominal surgeon

Tuynman Juriaan, Amsterdam, NL

#### Challenges in Surgery of Endometriosis – always interdisciplinary?

Peter Oppelt, Linz, AT; Andreas Shamiyeh, Linz, AT

#### A gaze in the crystal ball: Where is the role of virtual reality and artificial Intelligence in colorectal surgery

Müller Beat, Basel, CH

### MALIGNANT COLORECTAL DISEASE

#### Cytoreductive Surgery and Intraperitoneal Chemotherapy – facts and hopes

Michel Adamina, Winterthur, CH

#### Metastatic Colorectal Cancer – surgical approaches and limits

Jürgen Weitz, Dresden, DE

#### Extended lymph node dissection for rectal cancer, is it still under debate?

Miranda Kusters, Amsterdam, NL

#### Organ preservation functional outcome in rectal cancer treatment – in line with patient's needs? (Robot – laparoscopic – open surgery?)

Hans de Wilt, Nijmegen, NL

### ROBOTICS

#### Advances in Robotic Surgery and what we learnt so far

Parvaiz Amjad, Portsmouth, UK

#### Challenging the market: Robotic (assistant) Devices and how to choose wisely (Da Vinci – Hugo Ras – Distalmotion ua)

Khan Jim, London, UK

#### TAMIS - Robotic Transanal Surgery, does it make it easier?

Knol Joep, Genk, BE

#### Live Surgery – Contonal Hospital of St.Gallen

Walter Brunner, St.Gallen, CH;  
Salvadore Conde Morales, Sevilla, ES;  
Friedrich Herbst, Vienna, AUT;  
Amjad Parvaiz, Portsmouth, UK

#### Video Session

#### Lars Pahlmann Lecture

Markus Büchler, Lisboa, PRT

#### Honorary Lecture

Bill Heald, Lisboa, PRT

Information & Registration [www.colorectalsurgery.eu](http://www.colorectalsurgery.eu)



## SYSTEMATIC REVIEW

# Surgical techniques for mesenteric lengthening in ileoanal pouch surgery: a systematic review

Marije Zwakman<sup>1</sup> | Judith E. K. R. Hentzen<sup>1</sup> | Jara E. Jonker<sup>1</sup> | Christina Krikke<sup>2</sup> | Johan F. M. Lange<sup>2</sup> | Sijbrand H. S. Hofker<sup>2</sup>

<sup>1</sup>Department of Surgery, University Medical Center Groningen, Groningen, The Netherlands

<sup>2</sup>Department of Abdominal Surgery, University Medical Center Groningen, Groningen, The Netherlands

## Correspondence

Marije Zwakman, Department of Surgery, University Medical Center Groningen, Hanzeplein 1, 9713 GZ Groningen, The Netherlands.

Email: [m.zwakman@umcg.nl](mailto:m.zwakman@umcg.nl)

## Abstract

**Aim:** The key to successful construction of an ileal pouch–anal anastomosis (IPAA) following proctocolectomy in patients with ulcerative colitis or familial adenomatous polyposis is the ability of the pouch reservoir to reach the anus well vascularized and without tension. The aim of this systematic review was to provide an overview of previously described different surgical lengthening techniques to achieve adequate length for a tension-free IPAA.

**Method:** Pubmed, Embase and Cochrane Library databases were systematically searched. Two reviewers conducted a systematic search with combinations of keywords for the surgical procedure and surgical lengthening techniques. All publications that reported one or more surgical lengthening techniques during IPAA surgery in adult patients were selected, consisting of reviews, cohort studies, case reports, human cadaver studies and expert opinions. The primary outcomes measured were the different surgical lengthening techniques and the step-by-step approach they involve that can be used during surgery to achieve adequate length for an IPAA.

**Results:** Of 1577 records reviewed, 19 articles were included in this systematic review describing at least 1181 patients (i.e. one review, four retrospective studies, five human cadaver studies, two case reports and seven expert opinions). A total of six different surgical lengthening techniques with various subtechniques were found and described, consisting of pouch folding, construction of different types of pouches, stepladder incisions, skeletonization of vessels, division and ligation of mesenteric vessels and using an interposition vein graft. No prospective or randomized controlled trials were performed regarding this topic. Quality assessment showed a medium quality of the included studies.

**Conclusion:** Different surgical lengthening techniques are described in a step-by-step approach to create adequate mesenteric length during IPAA surgery, in patients in whom the ileal pouch cannot reach the dentate line.

## KEYWORDS

ileal pouch anal anastomosis, restorative proctocolectomy, surgical lengthening techniques

Marije Zwakman and Judith E. K. R. Hentzen share first authorship.

This manuscript has not been or will not be a podium or poster meeting presentation. PROSPERO online database of systematic reviews ID: CRD42022295866.

This is an open access article under the terms of the [Creative Commons Attribution-NonCommercial-NoDerivs](https://creativecommons.org/licenses/by-nc-nd/4.0/) License, which permits use and distribution in any medium, provided the original work is properly cited, the use is non-commercial and no modifications or adaptations are made.

© 2023 University Medical Center Groningen. *Colorectal Disease* published by John Wiley & Sons Ltd on behalf of Association of Coloproctology of Great Britain and Ireland.

## INTRODUCTION

Ileal pouch–anal anastomosis (IPAA) is performed following proctocolectomy for patients with medically refractory ulcerative colitis or (pre-)cancerous lesions within the colon or for patients with familial adenomatous polyposis who undergo prophylactic colectomy. IPAA gives these groups of patients a stoma-free life [1–6]. However, IPAA involves many challenges to achieve a tension-free, well-perfused anastomosis. Increased tension on the anastomosis can lead to failure of the pouch due to ischaemia, necrosis and anastomotic dehiscence [1].

During a restorative proctocolectomy with IPAA, the colon and rectum are resected while the sphincter is preserved. Subsequently, an anastomosis is created between the ileal pouch and the rectal cuff or dentate line [7]. Among the challenges of this extensive procedure is the ability to construct a well-perfused, tension-free anastomosis [2, 3, 6, 8]. Fortunately, this is not a problem in most cases. However, it can be difficult and sometimes impossible because of a short ileal mesentery [1]. Factors that determine the success of the construction and anastomosis of the pouch are the length of the pouch and anatomy of the right colonic and ileal vasculature [9, 10]. Literature on how to deal with too short a pouch is mostly anecdotal and focused on expert opinions. To the best of our knowledge, no systematic review on this subject has previously been reported.

Taken together, the aim of this systematic review is to identify the adequate length required to create an ileal pouch and to identify the surgical techniques that can be used to achieve adequate length for an IPAA.

## METHOD

This systematic review was conducted following a publicly available protocol registered with the PROSPERO online database of systematic reviews (ID: CRD42022295866) and the results were reported according to the Preferred Reporting Items for Systematic Reviews and Meta-Analyses (PRISMA) guidelines (Appendix S1) [11].

### Literature search strategy

The search strategy was developed in collaboration with a medical research librarian, and a full description of this search strategy for each electronic database can be found in Table S1. We performed a comprehensive literature search of the Pubmed, Embase and Cochrane Library (trials) databases from 1 January 1950 to 1 May 2022. The search contained the following Medical Subject Headings (MeSH) terms and free-text terms: (“pouch”, “ileal”, “ileoanal”) AND (“length technique”, “strategy”, “surger”, “considerat”) AND (“mesentery”, “mesenter”). Reference mining of the included studies was conducted to find any additional articles.

### Eligibility criteria

Studies were included for review based on the following eligibility criteria: (1) any study (retrospective, prospective, case report, human cadaver or expert opinion) that clearly reported one or more surgical lengthening techniques to achieve adequate length for a tension-free IPAA; (2) in the case of clinical data patients were adults with ulcerative colitis or familial adenomatous polyposis; (3) research was original and peer-reviewed. To guarantee that the publications were understood at an academic level, the articles were required to be written in English or Dutch. Besides prospective and retrospective study designs, we also included case reports, expert opinion reports and human cadaver studies to increase the knowledge about all previously described lengthening techniques in the scientific literature.

### Study selection

Titles and abstracts were independently reviewed for eligibility according to the predefined criteria by two authors (MZ and JEKRH). The reviewers were not blinded to publication date, journal or authors. The full texts of potentially eligible articles were retrieved and assessed for inclusion independently by each author. Disagreement about study inclusion was resolved by consensus or by discussion with a third author (SHSH).

### Data extraction and quality assessment

Data extraction for predetermined items was performed independently by two authors (MZ and JERKH) by using a standard paper-based extraction sheet. The following items were extracted from each study: general study characteristics (first author, year of publication, country of origin, study years, study design, sample size), surgery characteristics (surgical lengthening techniques performed, additional length created), pouch-related adverse events (anastomotic dehiscence or leakage, anastomotic stricture, wound infection, pouch-related fistula, pouch ischaemia, haemorrhage or reoperations), main conclusions from the experts and information for assessment of the risk of bias.

The quality of the eligible studies was assessed by two reviewers (MZ and JERKH) independently by using the different Joanna Briggs Institute (JBI) Critical Appraisal Tools: the JBI Critical Appraisal Checklist for Case Reports [12], the JBI Critical Appraisal Checklist for Case Series [13], the JBI Critical Appraisal Checklist for Cohort Studies [14], and the JBI Critical Appraisal Checklist for Text and Opinion [15].

### Outcomes

The primary outcomes were the different surgical lengthening techniques to achieve adequate length for an IPAA. The secondary

outcomes were definition of adequate length according to literature and additional created length with different surgical lengthening techniques.

All figures used in this systematic review to visually explain the different techniques were created and designed by JFML and composed with Photoshop.

## RESULTS

### Study selection and study characteristics

A total of 1577 potentially relevant records were identified through electronic searches of Embase ( $n = 1021$ ), Pubmed ( $n = 526$ ) and the Cochrane Library ( $n = 30$ ). After removal of duplicates, a further 744 irrelevant records were excluded through screening titles and reading abstracts. The 28 remaining studies were investigated in full text and a further nine studies were excluded. The PRISMA flowchart is shown in [Figure 1](#).

Nineteen studies fulfilled the eligibility criteria of this systematic review, and this included one review [2], four retrospective studies [5, 16–18], five human cadaver studies [3, 6, 8, 19, 20], two case reports [4, 21] and seven expert opinions [1, 22–27]. These studies represented at least 1181 patients who underwent proctocolectomy with IPAA and 151 human cadavers in which surgical lengthening techniques for IPAA are described. Four expert opinion reports did not mention any patient numbers. Six different surgical lengthening techniques were identified. The characteristics of all included studies are shown in [Table 1](#).

### Quality assessment

To evaluate the quality of the included articles, a quality assessment was performed using the different JBI Critical Appraisal Tools, the results of which are summarized in [Table S2A–C](#).

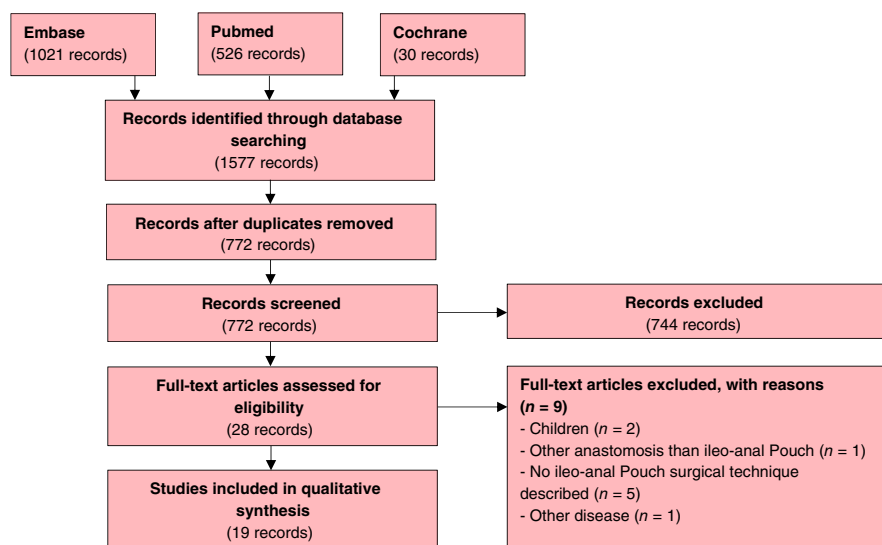
Three out of four cohort studies (75%) scored a good overall appraisal for the quality assessment. Identification of and strategy for possible confounding factors was not reported by two cohort studies (50%), and two cohort studies (50%) did not report follow-up data.

Four of out seven case reports and human cadaver studies (57%) scored a good overall appraisal for quality assessment. Three studies (43%) did not report clear criteria for patient or cadaver inclusion and four studies (57%) did not report clear clinical information on the patients or cadavers.

Five out of seven expert opinion reports (71%) scored a good overall appraisal for the quality assessment. Four studies (57%) did not provide any substantial information regarding their analytical process that led to their expert opinion. Four studies (57%) did not compare their expert opinion with the current scientific literature.

### Initial IPAA surgery

Proctocolectomy with IPAA is an extensive procedure and consists of different phases. If not previously carried out, an abdominal colectomy is performed by mobilizing the entire colon from the terminal ileum to the rectosigmoid. The terminal ileum is transected, and the mesenteric vessels of the colon are ligated. The last ileal arcade including the ileocolic artery is preserved to sustain vascular supply to the terminal ileum. Subsequently, circumferential mobilization of the rectum down to the level of the levator ani muscles is performed and the distal rectum is transected at the top of the levator ani muscles, preserving a 1–3 cm rectal cuff and the anal transitional zone. If a mucosectomy is performed, it is started transanally at the dentate line. The previous transection usually limits the extent of the mucosectomy to the most distal 1–3 cm of anorectal mucosa. Hereafter, the pouch reservoir is constructed by folding the ileal segment; different designs such as the J-, S- and W-pouch are described in literature [28, 29]. The apex of the pouch is brought towards the anus



**FIGURE 1** Flowchart of the systematic review.

**TABLE 1** Characteristics of the studies included in the systematic review describing surgical lengthening techniques for an ileal pouch–anal anastomosis.

Author	Year	Country	Study design	No. of patients	Tips and tricks	Main outcomes
Smith	1984	USA	Human cadaver study	58	Mesenteric vascular division Construction of a J-pouch Construction of an S-pouch	S-pouch reached further than the J-pouch
Ballantyne	1985	USA	Expert opinion	330	Division of the ICA Construction of the SMA Construction of a J-pouch	-
Burnstein	1987	USA	Expert opinion	159	Stepladder incisions Division of vessels between primary and secondary arcades Division of SMA	Careful attention to technical details resulted in the consistent capability of the J-pouch to reach the anus
Cherqui	1987	France	Human cadaver angiographic study	13	Division of the ICA Division of the SMA	When performing IPAA, care should be taken to preserve the vascularization of the terminal ileum and to extend the inferior reach of the reservoir. Division of the ileocecal artery is a safe and efficient procedure of gaining length
Goes	1995	USA	Human cadaver study	6	Vascular ligation between colon wall and MVA Division of the SMA Division of the ICA Division of the RCA Division of the TIM	In this anatomic study, SMA, ICA and RCA ligation and division of the terminal ileal mesentery provided a mean additional length to the mesentery of 36.5% compared with the length obtained after the distal third of SMA, ICA and RCA ligation
Thirlby	1995	USA	Retrospective study	74	Division of mesentery close to caecum to preserve the ICA Division of the SMA Tagging suture, placed 15 cm from terminal ileum Division of the ICA Division of one to three arcade vessels between the vasa recta and the terminal branch of the SMA	-
Martel	1998	France	Retrospective study	65	Division of the SMA	-
Michelassi	2000	USA	Expert opinion	300	Stepladder incisions Division of the SMA Pouch folding anteriorly Construction of a J-pouch	-
Martel	2002	France	Human cadaver study	12	Division of the ICA Division of the SMA	The increase in mesenteric length was greater after SMA division than after ICA division
Araki	2006	France	Retrospective study	120	Division of the ICA Division of the SMA Division of the MVA Division of the ICA and SMA Division of the ICA and MVA Division of the SMA and ICA	Mesentery lengthening techniques allows the construction of an IPAA in almost all patients without increasing postoperative morbidity Because mesentery lengthening techniques may require division of the ICA and SMA, preservation of the MVA whenever possible is important and of critical significance

TABLE 1 (Continued)

Author	Year	Country	Study design	No. of patients	Tips and tricks	Main outcomes
Baig	2006	USA	Expert opinion	-	Stepladder incisions	The mesenteric transillumination stepladder technique offers the possibility of adding mesenteric length without any known increased complications
Uraiqat	2007	Australia	Review	-	Pouch folding Construction of an S-pouch Stepladder incisions Mesenteric vascular division Division of RCA, ICA and SMA	Proposed algorithm for mesenteric lengthening techniques
Metcalf	2008	USA	Case report	1	Interposition vein graft VSM	Extending the length of the small-bowel mesentery by division of the SMA and use of an interposition saphenous vein graft for reconstruction is a useful technique. It should be used as a last resort, because risks of complications are unknown
Kirat	2010	USA	Expert opinion	-	Stepladder incisions Division of the SMA Construction of a J-pouch Construction of a S-pouch	The creation of a J-pouch is easier and has generally a similar rate of complications and functional outcomes when compared with other types of pouch
Ma	2011	Australia	Expert opinion	-	Closing the original enterotomy and re-creating it approximately 4 cm proximal to the apex on the antimesenteric border	With the described technique all subsequent pouches have reached to the dentate line without the need for mesenteric manoeuvres
Chu	2015	USA	Case report	1	Division of the RCA, ICA and SMA Construction of an S-pouch	The mesenteric-lengthening technique described in this report is a safe and effective method for addressing a difficult IPAA that will not reach
Parray	2016	India	Expert opinion	-	Stepladder incisions Skeletonization Construction of an S-pouch Division of smaller arcades in mesentery Division of the ICA Division of the SMA	Proposed algorithm for mesenteric lengthening techniques
Ismail	2018	Turkey	Human cadaver angiographic study	25	Stepladder incisions Division of the SMA, RCA and MCA Division of the SMA, RCA and ICA Division of the SMA without preserving any of the colic or marginal arteries	Stepladder incisions through the superior mesenteric pedicle trace are usually sufficient for mesenteric lengthening. In addition, division of the superior mesenteric pedicle with either a preserving marginal artery or without preserving ileocolic and marginal arteries leads to additional mesenteric lengthening
Rottoli	2021	Italy	Retrospective study	131	Division of the SMA Pouch folding anteriorly	-

Abbreviations: ICA, ileocolic artery; IPAA, ileal pouch–anal anastomosis; MCA, middle colic artery; MVA, marginal vascular arcade; RCA, right colic artery; SMA, superior mesenteric artery; TIM, terminal ileal mesentery.

for final anastomosis. Construction of the IPAA can be by either a hand-sewn, single-stapled or double-stapled technique [30].

## Definition of adequate mesenteric length

The key to successful pouch surgery is to obtain a tension-free anastomosis by gaining adequate mesenteric length. Interestingly, only 10 out of 19 studies (53%) described their definition for adequate mesenteric length in IPAA surgery [1, 5, 16, 18, 22–27]. The majority of these studies ( $n = 9$ , 90%) used the border of the pubic symphysis as a landmark to confirm the ability of the pouch to reach the anal cuff [1, 5, 16, 18, 22–24, 26, 27]. There is no consensus in the literature about which border of the pubic symphysis (i.e. the superior or inferior border) should be used; the length difference between both borders is estimated as around 2 cm. Eight studies (80%) used the inferior border of the pubic symphysis and defined an adequate mesenteric length within a range of 2–6 cm below this point [1, 5, 18, 22–24, 26, 27]. One study described an adequate mesenteric length as 10 cm below the superior border of the pubic symphysis [16]. One study defined an adequate mesenteric length as that for which the ileal pouch can reach the level of the levator floor with no tension [25]. Three studies described that the pouch is directly anastomosed to the anus without leaving a rectal cuff [18, 22, 24]. Three studies described the presence of a rectal cuff [22, 23, 25] and, of these, one study defined that the length of the rectal cuff should be 2–3 cm [23]. All the different definitions described seem to be based on expert opinion.

## Type of surgical lengthening technique

As previously mentioned, six different surgical lengthening techniques were identified from the 19 studies included in this systematic review. A summary of all these techniques in a step-by-step approach to the creation of an adequate length during IPAA surgery, including corresponding figures, will be described below. The created additional length per surgical technique is outlined in Table 2.

### Pouch folding

One review [2], one retrospective study [16], and one expert opinion [23] described the different techniques for folding the body of the pouch, shown in Figure 2(A). The techniques described in the review are based on the personal observations of the main author of the publication. The technique of folding the pouch posteriorly (with the mesentery anterior) is described as the preferred choice in patients when length is not anticipated to be an issue. Folding the pouch anteriorly (with the mesentery posterior) would result in an extra length of 0.5–1 cm and should therefore be used in patients where reach is critical. The retrospective study also described that folding anteriorly would result in an extra length of about 1 cm when compared with folding the pouch posteriorly. In the expert opinion

publication, the technique of folding the pouch anteriorly is also mentioned as the preferred technique without further explanation.

### Stepladder incisions

Stepladder incisions are reported in one review [2], one human cadaver study [3] and five expert opinions [1, 22, 23, 25, 26]. One expert opinion described no complications for this specific technique [1].

In previous literature, stepladder incisions have been described as a simple and safe method to increase the length of the small bowel mesentery [1, 3, 23]. Serial transverse, side-to-side, incisions are made on the anterior and posterior surfaces of the peritoneum of the mesentery of the small bowel as shown in Figure 2(B). These incisions would be 1–3 cm long [1–3, 26]. The number of incisions varies between two to eight [1–3, 26]. Additional length is mentioned in four studies, varying from 2 to 8 cm [1–3, 26].

Caution is warranted when identifying the vascular arcades in the small bowel mesentery [1]. Adequate perfusion of the ileum is necessary to protect the anastomosis from ischaemia and consequent failure of the pouch.

### Skeletonization of vessels

This technique, where the mesentery around the vessels is skeletonized to gain more length, is described in only one expert opinion and is shown in Figure 2(C) [22]. It is performed when length is still short after the stepladder incisions. No information about the length gained is reported.

### Construction of a J- or S-pouch

A wide variety of techniques have been used to construct the faecal reservoir. J- and S-pouches have been the most widely used, but the optimal type of reservoir remains controversial. A J-pouch is constructed from the terminal 30–40 cm of the ileum by folding it into two 15–20 cm segments, whereby an enterostomy is made at the pouch apex and a side-to-side anastomosis of the two segments is created through the enterostomy with a linear stapler device. An S-pouch is constructed from three limbs of 12–15 cm of ileum with a 2 cm exit conduit. An enterostomy is created in an S-shape and the ileal segments are approximated with running sutures.

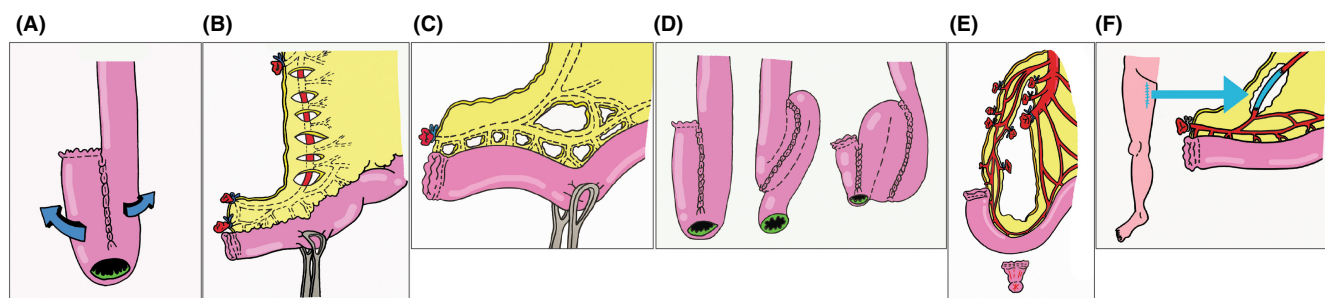
The J- and S-pouch techniques are included in our current review as both techniques were most frequently described in the 19 included studies. These techniques, including the W-pouch, which is not described in the included literature, are shown in Figure 2(D). One review [2], two human cadaver studies [8, 19], four expert opinions [22, 23, 25, 27] and one case report [4] described the construction of a J- or S-pouch. Two expert opinions



**TABLE 2** Description of additional length per surgical technique.

Technique	Description	Additional length
Pouch folding	The pouch is folded to lie anteriorly and the mesentery posteriorly in relation to the body [16]	0.5–1 cm [2, 16]
Stepladder relaxing incisions	Serial (three to six) incisions are made horizontally through the mesentery of the small intestine [1–3, 22, 23, 25, 26]	2–8 cm [1–3, 26]
Skeletonizing vessels in the mesentery	Emptying of the mesenteric vessels from specific structures to decrease the thickness, thus enabling excision or clamping and diminishing bleeding [22]	Not reported
Construction of an S-pouch	An ileal pouch that is surgically designed to have an S-shape [2, 4, 22]	1–3 cm [2, 22]
Division and ligation of mesenteric vessels	Mesenteric vascular division [2, 8]	2–4 cm [8]
	Division of the ICA [5, 6, 18–20, 22, 27]	2–12.5 cm [6, 18–20, 22]
	Division of the SMA [5, 6, 16–20, 22, 23, 25–27]	2.1–6.5 cm [6, 17, 19, 20]
	Division of the TIM [6]	11.2 cm [6]
	Division of the RCA [6]	Not reported
	Division of the MVA [18]	Not reported
	Division of the ICA and SMA [18]	Not reported
	Division of the ICA and MVA [18]	Not reported
	Division of the ICA and RCA [6]	7.5 cm [6]
	Division of the RCA, ICA and SMA [2–4, 6]	3.6 cm [6]
	Division of the RCA, SMA and MCA [3]	Not reported
	Vascular ligation between colon wall and MVA [19]	Not reported
	Division mesentery close to the caecum to preserve the ICA [5]	Not reported
	Division of the SMA without preserving any of the colic or marginal arteries [3]	Not reported
Division of one to three arcade vessels between the vasa recta and the terminal branch of the SMA [5]	1–2 cm [5]	
Division of vessels between primary and secondary arcades [26]	2–5 cm [26]	
Interposition vein graft VSM	Extending the length of the small-bowel mesentery by division by the SMA and use of an interposition saphenous vein graft for reconstruction is a useful technique [21]	6 cm [21] depending on required length

Abbreviations: ICA, ileocolic artery; MCA, middle colic artery; MVA, marginal vascular arcade; RCA, right colic artery; SMA, superior mesenteric artery; TIM, terminal ileal mesentery.

**FIGURE 2** The six surgical lengthening techniques: (A) pouch folding anterior and posterior; (B) stepladder incisions; (C) skeletonization of vessels; (D) J-, S- and W-pouches; (E) division and ligation of the ileocolic artery, marginal artery of the colon and the right colic artery; (F) interposition vein graft.

[23, 27] and one case report [4] mentioned the construction of a J-pouch without further explanation. The review [2] only refers to one of the human cadaver studies [19]. So, in summary, only four articles described the additional length. One human cadaver study compared the S- and J-pouch configuration in nine human cadavers and found that the S-pouch consistently reached a mean of 2.7 cm further below the pubic symphysis when compared with the J-pouch [8]. Another human cadaver study found that in eight out of 13 cases (62%) S-shaped pouches reached lower than J-shaped pouches, whereby the overall mean difference between S- and J-pouches was 0.68 cm [19]. The two remaining expert opinion publications described an advantage of 2–4 cm in favour of an S-shaped pouch without referring to any study results or other scientific literature [22, 25].

### Division and ligation of mesenteric vessels

This technique is widely described in the literature as the main manoeuvre for creating additional mesenteric length. Different combinations of ligating vascular arcades or arteries have been described. One review [2], five expert opinions [22, 23, 25–27], five human cadaver studies [3, 6, 8, 19, 20], four retrospective studies [5, 16–18] and one case report [4] described a total of 15 potential options. Division of the ileocolic artery (ICA) and division of the superior mesenteric artery (SMA) are the most common options for meticulous ligation of blood vessels with an additional length of respectively 2–12.5 cm [6, 18–20, 22] and 2.1–6.5 cm [6, 17, 19, 20]. Other arteries that can be ligated are the terminal ileal mesentery (TIM), right colic artery (RCA), marginal vascular arcade (MVA) and middle colic artery (MCA). An example of ligation of the MCA, RCA and ICA is shown in Figure 2(E). Two studies advise preservation of the MVA for vascularization of the terminal ileum but ligation of the ICA, RCA and SMA [6, 18]. This will lead to an increase in mesenteric length of 36.5%. One human cadaver study showed that division of the SMA will lead to a greater increase in mesenteric length than division of the ICA [20]. Taken together, when performing IPAA, care should be taken to preserve vascularization to prevent pouch failure and anastomotic leakage. Previous literature does not show consensus on the most safe and efficient option to gain sufficient length by division and ligation of mesenteric vessels.

### Interposition vein graft

One case study reported use of the greater saphenous vein to overcome the deficit in length, as shown in Figure 2(F) [21]. The vein was harvested from the groin, reversed and anastomosed proximally to the superior mesenteric artery and distally to one of the arteries of the mesentery. This artery is described as a '4-mm artery' without further specifications. This study mentioned that this technique should be used as a last resort.

## DISCUSSION AND CONCLUSION

This systematic review reports all previous described surgical lengthening techniques to achieve adequate length for a tension-free IPAA. These techniques include pouch folding, stepladder incisions, skeletonization of vessels, construction of a J- or S-pouch, division and ligation of mesenteric vessels, and the use of an interposition vein graft. In cases of significantly shortened mesenteric bowel, IPAA surgeons should integrate the various mesenteric lengthening techniques into their operative algorithm to create a tension-free IPAA.

All techniques described support IPAA surgeons in clinical decision-making during surgery when there is a case of short mesenteric length. On the other hand, these techniques theoretically have the potential to damage the blood supply to the pouch. No doubt exists that an anastomosis under tension or without sufficient blood supply increases the risk of postoperative complications, ranging from subclinical anastomotic leak to ischaemia, pouch necrosis, fistula formation and pelvic sepsis. Furthermore, anastomotic leak and pelvic sepsis have been proven to be strongly associated with a higher risk of poor function and pouch failure [31]. Interestingly, only four out of 19 studies [16–18, 23] included in the current systematic review reported the presence of postoperative complications and three studies claimed to have none during follow-up [1, 4, 5]. None of the included studies investigated the association between the use of specific lengthening techniques and the presence of postoperative morbidity. Overall, in our included studies, lower postoperative complication rates were reported when compared with other scientific papers reporting postoperative morbidity after IPAA surgery. This may be partly explained by the fact that multiple case reports were included in our systematic review and that most of the studies did not report postoperative complications at all.

Besides the technical considerations for creating the optimal anastomosis, other factors, such as patient-related factors are known to influence the anastomosis. Our included studies identified obesity, height, a narrow pelvis, thick mesentery, short vessels and diffuse adhesions due to prior surgery or previous small bowel resection as conditions for predicting difficulty in creating a tension-free anastomosis [3, 16, 20, 22, 25]. Preoperative imaging could be useful to identify short mesenteric vessels so the operating plan can be adjusted if necessary. However, none of the included studies performed preoperative imaging. Only one study suggested that preoperative angiographic imaging is not necessary [17].

Division and ligation of the mesenteric vessels is often used as a lengthening technique. To ensure good vascularization of the terminal ileum after division, vascular clamps are used for temporary occlusion. This 'clamping test' is described in eight studies to ensure pouch viability [3, 4, 16–19, 22, 27]. Mesenteric arteries can be divided safely if vascular pulsations remain and the colour does not change after 15 min of clamping [17, 22]. Balancing between adequate length and sufficient perfusion may be challenging. Intraoperative fluorescence angiography using indocyanine

green is used for assessment of macro- and micro-circulatory status in colorectal surgery [32] and could contribute to prevention of insufficient perfusion [33, 34]. The application of indocyanine green fluorescence in pouch surgery is a promising technique to assess perfusion of the pouch [35, 36]. It can lead to a change of intraoperative management through suture reinforcement of hypoperfused areas or formation of a temporary diverting ileostomy [36]. However, literature on this topic is scarce. To date, four studies have described the use of fluorescence angiography during IPAA, with promising results towards the incidence of postoperative anastomotic leakage [35–38]. Future research should focus on study designs with larger cohorts that can describe the potential added value of fluorescence angiography in IPAA surgery.

Various pouch designs are being used in IPAA surgery including the J-, S- and W-shaped pouches [28]. The J-pouch is the most often used design. In our systematic review, we showed an advantage of 2–4 cm additional length when using an S-pouch instead of a J-pouch. Hence, an S-pouch is more often created when there remains excessive tension on the IPAA. Besides creating enough length and making a tension-free anastomosis, postoperative complications and long-term functional outcomes should be considered when choosing a pouch design. Lovegrove et al. performed a large meta-analysis on the perioperative outcomes for different pouch designs, including 19 studies with 1519 patients with a J-, S- or W-pouch [28]. Among these three types of pouch design, no significant differences were found in postoperative complications (i.e. anastomotic leak, stricture, pelvic sepsis, pouchitis, small bowel obstruction and pouch failure). In terms of functional outcomes, bowel frequency and the use of antidiarrheal medication was higher in patients with a J-pouch. However, patients with an S- or W-pouch had more difficulty in pouch evacuation, resulting in a lower quality of life [28, 29]. Taken together, it seems favourable to create a J-pouch with good functional outcome in most cases, and only switch to an S- or W-design when there is inadequate length.

When adequate length is still not achieved, even after several lengthening techniques, another technique has been used in our hospital. This technique, called the floating pouch, has not yet been described in the literature. The pouch is created and thereafter left in the pelvis with a proximal diverting ileostomy. A second surgery, about a half year later, takes place to create the anastomosis. In our experience, the vessels have gained enough length for sufficient reach and the final anastomosis is created. Future studies are needed to investigate this lengthening technique.

The current systematic review has certain strengths and limitations. To the best of our knowledge, this is the first systematic review to report all different available surgical lengthening techniques in IPAA surgery. Fifteen years ago, Uraiqat et al. published an overview including four different surgical lengthening techniques based on eight selected studies [2]. However, no systematic search was conducted in their review. In addition, the images drawn by one of the current authors visually support the reader in understanding all different surgical lengthening techniques.

This current systematic review has some limitations. Although we identified various surgical lengthening techniques, it was not possible to investigate the association between these different surgical techniques and the risk of developing postoperative complications. Furthermore, an initial objective of this study was to identify an adequate length for creating an ileal pouch. While most studies use the pubic symphysis as a landmark, there is no consensus in the literature about which part of the pubic symphysis should be used to assess reach, leading to unclear definitions and thus making comparisons between studies more difficult. Also, one could hypothesize that adequate length differs per patient. It is most important that the pouch can be created without tension on the pouch–anal anastomosis. Prospective studies on this topic, including preoperative measured length of the pelvis and pubic symphysis, could be considered to define this crucial factor. Another limitation of this study is that the findings of this systematic review may be somewhat limited by the medium quality of the included studies. No prospective or randomized controlled trials have been performed regarding this topic.

In conclusion, this manuscript describes a step-by-step approach in the operative algorithm: pouch folding, stepladder incisions, skeletonization of vessels, construction of a J- or S-pouch, division and ligation of mesenteric vessels, and the use of an interposition vein graft.

Future research should primarily focus on study designs that describe and evaluate new techniques such as the floating pouch and intraoperative fluorescence angiography using indocyanine green. In addition, the definition of ‘adequate length’ should be examined, including the method for measuring the length of the pouch.

#### FUNDING INFORMATION

None declared.

#### CONFLICT OF INTEREST STATEMENT

None declared.

#### ETHICAL APPROVAL

As a systematic review, approval from the Medical Ethics Review Committee was not required.

#### DATA AVAILABILITY STATEMENT

The data that support the findings of this study are available from the corresponding author upon reasonable request.

#### ORCID

Marije Zwakman  <https://orcid.org/0000-0002-3060-7431>

Jara E. Jonker  <https://orcid.org/0000-0002-8012-266X>

#### REFERENCES

- Baig MK, Weiss EG, Noguera JJ, Wexner SD. Lengthening of small bowel mesentery: stepladder incision technique. *Am J Surg.* 2006;191(5):715–7. <https://doi.org/10.1016/j.amjsurg.2005.08.032>
- Uraiqat AA, Byrne CMD, Phillips RKS. Gaining length in ileal-anal pouch reconstruction: a review. *Colorectal Dis.* 2007;9(7):657–61. <https://doi.org/10.1111/j.1463-1318.2006.01181.x>

3. Ismail E, Açar HI, Arslan MN, Çoban İ, Cömert A, Aşlar AK, et al. Comparison of mesenteric lengthening techniques in IPAA: an anatomical and angiographic study on fresh cadavers. *Dis Colon Rectum*. 2018;61(8):979–87. <https://doi.org/10.1097/DCR.0000000000001133>
4. Chu DI, Tognelli J, Kartheuser AH, Dozois EJ. Strategy for the difficult-to-reach ileal pouch-anal anastomosis: technical steps of an in vivo application of a mesenteric-lengthening technique. *Tech Coloproctol*. 2015;19(11):705–9. <https://doi.org/10.1007/s10151-015-1374-6>
5. Thirlby RC. Optimizing results and techniques of mesenteric lengthening in ileal pouch-anal anastomosis. *Am J Surg*. 1995;169:499–502.
6. Goes RN, Nguyen P, Huang D, Beart RW. Lengthening of the mesentery using the marginal vascular arcade of the right colon as the blood supply to the ileal pouch. *Dis Colon Rectum*. 1995;38(8):893–5.
7. Parks AG, Nicholls RJ. Proctocolectomy without ileostomy for ulcerative colitis. *Br Med J*. 1978;2(6130):85–8. <https://doi.org/10.1136/bmj.2.6130.85>
8. Smith L, Friend WG, Medwell SJ. The superior mesenteric artery the critical factor in the pouch pull-through procedure. *Dis Colon Rectum*. 1984;27:741–4.
9. Wu C, Ye K, Wu Y, Chen Q, Xu J, Lin J, et al. Variations in right colic vascular anatomy observed during laparoscopic right colectomy. *World J Surg Oncol*. 2019;17(1):16. <https://doi.org/10.1186/s12957-019-1561-4>
10. de Martino RR. Normal and variant mesenteric anatomy. In: Oderich GS, editor. *Mesenteric vascular disease*. New York: Springer; 2015. [https://doi.org/10.1007/978-1-4939-1847-8\\_2](https://doi.org/10.1007/978-1-4939-1847-8_2)
11. Tricco AC, Lillie E, Zarin W, O'Brien KK, Colquhoun H, Levac D, et al. PRISMA extension for scoping reviews (PRISMA-ScR): checklist and explanation. *Ann Intern Med*. 2018;169(7):467–73. <https://doi.org/10.7326/M18-0850>
12. The Joanna Briggs Institute. The Joanna Briggs Institute critical appraisal tools for use in JBI systematic reviews, checklist for case reports. The Joanna Briggs Institute Critical Appraisal tools; 2016.
13. The Joanna Briggs Institute. The Joanna Briggs Institute critical appraisal tools for use in JBI systematic reviews, checklist for case series. The Joanna Briggs Institute Critical Appraisal Tools for Use in JBI Systematic Reviews; 2017.
14. The Joanna Briggs Institute. The Joanna Briggs Institute critical appraisal tools for use in JBI systematic reviews, checklist for cohort studies. The Joanna Briggs Institute Critical Appraisal tools; 2016.
15. The Joanna Briggs Institute. Checklist for quasi-experimental (non-randomized experimental studies). JBI; 2020.
16. Rottoli M, Tanzanu M, Lanci AL, Gentilini L, Boschi L, Poggioli G. Mesenteric lengthening during pouch surgery: technique and outcomes in a tertiary Centre. *Updates Surg*. 2021;73(2):581–6. <https://doi.org/10.1007/s13304-021-00984-x>
17. Martel P, Majery N, Savigny B, Sezeur A, Gallot D, Malafosse M. Mesenteric lengthening in ileoanal pouch anastomosis for ulcerative colitis is high division of the superior mesenteric pedicle a safe procedure? *Dis Colon Rectum*. 1998;41(7):862–6.
18. Araki T, Parc Y, Lefevre J, Dehni N, Turet E, Parc R. The effect on morbidity of mesentery lengthening techniques and the use of a covering stoma after ileoanal pouch surgery. *Dis Colon Rectum*. 2006;49(5):621–8. <https://doi.org/10.1007/s10350-005-0322-3>
19. Cherqui D, Valleur P, Perniceni T, Hautefeuille P. Inferior reach of ileal reservoir in ileoanal anastomosis experimental anatomic and angiographic study. *Dis Colon Rectum*. 1987;30(5):365–71.
20. Martel P, Blanc P, Bothereau H, Malafosse M, Gallot D. Comparative anatomical study of division of the ileocolic pedicle or the superior mesenteric pedicle for mesenteric lengthening. *Br J Surg*. 2002;89:775–8.
21. Metcalf DR, Nivatvongs S, Sullivan TM, Suwanthanma W. A technique of extending small-bowel mesentery for ileal pouch-anal anastomosis: report of a case. *Dis Colon Rectum*. 2008;51(3):363–4. <https://doi.org/10.1007/s10350-007-9167-2>
22. Parray FQ. J pouch - how to gain length. *J Surg Emerg Med*. 2016;1:101.
23. Michelassi F, Hurst R. Restorative proctocolectomy with J-pouch ileoanal anastomosis. *Arch Surg*. 2000;135:347–53.
24. Ma RWL, Gold DM. Ileoanal pouch: short mesentery? Lengthen the pouch. *Ann R Coll Surg Engl*. 2011;93(6):488–9. <https://doi.org/10.1308/003588411X592130e>
25. Kirat HT, Remzi FH. Technical aspects of ileoanal pouch surgery in patients with ulcerative colitis. *Clin Colon Rectal Surg*. 2010;23(4):239–47. <https://doi.org/10.1055/s-0030-1268250>
26. Burnstein MJ, Schoetz DJ, Coller JA, Veidenheimer MC. Technique of mesenteric lengthening in ileal reservoir-anal anastomosis. *Dis Colon Rectum*. 1987;30:863–6.
27. Ballantyne GH, Pemberton JH, Beart RW, Wolff BG, Dozois RR. Ileal J pouch-anal anastomosis current technique. *Dis Colon Rectum*. 1985;28:197–202.
28. Lovegrove RE, Heriot AG, Constantinides V, Tilney HS, Darzi AW, Fazio VW, et al. Meta-analysis of short-term and long-term outcomes of J, W and S ileal reservoirs for restorative proctocolectomy. *Colorectal Dis*. 2007;9(4):310–20. <https://doi.org/10.1111/j.1463-1318.2006.01093.x>
29. Mukewar S, Wu X, Lopez R, Shen B. Comparison of long-term outcomes of S and J pouches and continent ileostomies in ulcerative colitis patients with restorative proctocolectomy-experience in subspecialty pouch center. *J Crohns Colitis*. 2014;8(10):1227–36. <https://doi.org/10.1016/j.crohns.2014.02.019>
30. Lovegrove RE, Constantinides VA, Heriot AG, Athanasiou T, Darzi A, Remzi FH, et al. A comparison of hand-sewn versus stapled ileal pouch anal anastomosis (IPAA) following proctocolectomy: a meta-analysis of 4183 patients. *Ann Surg*. 2006;244(1):18–26. <https://doi.org/10.1097/01.sla.0000225031.15405.a3>
31. Esen E, Keshinro A, Remzi FH. Ileoanal pouch: pelvic sepsis and poor function - now what? *J Laparoendosc Adv Surg Tech A*. 2021;31(8):867–74. <https://doi.org/10.1089/lap.2021.0030>
32. Kawada K, Hasegawa S, Wada T, Takahashi R, Hisamori S, Hida K, et al. Evaluation of intestinal perfusion by ICG fluorescence imaging in laparoscopic colorectal surgery with DST anastomosis. *Surg Endosc*. 2017;31(3):1061–9. <https://doi.org/10.1007/s00464-016-5064-x>
33. Jafari MD, Wexner SD, Martz JE, McLemore EC, Margolin DA, Sherwinter DA, et al. Perfusion assessment in laparoscopic left-sided/anterior resection (PILLAR II): a multi-institutional study. *J Am Coll Surg*. 2015;220(1):82–92. <https://doi.org/10.1016/j.jamcollsurg.2014.09.015.e1>
34. van den Bos J, van Kooten L, Engelen SME, Lubbers T, Stassen LPS, Bouvy ND. Feasibility of indocyanine green fluorescence imaging for intraoperative identification of parathyroid glands during thyroid surgery. *Head Neck*. 2019;41(2):340–8. <https://doi.org/10.1002/hed.25451>
35. Spinelli A, Cantore F, Kotze PG, David G, Sacchi M, Carvello M. Fluorescence angiography during transanal trans-stomal proctectomy and ileal pouch anal anastomosis – a video vignette. *Colorectal Dis*. 2018;20(3):262–3. <https://doi.org/10.1111/codi.13992>
36. Joosten JJ, Reijntjes MA, Slooter MD, Duijvestein M, Buskens CJ, Bemelman WA, et al. Fluorescence angiography after vascular ligation to make the ileo-anal pouch reach. *Tech Coloproctol*. 2021;25(7):875–8. <https://doi.org/10.1007/s10151-021-02447-2>
37. Spinelli A, Carvello M, Kotze PG, Maroli A, Montroni I, Montorsi M, et al. Ileal pouch-anal anastomosis with fluorescence angiography: a case-matched study. *Colorectal Dis*. 2019;21(7):827–32. <https://doi.org/10.1111/codi.14611>

38. Freund MR, Kent I, Agarwal S, Wexner SD. Use of indocyanine green fluorescence angiography during ileal J-pouch surgery requiring lengthening maneuvers. *Tech Coloproctol.* 2022;26(3):181–6. <https://doi.org/10.1007/s10151-021-02557-x>

### SUPPORTING INFORMATION

Additional supporting information can be found online in the Supporting Information section at the end of this article.

**How to cite this article:** Zwakman M, Hentzen JEK, Jonker JE, Krikke C, Lange JFM, Hofker SHS. Surgical techniques for mesenteric lengthening in ileoanal pouch surgery: a systematic review. *Colorectal Dis.* 2023;25:1079–1089. <https://doi.org/10.1111/codi.16498>