

## University of Groningen

### Permanent, bilateral common carotid artery occlusion in the rat

Farkas, Eszter; Luiten, Paul G. M.; Bari, Ferenc

*Published in:*  
Brain Research Reviews

*DOI:*  
[10.1016/j.brainresrev.2007.01.003](https://doi.org/10.1016/j.brainresrev.2007.01.003)

**IMPORTANT NOTE: You are advised to consult the publisher's version (publisher's PDF) if you wish to cite from it. Please check the document version below.**

*Document Version*  
Publisher's PDF, also known as Version of record

*Publication date:*  
2007

[Link to publication in University of Groningen/UMCG research database](#)

*Citation for published version (APA):*

Farkas, E., Luiten, P. G. M., & Bari, F. (2007). Permanent, bilateral common carotid artery occlusion in the rat: A model for chronic cerebral hypoperfusion-related neurodegenerative diseases. *Brain Research Reviews*, 54(1), 162-180. <https://doi.org/10.1016/j.brainresrev.2007.01.003>

**Copyright**

Other than for strictly personal use, it is not permitted to download or to forward/distribute the text or part of it without the consent of the author(s) and/or copyright holder(s), unless the work is under an open content license (like Creative Commons).

The publication may also be distributed here under the terms of Article 25fa of the Dutch Copyright Act, indicated by the "Taverne" license. More information can be found on the University of Groningen website: <https://www.rug.nl/library/open-access/self-archiving-pure/taverne-amendment>.

**Take-down policy**

If you believe that this document breaches copyright please contact us providing details, and we will remove access to the work immediately and investigate your claim.

*Downloaded from the University of Groningen/UMCG research database (Pure): <http://www.rug.nl/research/portal>. For technical reasons the number of authors shown on this cover page is limited to 10 maximum.*

available at [www.sciencedirect.com](http://www.sciencedirect.com)[www.elsevier.com/locate/brainresrev](http://www.elsevier.com/locate/brainresrev)
**BRAIN  
RESEARCH  
REVIEWS**

## Review

# Permanent, bilateral common carotid artery occlusion in the rat: A model for chronic cerebral hypoperfusion-related neurodegenerative diseases

Eszter Farkas<sup>a,\*</sup>, Paul G.M. Luiten<sup>b</sup>, Ferenc Bari<sup>c</sup>

<sup>a</sup>Department of Anatomy, School of Medicine, University of Szeged, H-6701 Szeged, P.O. Box 427, Hungary

<sup>b</sup>Department of Molecular Neurobiology, University of Groningen, Groningen, The Netherlands

<sup>c</sup>Department of Physiology, School of Medicine, University of Szeged, Szeged, Hungary

### ARTICLE INFO

#### Article history:

Accepted 3 January 2007

Available online 18 January 2007

#### Keywords:

Carotid occlusion  
Cerebral blood flow  
Hippocampus  
Learning  
Rat  
White matter

### ABSTRACT

Chronic cerebral hypoperfusion has been associated with cognitive decline in aging and Alzheimer's disease. Moreover, the pattern of cerebral blood flow in mild cognitive impairment has emerged as a predictive marker for the progression into Alzheimer's disease. The reconstruction of a pathological condition in animal models is a suitable approach to the unraveling of causal relationships. For this reason, permanent, bilateral occlusion of the common carotid arteries (2VO) in rats has been established as a procedure to investigate the effects of chronic cerebral hypoperfusion on cognitive dysfunction and neurodegenerative processes. Over the years, the 2VO model has generated a large amount of data, revealing the 2VO-related pattern of cerebral hypoperfusion and metabolic changes, learning and memory disturbances, failure of neuronal signaling, and the neuropathological changes in the hippocampus. In addition, the model has been introduced in research into ischemic white matter injury and ischemic eye disease. The present survey sets out to provide a comprehensive summary of the achievements made with the 2VO model, and a critical evaluation and integration of the various results, and to relate the experimental data to human diseases. The data that have accumulated from use of the 2VO model in the rat permit an understanding of the causative role played by cerebral hypoperfusion in neurodegenerative diseases. Thorough characterization of the model suggests that 2VO in the rat is suitable for the development of potentially neuroprotective strategies in neurodegenerative diseases.

© 2007 Elsevier B.V. All rights reserved.

\* Corresponding author. Fax: +36 62 545707.

E-mail address: [farkase@anat-fm.szote.u-szeged.hu](mailto:farkase@anat-fm.szote.u-szeged.hu) (E. Farkas).

Abbreviations:  $\alpha 7$ NicR,  $\alpha 7$ -nicotinic acetylcholine receptor; 2VO, permanent, bilateral common carotid artery occlusion, two-vessel occlusion; AD, Alzheimer's disease; APP, amyloid precursor protein; BBB, blood–brain barrier; BDNF, brain-derived neurotrophic factor; CBF, cerebral blood flow; CgA, chromogranin A; COX-2, cyclooxygenase-2; Cu/Zn-SOD, Cu/Zn-superoxide dismutase; DG iml, dentate gyrus inner molecular layer; DG, dentate gyrus; EEG, electroencephalogram; EP, encephalogenic peptide; GAP-43, growth-associated protein-43; GFAP, glial fibrillary acidic protein; GSH, glutathione; H&E, hematoxylin–eosin; HPC, hippocampus; IDE, insulin-degrading enzyme; IPL, retina inner plexiform layer; MAP-2, microtubule-associated protein-2; MBP, myelin basic protein; MDA, malondialdehyde; MMP-2, matrix metalloproteinase-2; Nep, neprilysin; NO, nitric oxide; OPL, retina outer plexiform layer; or, hippocampus CA1 stratum oriens; pyr, hippocampus CA1 stratum pyramidale; rad, hippocampus CA1 stratum radiatum; ROS, reactive oxygen species; Sec,  $\gamma$ -secretase; SHAM, sham-operated control; WM, white matter

---

## Contents

1. Introduction . . . . .	163
2. The spatial and temporal patterns of blood flow in experimental cerebral hypoperfusion. . . . .	164
2.1. Cerebral blood flow and metabolism . . . . .	164
2.2. Compensatory mechanisms . . . . .	166
3. The effects of chronic cerebral hypoperfusion on the blood–brain barrier. . . . .	166
4. Alterations in the electrophysiological activity of the brain during chronic cerebral hypoperfusion . . . . .	167
5. Impairment of learning and memory in chronic cerebral hypoperfusion . . . . .	167
6. Neuropathologic changes induced by chronic cerebral hypoperfusion in the brain. . . . .	168
6.1. Neuronal damage . . . . .	168
6.2. Astrocytic reactions . . . . .	170
6.3. Microglial activation . . . . .	170
6.4. Potential mechanisms for neurodegeneration . . . . .	170
7. Chronic cerebral hypoperfusion-related white matter injury . . . . .	170
8. The effects of chronic cerebral hypoperfusion on the visual system. . . . .	172
9. Systemic changes following experimental cerebral hypoperfusion. . . . .	173
9.1. Body weight . . . . .	173
9.2. Blood pressure . . . . .	174
9.3. Plasma hormone concentration . . . . .	174
9.4. Leukocyte stimulation . . . . .	174
9.5. Diagnostic prospects . . . . .	175
10. Methodological considerations . . . . .	175
10.1. Species and strains . . . . .	175
10.2. Anesthetics. . . . .	175
10.3. Other technical approaches. . . . .	175
10.4. Standardization . . . . .	176
11. Summary and conclusions . . . . .	176
Acknowledgments . . . . .	177
References. . . . .	177

---

## 1. Introduction

Disorders of the cerebral circulation are the causes of or factors contributing to numerous neurological and psychiatric illnesses. A sudden disruption of the blood supply to distinct brain regions leads to stroke, while a moderate but persistent reduction in regional cerebral blood flow (CBF) compromises memory processes and contributes to the development and progression of dementia. The association of decreased CBF, particularly in the temporal and parietal cortices, with Alzheimer's disease (AD) has been firmly established (de la Torre, 2002; Farkas and Luiten, 2001; Matsuda, 2001). Additionally, the degree or pattern of cerebral hypoperfusion in mild cognitive impairment has been suggested as a predictive marker for the progression to AD (Borroni et al., 2006; Hirao et al., 2005). Furthermore, global cerebral hypoperfusion can occur in patients who have suffered a cardiac arrest or those who undergo complex cardiac surgery, and this condition can lead to a poor neurologic outcome (Hypothermia after Cardiac Arrest Study Group, 2002; Nussmeier, 2002). For an understanding of the role of the cerebrovascular pathology in the development of a cognitive dysfunction and dementia, it is important to explore the cerebral hypoperfusion-related metabolic changes, the distinct neurodegenerative and cognitive correlates of hypoperfusion, and the causal relation-

ships between these factors. Furthermore, recognition of particular mechanisms in the chain of events from chronic cerebral hypoperfusion to a cognitive decline may identify potential targets for effective therapies. For these purposes, a number of animal models have been introduced.

Vessel occlusion studies aim at creating ischemic or oligemic injuries with various degrees of severity in the brains of experimental animals. The rat is a frequently used species in consequence of the good survival rate, the satisfactory recovery from surgery, the easy and reproducible behavioral testing, the relatively low costs, and ethical acceptance. A great variety of rat vessel occlusion models have emerged, most of which are applied in stroke research. Since stroke is an acute pathophysiological condition, the experimental stroke models are generally employed to investigate the short-term effects of vessel occlusion, and the possibilities of rapid interventions designed to limit neurodegenerative processes. To this end, two experimental approaches have evolved in the rat: transient occlusion of the middle cerebral artery and permanent occlusion of extracranial vessels (e.g. vertebral and carotid arteries) in combination with experimental hypotension or hypoxia. In the frequently used transient ischemia models, there is an obvious component of reperfusion, the brain damage is focal and severe, the ischemic site can typically be divided into a core and a penumbra region,

motor dysfunction evidently appears as a functional correlate of the brain damage, and even seizures may develop.

For the reproduction of chronic cerebral hypoperfusion as it occurs in human aging and AD, permanent, bilateral occlusion of the common carotid arteries of rats (2-vessel occlusion, 2VO) has been introduced. The rat is a suitable rodent species for this purpose because the complete circle of Willis affords incessant (but reduced) blood flow after the onset of 2VO. In contrast, the lack or the underdevelopment of the posterior communicating arteries of the circle of Willis causes severe ischemia during 2VO in gerbils and most of the mouse strains. In the rat 2VO model, the surgical methods, the permanent nature of the ligation of the common carotid arteries, the lack of exacerbating factors (hypotension or hypoxia), and the experimental animal species (the rat) are standard, and therefore the 2VO model can be regarded as a single defined entity from a technical point of view. As opposed to stroke research, 2VO studies have the aim of investigation of the long-term effects of chronic cerebral hypoperfusion. In 2VO rats, the vessel occlusion is permanent and long-lasting, reperfusion injury (as a result of an instant recovery of perfusion) does not occur, the cerebral hypoperfusion is global, and thus a distinct ischemic core and penumbra region cannot be outlined, the damage to the nervous tissue is less dramatic, and there are no obvious signs of motor dysfunction or seizures.

In aging and AD, the sequence of the events of cerebral hypoperfusion and neurodegeneration has been a subject of debate. A chronic reduction in CBF was earlier believed to induce the neurodegenerative processes; however, the view was also raised that an earlier neuronal cell loss would require a consequently lower supply of energy substrates, and therefore a lower perfusion rate. Following the introduction of the concept of the neurovascular unit (the functionally integrated network of neural and vascular cells), this controversy can be explained: damage to any of the components of the unit results in consequences to the functioning of the entire unit.

With the help of the 2VO model, the causal and sequential interactions of cerebral hypoperfusion, neuronal injury and memory deficits have been elucidated. Experimental evidence has demonstrated the initiating role of chronic cerebral hypoperfusion in neural damage to the hippocampus, the cerebral cortex, the white matter (WM) areas and the visual system. Because of the vulnerability of the WM, the retina and the visual pathways, the 2VO model has recently been applied with success in other research fields, such as ischemic WM injury and ischemic eye diseases.

The aims of the current review are to provide a comprehensive survey of the experimental evidence that has accumulated from use of the 2VO model in the rat, to relate the results to human neurological conditions, and to consider the particular subtleties and pitfalls of the method.

## 2. The spatial and temporal patterns of blood flow in experimental cerebral hypoperfusion

It has been well established that aging and dementia are accompanied by a reduced CBF (Farkas and Luiten, 2001). The degree of cerebral hypoperfusion observed in clinical studies

ranges from ~94% in the parietal and temporal cortices of elderly individuals as compared with younger volunteers (Claus et al., 1998) to ~73% in the same regions and the hippocampus of AD patients as compared with age-matched, healthy controls (Farkas and Luiten, 2001). In order to tackle the neurological and neuropathological consequences of such a reduction in CBF, a similar condition must be created in experimental animals. 2VO rats have long been employed to examine the role of cerebral hypoperfusion in neurodegenerative processes. However, the flow pattern in 2VO rats does not perfectly match that in aging or demented humans. The CBF and cerebral metabolism change dynamically following the onset of 2VO: the CBF drops sharply immediately after occlusion induction and normalizes over months via compensatory and adaptive mechanisms. There is a relatively long period of time, during which the cerebral hypoperfusion in 2VO rats is comparable to that in humans. It is first necessary to outline the alterations in CBF and related metabolic rates in 2VO rats.

### 2.1. Cerebral blood flow and metabolism

The regional CBF in selected brain structures has been measured at a number of time points after 2VO has been produced, ranging between 2.5 h and 6 months (Table 1). The greatest reduction in CBF (to ~35–45% of the control level) was recorded in the cortical and WM areas, the CBF in the hippocampus decreasing to a lesser extent (to ~60% of the control) (Ohta et al., 1997; Otori et al., 2003; Tsuchiya et al., 1992; Ulrich et al., 1998). The CBF values had already started to gradually recover at 1 week, but were still significantly lower than the control values 4 weeks after 2VO induction (Otori et al., 2003; Schmidt-Kastner et al., 2001; Tomimoto et al., 2003; Tsuchiya et al., 1992). Between 8 weeks and 3 months, either only a slight reduction or virtually no reduction has been reported (Ohta et al., 1997; Otori et al., 2003). Finally, after 6 months of 2VO, the CBF was indistinguishable from the control (Choy et al., 2006). Besides the basal flow, the cerebrovascular reactivity was also negatively affected. The CBF responses to challenges with acetazolamide (a vasodilator through the inhibition of carbonic anhydrase) were impaired from 30 min to 6 weeks after 2VO initiation (Ulrich et al., 1998).


A number of the components of the brain metabolism have been characterized in the 2VO model, but there has been no comprehensive study to demonstrate the parallel changes in different variables such as the glucose metabolism, the ATPase activity, and the ATP and lactate concentrations. Nevertheless, the individual studies that offer data on these variables help in the construction of an overview. The cerebral glucose utilization was found to follow the reduction in CBF with an initial delay and a more rapid recovery (Otori et al., 2003; Tsuchiya et al., 1993). Furthermore, sudden depletions of ATP and phosphocreatine were detected in the cerebral cortex 5–10 min after 2VO induction and persisted, though to a lesser extent, for 2 weeks (Briede and Duburs, *in press*; Plaschke, 2005). The concentration of ATP was restored to the control level at 8 weeks, while that of phosphocreatine still remained significantly decreased (Plaschke, 2005). Finally, the ATPase activity was considerably decreased, and the lactate concentrations in the hippocampus and cortex were increased 2.5-

**Table 1 – Cerebral blood flow in chronic cerebral hypoperfusion**

Method	Rat strain	Anesthesia	Brain region (a selection)	Time of sampling/Value (% of control)				Reference
				2 days	1 week	4 weeks	8 weeks	
<sup>14</sup> C]iodo-antipyrine	Wistar, (12 weeks old, 300–400 g)	1% halothane	Parietal cortex	45.7	44.9	69.8	92.5	Otori et al. (2003)
			Temporal cortex	35.8	40.4	79	104.5	
			Hippocampus CA1	78.4	67.6	66.3	100.5	
			Thalamus	61	57.8	78.1	108.5	
			Corpus callosum	33.3	41.8	56.4	81.3	
				1 week				
<sup>14</sup> C]iodo-antipyrine	Wistar (250–300 g)	3% halothane	Parietal cortex	63				Schmidt-Kastner et al. (2001)
			Temporal cortex	57				
			Hippocampus	75				
			Thalamus	76				
				2.5 h	1 week			
<sup>14</sup> C]iodo-antipyrine	Wistar (150–270 g)	1.5–2% halothane	Frontal cortex	36	65.5			Tsuchiya et al. (1992)
			Parietal cortex	30.5	62.8			
			Hippocampus CA	51.2	73.6			
			Medial thalamus	49.4	79.8			
			Corpus callosum	48.8	72.1			
				After 2VO onset	6 months			
Arterial spin labeling/ spin-echo echoplanar imaging	Sprague–Dawley (200–370 g)	2% halothane	Cortex	33.6	92.6			Choy et al. (2006)
			Hippocampus	58.3	103.1			
			Thalamus	69.5	106.6			
				2 days	10 days	3 months		
Colored microsphere method	Wistar (9 weeks old)	50 mg/kg sodium pentobarbital	Anterior cortex	~54	~60	~82		Ohta et al. (1997)
			Posterior cortex	~47	~58	~80		
			Hippocampus	~65	~66	~96		
				1–3 days	1 week	2 weeks	30 days	
Laser Doppler flowmetry	Wistar (200–250 g)	25 mg/kg sodium pentobarbital	Corpus callosum	32–33.6	52.3	59.1	64	Tomimoto et al. (2003)
							1 h	
Laser Doppler flowmetry	Sprague–Dawley (290–340 g)	0.8–1.5% halothane	Frontoparietal cortex	<35				Busch et al., 2003
Laser Doppler flowmetry	Wistar–Kyoto (304–445 g)	3.6 mg/kg chloral hydrate	Cortex	62–69%				Ulrich et al. (1998)

fold 34 days after the onset of 2VO (Shang et al., 2005). These data indicate that the changes in CBF can be divided into three phases with a gradual transition with regard to the metabolic and homeostatic state of the tissue (Fig. 1). The acute phase immediately after the start of occlusion lasts for a maximum

of 2–3 days. The CBF falls dramatically at once and remains very low in this period, creating hypoxic–ischemic conditions, which may compromise the electrophysiological activity of the nervous tissue (Marosi et al., 2006). A phase of chronic hypoperfusion follows, lasting for 8 weeks–3 months. This



**Fig. 1 – The successive phases of chronic cerebral hypoperfusion induced by permanent, bilateral occlusion of the common carotid arteries in the rat. The phases were determined theoretically from the degree of cerebral perfusion, the metabolic status and the electrophysiological activity of the nervous tissue. Abbreviations: 2VO: permanent, bilateral common carotid artery occlusion; CBF: cerebral blood flow.**

hypoperfusion is believed to sustain chronic, moderate hypoglycemia, which corresponds with oligemia. This is the phase which most closely resembles the condition of reduced CBF in human aging and dementia. In the final phase of restitution, the CBF returns to the baseline, and the cerebral hypoperfusion, together with the suboptimal metabolism, gradually ceases.

## 2.2. Compensatory mechanisms

The finding that CBF normalizes over a period of months in the 2VO model, even though the occlusion is permanent, indicates that compensatory or adaptive mechanisms are turned on. Compensatory blood flow may be provided through artery dilation, the recruitment of nonperfused capillaries (if there are such in the brain), and angiogenesis. Biochemical regulation of the CBF may also play a significant part in the adaptation.

In support of these views, experimental evidence has been acquired on the enlargement of the arteries at the base of the brain. The posterior vessels contributing to or emanating from the circle of Willis (e.g. the basilar artery, the posterior cerebral artery, and the posterior communicating artery) exhibited considerably increased post mortem diameter 15 weeks–6 months after the onset of 2VO (Choy et al., 2006; Oldendorf, 1989). The initial arterial dilation is probably flow-induced, involving the activation of nitric oxide synthase, NADPH oxidase, and phosphatidylinositol-3 kinase (Paravicini et al., 2006). Furthermore, vascular remodeling and arteriogenesis take place, as indicated by the appearance of extracranial collaterals emanating from the vertebral arteries and by the tortuosity of the basilar and vertebral arteries (Choy et al., 2006; Oldendorf, 1989).

At the level of the microvessels, the specific compensatory mechanisms are still uncertain. Nitric oxide (NO) is a very potent vasodilator, which is released at increased concentration in the brain parenchyma in response to cerebral ischemic insults. The role of NO in ischemic brain injuries is complex and controversial, but a recent investigation has demonstrated the beneficial effects of NO in elevating blood flow and promoting angiogenesis (Keynes and Garthwaite, 2004). There

are few data on the cerebral concentration of NO in 2VO rats. One study has revealed that the NO concentration in the hippocampus is considerably elevated 2 weeks after 2VO induction, but the authors did not attempt to relate this finding to the vasoregulation (de la Torre et al., 2003). On the other hand, an increased capillary diameter, neovascularization, and an enhanced immunocytochemical signal for vascular endothelial growth factor were noted in the cortex and hippocampus after 4 weeks of 2VO. However, the findings were not confirmed at 13 weeks (de Wilde et al., 2002; Ohtaki et al., 2006). The discrepancy between these results may indicate the occurrence of dynamic, microvascular remodeling following the changes in CBF: growth factors may induce angiogenesis at lower perfusion rates (at early time points after 2VO onset), while the capillary network may readjust to its original density as the CBF normalizes.

In summary, the chronic, oligemic phase of 2VO (Fig. 1) seems to correspond best to the chronic cerebral hypoperfusion in human aging and dementia. However, in an evaluation of its neuropathological consequences, the preceding acute phase cannot be ignored. In order to distinguish the initial, acute neuronal injury from the later, chronic damage, samples must be taken from both the acute phase and the chronic phase. Briefly, in support of chronic neurodegeneration as opposed to the acute injury in the model, the first signs of hippocampal damage in hematoxylin–eosin-stained sections appeared 1 week after the initiation of 2VO and gradually extended to the cortex during 4 weeks (Ohtaki et al., 2006). Total unilateral destruction of the hippocampus could not be seen after 2 weeks of 2VO, but was observed in more than half of the animals after 13 weeks (Farkas et al., 2004b). An assessment in the Morris water maze revealed that the spatial memory gradually worsened as the survival times extended from 4 weeks up to 20 weeks after the ligation of the vessels (Liu et al., 2005). These results promote the hypothesis that the most extensive neurodegenerative process takes place during the chronic phase of 2VO-induced cerebral hypoperfusion (see also the section Neuropathologic changes induced by chronic cerebral hypoperfusion in the brain).

## 3. The effects of chronic cerebral hypoperfusion on the blood–brain barrier

The blood–brain barrier (BBB), the interface between blood-borne molecules and the central nervous system, is quite vulnerable to ischemia. For example, the BBB becomes readily permeable to large molecules in a severely ischemic environment (Lenzér et al., 2005; Preston and Foster, 1997). However, there is little evidence of disruption of the BBB during healthy aging (Mooradian, 1988; Stewart et al., 1987), and only a few studies have indicated actual leakage of the BBB in AD (Schlageter et al., 1987; Wisniewski et al., 1997). Similarly, to the best of our knowledge, no evidence has been presented for the opening of the BBB in 2VO rats. Accordingly, we propose that the relatively mild ischemia/oligemia created by cerebral hypoperfusion is insufficient to harm the isolating function of the BBB, probably because disruption of the BBB is normally an acute reaction to severe ischemia, rather than a chronically developing pathology.

On the other hand, the BBB displays ultrastructural abnormalities in the form of basement membrane thickening and fibrous collagen deposits, which develop chronically during aging and dementia (Farkas and Luiten, 2001). The accumulation of collagen fibers in the microvascular basement membrane may hinder specific BBB transport for important nutrients such as glucose and essential amino acids and could hamper the fine regulation of the regional CBF (Farkas and Luiten, 2001). In the aging brain, a significant correlation has been established between collagen deposits in the microvascular wall and advancing age in the frontal and occipital WM (Farkas et al., 2006a). Furthermore, in AD, the proportion of capillaries displaying collagen accumulation in the microvascular basement membrane in the cingulate cortex was considerably higher than in age-matched controls (Farkas et al., 2000). Whether such basement membrane pathology is related to cerebral hypoperfusion has been tested in the 2VO model. Electron microscopic examination revealed microvascular basement membrane thickening and collagen deposits comparable to those seen in the human post mortem studies after 14 months of 2VO. The proportion of affected capillaries in the hippocampus in 2VO rats almost doubled as compared with controls (De Jong et al., 1999). A similar analysis did not demonstrate significant basement membrane pathology 13 weeks after 2VO onset (de Wilde et al., 2002). As very old rats (30 months) not subjected to any surgical intervention also displayed marked capillary basement membrane pathology (De Jong et al., 1990), chronic cerebral hypoperfusion is suggested to be a causative, accelerating condition for such age-related BBB damage.

In conclusion, the condition of the BBB in 2VO rats appears to correspond closely to microvascular damage in the human. While breaching of the BBB in human conditions or experimental cerebral hypoperfusion cannot be clearly proven, the capillary basement membrane pathology in the 2VO model is very similar to the situation in human aging and dementia. Chronic cerebral hypoperfusion is therefore regarded as a causative factor of human BBB damage in aging and AD.

#### 4. Alterations in the electrophysiological activity of the brain during chronic cerebral hypoperfusion

Relatively few studies have recorded hypoperfusion-induced changes in the electrophysiological activity of the rat brain. The retina of 2VO rats has been flash-stimulated, and visual evoked potentials recorded from the occipital cortex. The latency of the positive peaks ( $P_2$ ) was increased, while the amplitude (the difference between the negative and positive peaks,  $N_2-P_2$ ) was diminished 10 days after 2VO induction (Aytac et al., 2006). However, these results may not reflect the failing activity of the cerebrocortical neurons because the retina, the optic nerves, and the optic tract are extensively injured by the 2VO-induced hypoperfusion (see also the section The effects of chronic cerebral hypoperfusion on the visual system (Farkas et al., 2004a; Ohta et al., 1997; Stevens et al., 2002)).

Another set of experiments has furnished more reliable data on the electrophysiological activity of the hippocampus

CA1 subfield after the onset of 2VO. Here, the unilateral CA3 region of the hippocampus was electrically stimulated, and the stimulation-evoked population spikes in the contralateral CA1 were recorded. Between 80 and 150 min after the onset of 2VO, the evoked population spike amplitudes decreased dramatically and became undetectable. However, this functional impairment proved to be reversible. When the experiment was performed 3 days after the induction of 2VO, the evoked population spikes no longer differed from those in the sham-operated controls (Marosi et al., 2006). The explanation for this surprising recovery is twofold: first, the silencing of the CA1 pyramidal cells was not followed by immediate neuronal cell death, but possibly by metabolic adaptation; and second, the blood flow to the hippocampus has been shown to start recovering already on the second day after occlusion of the vessels (Tsuchiya et al., 1992), which may contribute to the returning functional activity of the pyramidal cells. It would be interesting to repeat the experiment at a later time (2–10 weeks), when hippocampal neuronal cell death is obvious.

In another experimental approach, the electroencephalogram (EEG) was recorded in rats in the acute phase of 2VO. In half of the animals, slow waves with reduced amplitudes appeared initially in the EEG, the rhythm of the EEG then gradually disappeared, and finally, 300–400 s after the induction of 2VO, the EEG became isoelectric (Briede and Duburs, in press). Again, it would be of interest to know how the EEG changes over a longer period of time, in the chronic phase of cerebral hypoperfusion.

The extinction of electrophysiological activity in the acute phase of cerebral hypoperfusion appears to be consistent with the opinion on ischemic thresholds: as the CBF gradually decreases, the oligemia shifts to ischemia, which is defined by the affected electrical function of the neurons. Neurons can be rescued in the upper range of ischemia, before massive  $K^+$  efflux occurs (Obrenovitch, 1995). This may also be the mechanism responsible for the return of evoked population spikes reported by Marosi et al. (2006).

#### 5. Impairment of learning and memory in chronic cerebral hypoperfusion

The hypothesis that chronic cerebral hypoperfusion contributes to the progression of dementia was proposed long ago (de la Torre, 2000; Farkas and Luiten, 2001). Traditionally, the two most frequently used tests to measure the hippocampus-related spatial learning capacity in chronic cerebral hypoperfusion in rats are the Morris water maze and the 8-arm radial maze. In these learning paradigms, substantial evidence has been compiled in support of learning being impaired by 2VO (Farkas and Luiten, 2001). An increasing number of studies have demonstrated that 2VO rats cover longer swim paths or display longer escape latencies in the Morris water maze (Farkas and Luiten, 2001; Farkas et al., 2004b; Liu et al., 2005; Shang et al., 2005) and commit more errors than the sham-operated controls in the 8-arm radial maze (Farkas and Luiten, 2001; Murakami et al., 2000; Sopala and Danysz, 2001). Thus, it has been firmly established that experimental cerebral hypoperfusion compromises spatial learning in rats. In

addition to these behavioral models, measurements were recently made of the locomotor activity in an open field, anxiety-related avoidance retention in an elevated T-maze, and non-spatial memory in an object recognition test. The total distance covered by the 2VO animals in the open field did not differ from that for the controls, indicating that the locomotor activity remained intact (de Bortoli et al., 2005). However, the 2VO rats proved to be significantly impaired as compared with the controls in an anxiety-related task, the elevated T-maze (de Bortoli et al., 2005): as reflected by the shorter latency of leaving the closed arm, the 2VO rats were either less anxious to enter the open arms of the T-maze or remembered less well that entering the open arms was associated with anxiety. The latter explanation seems to be the more accurate since the 2VO rats did not appear less anxious as compared with their respective sham controls in the elevated plus maze (de Wilde et al., 2002). Finally, the non-spatial memory in an object recognition test evaluated with a discrimination index was also impaired in 2VO rats 60 and 90 days following occlusion of the vessels (Sarti et al., 2002a). These data suggest that not only the visuospatial learning, but also fear conditioning and non-spatial memory are impaired by 2VO.

In view of the finding that the cerebral perfusion rate changes over time in the 2VO model, it is of interest to establish whether the learning impairment develops exclusively due to the sudden drop in blood flow in the acute phase or worsens in the chronic phase of 2VO. Hence, the learning performance has been compared at several time points in the 2VO model. Tests on rats in the 8-arm radial maze 1 week after 2VO induction revealed no difference in working and reference memory scores between the 2VO and control animals, but 16 months later the 2VO animals committed significantly more errors (Sopala and Danysz, 2001). In the Morris water maze, similar tendencies have been observed. The 2VO rats performed significantly worse than the controls 4 weeks after the onset of 2VO, and the learning impairment was considerably augmented as time passed. The escape latency at 20 weeks was significantly longer than that at 4 weeks after 2VO initiation, which was reflected in the time spent in the platform quadrant in the retention trial (Liu et al., 2005). In a non-spatial learning paradigm, the object recognition test, 2VO rats performed as well as the controls after 30 days of 2VO, but a delayed learning impairment had developed by 60 days, which was further enhanced after 90 days (Sarti et al., 2002a). These results convincingly support the concept that the chronic phase of 2VO plays a major role in the gradual deterioration of the learning ability, though damage occurring in the acute phase of CBF reduction cannot be categorically excluded.

A final point to consider here is whether the learning ability can return to the normal level on the cessation of cerebral hypoperfusion. In order to resolve this question, learning tests with 2VO rats must be performed after the CBF has returned to the baseline, i.e. more than 6 months after the 2VO surgery. In this respect, results obtained with both the Morris water maze and the radial arm maze paradigms ~6 months and 1 year after 2VO induction demonstrated that the spatial learning was impaired even at these late time points (De Jong et al., 1999; Pappas et al., 1996). These observations suggest that the

2VO-induced, permanent neuronal damage (see below) rather than the cerebral hypoperfusion itself is correlated with the memory failure.

---

## 6. Neuropathologic changes induced by chronic cerebral hypoperfusion in the brain

### 6.1. Neuronal damage

For several reasons, the favored brain region for the study of 2VO-induced neurodegeneration is the hippocampus. First of all, the hippocampus is the area that displays the most characteristic neuropathological damage in AD. Second, the hippocampus is highly implicated in spatial learning and memory as assessed by the Morris water maze and the 8-arm radial maze. For this reason, neuronal injury in the hippocampus and impaired spatial learning can be related. Third, the hippocampus (and particularly its CA1 subfield) is one of the brain regions most sensitive to ischemia. Finally, the distinct laminar structure of the hippocampus and its precisely mapped synaptic connections allow exact cell-type (e.g. pyramidal cells) or layer-specific measurements.

The most obvious signs of neurodegeneration are the loss of neuronal cell bodies and synaptic contacts. Cerebral hypoperfusion-induced neuronal cell death can be visualized with conventional dyes such as hematoxylin–eosin, cresyl violet, or toluidine blue, or with more sophisticated techniques such as the TUNEL labeling of apoptotic neurons (Table 2). The conventional staining procedures revealed no conspicuous loss of neurons during the first week after 2VO induction (Ohtaki et al., 2006). Later, however, increasing neuronal damage was noted. At 2 weeks, 6–29% of the animals exhibited hippocampal injury in the CA1 subfield (Farkas et al., 2006b; Ohtaki et al., 2006; Schmidt-Kastner et al., 2001). At 4 weeks, this had increased to 55% (Ohtaki et al., 2006), while at 8–13 weeks, total hippocampal destruction was observed in 67% of the 2VO rats (Farkas et al., 2004b; Liu et al., 2006). TUNEL-labeled apoptotic cell death was detected particularly in the CA1 and CA3 regions at 2 weeks after the onset of 2VO, with an increased rate 25 weeks later (Bennett et al., 1998). Thus, both technical approaches demonstrated that the neurodegeneration in the hippocampus gradually progressed with time.

The predominant type of neuronal cell death (apoptosis vs. necrosis) in chronic cerebral hypoperfusion has so far remained an unresolved issue. In ischemic brain injury, both modes of cell death occur, represented in a spatial and temporal distribution determined by the severity of the ischemia (Harukuni and Bhardwaj, 2006). The key determinant for the mode of neuronal death is the intracellular concentration of ATP. As a basic approach, apoptosis takes place in the presence of ATP, while necrosis is typically characterized by lack of the energy substrate (Ueda and Fujita, 2004). As mentioned above, in the initial phase of 2VO, ATP is rapidly depleted, but the ATP level returns to the control by 8 weeks after the onset of 2VO (Briede and Duburs, in press; Plaschke, 2005). These data suggest that necrotic cell death most probably predominates in the acute phase of



**Table 2 – Neuronal damage in the hippocampus in chronic cerebral hypoperfusion: a selection of recent data**

Survival time	Rat strain	Anesthesia	Marker	Neuronal damage	Reference
0, 1, 2, and 4 weeks	Slc Wistar (13–15 weeks)	50 mg/kg sodium pentobarbital	H&E	CA1 neuronal cell death: no damage before week 1, in 2 of 7 rats at week 1 (29%), in 6 of 11 rats at week 2–4 (55%)	Ohtaki et al. (2006)
2, 4, and 8 weeks	Wistar (250–300 g)	3% halothane	H&E	Neuronal damage: in 1 of 15 rats (7%)	Schmidt-Kastner et al. (2001)
1, 3, 6, and 24 h; 7 and 14 days			In situ hybridization: BDNF mRNA	Increase in DG at 6 h	
2, 4, 7, and 14 days, 16 weeks	Wistar (14 weeks)	30 mg/kg sodium pentobarbital	AD-related factors: APP, Sec, $\alpha$ 7NicR, and AchE mRNA	$\alpha$ 7NicR increase on day 4; AchE decrease at week 16; APP increase on days 4 and 7; Sec increase on day 4	Tohda et al. (2004)
4 days	Wistar (14 weeks)	30 mg/kg sodium pentobarbital	AD-related factors: APP, Sec, $\alpha$ 7NicR, Nep and IDE mRNA	Increase in all measured mRNA	Hayashi et al. (2005)
1 week, 2 and 6 months	Wistar (250–350 g)	3% halothane	NeuN	No focal damage, irregular labeling in CA1 in 1 rat at 6 months	Schmidt-Kastner et al. (2005)
2 weeks	Wistar (300–320 g)	400 mg/kg chloral hydrate	Cresyl violet	Moderate (6%) pyramidal cell loss in CA1	Farkas et al. (2006b)
2 and 27 weeks	Sprague–Dawley (9–10 months)	100 mg/kg ketamine + 50 mg/kg sodium methohexital	H&E	Necrotic pyramidal cells at week 2	Bennett et al. (1998)
14 and 190 days	Sprague–Dawley (9–10 months)	100 mg/kg ketamine + 40 mg/kg sodium methohexital	TUNEL Cresyl violet Palmgren silver impregnation	Increased on weeks 2 and 27 CA1 pyramidal cell loss at 190 days	Pappas et al. (1996)
4, 10, and 20 weeks	Wistar (300–350 g)	350 mg/kg chloral hydrate	Real-time RT-PCR and Western blot: GAP-43, MAP-2, synaptophysin	GAP-43: increase of mRNA, no change in protein; MAP-2: both mRNA and protein decrease at weeks 10 and 20; synaptophysin: no change in mRNA, decrease in protein	Liu et al. (2005)
1 and 4 months	Wistar (6–9 months old)	40 mg/kg sodium pentobarbital	Cresyl violet	CA1 pyramidal cell loss at 4 months	Ni et al. (1995)
34 days	Sprague–Dawley (female, 220–250 g)	350 mg/kg chloral hydrate	Thionine	Neuron loss in CA1	Shang et al. (2005)
8 weeks	Wistar (320–360 g)	350 mg/kg chloral hydrate	Toluidine blue Macroscopic examination	26% loss of CA1 pyramidal cells Total hippocampal lesion in 4 of 6 rats	Liu et al. (2006)
90 days	Wistar (270–290 g)	1–2% halothane	H&E	No damage	Sarti et al. (2002a,b)
13 weeks	Wistar (200–220 g)	400 mg/kg chloral hydrate	COX-2 Macroscopic examination	Reduced number of COX-2 positive granule cells in DG iml Total unilateral hippocampal lesion in 4 of 6 rats	Farkas et al. (2004b)

Abbreviations:  $\alpha$ 7NicR:  $\alpha$ 7-nicotinic acetylcholine receptor, AD: Alzheimer's disease, BDNF: brain-derived neurotrophic factor, COX-2: cyclooxygenase-2, APP: amyloid precursor protein, DG iml: dentate gyrus inner molecular layer, GAP-43: growth-associated protein-43, H&E: hematoxylin–eosin, IDE: insulin-degrading enzyme, MAP-2: microtubule-associated protein-2, Nep: neprilysin, Sec:  $\gamma$ -secretase.

2VO, as also evidenced by the CA1 pyramidal cell morphology in hematoxylin–eosin or cresyl violet-stained sections, while the delayed neuronal death could be apoptotic (Bennett et al., 1998).

The presented results lead to the question of whether the neuronal damage observed at long survival times after 2VO initiation is induced by the initial, ischemic phase of cerebral hypoperfusion, or whether it is the outcome of a long-lasting neurodegeneration caused by the chronic, oligemic phase of 2VO. In view of the limitations of the 2VO model in this respect, this issue is difficult to resolve, but it is probable that both the early ischemic and the later oligemic compo-

nents contribute to the hippocampal neuron loss and result in a continuous spectrum of necrotic and apoptotic cell death.

Chronic cerebral hypoperfusion also affects the dendritic arborizations and synaptic contacts. Microtubule-associated protein-2 (MAP-2) is a cytoskeletal phosphoprotein associated with dendritic microtubules that is thought to reflect dendritic branching, remodeling, and plasticity (Friedrich and Aszodi, 1991) and has been regarded as a highly sensitive marker of ischemic brain damage (Dawson and Hallenbeck, 1996). Both the mRNA and the protein concentration of MAP-2 fell from 4 weeks to 20 weeks after the induction of 2VO, indicating a

progressive loss of dendrites. More interestingly, the diminishing MAP-2 signals correlated strongly with the declining Morris water maze performance of the rats in the retention trial (Liu et al., 2005). Synaptophysin protein, which labels synaptic vesicles (Thiel, 1993), demonstrated a similar reduction caused by 2VO and an association with the spatial memory (Liu et al., 2005). These data indicate that cerebral hypoperfusion disturbs the wiring of the neuronal circuits and the communication between the neurons, which contributes to the learning deficiency.

## 6.2. Astrocytic reactions

Cerebral ischemia triggers reactive astrocytosis with detectable morphological signs such as hypertrophy and proliferation (Panickar and Norenberg, 2005). The marker widely used to label astrocytic proliferation is the intermediate filament glial fibrillary acidic protein (GFAP), which accumulates in reactive astrocytes. A number of studies have been made of the presence and time course of reactive astrocytosis in chronic cerebral hypoperfusion with the help of GFAP immunocytochemistry. Even though astrocytic proliferation was already detected in the cortex and visual pathways after 1 week of 2VO, an increased GFAP signal was not discerned in the hippocampus until 6 months later (Farkas et al., 2004a,b, 2006b; Pappas et al., 1996; Schmidt-Kastner et al., 2005). Astrogliosis is therefore considered to be a late-emerging event in the hippocampus in chronic cerebral hypoperfusion.

## 6.3. Microglial activation

Ischemic insults impose rapid microglial activation, which participates in the defense of the nervous tissue, although microglia may also transform into cytotoxic cells (Eisel et al., 2006; Kreutzberg, 1996). The two techniques most widely used to visualize microglia are OX-42 immunocytochemistry and lectin histochemistry (Streit and Kreutzberg, 1987; Suzuki et al., 1988). The antibody OX-42 is known to label CR3 complement receptors (CD11b) present on amoeboid or activated microglia (Leong and Ling, 1992), while both resting and activated microglia seem to possess a selective affinity for plant-derived lectins, which provides a histological tool with which to identify these cells (Streit and Kreutzberg, 1987).

Microglial activation has been examined at various time points between 10 min and 6 months after the onset of 2VO. The results obtained with OX-42 immunocytochemistry displayed a similar pattern: the microglial activation was already elevated in the hippocampus at 20 min and was still obvious 13 weeks after the onset of 2VO (Abraham and Lazar, 2000; Farkas et al., 2004b). In contrast, the lectin histochemistry technique revealed an enhanced activation of the microglia only in the optic tract (Schmidt-Kastner et al., 2005). Besides the increased presence of microglia in 2VO brains, we have observed that overt microglial activation in the hippocampal CA1 subfield clearly coincides with pyramidal cell death in some animals (~15–20%) after survival for 2 weeks (Figs. 2A–F). We assume that the animals with this accentuated histopathology correspond with those with total hippocampal

destruction at 13 weeks after 2VO surgery (Figs. 2G, H) (Farkas et al., 2004b).

## 6.4. Potential mechanisms for neurodegeneration

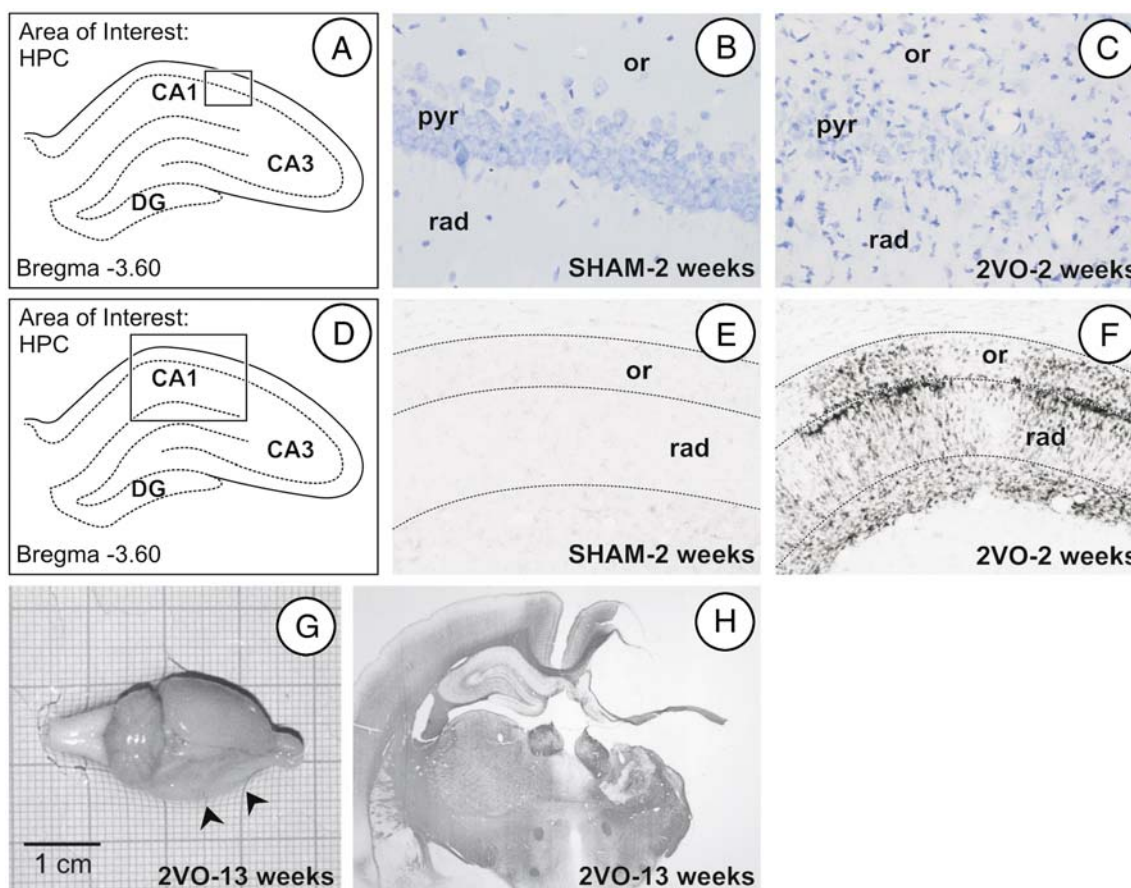
The chain of events that eventually lead to neuronal cell death in chronic cerebral hypoperfusion begins with neuronal energy failure due to the blood flow reduction and the consequent hypoxia and hypoglycemia. The energy failure in cerebral ischemia is reflected most evidently in the rapid depletion of ATP, also found in 2VO rats (Briede and Duburs, *in press*; Plaschke, 2005). In ischemic brain injury or stroke, the loss of ATP is promptly followed by the dysfunction of energy-dependent ion pumps, depolarization of the neurons, and the generation of reactive oxygen species (ROS) lethal to neurons at high concentration. The ROS in turn initiate lipid peroxidation, generating lipid peroxides that are degraded to reactive aldehyde products such as malondialdehyde (MDA) (Muralikrishna Adibhatla and Hatcher, 2006). In parallel with the increase in lipid peroxidation, the activities of enzymatic antioxidants such as Cu/Zn-superoxide dismutase (Cu/Zn-SOD) or the concentrations of non-enzymatic antioxidants such as glutathione (GSH) decrease (Nita et al., 2001). However, enhanced lipid peroxidation and a decreased capacity of the antioxidant systems have primarily been associated with reperfusion after ischemia (Nita et al., 2001), which is very gradual in permanent 2VO due to the flow compensation, if reperfusion in the classical sense (the sudden return of flow) occurs in 2VO at all. The concentration of MDA, indicative of lipid peroxidation, was considerably increased after 10 days of 2VO, and the activity of Cu/Zn-SOD and the concentration of GSH were significantly decreased, as is typical of ischemic brain injury (Aytac et al., 2006). These preliminary data require confirmation, but it is currently considered that 2VO creates a permanent ischemic/oligemic condition serious enough to sustain continuous oxidative stress (probably in both the acute and chronic phases), which could very well be the reason for the persistent and progressive neuronal damage.

---

## 7. Chronic cerebral hypoperfusion-related white matter injury

Cerebral WM lesions that accompany human aging and dementia have received increasing attention as WM injury visualized with clinical imaging techniques has been found to coincide with cognitive and psychiatric disorders in the elderly and AD patients (Barber et al., 1999; de Groot et al., 2000; de Leeuw et al., 2001). Cerebral ischemia has been hypothesized as the most probable cause of WM lesions, but direct confirmation of the assumption requires experimental models. The 2VO model has emerged as a suitable approach, with which to unravel the potential causal relationship between cerebrovascular insufficiency and WM lesions.

In consequence of the anatomical arrangement of the WM in the rat brain, the corpus callosum, the internal capsule, and the optic tract serve as the most common and easily delineated regions of interest for WM research. The



**Fig. 2** – The neurodegenerative changes caused in the hippocampus by bilateral occlusion of the common carotid arteries in the rat. (A–C) Cresyl violet staining to visualize the hippocampal CA1 pyramidal neurons 12 weeks after the onset of 2VO. The photographs were taken at 40 $\times$  magnification. (D–F) OX-42 immunocytochemistry to visualize microglial activation in the hippocampus CA1 stratum oriens and stratum radiatum 12 weeks after 2VO. The photographs were taken at 10 $\times$  magnification. (G and H) Macroscopic lesions of the hippocampus and cerebral cortex 13 weeks after the onset of 2VO. The photograph in panel H was taken at 4 $\times$  magnification. Abbreviations: 2VO: permanent, bilateral common carotid artery occlusion; DG: dentate gyrus; HPC: hippocampus; or: stratum oriens; pyr: stratum pyramidale; rad: stratum radiatum; SHAM: sham-operated control.

blood supply to these WM sites arrives through different routes; the severity of 2VO-induced ischemia therefore varies from area to area (Farkas et al., 2004a, 2005). Several studies have identified the optic tract as a predominantly vulnerable WM region in the rat brain because of its dependence on the direct blood supply from the internal carotid artery (Farkas et al., 2004a; Ohta et al., 1997; Takizawa et al., 2003; Wakita et al., 2002). The corpus callosum also exhibits typical, ischemia-related histopathologic changes as a consequence of 2VO, while the internal capsule seems to be better preserved (Farkas et al., 2004a; Takizawa et al., 2003; Wakita et al., 2002).

At various time points after the onset of 2VO, diverse manifestations of WM injury have been described (Table 3). The rarefaction and vacuolization of the WM in Klüver-Barrera-stained sections are the most consistent type of damage (Cho et al., 2006; Lee et al., 2006; Ohta et al., 1997; Otori et al., 2003; Wakita et al., 2002). Moreover, the myelin sheaths were disintegrated, astrocytes proliferated and degenerated, and the microglial cells were activated (Cho et

al., 2006; Farkas et al., 2004a; Lee et al., 2006). Furthermore, apoptotic markers such as TUNEL and caspase-3 indicated the apoptosis of oligodendrocytes and astrocytes (Lee et al., 2006; Tomimoto et al., 2003). Finally, the accumulation of amyloid precursor protein and chromogranin A in tortuous axons reflected disturbed or blocked axonal transport (Wakita et al., 2002).

The histopathological injuries observed in the 2VO model appear to be very similar to those identified in post mortem human WM lesions, such as WM rarefaction, demyelination, gliosis, regressive astrocytic changes, and the apoptotic cell death of oligodendrocytes and astrocytes (Kobayashi et al., 2002; Scheltens et al., 1995; Thomas et al., 2002; Tomimoto et al., 1997). Thus, the experimental evidence has confirmed the ischemic origin of WM lesions. Accordingly, 2VO in rats is regarded as an appropriate model for the reconstruction of histopathologic changes in human ischemic WM lesions. Recent studies have demonstrated that the 2VO model can be used for the development and testing of neuroprotective strategies with therapeutic prospects for WM injury (Cho et al.,

**Table 3 – Histopathology in the cerebral white matter in chronic cerebral hypoperfusion: a selection of recent data**

Survival time	Staining	WM site	Histopathology	Reference
1 h, 1, 3, 7, 14, and 30 days	Klüver–Barrera Bielschowsky silver APP: fast axonal transport CgA: anterograde axonal flow EP: degradation of myelin	Optic tract, internal capsule, corpus callosum, fiber bundle of the caudate putamen	WM rarefaction: from day 3 on Swollen fibers Increased signal, peak between days 7–14 Gradually increasing signal from day 1 to day 30	Wakita et al. (2002)
1 h, 1, 3, 7, 14, 30, and 90 days	Apoptosis markers: Caspase-1 Caspase-3 Fas FasL Bax TUNEL TNF $\alpha$ : proinflammatory cytokine	Corpus callosum	Protein increase between day 1 and 30 mRNA and protein increase between day 1 and 30 Immunonegative Increased in oligodendrocytes Increased signal on days 7–14 Immunolabeled after 2VO	Tomimoto et al. (2003)
2 days, 1, 4, and 8 weeks	Klüver–Barrera	Corpus callosum, internal capsule	WM rarefaction, vacuolization	Otori et al. (2003)
3, 7, 14, and 30 days	Klüver–Barrera TUNEL: apoptosis Caspase-3: apoptosis GFAP: astrogliosis OX-42 (CD11b): microglial activation CNPase: oligodendrocytes TNF $\alpha$ : proinflammatory cytokine	Optic tract	WM lesions Increase Increase Increase Increase Decrease Increase	Lee et al. (2006)
2 weeks	Klüver–Barrera Bielschowsky silver APP: fast axonal transport	Optic tract, internal capsule, corpus callosum	WM lesions Increase	Wakita et al. (2003)
2 weeks	Klüver–Barrera Bielschowsky silver MBP: myelin integrity MMP-2: myelin degradation OX-42 (CD11b): microglial activation	Optic tract, internal capsule, corpus callosum	Vacuolization Axonal damage Decrease Increase Increase	Cho et al. (2006)
8 weeks	Hematoxylin–eosin	Optic tract, corpus callosum, cingulum bundle, caudoputamen	Increase in % of vacuoles	Takizawa et al. (2003)
13 weeks	GFAP: astrogliosis OX-42: microglial activation MBP: myelin integrity Electron microscopy	Optic tract, internal capsule, corpus callosum Optic tract	Increase Increase Increase myelin sheath damage, increased oligodendrocyte density	Farkas et al. (2004a, 2005)
4 months	Klüver–Barrera	Optic tract	WM rarefaction, vacuolization, gliosis	Ohta et al. (1997)

Abbreviations: APP: amyloid precursor protein, CgA: chromogranin A, EP: encephalitogenic peptide GFAP: glial fibrillary acidic protein, MBP: myelin basic protein, MMP-2: matrix metalloproteinase-2.  
WM: white matter.

2006; Farkas et al., 2005; Takizawa et al., 2003; Wakita et al., 2003).

## 8. The effects of chronic cerebral hypoperfusion on the visual system

The 2VO model in rats has also been applied for ischemic eye research. In investigations of the ischemic component of diabetic retinopathy, chronic glaucoma, or ocular ischemic syndrome, a number of 2VO-induced functional and morphological pathologies of the optic system have been identified (Lavinsky et al., 2006; Yamamoto et al., 2006). Approximately 50% of 2VO animals lose their pupillary reflex (Davidson et al., 2000; Lavinsky et al., 2006; Stevens et al.,

2002), which makes the retina exceedingly vulnerable to light exposure and is probably involved in the abnormal circadian rhythm of the animals (Ohta et al., 1997). Furthermore, the electroretinograms have demonstrated that the b-wave amplitude, representing on-bipolar and Müller cell activity in response to light, is dramatically decreased 7 days after the onset of 2VO (Barnett and Osborne, 1995). In contrast, the a-wave amplitude reflecting the photoreceptor function is significantly increased, indicating that the photoreceptor utility is maintained for up to 7 days (Barnett and Osborne, 1995).

These functional changes are accompanied by structural damage. Macroscopic examination and Gallyas staining of the optic nerves revealed considerable atrophy associated with loss of the pupillary reflex (Ohta et al., 1997; Stevens et al.,

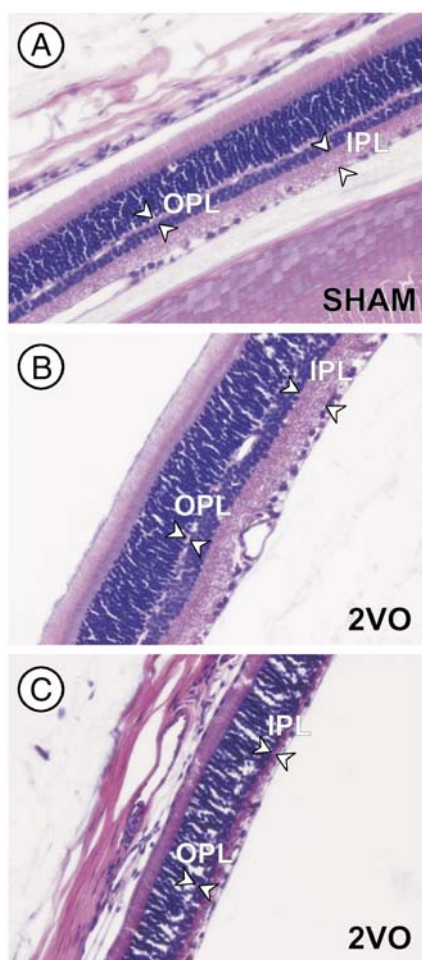
2002). The optic tract also suffers marked damage in the form of myelin disintegration, excessive astrogliosis, and microglial activation labeled with immunocytochemistry (Farkas et al., 2004a). The total retinal thickness of 2VO rats that lost their pupillary reflex fell from  $\sim 120 \mu\text{m}$  to  $\sim 87 \mu\text{m}$ , while 2VO rats with a preserved pupillary reflex displayed no reduction in total retinal thickness (Lavinsky et al., 2006). Particularly the synaptic zones, the inner and outer plexiform layers appeared to be markedly affected, as shown in representative photographs taken after 2 weeks of 2VO (Fig. 3). The loss of ganglionic cells that followed the integrity of the pupillary reflex could be observed from 1 week on and was most dramatic from 90 days on (Stevens et al., 2002; Yamamoto et al., 2006). Receptor cell loss was delayed as compared with the ganglionic cell pathology and was detected from 2 months on

(Yamamoto et al., 2006). Thus, about half of 2VO rats display an impaired visual ability.

These observations appear to be rather disturbing for researchers investigating cognitive dysfunctions caused by 2VO because spatial memory is frequently assessed in learning tests that are based on visual cues. The most popular memory tests in general use for 2VO rats are the Morris water maze and the 8-arm radial maze (Farkas and Luiten, 2001). In order to distinguish the contribution of visual impairment from the hippocampal neuronal damage to the spatial learning dysfunction, various approaches have been employed.

When 2VO rats were divided into groups based on the presence or absence of the pupillary reflex, both groups committed more errors in the 8-arm radial maze as compared with the sham-operated controls, but the rats with an impaired pupillary reflex performed noticeably worse than the group with an intact reflex (Davidson et al., 2000). In another study, the learning capacities of rats with bilateral internal carotid artery occlusion or with 2VO were compared. In the Morris maze, the internal carotid artery-occluded animals did not perform worse than the controls, whereas the 2VO animals did. In the 8-arm radial maze, the results resembled those obtained with the groups based on pupillary reflex integrity: both the internal carotid artery-occluded and the 2VO groups committed more errors than the controls, and the 2VO group gave the worst performance (Ohta et al., 1997).

These experiments suggest that cerebral hypoperfusion itself compromises the learning process, but damage to the visual system aggravates the test results that depend on visual cues. It is highly likely that hypoperfusion severe enough to damage the retina has a more dramatic impact on the hippocampus and the related memory processes. Auditory and tactile stimuli also guide rats in spatial learning; this is especially true for albino rats with limited vision. In support of this view, rats blind in one eye are able to navigate as well as binocular animals in the Morris water maze (Panakhova et al., 1986). The concerns as to the exact role of impaired vision in spatial learning in the 2VO model remain unresolved because of the lack of unequivocal evidence. However, it is certain that 2VO induces learning deficits because non-visual learning characterized in the elevated T-maze and in an object recognition test is clearly affected in the model (de Bortoli et al., 2005; Sarti et al., 2002a).



**Fig. 3** – The differential degeneration of the retina caused by bilateral occlusion of the common carotid arteries in the rat. Twelve weeks after the vessel ligations, the hematoxylin–eosin-stained retina sections of some rats appeared spared (B), while those of others were severely injured (C). There is a noteworthy narrowing of the synaptic zones (IPL and OPL) indicated by arrowheads. The photographs were taken at 40 $\times$  magnification. Abbreviations: 2VO: permanent, bilateral common carotid artery occlusion; IPL: inner plexiform layer; OPL: outer plexiform layer; SHAM: sham-operated control.

## 9. Systemic changes following experimental cerebral hypoperfusion

### 9.1. Body weight

Like larger surgical interventions in general, 2VO is followed by a decrease in body weight. On postoperative days 1 and 2, a loss in body weight can be observed in both the sham-operated and 2VO groups. Since certain muscles in the ventral cervical region (e.g. the sternohyoid and the sternomastoid muscles) are slightly damaged during the preparation of the carotid arteries, discomfort during movement of the head, mastication, and swallowing may

contribute to this initial weight loss. The sham-operated animals (which undergo all surgical procedures but the actual vessel ligation) start to regain weight rapidly, while the 2VO animals lag somewhat behind, even up to 10 weeks after the onset of 2VO (Farkas et al., 2002a). The slower gain in body weight following 2VO cannot be attributed to the surgical method since the control animals are exposed to the same procedures. A potential increase in sympathetic tone or hormonal changes due to the ligation may be considered responsible for the delayed weight gain. On the other hand, the blood flow to the hypothalamus, a major center of autonomic control, is also markedly reduced in the 2VO model (Otori et al., 2003; Tsuchiya et al., 1992), which may compromise the hypothalamic function. Unfortunately, experimental data on the relationship between chronic cerebral hypoperfusion, hypothalamic injury, and autonomic regulation are scarce.

### 9.2. Blood pressure

As a consequence of 2VO, the blood flow decreases dramatically in the carotid sinus, where baroreceptors continuously monitor the blood pressure. The sudden drop in blood pressure triggers a cardiovascular baroreflex, increases the sympathetic tone, and initiates a hypertensive response. Early reports described the hypertensive response after 2VO surgery, indicated by increases in blood pressure and heart rate (Krieger, 1963; Wang et al., 1970). With the help of a femoral artery canule, the mean arterial pressure in awake laboratory rats was demonstrated to increase by approximately 65 mmHg relative to the baseline in the acute phase of 2VO (15–60 s) (Parra et al., 2005). Our experiments followed the long-term changes in systolic blood pressure measured with the tail cuff method in unrestrained, awake rats from 24 h up to 9 weeks after the onset of permanent 2VO. Even as long as 9 weeks after vessel occlusion, the systolic blood pressure displayed a sustained, significant increase of 10–12 mmHg over the baseline (Fig. 4), even though the aortic baroreflex loop was intact. Similar results were obtained under halothane anesthesia for the mean arterial pressure (Otori et al., 2003).

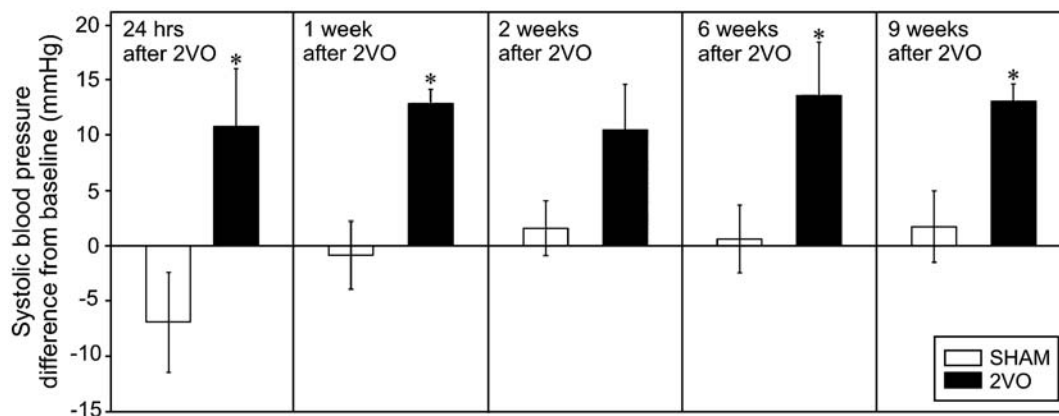
These results indicate a persistent elevation of the sympathetic tone in the permanent 2VO model.

### 9.3. Plasma hormone concentration

Experimental evidence on plasma hormone concentrations in animals with 2VO is scarce, although the increased sympathetic tone implies the involvement of hormonal regulation. An increased release of vasopressin as a direct response to 2VO has been repeatedly demonstrated (Clark and Silva, 1967; Dreifuss et al., 1976), but the chronic hormonal changes have not been investigated. Likewise, the plasma concentrations of catecholamines and angiotensin, assessed in dogs, proved to be elevated during the acute phase of 2VO (Brassard and Yamaguchi, 1989; Hodge et al., 1966), but less is known about the chronic hormonal fluctuations in permanent 2VO. Finally, even though acute changes in the plasma concentration of corticosterone have not been recorded, our experiments demonstrated that 2VO persisting for 3 months caused a significant increase in the circulating corticosterone level in a stressful situation (Farkas et al., 2002b). Besides their participation in the sympathetic response, these hormonal changes may be of metabolic significance and contribute to the slower gain in body weight in the 2VO animals.

### 9.4. Leukocyte stimulation

In a search for peripheral inflammatory markers, the formation of leukocyte–platelet aggregates and the activation of neutrophil granulocytes have been identified in blood drawn from the jugular vein after cerebral ischemia–reperfusion injury (Ritter et al., 2005). Similarly, the enhanced aggregation of leukocytes and neutrophil activation were observed in blood from the femoral and jugular veins of rats 5 h after the onset of 2VO, as compared with the sham-operated controls (Sancesario et al., 1997). Even though these changes have been primarily associated with reperfusion injury, the results from the 2VO experiment infer that cerebral hypoperfusion itself may generate a systemic inflammatory response.



**Fig. 4** – Change in systolic blood pressure after bilateral occlusion of the common carotid arteries in the rat. Systolic blood pressure was measured repeatedly on freely moving, awake rats with the tail cuff method. Abbreviations: 2VO: permanent, bilateral common carotid artery occlusion; SHAM: sham-operated control.

### 9.5. Diagnostic prospects

This survey has provided illustrative examples of systemic changes in response to 2VO. The conventional approach to the causal interaction between peripheral changes and cerebrovascular events examines the effects of peripheral risk factors on cerebrovascular pathology. However, as the experimental evidence presented here compellingly demonstrates, cerebrovascular injury can evoke a complex set of systemic reactions. The importance of these observations may be appreciated when routinely applicable diagnostic tools are designed for the prediction and follow-up of chronic cerebrovascular insufficiencies.

## 10. Methodological considerations

### 10.1. Species and strains

It is widely known that 2VO induces neuronal damage with varying degrees of severity in different mammal species. Two species frequently employed for carotid occlusion studies are the rat and the gerbil. These two models create distinct ischemic conditions in the brain. Because of the lack of communicating arteries between the carotid and vertebral systems, carotid occlusion in the gerbil leads to severe forebrain ischemia. In contrast, the complete circle of Willis in the rat affords compensatory flow from the vertebral arteries to the regions that would normally be supplied by the ligated carotid arteries; the 2VO in the rat therefore causes cerebral hypoperfusion rather than stroke.

Besides the clear-cut differences between species, a number of studies have also drawn attention to variations between strains. Thus mouse strains with an enhanced susceptibility to global cerebral ischemia (e.g. C57black/6) displayed less well developed posterior anastomoses or an incomplete posterior communication in the circle of Willis (Beckmann, 2000; Fujii et al., 1997). Similar observations on anatomical variations of the circle of Willis were published about gerbils obtained from different vendors (Breuer and Mayevsky, 1992; Laidley et al., 2005). Among rat strains, the CA1 hippocampal subfield of Fischer 344 rats appeared to be more vulnerable to 2VO combined with hypotension than those of Sprague–Dawley and Wistar rats (Iwasaki et al., 1995). Even a particular rat strain from different suppliers may be the source of differences in ischemic tolerance. The amplitude of population spikes in the hippocampal CA1 region evoked by electrical stimulation of the contralateral CA3 subfield decreased more dramatically after the onset of 2VO in Wistar rats supplied by Harlan as compared with Wistar rats from the Charles-River Laboratories (Marosi et al., 2006).

All these data suggest that, depending on the cerebrovascular condition to be reproduced experimentally, the most suitable strain must be chosen for the purpose. For example, Wistar rats appear to be ideal for the study of chronic cerebral hypoperfusion by imposing 2VO because the blood flow through the collaterals and the ischemic tolerance of the nervous tissue are relatively good. Furthermore, data analysis and comparison with results published by others must take any strain differences into account.

### 10.2. Anesthetics

The method of anesthesia applied must be considered because various anesthetics may exert different effects on the autonomic responses and cerebral metabolic rate in the 2VO model. In this respect, the effects of different anesthetics on physiological measures such as the mean arterial pressure and heart rate have been evaluated in 2VO rats. Under sodium thiopental, sodium pentobarbital, or alpha-chloralose anesthesia, 2VO elicited a systemic arterial pressor response comparable to that in conscious animals, while ketamine hydrochloride plus acepromazine was not as reliable. The stability of the baseline values for heart rate and arterial pressure indicated that sodium thiopental and sodium pentobarbital were the most suitable anesthetics for the measurement of systemic responses to 2VO (Lash et al., 1992).

Since certain anesthetics (e.g. halothane, ketamine, or isoflurane) are thought to furnish neuroprotection in ischemia by reducing the cerebral metabolic rate, some research groups have set out to characterize and compare the neuroprotective capacities of these agents. When 2VO was combined with hypotension, which also resulted in isoelectric EEG, measurement of the histological damage in the hippocampus pointed to isoflurane as the most neuroprotective anesthetic (Miura et al., 1998; Nellgard et al., 2000). However, when the EEG activity was maintained in the same model, no significant difference in neuroprotection could be established between isoflurane, ketamine, and fentanyl (Miura et al., 1998). 2VO has been demonstrated to lead to isoelectric EEG 300–400 s after occlusion of the vessels in a small proportion of rats (Briede and Duburs, in press), and isoflurane anesthesia may therefore blunt the 2VO-induced neurodegenerative processes. Furthermore, isoflurane has been shown to attenuate ischemia-induced glutamate release in the hippocampus (Patel et al., 1995). Whether the accentuated neuroprotective capacity of isoflurane as compared with other anesthetics is an advantage or a disadvantage in the 2VO model is a difficult question to resolve, but the choice of anesthesia remains a factor that may account for variations between studies involving the use of different agents.

### 10.3. Other technical approaches

The widespread use of 2VO indicates that this has proved to be a suitable method with which to reconstruct the cerebral hypoperfusion-induced components of human dementia. Nonetheless, because of the flow characteristics in 2VO rats, some modification of the model may be justified in the future.

A few attempts have recently been made to refine the 2VO model in order to avoid the acute phase directly after the occlusion. These studies focus on exploring technical solutions so as to be able to examine the neural consequences of gradually developing chronic cerebral hypoperfusion, or of atherosclerosis in the carotid bifurcation, as occurs in human aging and dementia. To this end, silicone collar cuffs were positioned around the common carotid arteries with the aim of reproducing the inflammatory response caused by atherosclerosis. This resourceful manipulation, however, did not cause long-term memory impairment (de Bortoli et al., 2005).

Another study suggested occlusion of the two common carotid arteries separately, at an interval of 1 week, which would allow hypoperfusion in the brain to develop more gradually (Sarti et al., 2002b). A late-emerging, progressive learning dysfunction has been induced with this approach in an object recognition test and the Y-maze (Sarti et al., 2002a). However, the method also involves a sudden drop in blood supply, even though this is unilateral, and probably shorter than in 2VO. An additional complicating factor is that the rats have to undergo anesthesia twice in a week, which causes further distress to the animals.

A further possibility is balloon angioplasty. This intervention involves the insertion of an inflatable balloon to the carotid bifurcation via the external carotid artery. Once in position, the balloon is inflated and withdrawn some millimeters a few times to trigger endothelial damage. The balloon is then removed, and the external carotid artery is closed. This method causes intimal hyperplasia and arterial stenosis (Clowes et al., 1983) and is a commonly used model for clinical arterial reconstruction surgery (Zubilewicz et al., 2001). The cerebral hemodynamic, behavioral, and neuropathological consequences of balloon angioplasty in the rat are not known. Since the narrowing of the carotid arteries develops gradually in this model, a possible change in CBF and the development of neurodegenerative processes may be worth investigating.

#### 10.4. Standardization

As shown in Figs. 2 and 3, the degree of neuronal and retinal damage varies greatly, even within the same experiment, where the variables (including the strain, the anesthetic, and the investigator performing the surgical interventions) are kept at a minimum. The source of this heterogeneity is probably the cerebrovascular architecture or the ischemic tolerance of the nervous tissue of the individual animals, as is the case with humans. As an additional factor, the age of the animals at the time of 2VO surgery may also be responsible for the heterogeneity. The proportion of rats with severe brain damage after the onset of 2VO appears to be higher when the animals are young at the time of the surgery (body weight <250 g, personal observation).

Standardization of the experiments is a reasonable requirement as concerns reproducibility and interpretation. Since the 2VO model has been generally used for the investigation of chronic cerebral hypoperfusion, such standardization should be aimed at the selection of rats that do not suffer severe ischemic brain damage.

Laboratories that use the 2VO model should agree on the selection criteria, though a number of variables complicate the development of such standards. For example, the heterogeneity of the survival times and the particular techniques used to collect data (e.g. flowmetry, electrophysiology, behavioral physiology, and histology) require different definitions for their standards. The observation and neurological evaluation of the motor dysfunction after 2VO surgery could be a rough approach, but 2VO animals do not display clear motor deficits like those observed in stroke models (Sarti et al., 2002a). As a consensus, brain slices containing the dorsal hippocampus could be stained with traditional dyes such as cresyl violet or

hematoxylin–eosin, and the damage to the CA1 pyramidal cells (one of the most vulnerable areas that is easy to define) could be graded for given survival times. Such a grading system could serve as a selection criterion via which to separate animals with severe ischemic brain damage from those with mild, cerebral hypoperfusion-related injury.

---

## 11. Summary and conclusions

The cerebral hemodynamic, metabolic, functional, and neuropathological data necessitated a survey of the achievements with the 2VO model. The nature and gravity of the insult inflicted by 2VO, and the severity of the consequent neuronal damage demand a review because they have not been comprehensively and conclusively determined. Most investigators agree that the level of cerebral hypoperfusion in the model is moderate, and the resulting neuronal injury is relatively mild. However, the terms ischemia and oligemia are used inconsistently in the literature to describe the condition produced. The terminology for ischemic thresholds in ischemic penumbra research may serve as a guideline for the proper identification of the 2VO-induced conditions. In this terminology, oligemia means a range of cerebral hypoperfusion where the electrical function of the nervous tissue is not yet affected. Ischemia denotes a condition where the flow values are low enough to cause electrical failure and a massive K<sup>+</sup> efflux into the extracellular space (Obrenovitch, 1995).

In the 2VO model, ischemia is followed by oligemia corresponding with the acute and chronic phases as shown in Fig. 1, but spatial variations are also present, depending on the angioarchitecture and the vulnerability of specific brain regions. For example, the optic tract may undergo ischemia, while at the same time the hippocampus could be in the oligemic phase, as reflected by the CBF values and the histologic damage (Tables 1–3). The terms ischemia and oligemia in the 2VO model should therefore be used with care and selectively, with consideration to the time after occlusion of the vessels, and the brain region investigated.

As regards the issue of acute and chronic neurodegeneration in the 2VO model, some researchers have expressed concern that the neuronal damage could primarily occur in the acute phase as opposed to the chronic phase of 2VO. The current survey has demonstrated that the neuropathology, together with the learning dysfunction, is progressive and is not caused exclusively in the acute phase.

Impairment of the visual system after 2VO induction led to further doubts as to the outcome and interpretation of spatial orientation tasks based on visual cues. As detailed above, no explicit solution has been found to distinguish the share of visual impairment in the poor performance of 2VO rats in the Morris maze and the 8-arm radial maze. However, other non-visual learning paradigms (e.g. the elevated T-maze and the object recognition test) recently introduced in 2VO studies clearly demonstrate that the memory processes are progressively disturbed in the model.

Most published 2VO studies have been descriptive, and only a few groups of researchers have set out to unravel the exact intracellular and biochemical mechanisms that lead to



2VO-related neuronal injury. The explanation for the lack of experimental data may be that unsuccessful attempts have not been published, or the demand for such information has not been high, but the role of oxidative stress in 2VO-induced neurodegeneration could be an attractive target of investigation that could be extrapolated to human cerebral hypoperfusion.

Overall, the 2VO rat model has prompted an understanding of the causative role played by cerebral hypoperfusion in neurodegenerative diseases. Future 2VO studies could well unravel the hypoperfusion-related biochemical mechanisms involved in neuronal damage. As a final point, the 2VO model has now been extensively characterized, and it seems highly suitable for the testing of potentially neuroprotective drugs.

## Acknowledgments

This work was supported by the Hungarian Scientific Research Fund (OTKA) grants F042803 (E.F.) and K63401 (F.B.), the Hungarian National Office for Research and Technology (NKTH), a Visiting Scholar grant from the Royal Netherlands Academy of Arts and Sciences to E.F., and a Bolyai János Research Scholarship of the Hungarian Academy of Sciences to E.F.

## REFERENCES

- Abraham, H., Lazar, G., 2000. Early microglial reaction following mild forebrain ischemia by common carotid artery occlusion in rats. *Brain Res.* 862, 63–73.
- Aytac, E., Oktay Seymen, H., Uzun, H., Dikmen, G., Altug, T., 2006. Effects of iloprost on visual evoked potentials and brain tissue oxidative stress after bilateral common carotid artery occlusion. *Prostaglandins Leukot. Essent. Fat. Acids* 74, 373–378.
- Barber, R., Scheltens, P., Gholkar, A., Ballard, C., McKeith, I., Ince, P., Perry, R., O'Brien, J., 1999. White matter lesions on magnetic resonance imaging in dementia with Lewy bodies, Alzheimer's disease, vascular dementia, and normal aging. *J. Neurol. Neurosurg. Psychiatry* 67, 66–72.
- Barnett, N.L., Osborne, N.N., 1995. Prolonged bilateral carotid artery occlusion induces electrophysiological and immunohistochemical changes to the rat retina without causing histological damage. *Exp. Eye Res.* 61, 83–90.
- Beckmann, N., 2000. High resolution magnetic resonance angiography non-invasively reveals mouse strain differences in the cerebrovascular anatomy in vivo. *Magn. Reson. Med.* 44, 252–258.
- Bennett, S.A., Tenniswood, M., Chen, J.H., Davidson, C.M., Keyes, M.T., Fortin, T., Pappas, A., 1998. Chronic cerebral hypoperfusion elicits neuronal apoptosis and behavioral impairment. *NeuroReport* 9, 161–166.
- Borroni, B., Anchisi, D., Paghera, B., Vicini, B., Kerrouche, N., Garibotto, V., Terzi, A., Vignolo, L.A., Di Luca, M., Giubbini, R., Padovani, A., Perani, D., 2006. Combined 99mTc-ECD SPECT and neuropsychological studies in MCI for the assessment of conversion to AD. *Neurobiol. Aging* 27, 24–31.
- Brassard, M., Yamaguchi, N., 1989. Evidence that increases in circulating catecholamines of adrenal origin are not involved in pressor response to bilateral carotid occlusion in anaesthetized dogs. *Clin. Exp. Pharmacol. Physiol.* 16, 147–160.
- Breuer, Z., Mayevsky, A., 1992. Brain vasculature and mitochondrial responses to ischemia in gerbils. II. Strain differences and statistical evaluation. *Brain Res.* 598, 251–256.
- Briede, J., Duburs, G., in press. Protective effect of cerebrocrast on rat brain ischaemia induced by occlusion of both common carotid arteries. *Cell Biochem. Funct.* (Available online ahead of print).
- Busch, H.J., Buschmann, I.R., Mies, G., Bode, C., Hossmann, K.A., 2003. Arteriogenesis in hypoperfused rat brain. *J. Cereb. Blood Flow Metab.* 23, 621–628.
- Cho, K.O., La, H.O., Cho, Y.J., Sung, K.W., Kim, S.Y., 2006. Minocycline attenuates white matter damage in a rat model of chronic cerebral hypoperfusion. *J. Neurosci. Res.* 83, 285–291.
- Choy, M., Ganesan, V., Thomas, D.L., Thornton, J.S., Proctor, E., King, M.D., van der Weerd, L., Gadian, D.G., Lythgoe, M.F., 2006. The chronic vascular and haemodynamic response after permanent bilateral common carotid occlusion in newborn and adult rats. *J. Cereb. Blood Flow Metab.* 26, 1066–1075.
- Clark, B.J., Silva Jr., M.R.E., 1967. An afferent pathway for the selective release of vasopressin in response to carotid occlusion and haemorrhage in the cat. *J. Physiol.* 191, 529–542.
- Claus, J.J., Breteler, M.M., Hasan, D., Krenning, E.P., Bots, M.L., Grobbee, D.E., van Swieten, J.C., van Harskamp, F., Hofman, A., 1998. Regional cerebral blood flow and cerebrovascular risk factors in the elderly population. *Neurobiol. Aging* 19, 57–64.
- Clowes, A.W., Reidy, M.A., Clowes, M.M., 1983. Mechanisms of stenosis after arterial injury. *Lab. Invest.* 49, 208–215.
- Davidson, C.M., Pappas, B.A., Stevens, W.D., Fortin, T., Bennett, S.A., 2000. Chronic cerebral hypoperfusion: loss of pupillary reflex, visual impairment and retinal neurodegeneration. *Brain Res.* 859, 96–103.
- Dawson, D.A., Hallenbeck, J.M., 1996. Acute focal ischemia-induced alterations in MAP2 immunostaining: description of temporal changes and utilization as a marker for volumetric assessment of acute brain injury. *J. Cereb. Blood Flow Metab.* 16, 170–174.
- de Bortoli, V.C., Tangrossi Junior, H., de Aguiar Correa, F.M., Almeida Sde, S., de Oliveira, A.M., 2005. Inhibitory avoidance memory retention in the elevated T-maze is impaired after perivascular manipulation of the common carotid arteries. *Life Sci.* 76, 2103–2114.
- de Groot, J.C., de Leeuw, F.E., Oudkerk, M., Hofman, A., Jolles, J., Breteler, M.M., 2000. Cerebral white matter lesions and depressive symptoms in elderly adults. *Arch. Gen. Psychiatry* 57, 1071–1076.
- De Jong, G.I., de Weerd, H., Schuurman, T., Traber, J., Luiten, P.G.M., 1990. Microvascular changes in aged rat forebrain. Effects of chronic nimodipine treatment. *Neurobiol. Aging* 11, 381–389.
- De Jong, G.I., Farkas, E., Plass, J., Keijser, J.N., de la Torre, J.C., Luiten, P.G.M., 1999. Cerebral hypoperfusion yields capillary damage in hippocampus CA1 that correlates to spatial memory impairment. *Neuroscience* 91, 203–210.
- de la Torre, J.C., 2000. Impaired cerebrovascular perfusion. Summary of evidence in support of its causality in Alzheimer's disease. *Ann. N. Y. Acad. Sci.* 924, 136–152.
- de la Torre, J.C., 2002. Vascular basis of Alzheimer's pathogenesis. *Ann. N. Y. Acad. Sci.* 977, 196–215.
- de la Torre, J.C., Pappas, B.A., Prevot, V., Emmerling, M.R., Mantione, K., Fortin, T., Watson, M.D., Stefano, G.B., 2003. Hippocampal nitric oxide upregulation precedes memory loss and A beta 1–40 accumulation after chronic brain hypoperfusion in rats. *Neurol. Res.* 25, 635–641.
- de Leeuw, F.E., de Groot, J.C., Achten, E., Oudekerk, M., Ramos, L.M., Heijboer, R., Hofman, A., Jolles, J., van Gijn, J., Breteler, M.M., 2001. Prevalence of cerebral white matter lesions in elderly people: a population based magnetic resonance imaging study. The Rotterdam Scan study. *J. Neurol. Neurosurg. Psychiatry* 70, 9–14.

- de Wilde, M.C., Farkas, E., Gerrits, M., Kiliaan, A.J., Luiten, P.G.M., 2002. The effect of n-3 polyunsaturated fatty acid-rich diets on cognitive and cerebrovascular parameters in chronic cerebral hypoperfusion. *Brain Res.* 947, 166–173.
- Dreifuss, J.J., Harris, M.C., Tribollet, E., 1976. Excitation of phasically firing hypothalamic supraoptic neurones by carotid occlusion in rats. *J. Physiol.* 257, 337–354.
- Eisel, U.L., Biber, K., Luiten, P.G.M., 2006. Life and death of nerve cells: therapeutic cytokine signaling pathways. *Curr. Signal Transduct. Ther.* 1, 133–146.
- Farkas, E., Luiten, P.G.M., 2001. Cerebral microvascular pathology in aging and Alzheimer's disease. *Prog. Neurobiol.* 64, 575–611.
- Farkas, E., De Jong, G.I., de Vos, R.A.I., Jansen Steur, E.N.H., Luiten, P.G.M., 2000. Pathological features of cerebral capillaries are doubled in Alzheimer's disease and Parkinson's disease. *Acta Neuropathol. (Berl.)* 100, 395–402.
- Farkas, E., de Wilde, M.C., Kiliaan, A.J., Meijer, J., Keijsers, J.N., Luiten, P.G.M., 2002a. Dietary long chain PUFAs differentially affect hippocampal muscarinic 1 and serotonergic 1A receptors in experimental cerebral hypoperfusion. *Brain Res.* 954, 32–41.
- Farkas, E., de Wilde, M.C., Kiliaan, A.J., Luiten, P.G.M., 2002b. Systemic effects of dietary n-3 PUFA supplementation accompany changes of CNS parameters in cerebral hypoperfusion. *Ann. N. Y. Acad. Sci.* 977, 77–86.
- Farkas, E., Donka, G., de Vos, R.A.I., Mihály, A., Bari, F., Luiten, P.G.M., 2004a. Experimental cerebral hypoperfusion imposes white matter injury and microglial activation in the rat brain. *Acta Neuropathol. (Berl.)* 108, 57–64.
- Farkas, E., Inostóris, Á., Domoki, F., Mihály, A., Luiten, P.G.M., Bari, F., 2004b. Diazoxide and dimethyl sulphoxide prevent cerebral hypoperfusion-related learning dysfunction and brain damage after carotid artery occlusion. *Brain Res.* 1008, 252–258.
- Farkas, E., Annaházi, A., Inostóris, Á., Mihály, A., Luiten, P.G.M., Bari, F., 2005. Diazoxide and dimethyl sulphoxide alleviate experimental cerebral hypoperfusion-induced white matter injury in the rat brain. *Neurosci. Lett.* 373, 195–199.
- Farkas, E., de Vos, R.A.I., Donka, G., Jansen Steur, E.N.H., Mihály, A., Luiten, P.G.M., 2006a. Age-related microvascular degeneration in the human cerebral periventricular white matter. *Acta Neuropathol. (Berl.)* 111, 150–157.
- Farkas, E., Inostóris, Á., Domoki, F., Mihály, A., Bari, F., 2006b. The effect of pre- and post-treatment with diazoxide on the early phase of chronic cerebral hypoperfusion in the rat. *Brain Res.* 1087, 168–174.
- Friedrich, P., Aszodi, A., 1991. MAP2: a sensitive cross-linker and adjustable spacer in dendritic architecture. *FEBS Lett.* 295, 5–9.
- Fujii, M., Hara, H., Meng, W., Vonsattel, J.P., Huang, Z., Moskowitz, M.A., 1997. Strain-related differences in susceptibility to transient forebrain ischemia in SV-129 and C57black/6 mice. *Stroke* 28, 805–810 (discussion 1811).
- Harukuni, I., Bhardwaj, A., 2006. Mechanisms of brain injury after global cerebral ischemia. *Neurol. Clin.* 24, 1–21.
- Hayashi, H., Tohda, M., Watanabe, H., Murakami, Y., Matsumoto, K., 2005. The effects of Choto-san on the mRNA expression of Alzheimer's disease related factors in the permanent ischemic rat brain. *Biol. Pharm. Bull.* 28, 744–746.
- Hirao, K., Ohnishi, T., Hirata, Y., Yamashita, F., Mori, T., Moriguchi, Y., Matsuda, H., Nemoto, K., Imabayashi, E., Yamada, M., Iwamoto, T., Arima, K., Asada, T., 2005. The prediction of rapid conversion to Alzheimer's disease in mild cognitive impairment using regional cerebral blood flow SPECT. *NeuroImage* 28, 1014–1021.
- Hodge, R.L., Lowe, R.D., Vane, J.R., 1966. Increased angiotensin formation in response to carotid occlusion in the dog. *Nature* 211, 491–493.
- Hypothermia after Cardiac Arrest Study Group, 2002. Mild therapeutic hypothermia to improve the neurologic outcome after cardiac arrest. *N. Engl. J. Med.* 346, 549–556.
- Iwasaki, H., Olunachi, Y., Kume, E., Kriegelstein, J., 1995. Strain differences in vulnerability of hippocampal neurons to transient cerebral ischaemia in the rat. *Int. J. Exp. Pathol.* 76, 171–178.
- Keynes, R.G., Garthwaite, J., 2004. Nitric oxide and its role in ischaemic brain injury. *Curr. Mol. Med.* 4, 179–191.
- Kobayashi, K., Hayashi, M., Nakano, H., Fukutami, Y., Sasaki, K., Shimazaki, M., Koshino, Y., 2002. Apoptosis of astrocytes with enhanced lysosomal activity and oligodendrocytes in white matter lesions in Alzheimer's disease. *Neuropathol. Appl. Neurobiol.* 28, 238–251.
- Kreutzberg, G.W., 1996. Microglia: a sensor for pathological events in the CNS. *Trends Neurosci.* 19, 312–318.
- Krieger, E.M., 1963. Carotid occlusion in the rat: circulatory and respiratory effects. *Acta Physiol. Lat. Am.* 13, 350–357.
- Laidley, D.T., Colbourne, F., Corbett, D., 2005. Increased behavioral and histological variability arising from changes in cerebrovascular anatomy of the Mongolian gerbil. *Curr. Neurovasc. Res.* 2, 401–407.
- Lash, J.M., Haase, E., Shoukas, A.A., 1992. Systemic responses to carotid occlusion in the anesthetized rat. *J. Appl. Physiol.* 72, 1247–1254.
- Lavinsky, D., Sarmiento Artermi, N., Achaval, M., Netto, C.A., 2006. Chronic bilateral common carotid artery occlusion: a model for ocular ischemic syndrome in the rat. *Graefes Arch. Clin. Exp. Ophthalmol.* 244, 199–204.
- Lee, J.H., Park, S.Y., Shin, Y.W., Hong, K.W., Kim, C.D., Sung, S.M., Kim, K.Y., Lee, W.S., 2006. Neuroprotection by cilostazol, a phosphodiesterase type 3 inhibitor, against apoptotic white matter changes in rat after chronic cerebral hypoperfusion. *Brain Res.* 1082, 182–191.
- Lenzser, G., Kis, B., Bari, F., Busija, D.W., 2005. Diazoxide preconditioning attenuates global cerebral ischemia-induced blood-brain barrier permeability. *Brain Res.* 1051, 72–80.
- Leong, S.K., Ling, E.A., 1992. Amoeboid and ramified microglial: their interrelationship and response to brain injury. *Glia* 6, 39–47.
- Liu, H.X., Zhang, J.J., Zheng, P., Zhang, Y., 2005. Altered expression of MAP-2, GAP-43, and synaptophysin in the hippocampus of rats with chronic cerebral hypoperfusion correlates with cognitive impairment. *Brain Res. Mol. Brain Res.* 139, 169–177.
- Liu, J., Jin, D.Z., Xiao, L., Zhu, X.Z., 2006. Paeoniflorin attenuates chronic cerebral hypoperfusion-induced learning dysfunction and brain damage in rats. *Brain Res.* 1089, 162–170.
- Marosi, M., Rakos, G., Robotka, H., Nemeth, H., Sas, K., Kis, Z., Farkas, T., Lur, G., Vecsei, L., Toldi, J., 2006. Hippocampal (CA1) activities in Wistar rats from different vendors. Fundamental differences in acute ischemia. *J. Neurosci. Methods* 156, 231–235.
- Matsuda, H., 2001. Cerebral blood flow and metabolic abnormalities in Alzheimer's disease. *Ann. Nucl. Med.* 15, 85–92.
- Miura, Y., Grocott, H.P., Bart, R.D., Pearlstein, R.D., Dexter, F., Warner, D.S., 1998. Differential effects of anesthetic agents on outcome from near-complete but not incomplete global ischemia I the rat. *Anesthesiology* 89, 289–291.
- Mooradian, A.D., 1988. Effect of aging on the blood-brain barrier. *Neurobiol. Aging* 9, 31–39.
- Murakami, Y., Ikenoya, M., Matsumoto, K., Li, H., Watanabe, H., 2000. Ameliorative effect of tacrine on spatial memory deficit in chronic two-vessel occluded rats is reversible and mediated by muscarinic M1 receptor stimulation. *Behav. Brain Res.* 109, 83–90.
- Muralikrishna Adibhatla, R., Hatcher, J.F., 2006. Phospholipase A2, reactive oxygen species, and lipid peroxidation in cerebral ischemia. *Free Radical Biol. Med.* 40, 376–387.
- Nellgard, B., Mackensen, G.B., Pineda, J., Wllon III, J.C., Pearlstein,

- R.D., Warner, D.S., 2000. Anesthetic effects on cerebral metabolic rate predict histologic outcome from near-complete forebrain ischemia in the rat. *Anesthesiology* 93, 431–436.
- Ni, J.W., Matsumoto, K., Li, H.B., Murakami, Y., Watanabe, H., 1995. Neuronal damage and decrease of central acetylcholine level following permanent occlusion of bilateral common carotid arteries in rat. *Brain Res.* 673, 290–296.
- Nita, D.A., Nita, V., Spulber, S., Moldovan, M., Popa, D.P., Zagrean, A.M., Zagrean, L., 2001. Oxidative damage following cerebral ischemia depends on reperfusion—a biochemical study in rat. *J. Cell. Mol. Med.* 5, 163–170.
- Nussmeier, N.A., 2002. A review of risk factors for adverse neurologic outcome after cardiac surgery. *J. Extra-Corpor. Technol.* 34, 4–10.
- Obrenovitch, T.P., 1995. The ischaemic penumbra: twenty years on. *Cerebrovasc. Brain Metab. Rev.* 7, 297–323.
- Ohta, H., Nishikawa, H., Kimura, H., Anayama, H., Miyamoto, M., 1997. Chronic cerebral hypoperfusion by permanent internal carotid ligation produces learning impairment without brain damage in rats. *Neuroscience* 79, 1039–1050.
- Ohtaki, H., Fujimoto, T., Sato, T., Kishimoto, K., Fujimoto, M., Moriya, M., Shioda, S., 2006. Progressive expression of vascular endothelial growth factor (VEGF) and angiogenesis after chronic ischemic hypoperfusion in rat. *Acta Neurochir., Suppl.* 96, 283–287.
- Oldendorf, W.H., 1989. Trophic changes in the arteries at the base of the brain in response to bilateral common carotid ligation. *J. Neuropathol. Exp. Neurol.* 48, 534–547.
- Otori, T., Katsumata, T., Muramatsu, H., Kashiwagi, F., Katayama, Y., Terashi, A., 2003. Long-term measurements of cerebral blood flow and metabolism in a rat chronic hypoperfusion model. *Clin. Exp. Pharmacol. Physiol.* 30, 266–272.
- Panakhova, E., Buresova, O., Bures, J., 1986. The effect of binocular and monocular viewing conditions on performance of rats in the Morris water maze. *Physiol. Bohemoslov.* 35, 53–61.
- Panickar, K.S., Norenberg, M.D., 2005. Astrocytes in cerebral ischemic injury: morphological and general considerations. *Glia* 50, 287–298.
- Pappas, B.A., de la Torre, J.C., Davidson, C.M., Keyes, M.T., Fortin, T., 1996. Chronic reduction of cerebral blood flow in the adult rat: late-emerging CA1 cell loss and memory dysfunction. *Brain Res.* 708, 50–58.
- Paravicini, T.M., Miller, A.A., Drummond, G.R., Sobey, C.G., 2006. Flow-induced cerebral vasodilatation in vivo involves activation of phosphatidylinositol-3 kinase, NADPH-oxidase, and nitric oxide synthase. *J. Cereb. Blood Flow Metab.* 26, 836–845.
- Parra, R.S., Mendes, L.A., Fazan Jr., R., Salgado, H.C., 2005. Pressure response to carotid occlusion in diabetic rats: effect of insulin therapy. *Diabetes Res. Clin. Pract.* 68, 12–17.
- Patel, P.M., Drummond, J.C., Cole, D.J., Goskowicz, R.L., 1995. Isoflurane reduces ischemia-induced glutamate release in rats subjected to forebrain ischemia. *Anesthesiology* 82, 996–1003.
- Plaschke, K., 2005. Aspects of ageing in chronic cerebral oligoemia. Mechanisms of degeneration and compensation in rat models. *J. Neural Transm.* 112, 393–413.
- Preston, E., Foster, D.O., 1997. Evidence for pore-like opening of the blood–brain barrier following forebrain ischemia in rats. *Brain Res.* 761, 4–10.
- Ritter, L.S., Stempel, K.M., Coull, B.M., McDonagh, P.F., 2005. Leukocyte–platelet aggregate in rat peripheral blood after ischemic stroke and reperfusion. *Biol. Res. Nurs.* 6, 281–288.
- Sancesario, G., Pietroiusti, A., Cestaro, B., Fusco, F.R., Magrini, A., Patacchioli, F.R., Franceschelli, L., Galante, A., 1997. Mild brain ischemia increases cerebral lipid peroxidation and activates leukocytes in the peripheral blood of rats. *Funct. Neurol.* 12, 283–291.
- Sarti, C., Pantoni, L., Bartolini, L., Inzitari, D., 2002a. Persistent impairment of gait performances and working memory after bilateral common carotid artery occlusion in the adult Wistar rat. *Behav. Brain Res.* 136, 13–20.
- Sarti, C., Pantoni, L., Bartolini, L., Inzitari, D., 2002b. Cognitive impairment and chronic cerebral hypoperfusion: what can be learned from experimental models. *J. Neurol. Sci.* 203–204, 263–266.
- Scheltens, P., Barkhof, F., Leys, D., Wolters, E.C., Ravid, R., Kamphorst, W., 1995. Histopathologic correlates of white matter changes in MRI in Alzheimer's disease and normal aging. *Neurology* 45, 883–888.
- Schlageter, N.L., Carson, R.E., Rapoport, S.I., 1987. Examination of blood–brain barrier permeability in dementia of the Alzheimer type with [<sup>68</sup>Ga]EDTA and positron emission tomography. *J. Cereb. Blood Flow Metab.* 7, 1–8.
- Schmidt-Kastner, R., Truettner, J., Lin, B., Zhao, W., Saul, I., Busto, R., Ginsberg, M.D., 2001. Transient changes of brain-derived neurotrophic factor (BDNF) mRNA expression in hippocampus during moderate ischemia induced by chronic bilateral common carotid artery occlusion in the rat. *Brain Res. Mol. Brain Res.* 92, 157–166.
- Schmidt-Kastner, R., Aguirre-Chen, C., Saul, I., Yick, L., Hamasaki, D., Busto, R., Ginsberg, M.D., 2005. Astrocytes react to oligemia in the forebrain induced by chronic bilateral common carotid artery occlusion in rats. *Brain Res.* 1052, 28–39.
- Shang, Y., Cheng, J., Oi, J., Miao, H., 2005. Scutellaria flavonoid reduced memory dysfunction and neuronal injury caused by permanent global ischemia in rats. *Pharmacol. Biochem. Behav.* 82, 67–73.
- Sopala, M., Danysz, W., 2001. Chronic cerebral hypoperfusion in the rat enhances age-related deficits in spatial memory. *J. Neural Transm.* 108, 1445–1456.
- Stevens, W.D., Fortin, T., Pappas, B.A., 2002. Retinal and optic nerve degeneration after chronic carotid ligation: time course and role of light exposure. *Stroke* 33, 1107–1112.
- Stewart, P.A., Magliocco, M., Hayakawa, K., Farrell, C.L., Del Maestro, R.F., Girvin, J., Kaufmann, J.C., Vinters, H.V., Gilbert, J., 1987. A quantitative analysis of blood–brain barrier ultrastructure in the aging human. *Microvasc. Res.* 33, 270–282.
- Streit, W.J., Kreutzberg, G.W., 1987. Lectin binding by resting and reactive microglial. *J. Neurocytol.* 16, 249–260.
- Suzuki, H., Franz, H., Yamamoto, T., Iwasaki, Y., Konno, H., 1988. Identification of the normal microglial population in human and rodent nervous tissue using lectin-histochemistry. *Neuropathol. Appl. Neurobiol.* 14, 221–227.
- Takizawa, S., Fukuyama, N., Hirabayashi, H., Kohara, S., Kazahari, S., Shinohara, Y., Nakazawa, H., 2003. Quercetin, a natural flavonoid, attenuates vacuolar formation in the optic tract in rat chronic cerebral hypoperfusion model. *Brain Res.* 980, 156–160.
- Thiel, G., 1993. Synapsin I, synapsin II, and synaptophysin: marker proteins of synaptic vesicles. *Brain Pathol.* 3, 87–95.
- Thomas, A.J., Perry, R., Barber, R., Kalaria, R.N., O'Brien, J.T., 2002. Pathologies and pathological mechanisms for white matter hyperintensities in depression. *Ann. N. Y. Acad. Sci.* 977, 333–339.
- Tohda, M., Suwanakitch, P., Jeenapongsa, R., Hayashi, H., Watanabe, H., Matsumoto, K., 2004. Expression changes of the mRNA of Alzheimer's disease related factors in the permanent ischemic rat brain. *Biol. Pharm. Bull.* 27, 2021–2023.
- Tomimoto, H., Akiguchi, I., Wakita, H., Suenaga, T., Nakamura, S., Kimura, J., 1997. Regressive changes of astroglia in white matter lesions in cerebrovascular disease and Alzheimer's disease patients. *Acta Neuropathol. (Berl.)* 94, 146–152.
- Tomimoto, H., Ihara, M., Wakita, H., Ohtani, R., Lin, J.X., Akiguchi, I.,

- Kinoshita, M., Shibasaki, H., 2003. Chronic cerebral hypoperfusion induces white matter lesions and loss of oligodendroglia with DNA fragmentation in the rat. *Acta Neuropathol. (Berl.)* 106, 527–543.
- Tsuchiya, M., Sako, K., Yura, S., Yonemasu, Y., 1992. Cerebral blood flow and histopathological changes following permanent bilateral carotid artery ligation in Wistar rats. *Exp. Brain Res.* 89, 87–92.
- Tsuchiya, M., Sako, K., Yura, S., Yonemasu, Y., 1993. Local cerebral glucose utilisation following acute and chronic bilateral carotid artery ligation in Wistar rats: relation to changes in local cerebral blood flow. *Exp. Brain Res.* 95, 1–7.
- Ueda, H., Fujita, R., 2004. Cell death mode switch from necrosis to apoptosis in brain. *Biol. Pharm. Bull.* 27, 950–955.
- Ulrich, P.T., Kroppenstedt, S., Heimann, A., Kempfski, O., 1998. Laser-Doppler scanning of local cerebral blood flow and reserve capacity and testing of motor and memory functions in a chronic 2-vessel occlusion model in rats. *Stroke* 29, 2412–2420.
- Wakita, H., Tomimoto, H., Akiguchi, I., Matsuo, A., Lin, J.X., Ihara, M., McGeer, P.L., 2002. Axonal damage and demyelination in the white matter after chronic cerebral hypoperfusion in the rat. *Brain Res.* 924, 63–70.
- Wakita, H., Tomimoto, H., Akiguchi, I., Lin, J.X., Ihara, M., Ohtani, R., Shibata, M., 2003. Ibutilast, a phosphodiesterase inhibitor, protects against white matter damage under chronic cerebral hypoperfusion in the rat. *Brain Res.* 992, 53–59.
- Wang, H.H., Chai, C.Y., Kuo, J.S., Wang, S.C., 1970. Participation of cardiac and peripheral sympathetics in carotid occlusion response. *Am. J. Physiol.* 218, 1548–1554.
- Wisniewski, H.M., Vorbrodt, A.W., Wegiel, J., 1997. Amyloid angiopathy and blood–brain barrier changes in Alzheimer's disease. *Ann. N. Y. Acad. Sci.* 826, 161–172.
- Yamamoto, H., Schmidt-Kastner, R., Hamasaki, D.I., Yamamoto, H., Parel, J.M., 2006. Complex neurodegeneration in retina following moderate ischemia induced by bilateral common carotid artery occlusion in Wistar rats. *Exp. Eye Res.* 82, 767–779.
- Zubilewicz, T., Wronski, J., Bourriez, A., Terlecki, P., Guinault, A.M., Muscatelli-Groux, B., Michalak, J., Mellièrè, D., Becquemin, J.P., Allaire, E., 2001. Injury in vascular surgery—The intimal hyperplastic response. *Med. Sci. Monit.* 7, 316–324.