

University of Groningen

Hyperthermic isolated limb perfusion, preoperative radiotherapy, and surgery (PRS) a new limb saving treatment strategy for locally advanced sarcomas

Stevenson, Marc G; Seinen, Jojanneke M; Pras, Elisabeth; Brouwers, Adrienne H; van Ginkel, Robbert J; van Leeuwen, Barbara L; Suurmeijer, Albert J H; Been, Lukas B; Hoekstra, Harald J

Published in:
Journal of Surgical Oncology

DOI:
[10.1002/jso.25008](https://doi.org/10.1002/jso.25008)

IMPORTANT NOTE: You are advised to consult the publisher's version (publisher's PDF) if you wish to cite from it. Please check the document version below.

Document Version
Publisher's PDF, also known as Version of record

Publication date:
2018

[Link to publication in University of Groningen/UMCG research database](#)

Citation for published version (APA):

Stevenson, M. G., Seinen, J. M., Pras, E., Brouwers, A. H., van Ginkel, R. J., van Leeuwen, B. L., Suurmeijer, A. J. H., Been, L. B., & Hoekstra, H. J. (2018). Hyperthermic isolated limb perfusion, preoperative radiotherapy, and surgery (PRS) a new limb saving treatment strategy for locally advanced sarcomas. *Journal of Surgical Oncology*, 117(7), 1447-1454. <https://doi.org/10.1002/jso.25008>

Copyright


Other than for strictly personal use, it is not permitted to download or to forward/distribute the text or part of it without the consent of the author(s) and/or copyright holder(s), unless the work is under an open content license (like Creative Commons).

The publication may also be distributed here under the terms of Article 25fa of the Dutch Copyright Act, indicated by the "Taverne" license. More information can be found on the University of Groningen website: <https://www.rug.nl/library/open-access/self-archiving-pure/taverne-amendment>.

Take-down policy

If you believe that this document breaches copyright please contact us providing details, and we will remove access to the work immediately and investigate your claim.

Hyperthermic isolated limb perfusion, preoperative radiotherapy, and surgery (PRS) a new limb saving treatment strategy for locally advanced sarcomas

Marc G. Stevenson MD¹  | Jojanneke M. Seinen MD¹ | Elisabeth Pras MD, PhD² |
Adrienne H. Brouwers MD, PhD³ | Robbert J. van Ginkel MD, PhD¹ |
Barbara L. van Leeuwen MD, PhD¹ | Albert J. H. Suurmeijer MD, PhD⁴ |
Lukas B. Been MD, PhD¹ | Harald J. Hoekstra MD, PhD¹

¹ Department of Surgical Oncology, University of Groningen, University Medical Center Groningen, Groningen, The Netherlands

² Department of Radiation Oncology, University of Groningen, University Medical Center Groningen, Groningen, The Netherlands

³ Department of Nuclear Medicine and Molecular Imaging, University of Groningen, University Medical Center Groningen, Groningen, The Netherlands

⁴ Department of Pathology and Medical Biology, University of Groningen, University Medical Center Groningen, Groningen, The Netherlands

Correspondence

Lukas B. Been, MD, PhD, Department of Surgical Oncology, University of Groningen, University Medical Center Groningen, BA31, PO Box 30.001, 9700 RB Groningen, The Netherlands.
Email: l.b.been@umcg.nl

Funding information

Stichting MelanomaSarcomaGroningana (Ubbergseveldweg 144, Nijmegen, The Netherlands)

Background: This feasibility study presents the results of a new intensive treatment regimen for locally advanced extremity soft tissue sarcomas (ESTS), consisting of hyperthermic isolated limb perfusion (HILP), preoperative external beam radiotherapy (EBRT), and surgical resection.

Methods: From 2011 to 2016, 11 high grade locally advanced ESTS patients underwent this treatment regimen. Preoperative EBRT (12 × 3 Gy) started <4 weeks following the HILP (TNF- α and melphalan) and the surgical resection was planned to take place <2 weeks following the end of the EBRT.

Results: All patients completed the treatment. After a median follow-up of 32 (23-50) months, the limb was saved in 10 patients (91%), 1 patient (9%) developed a local recurrence, 5 patients (45%) developed distant metastases, and 3 patients (27%) died of their disease. During follow-up two patients (18%) developed a pathologic fracture of the treated limb and three patients (27%) developed a major wound complication requiring surgical intervention. The median overall treatment time (OTT) was 56 (49-69) days.

Conclusions: This intensive treatment regimen is feasible and safe in locally advanced ESTS, and it achieves oncological results that are comparable with conventional HILP treatment. In addition, the major wound complication risk is comparable and the OTT is reduced.

KEYWORDS

limb salvage, neoadjuvant treatment, perfusion, radiation, sarcoma

Abbreviations: EBRT, external beam radiotherapy; EORTC-STBSG, European organization for research and treatment of cancer-soft tissue and bone sarcoma group; ESTS, extremity soft tissue sarcoma; HILP, hyperthermic isolated limb perfusion; IFN- γ , interferon- γ ; ILP, isolated limb perfusion; IQR, interquartile range; IRB, institutional review board; OTT, overall treatment time; PRS, perfusion, preoperative radiotherapy, and surgery; STS, soft tissue sarcoma; TNF- α , tumor-necrosis factor- α ; UMCG, University Medical Center Groningen.

Data presented (oral presentation) at SSO 2017, March 15-18, Seattle, WA.

1 | INTRODUCTION

Annually, approximately 600-700 patients are diagnosed with soft tissue sarcoma (STS) in The Netherlands, making it a relatively rare malignancy which accounts for less than 1% of all cancers in adults.¹

In patients with extremity soft tissue sarcoma (ESTS), amputation does not improve survival rates.² Thus limb salvage treatment has become increasingly important over the years³ and neoadjuvant treatment regimens have been developed to prevent limb amputation in locally advanced ESTS. In the 1990s, there was renewed interest in hyperthermic isolated limb perfusion (HILP), originally developed by Creech et al⁴ in 1957, for treating locally advanced ESTS.⁵⁻⁷ Initially, interferon- γ (IFN), and tumor necrosis factor- α (TNF- α) were added to the commonly used melphalan perfusate. However, IFN was soon abandoned due to ineffectiveness.^{8,9} The addition of TNF- α however, led to high response rates and limb preservation,^{8,9} and eventually to the approval of TNF- α in Europe,¹⁰ resulting in over 40 centers using HILP in the treatment of locally advanced ESTS.¹¹

Since 1991, patients with locally advanced ESTS have been treated at the University Medical Center Groningen (UMCG) with neoadjuvant HILP followed by delayed surgical resection, and postoperative external beam radiotherapy (EBRT) when indicated. Hoven-Gondrie et al¹² described this cohort of 113 patients, of which 63 patients (56%) underwent HILP, surgery, and postoperative EBRT and 50 patients (44%) underwent HILP and surgery alone. This conventional perfusion treatment is extensive, long lasting, and the recovery and waiting time between the different treatment stages is long (6 and 8 weeks between neoadjuvant HILP and surgical resection and another 6 and 8 weeks between surgical resection and the start of the postoperative EBRT, resulting in an overall median treatment time of 22 (20-24) weeks (including the postoperative EBRT). Due to the postoperative timing of the EBRT, radiation schemes are long and high doses are administered that is 30-35 \times 2 Gy. A follow-up study performed at the UMCG showed serious long-term treatment induced morbidity in 63% of patients.¹³ Moreover, the long-term morbidity tends to be higher in postoperative irradiated patient as compared with preoperative EBRT in ESTS.¹⁴

The standard preoperative EBRT dose for ESTS is 50 Gy given in 25 daily fractions of 2 Gy, however, several studies have been conducted combining preoperative hypofractionated EBRT with neoadjuvant chemotherapy.¹⁵

At the UMCG a new intensive treatment regimen consisting of Perfusion, hypofractionated preoperative Radiotherapy, and Surgery (PRS) for locally advanced ESTS was investigated with the ultimate goal to reduce the short- and long-term treatment-induced morbidity and to reduce the overall treatment time (OTT) while achieving comparable oncological outcome. The results of this treatment regimen are presented in this feasibility study.

2 | MATERIALS AND METHODS

2.1 | Patients

From 2011 to 2016, 11 patients, nine males and two females with a median age of 64 (44-74) years were included in this novel, Institutional Review Board (IRB) approved, treatment regimen (IRB protocol review case-number 2010/299). Patients diagnosed with a primarily non-resectable (locally advanced), non-metastatic, high grade ESTS were included in this study. At the UMCG all sarcoma patients are presented and discussed in a weekly multidisciplinary sarcoma team meeting. Accordingly, patients eligible for HILP treatment were included in the PRS treatment regimen based on a tumor board decision. Data were prospectively collected and retrospectively analyzed. The PRS treatment consisted of neoadjuvant HILP, preoperative hypofractionated EBRT, followed by surgical resection with plastic surgical reconstruction when required. All patients were treated by a rehabilitation specialist and/or physiotherapist prior to, during, and after the treatment course, to optimize the functional treatment outcome. Follow-up ended at death or April 30, 2017. Data concerning demographics, tumor characteristics, comorbidity, hospitalization, and follow-up were collected from medical records. The OTT was defined as the time between HILP and surgical resection and was used as marker to estimate the extent of treatment.

2.2 | Perfusion

The HILP procedure at the UMCG is based on the procedure developed by Creech et al.⁴ The operation was performed under general anesthesia. An incision was made, and the major artery and vein of the leg were isolated, collateral vessels ligated, and 3.3 mg heparin per/kg bodyweight was given intravenously. The blood flow of the leg was isolated from the systemic circulation by cannulating the main artery and vein and connecting it to an extracorporeal circuit. Subsequently, a tourniquet was applied to minimize leakage of TNF- α (Beromun[®], Boehringer-Ingelheim GmbH, Vienna, Austria) and/or melphalan (Alkeran[®], GlaxoSmithKline Pharmaceuticals, Research Triangle Park, NC) into the systemic circulation. A precordial scintillation detector and I¹³¹-human serum albumin were used to continuously measure the leakage into the systemic circulation.^{16,17} The ILP was performed under controlled mild hyperthermia (38.5-40.0°C). For upper extremity and popliteal perfusions, 1 mg TNF- α was used; while, 2 mg was used for iliac or femoral perfusions. After 15 min of TNF- α perfusion, melphalan (10 mg/L limb volume for upper extremity and popliteal perfusions and 13 mg/L for iliac and femoral perfusions) was added. After another 45 min, the limb was washed with 2 L (for upper extremity and popliteal perfusions) or 6 L (iliac/femoral) of saline. Afterwards, the limb was filled with red blood cell concentrate (1 U). The cannulas were removed, the vessels repaired, and the heparin antagonized with protamine sulphate. To prevent a compartment syndrome, a closed fasciotomy of the anterior compartment of the lower leg was performed.^{18,19} The patient was closely

observed in the intensive care unit for the first 24 h following the procedure. The complete perfusion technique and leakage monitoring have been previously described in more detail.²⁰

2.3 | Radiotherapy

To complete the neoadjuvant therapy, patients were treated with preoperative hypofractionated PET-CT guided EBRT, which was planned to start 4 weeks after HILP. Patients underwent an FDG PET-CT in radiation position to delineate the tumor, and to obtain gross tumor and planning target volumes (Figure 1). Intensity modulated radiotherapy was delivered with a linear accelerator in a hypofractionated schedule of 12×3 Gy.

2.4 | Resection

After completion of the preoperative EBRT, the surgical resection was scheduled to take place within 2 weeks. Since only patients with locally advanced ESTS were included, extensive surgical resections were performed. To achieve wound closure, plastic surgical reconstructions were performed when required. Excision was classified as R0 when the resection margins were microscopically free of tumor cells, as R1 when resection margins were involved microscopically, and as R2 when resection margins were macroscopically comprised.²¹ Complications that occurred during treatment or within 120 days following the surgical resection were noted and classified according to Clavien-Dindo.²² Wound complications requiring surgical intervention were defined as major wound complication.

2.5 | Histopathologic examination

Prior to treatment, a core needle biopsy was performed for histopathologic typing and grading of the tumor.^{23,24} All pathologic specimens were re-evaluated in 2017 by a pathologist with expertise in STS. The histopathologic tumor response to neoadjuvant treatment

was determined following recently published European Organization for Research and Treatment of Cancer-Soft Tissue and Bone Sarcoma Group (EORTC-STBSG) recommendations.²⁵ As follows: Grade A, no stainable tumor cells left; Grade B, single stainable tumor cells or small clusters (overall <1% left); Grade C, ≥ 1 -10% stainable tumor cells left; Grade D, ≥ 10 -<50% stainable tumor cells left; and Grade E, ≥ 50 % stainable tumor cells left.

2.6 | Statistical analysis

All variables were summarized with frequencies and percentages for discrete variables and medians and interquartile ranges (IQRs) for continuous variables; none of the variables were normally distributed. SPSS Version 22.0 (IBM SPSS Statistics for Windows, Version 22.0 Armonk, NY: IBM Corp) was used for statistical analyses.

3 | RESULTS

All 11 patients, nine males (82%) and two females (18%) with a median age 64 (44-74) years completed the scheduled PRS treatment regimen and all tumors were resectable following the neoadjuvant HILP and preoperative EBRT (Table 1). All tumors were high grade. Due to vascular involvement, one patient (9.1%) needed a vascular reconstruction following the surgical resection of the tumor remnant. Direct plastic surgical reconstructions were performed in three patients (27%) to obtain wound closure. Histopathologic examination of the resected specimens showed six R0 (55%), four R1 (36%) and one R2 resections (9%). The neoadjuvant treatment-induced tumor responses were: one grade A (9%), one grade B (9%), two grade C (18%), five grade D (45%), and two grade E (18%).

A total of 14 complications (either medical or surgical) occurred in 10 patients following the PRS treatment (Table 2). Three patients (27%) developed a major wound complication (requiring surgical intervention), caused by necrosis or ischemia of the wound or surgical

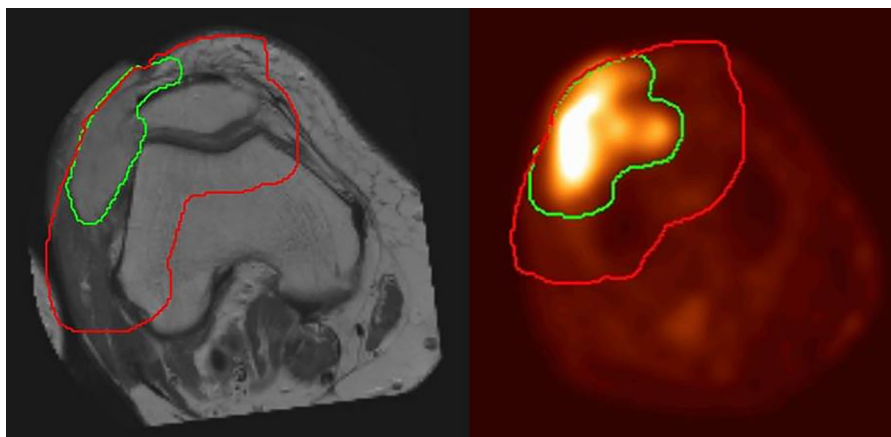


FIGURE 1 Delineation of a soft tissue sarcoma of the knee. In green the gross tumor volume and in red the planning target volume. On the left: a MRI scan fused to the radiotherapy planning CT-scan is shown, while on the right the FDG PET-CT scan is used for the delineation

TABLE 1 Patient and tumor characteristics

Patient	Gender	Age	Histopathologic findings	Location	Tumor size
1	M	32	Synovial sarcoma	Upper leg	6
2	F	41	Synovial sarcoma	Lower leg	4
3	F	74	Pleomorphic undifferentiated sarcoma	Upper leg	10
4	M	54	Pleomorphic undifferentiated sarcoma	Upper leg	17
5	M	63	Pleomorphic undifferentiated sarcoma	Lower leg	9
6	M	71	Myxofibrosarcoma	Upper leg	5
7	M	44	Myxofibrosarcoma	Upper leg	17
8	M	74	Pleomorphic undifferentiated sarcoma	Knee	7
9	M	64	Leiomyosarcoma	Knee	6
10	M	75	Pleomorphic undifferentiated sarcoma	Lower leg	8
11	M	67	Leiomyosarcoma	Knee	6

Age at start of treatment(years). Tumor size; maximum diameter (cm) at preoperative MRI-scan.

flap reconstruction. In one of these patients a lower limb amputation had to be performed due to ischemia causing an on-going secondary infection of the plastic surgery reconstruction. The median OTT for the PRS patients was 56 (49-69) days.

After a median follow-up of 32 (23-50) months, limb salvage was achieved in 10 patients (91%). One patient (9%) developed a local recurrence, five patients (45%) developed distant metastasis and three patients (27%) died of their disease. At end of follow-up six patients (55%) were alive without evidence of disease and two patients (18%) were alive with disease (Table 3). During follow-up, two pathologic fractures (18%) of the treated limb occurred: a femoral and a tibia

compound fracture. The femoral fracture was treated by intramedullary fixation (Figure 2), and the tibia compound fracture was treated conservatively.

4 | DISCUSSION

The current study shows that the combination of neoadjuvant HILP and preoperative EBRT is feasible in locally advanced ESTS. Over the past decades the limb saving treatment for locally advanced ESTS has evolved greatly, and new treatment strategies in ESTS treatment have

TABLE 2 Complications following PRS treatment

	PRS (n = 11)	Complication grade according to Clavien-Dindo ²²
Total amount of complications	N = 14	I-IIIb
Medical	3 (21%)	
Urinary tract infection	1	II
Urinary retention	2	I
Surgical	11 (79%)	
Seroma	2	I
Rash following melphalan administration	1	I
Wound infection needing intravenous antibiotics	1	II
Deep venous thrombosis	1	II
Cellulitis needing intravenous antibiotics	3	II
Wound infection	1	IIIb
Partial flap loss	2	IIIb
Patients developing a complication	10 (91%)	
Patients developing a major wound complication	3 (27%)	

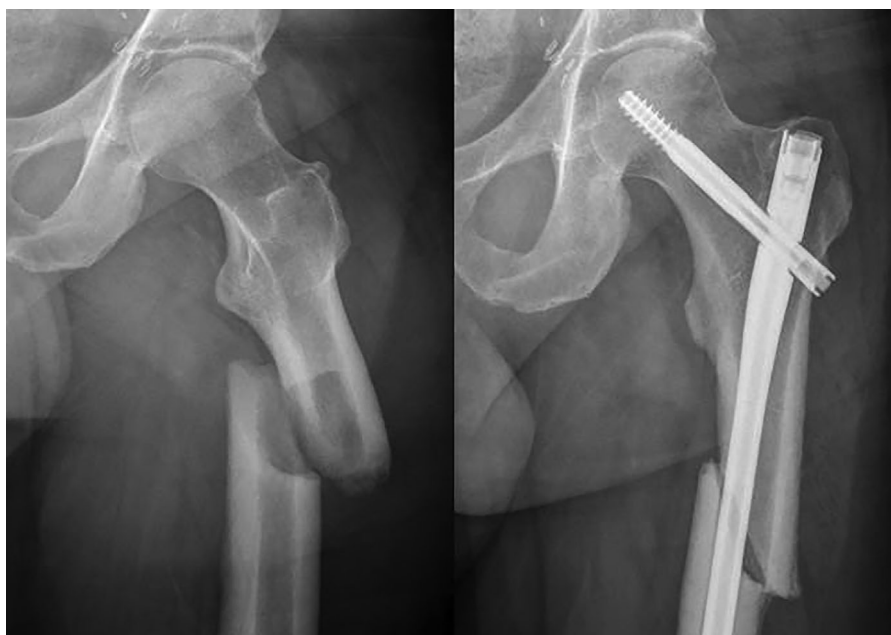Major wound complication: wound complication occurring during treatment or <120 days of surgical resection requiring surgical intervention. Abbreviation: PRS = perfusion, preoperative radiotherapy and surgery.

TABLE 3 Treatment results and oncological outcome

Patient	Histopathologic response grade ^a	R-status ^b	Local recurrence	Distant metastases	Status
1	C	R0	No	No	Alive without disease
2	D	R0	No	Yes	Died of disease
3	D	R0	No	No	Alive without disease
4	D	R1	No	Yes	Died of disease
5	A	R0	Yes	Yes	Died of disease
6	E	R1	No	No	Alive without disease
7	D	R0	No	Yes	Alive with disease
8	B	R0	No	No	Alive without disease
9	D	R1	No	Yes	Alive with disease
10	E	R1	No	No	Alive without disease
11	C	R2	No	No	Alive without disease

^aHistopathologic response Grade A, no stainable tumor cells left; Grade B, single stainable tumor cells or small clusters (overall <1% left); Grade C, ≥1-10% stainable tumor cells left; Grade D, ≥10- <50% stainable tumor cells left; and Grade E, ≥50% stainable tumor cells left.²⁵

^bR-status.²¹

**FIGURE 2** Pathologic femoral fracture treated by intramedullary fixation

been developed with the goal to improve outcome and/ or to decrease morbidity. First, the addition of postoperative EBRT to HILP and delayed surgical resection resulted in a significant improvement in local control without increasing morbidity in ESTS patients.^{26,27} Moreover, a follow-up study showed that dose reduction and a shorter HILP duration was safe and effective for patient outcome, as the 5-year local control rates and (limb) survival were not compromised.²⁸

HILP followed by delayed surgical resection and postoperative EBRT when indicated is commonly used and accepted throughout Europe to achieve local tumor control and limb salvage in locally advanced ESTS.¹¹ This results in a limb salvage

rate of approximately 80-90% in patients who would otherwise be considered for amputation.^{8,9,12,29-32} A systematic review by Bhanu et al²⁹ reported a limb salvage rate of 81%, local recurrence rate of 27%, distant failure rate of 40% and a median 5-year disease specific survival ranging from 47% to 56% following HILP for ESTS.²⁹

The oncological outcome for patients following the PRS treatment regimen that is limb salvage rate of 91%, local recurrence rate of 9%, distant failure rate of 45% and disease-specific survival of 73% seems to be comparable with the oncological outcome as reported in the literature.^{8,9,12,29-32}

The subtle higher limb salvage rate in the current study might be due to the relatively short follow-up. This might also account for the lower local recurrence rate and higher disease specific survival rate in the current study. However, the difference in local recurrence rate might also be caused by the consequent use of preoperative EBRT in the current series. Postoperative EBRT following HILP and delayed surgical resection was shown to improve the local tumor control in locally advanced ESTS, whereas the timing of EBRT does not seem to influence the oncological outcome in resectable ESTS.^{33–36} The distant failure rate in the current series (45%) seems similar to the 40% previously reported.²⁹ However, due to the small sample size and relative short follow-up, the current results should be interpreted with some caution and they need further confirmation in larger patient-cohorts.

The major wound complication risk found in the current study seems to be comparable with earlier reported data, which showed that 26% of patients required re-operation, re-intervention, or deep wound packing due to a wound complication, after surgical resection following isolated limb perfusion.³¹ The subtle higher percentage in the current study might be related to the intensified and shortened treatment course, whereas the administration of EBRT in the preoperative setting in the PRS treatment regimen might also play a role.³³

Due to tumor heterogeneity in STS, tumor necrosis present prior to the start of treatment cannot be distinguished from tumor necrosis induced by neoadjuvant treatment, possibly leading to an overestimation of the effect of neoadjuvant treatment. Therefore, the effectiveness of neoadjuvant treatment, based on tumor necrosis, reported in previous studies, including UMCG HILP series, might be questioned and tumor necrosis should not be used when making treatment decisions.^{25,37} Moreover, the tumor response can differ throughout these heterogeneous tumors while the tumor response at the closest surgical margin might have the most predictive value for local recurrence. In 2016, this led to a proposal for the standardization of the histopathologic examination of STS by the EORTC-STBSG. This protocol included a STS response score in which the tumor response to neoadjuvant treatment is estimated according to the proportion of stainable tumor cells.²⁵ A recent study did not find an association between the STS response score and survival following preoperative EBRT and surgical resection.³⁸ However, further studies considering local control and survival are necessary.

Postoperative EBRT in ESTS is characterized by long treatment times and high doses of radiotherapy resulting in increased long-term morbidity when compared with preoperative EBRT.^{14,15,33,35} Furthermore, the conventional HILP treatment is extensive, long lasting and includes long waiting periods between the different treatment stages (ie, 6–8 weeks between the HILP and surgical resection, and another 6–8 weeks between the surgical resection and the start of postoperative EBRT). Despite the higher major wound complication risk incorporated with preoperative EBRT, a tendency towards the use of preoperative EBRT seems to have originated in the treatment of resectable ESTS.

As mentioned, the standard preoperative EBRT dose in ESTS treatment is 50 Gy in 25 daily fractions of 2 Gy nowadays.¹⁵ In the past

various preoperative hypofractionated EBRT regimens, 10 × 3.5 Gy, 10 × 3 Gy, 5 × 3.5 Gy, and 8 × 3.5 Gy, combined with neoadjuvant chemotherapy have been conducted and resulted in acceptable local control rates.^{39–43}

Recently, the oncological outcome in resectable ESTS and trunk STS following 5 × 5 Gy hypofractionated preoperative EBRT was found to be comparable with the oncological outcome following the commonly used 25 × 2 Gy regimen. Furthermore, only 7% of the patients in the 5 × 5 Gy study developed a wound complication requiring a surgical intervention.⁴⁴ Dose reduction and hypofractionation in localized myxoid liposarcomas is under ongoing investigation and the first results of the DOREMY-study (NCT02106312) are awaited. These new hypofractionated preoperative EBRT schemes might lead to a further reduction in wound complication risk.

In summary, the results of the current study indicate that combining HILP and preoperative hypofractionated EBRT as neoadjuvant treatment is feasible and might further improve the treatment of patients with locally advanced ESTS without increasing the risk of local failure.

5 | CONCLUSION

This study demonstrates that the intensive PRS treatment regimen is feasible and safe in locally advanced ESTS. The PRS treatment which combines neoadjuvant HILP and preoperative EBRT, achieves oncological results that are comparable with oncological outcome from earlier reported data. In addition, the major wound complication risk is comparable and the overall treatment time is reduced.

ACKNOWLEDGMENT

M.G. Stevenson received a research grant from the Groningen Melanoma Sarcoma Foundation.

CONFLICTS OF INTEREST

The authors have no conflicts of interest to declare.

ORCID

Marc G. Stevenson  <http://orcid.org/0000-0002-9986-3505>

REFERENCES

- Soft Tissue Sarcoma incidence, Nederlandse Kankerregistratie, beheerd door IKNL © [July] 2017. Available at: www.cijfersoverkanker.nl
- Rosenberg SA, Tepper J, Glatstein E, et al. The treatment of soft-tissue sarcomas of the extremities: prospective randomized evaluations of (1) limb-sparing surgery plus radiation therapy compared with amputation and (2) the role of adjuvant chemotherapy. *Ann Surg.* 1982;196:305–315.

3. Hoekstra HJ, Schraffordt Koops H, Oldhoff J. Soft tissue sarcoma of the extremity. *Eur J Surg Oncol*. 1994;20:3–6.
4. Creech O, Jr, Kremenz ET, Ryan RF, Winblad JN. Chemotherapy of cancer: regional perfusion utilizing an extracorporeal circuit. *Ann Surg*. 1958;148:616–632.
5. Kremenz ET, Carter RD, Sutherland CM, Hutton I. Chemotherapy of sarcomas of the limbs by regional perfusion. *Ann Surg*. 1977;185:555–564.
6. Lienard D, Ewalenko P, Delmotte JJ, et al. High-dose recombinant tumor necrosis factor alpha in combination with interferon gamma and melphalan in isolation perfusion of the limbs for melanoma and sarcoma. *J Clin Oncol*. 1992;10:52–60.
7. Hoekstra HJ, Schraffordt Koops H, Molenaar WM, Oldhoff J. Results of isolated regional perfusion in the treatment of malignant soft tissue tumors of the extremities. *Cancer*. 1987;60:1703–1707.
8. Eggermont AM, Schraffordt Koops H, Lienard D, et al. Isolated limb perfusion with high-dose tumor necrosis factor-alpha in combination with interferon-gamma and melphalan for nonresectable extremity soft tissue sarcomas: a multicenter trial. *J Clin Oncol*. 1996;14:2653–2665.
9. Eggermont AM, Schraffordt Koops H, Klausner JM, et al. Isolated limb perfusion with tumor necrosis factor and melphalan for limb salvage in 186 patients with locally advanced soft tissue extremity sarcomas. The cumulative multicenter European experience. *Ann Surg*. 1996;224:756–764. discussion 764–5.
10. European Medicines Agency 2014. Available at: www.ema.europa.eu.
11. Verhoef C, de Wilt JH, Grunhagen DJ, et al. Isolated limb perfusion with melphalan and TNF-alpha in the treatment of extremity sarcoma. *Curr Treat Options Oncol*. 2007;8:417–427.
12. Hoven-Gondrie ML, Bastiaannet E, van Ginkel RJ, et al. Limb perfusion in soft tissue sarcomas: twenty years of experience. *Ned Tijdschr Geneesk*. 2013;157:A6148.
13. Hoven-Gondrie ML, Thijssens KM, Geertzen JH, et al. Isolated limb perfusion and external beam radiotherapy for soft tissue sarcomas of the extremity: long-term effects on normal tissue according to the LENT-SOMA scoring system. *Ann Surg Oncol*. 2008;15:1502–1510.
14. Davis AM, O'Sullivan B, Turcotte R, et al. Late radiation morbidity following randomization to preoperative versus postoperative radiotherapy in extremity soft tissue sarcoma. *Radiother Oncol*. 2005;75:48–53.
15. Haas RL, Miah AB, LePechoux C, et al. Preoperative radiotherapy for extremity soft tissue sarcoma; past, present and future perspectives on dose fractionation regimens and combined modality strategies. *Radiother Oncol*. 2016;119:14–21.
16. van Ginkel RJ, Limburg PC, Piers DA, et al. Value of continuous leakage monitoring with radioactive iodine-131-labeled human serum albumin during hyperthermic isolated limb perfusion with tumor necrosis factor-alpha and melphalan. *Ann Surg Oncol*. 2002;9:355–363.
17. Daryanani D, Komdeur R, Ter Veen J, et al. Continuous leakage measurement during hyperthermic isolated limb perfusion. *Ann Surg Oncol*. 2001;8:566–572.
18. Schraffordt Koops H, Oldhoff J, van der Ploeg E, et al. Some aspects of the treatment of primary malignant melanoma of the extremities by isolated regional perfusion. *Cancer*. 1977;39:27–33.
19. Schraffordt Koops H. Prevention of neural and muscular lesions during hyperthermic regional perfusion. *Surg Gynecol Obstet*. 1972;135:401–403.
20. Hoekstra H. *Isolated Limb Perfusion "Atlas of Procedures in Surgical Oncology with Critical, Evidence-based Commentary Notes."* RA Audisio. Singapore 596224: World Scientific Publishing Co, Pte, Ltd; 2009: 259–267.
21. Sobin L. Tumor of bone and soft tissues. R classification. In: Wittekind CH, eds. *TNM Classification of Malignant Tumours, UICC*. New York: Wiley Liss; 2002: 110.
22. Clavien PA, Barkun J, de Oliveira ML, et al. The Clavien-Dindo classification of surgical complications: five-year experience. *Ann Surg*. 2009;250:187–196.
23. Edge SB, Byrd DR, Compton CC, Fritz AG, Green FL, Trotti A. *AJCC Cancer Staging Manual*. New York Dordrecht Heidelberg London: Springer; 2010.
24. Fletcher CDM, Bridge JA, Hogendoorn P, Mertens F. *WHO Classification of Tumours of Soft Tissue and Bone*, 4th ed. 150 Cours Albert Thomas, Lyon, France: IARC; 2013.
25. Wardelmann E, Haas RL, Bovee JV, et al. Evaluation of response after neoadjuvant treatment in soft tissue sarcomas; the European Organization for Research and Treatment of Cancer-Soft Tissue and Bone Sarcoma Group (EORTC-STBSG) recommendations for pathological examination and reporting. *Eur J Cancer*. 2016;53:84–95.
26. Olieman AF, Pras E, van Ginkel RJ, et al. Feasibility and efficacy of external beam radiotherapy after hyperthermic isolated limb perfusion with TNF-alpha and melphalan for limb-saving treatment in locally advanced extremity soft-tissue sarcoma. *Int J Radiat Oncol Biol Phys*. 1998;40:807–814.
27. Thijssens KM, van Ginkel RJ, Pras E, et al. Isolated limb perfusion with tumor necrosis factor alpha and melphalan for locally advanced soft tissue sarcoma: the value of adjuvant radiotherapy. *Ann Surg Oncol*. 2006;13:518–524.
28. Hoven-Gondrie ML, Bastiaannet E, van Ginkel RJ, et al. TNF dose reduction and shortening of duration of isolated limb perfusion for locally advanced soft tissue sarcoma of the extremities is safe and effective in terms of long-term patient outcome. *J Surg Oncol*. 2011;103:648–655.
29. Bhangu A, Broom L, Nepogodiev D, et al. Outcomes of isolated limb perfusion in the treatment of extremity soft tissue sarcoma: a systematic review. *Eur J Surg Oncol*. 2013;39:311–319.
30. Deroose JP, Eggermont AM, van Geel AN, et al. Long-term results of tumor necrosis factor alpha- and melphalan-based isolated limb perfusion in locally advanced extremity soft tissue sarcomas. *J Clin Oncol*. 2011;29:4036–4044.
31. Jakob J, Tunn PU, Hayes AJ, et al. Oncological outcome of primary non-metastatic soft tissue sarcoma treated by neoadjuvant isolated limb perfusion and tumor resection. *J Surg Oncol*. 2014;109:786–790.
32. Grunhagen DJ, de Wilt JH, Graveland WJ, et al. Outcome and prognostic factor analysis of 217 consecutive isolated limb perfusions with tumor necrosis factor-alpha and melphalan for limb-threatening soft tissue sarcoma. *Cancer*. 2006;106:1776–1784.
33. O'Sullivan B, Davis AM, Turcotte R, et al. Preoperative versus postoperative radiotherapy in soft-tissue sarcoma of the limbs: a randomised trial. *Lancet*. 2002;359:2235–2241.
34. Strander H, Turesson I, Cavallin-Stahl E. A systematic overview of radiation therapy effects in soft tissue sarcomas. *Acta Oncol*. 2003;42:516–531.
35. Haas RL, Delaney TF, O'Sullivan B, et al. Radiotherapy for management of extremity soft tissue sarcomas: why, when, and where? *Int J Radiat Oncol Biol Phys*. 2012;84:572–580.
36. Albertsmeier M, Rauch A, Roeder F, et al. External beam radiation therapy for resectable soft tissue sarcoma: a systematic review and meta-Analysis. *Ann Surg Oncol*. 2017; Epub ahead of print. <https://doi.org/10.1245/s10434-017-6081-2>.
37. Vaynrub M, Taheri N, Ahlmann ER, et al. Prognostic value of necrosis after neoadjuvant therapy for soft tissue sarcoma. *J Surg Oncol*. 2015;111:152–157.
38. Schaefer IM, Hornick JL, Barysaukas CM, et al. Histologic appearance after preoperative radiation therapy for soft tissue sarcoma: assessment of the European organization for research and treatment of cancer-Soft tissue and bone sarcoma group response score. *Int J Radiat Oncol Biol Phys*. 2017;98:375–383.

39. Eilber F, Giuliano A, Huth JH. Neoadjuvant chemotherapy, radiation, and limited surgery for high grade soft tissue sarcomas of the extremity. In: Ryan JR BL, eds. *Recent Concepts in Sarcoma Treatment*. Dordrecht, The Netherlands: Kluwer Academic Publishers; 1988:115–116-122.
40. Hoekstra HJ, Schraffordt Koops H, Molenaar WM, et al. A combination of intraarterial chemotherapy, preoperative and postoperative radiotherapy, and surgery as limb-saving treatment of primarily unresectable high-grade soft tissue sarcomas of the extremities. *Cancer*. 1989;63:59–62.
41. Eilber F, Eckardt J, Rosen G, et al. Preoperative therapy for soft tissue sarcoma. *Hematol Oncol Clin North Am*. 1995;9:817–823.
42. Nijhuis PH, Pras E, Sleijfer DT, et al. Long-term results of preoperative intra-arterial doxorubicin combined with neoadjuvant radiotherapy, followed by extensive surgical resection for locally advanced soft tissue sarcomas of the extremities. *Radiother Oncol*. 1999;51:15–19.
43. Temple WJ, Temple CL, Arthur K, et al. Prospective cohort study of neoadjuvant treatment in conservative surgery of soft tissue sarcomas. *Ann Surg Oncol*. 1997;4:586–590.
44. Kosela-Paterczyk H, Szacht M, Morynski T, et al. Preoperative hypofractionated radiotherapy in the treatment of localized soft tissue sarcomas. *Eur J Surg Oncol*. 2014;40:1641–1647.

How to cite this article: Stevenson MG, Seinen JM, Pras E, et al. Hyperthermic isolated limb perfusion, preoperative radiotherapy, and surgery (PRS) a new limb saving treatment strategy for locally advanced sarcomas. *J Surg Oncol*. 2018;1–8. <https://doi.org/10.1002/jso.25008>

SYNOPSIS

A new intensive treatment regimen for locally advanced extremity soft tissue sarcomas is feasible and achieves oncological results that are comparable with conventional perfusion treatment.