

University of Groningen

Platelet serotonin is not elevated in patients with benign head and neck paragangliomas

Berends, Annika M. A.; Eijkelenkamp, Karin; Osinga, Thamara E.; Kerstens, Michiel N.; Links, Thera P.; van Faassen, Martijn; Kema, Ido P.; van der Horst-Schrivers, Anouk N. A.

Published in:
Clinical chemistry and laboratory medicine

DOI:
[10.1515/cclm-2017-0876](https://doi.org/10.1515/cclm-2017-0876)

IMPORTANT NOTE: You are advised to consult the publisher's version (publisher's PDF) if you wish to cite from it. Please check the document version below.

Document Version
Publisher's PDF, also known as Version of record

Publication date:
2018

[Link to publication in University of Groningen/UMCG research database](#)

Citation for published version (APA):

Berends, A. M. A., Eijkelenkamp, K., Osinga, T. E., Kerstens, M. N., Links, T. P., van Faassen, M., Kema, I. P., & van der Horst-Schrivers, A. N. A. (2018). Platelet serotonin is not elevated in patients with benign head and neck paragangliomas. *Clinical chemistry and laboratory medicine*, 56(7), E181-E183. <https://doi.org/10.1515/cclm-2017-0876>

Copyright

Other than for strictly personal use, it is not permitted to download or to forward/distribute the text or part of it without the consent of the author(s) and/or copyright holder(s), unless the work is under an open content license (like Creative Commons).

The publication may also be distributed here under the terms of Article 25fa of the Dutch Copyright Act, indicated by the "Taverne" license. More information can be found on the University of Groningen website: <https://www.rug.nl/library/open-access/self-archiving-pure/taverne-amendment>.

Take-down policy

If you believe that this document breaches copyright please contact us providing details, and we will remove access to the work immediately and investigate your claim.

Downloaded from the University of Groningen/UMCG research database (Pure): <http://www.rug.nl/research/portal>. For technical reasons the number of authors shown on this cover page is limited to 10 maximum.

Letter to the Editor

Annika M.A. Berends*, Karin Eijkelenkamp, Thamara E. Osinga, Michiel N. Kerstens, Thera P. Links, Martijn van Faassen, Ido P. Kema and Anouk N.A. van der Horst-Schrivers

Platelet serotonin is not elevated in patients with benign head and neck paragangliomas

<https://doi.org/10.1515/cclm-2017-0876>

Received September 27, 2017; accepted January 4, 2018

Keywords: blood platelets; head and neck paragangliomas; serotonin.

To the Editor,

Head and neck paragangliomas (HNPGs) are rare neuroendocrine tumors that arise from parasympathetic ganglia in the head, neck and mediastinal region [1]. HNPG can be classified as either sporadic or inherited and are usually benign. The discovery of many new predisposing germline mutations in recent years has resulted in a significant increase of predominantly asymptomatic germline mutation carriers visiting the outpatient clinic in order to be screened for the presence of HNPG, pheochromocytoma (PCC) and sympathetic paragangliomas (sPGL) [2]. Surveillance of these patients is recommended because early detection of an inherited HNPG may allow early treatment with a lower risk of treatment-associated complications. Current surveillance for HNPG consists of periodic radiological imaging of the head and neck region [3]. In contrast to PCC/sPGL, HNPGs rarely secrete (nor)epinephrine. Thus, biochemical screening by measurement of metanephrines in plasma or urine is not a suitable test to screen for HNPG. There is a clinical need for a reliable biomarker for early detection of HNPG in asymptomatic germline mutation carriers and in patients who had resection of an HNPG to screen for recurrent

disease. This would not only be more patient friendly than periodic radiological examinations but could also be more cost-effective.

It has been demonstrated that a substantial proportion of HNPG produces dopamine. We have recently investigated the dopamine concentration in platelets and found that it was higher in patients with HNPG when compared to healthy controls. Unfortunately, dopamine concentration in platelets cannot be considered as a useful biomarker in clinical practice because only 17% of patients had a dopamine concentration in platelets above the upper reference limit (URL) [4]. In another study, we showed that all HNPG tissue samples (n=18) stained positive for aromatic-L-amino-acid decarboxylase (AADC), the enzyme that converts L-3,4-dihydroxyphenylalanine (L-DOPA) to dopamine [5]. In addition, the presence of AADC in HNPG is supported by the high sensitivity of 6-[¹⁸F]fluor-L-3,4-dihydroxyphenylalanine positron emission tomography (¹⁸F-FDOPA-PET) for HNPG [6]. Notably, AADC is also involved in the synthesis of serotonin by converting 5-hydroxytryptophan (5-HTP) to serotonin (5-hydroxytryptamine). The expression of AADC in HNPG tissue in combination with a normal dopamine content in platelets in most HNPG patients could mean that AADC in these tumors contributes more to the biosynthesis of serotonin than of dopamine. In support of this, we have found an extremely high platelet serotonin concentration of 13.07 nmol/10⁹ platelets in a patient with a symptomatic malignant PGL [7, unpublished observation].

We therefore hypothesized that platelet serotonin concentration is elevated in patients with HNPG. In a previous study, the urinary excretion rate of 5-hydroxyindoleacetic acid (5-HIAA) was found to be normal in 114 patients with HNPG [8]. The measurement of serotonin in platelets, however, is a more sensitive method to demonstrate increased serotonin production, at least in neuroendocrine tumors of the small bowel [9].

In this observational study, the platelet serotonin concentration was measured in 28 patients with HNPG and in a control group. We included patients older than

*Corresponding author: Annika M.A. Berends, MD, Department of Endocrinology, University Medical Center Groningen, Hanzeplein 1, 9713 GZ Groningen, P.O. Box 30.001, 9700 RB Groningen, The Netherlands, E-mail: m.a.berends@umcg.nl

Karin Eijkelenkamp, Thamara E. Osinga, Michiel N. Kerstens, Thera P. Links and Anouk N.A. van der Horst-Schrivers: Department of Endocrinology, University of Groningen, University Medical Center Groningen, Groningen, The Netherlands

Martijn van Faassen and Ido P. Kema: Department of Laboratory Medicine, University of Groningen, University Medical Center Groningen, Groningen, The Netherlands

18 years, with a diagnosis of HNPGL without concurrent PCC or sPGL [4] (Table 1). The control group consisted of 68 healthy volunteers (35 men, 33 women, 35–56 years of age). Patients using selective serotonin reuptake inhibitors, tricyclic antidepressants, antiepileptic drugs, monoamine oxidase inhibitors and/or illicit drugs (amphetamine, cocaine, methylphenidate), which are known to interfere with serotonin uptake and/or metabolism, were excluded. The study protocol was approved by the Medical Ethics Committee of the University Medical Center of Groningen. Informed consent was obtained from all patients.

Platelet-rich plasma (PRP) was used for the determination of serotonin in platelets. Platelet serotonin concentration reflects the average exposure to serotonin during the preceding 8–10 days, so this represents a sensitive method for detection of sustained serotonin overproduction. EDTA blood was collected by venipuncture. PRP samples were processed within 1 h and stored on ice afterwards. For PRP preparation, blood was centrifuged at 120g for 30 min at 4 °C; 0.5 mL PRP was used for platelet count (Sysmex XE-2100). PRP was stored at –80 °C after adding EDTA plus the antioxidant L(+) ascorbic acid. Serotonin concentration was analyzed using online sample preparation coupled to isotope dilution liquid chromatography (Symbiosis™ System, Spark Holland, Emmen, the Netherlands) in combination with a XEVO TQ-MS tandem mass spectrometer (Waters, Milford, CT, USA). Serotonin analysis was performed essentially as previously described [10]. The content of serotonin in blood platelets was obtained by

dividing the serotonin concentration in PRP by the platelet concentration in the plasma. The serotonin content in blood platelets is presented as nmol serotonin/10⁹ platelets. The previous established URL for platelet serotonin concentration was 5.4 nmol/10⁹ platelets [8].

Results are presented as mean ± SD or as median with interquartile range. Comparison between groups was carried out with the Mann-Whitney U-test. Statistical analyses were performed with PASW statistics (version 22; IBM/SPSS, Armonk, NY, USA). A two-sided p-value <0.05 was considered statistically significant.

All patients in our study had a benign variant of HNPGL. Except for one patient, all patients had a platelet serotonin concentration below the URL. Compared to the platelet serotonin concentration of healthy volunteers, there were no significant differences (Figure 1; HNPGL 2.91 [2.13–3.71] nmol/10⁹ platelets vs. controls 3.07 [2.23–3.86] nmol/10⁹ platelets, p = 0.75).

With this study, we aimed to find a biomarker for HNPGL, which could be used during the surveillance of germline mutation carriers or after resection of an HNPGL. Unfortunately, our results do not support the potential diagnostic value of serotonin concentration in platelets. There are several possible explanations for our findings.

First, the overproduction of serotonin by HNPGL might be too small for detection against the background of normal serotonin production.

Second, it could be that only a subpopulation of the HNPGLs are endocrine active. All patients in our study had a benign variant of HNPGL. Complaints associated with a benign HNPGL are most often localized due to tumor compression of adjacent structures. Characteristics

Table 1: Characteristics of 28 patients with a head and neck paraganglioma.

Sex, male/female	11/17
Age, years (mean ± SD)	55 ± 17
Tumor location	
Carotid body PGL	14
Jugulotympanic PGL	9
Vagal PGL	1
Multifocal PGL	4
Germline mutations, n (%)	
None (sporadic)	9 (32)
Unknown	5 (18)
Hereditary syndrome	14 (50)
VHL	0 (0)
SDHA	1 (4)
SDHB	8 (28)
SDHD	4 (14)
SDHAF2	1 (4)

HNPGL, head and neck paraganglioma. Hereditary syndrome consisting of germline mutations in the von Hippel-Lindau (VHL), succinate dehydrogenase (SDH), subunit A (SDHA), subunit B (SDHB), subunit C (SDHC), subunit D (SDHD) or assembly factor 2 (SDHAF2).

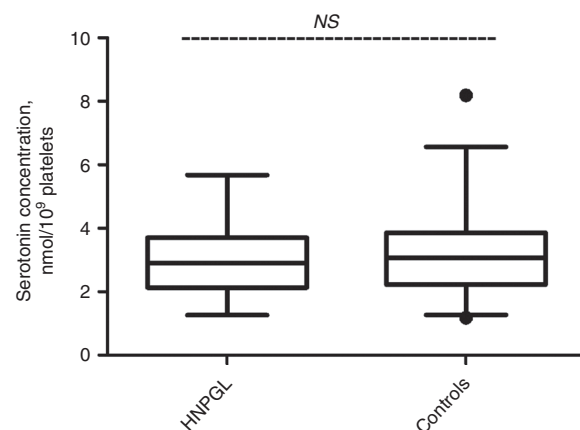


Figure 1: Box plot Whisker representing 5 and 95 percentiles and outliers. Concentration of serotonin in blood platelets in patients with a head and neck paraganglioma (HNPGL) compared with healthy controls (p = 0.75).

of serotonin excess such as flushes, diarrhea and palpitations are less explicitly described. As previously suggested, serotonin platelet concentration could be different in case of malignant disease.

In conclusion, our results do not support the potential diagnostic value of measurement of platelet serotonin concentration in patients with a benign HNPGL. It remains to be determined whether this assay might be clinically useful in patients with a malignant HNPGL.

Author contributions: All the authors have accepted responsibility for the entire content of this submitted manuscript and approved submission.

Research funding: None declared.

Employment or leadership: None declared.

Honorarium: None declared.

Competing interests: The funding organization(s) played no role in the study design; in the collection, analysis, and interpretation of data; in the writing of the report; or in the decision to submit the report for publication.

References

1. DeLellis R, Heitz P, Eng C. Pathology and genetics: tumours of endocrine organs (IARC WHO Classification of Tumours). Lyon, France: IARC Press, 2004.
2. NGS in PPGL (NGSnPPGL) Study Group, Toledo RA, Burnichon N, Cascon A, Benn DE, Bayley JP, Welander J, et al. Consensus statement on next-generation-sequencing-based diagnostic testing of hereditary pheochromocytomas and paragangliomas. *Nat Rev Endocrinol* 2017;13:233–47.
3. Corssmit EP, Romijn JA. Management of endocrine disease; clinical management of paragangliomas. *Eur J Endocrinol* 2014;171:231–43.
4. Osinga TE, van der Horst-Schrivers AN, van Faassen M, Kerstens MN, Dullaart RP, Peters MA, et al. Dopamine concentration in blood platelets is elevated in patients with head and neck paragangliomas. *Clin Chem Lab Med* 2016;54:1395–401.
5. Osinga TE, Korpershoek E, de Krijger RR, Kerstens MN, Dullaart RP, Kema IP, et al. Catecholamine-synthesizing enzymes are expressed in parasympathic head and neck paraganglioma tissue. *Neuroendocrinology* 2015;101:289–95.
6. King KS, Chen CC, Alexopoulos DK, Whatley MA, Reynolds JC, Patronas N, et al. Functional imaging of SDHx-related head and neck paragangliomas: comparison of 18F-fluorodihydroxyphenylalanine, 18F-fluorodopamine, 18F-fluoro-2-deoxy-D-glucose PET, 123I-metaiodobenzylguanidine scintigraphy, and 111In-pentetreotide scintigraphy. *J Clin Endocrinol Metab* 2011;96:2779–85.
7. Osinga TE, Kerstens MN, van der Klauw MM, Koornstra JJ, Wolffenbuttel BH, Links TP, et al. Intestinal pseudo-obstruction as a complication of paragangliomas: case report and literature review. *Neth J Med* 2013;71:512–7.
8. Van Hulsteijn LT, van Duinen N, Romijn JA, Smit JW, Corssmit EP. Urinary 5-HIAA excretion is not increased in patients with head and neck paragangliomas. *Int J Biol Markers* 2012;27:160–3.
9. Meijer WG, Kema IP, Volmer M, Willemsse PH, de Vries EG. Discriminating capacity of indole markers in the diagnosis of carcinoid tumors. *Clin Chem* 2000;46:1588–96.
10. de Jong WH, Wilkens MH, de Vries EG, Kema IP. Automated mass spectrometric analysis of urinary and plasma serotonin. *Anal Bioanal Chem* 2010;396:2609–16.