

University of Groningen

Effect of connective tissue grafting on peri-implant tissue in single immediate implant sites

Zuiderveld, Elise G; Meijer, Henny J A; den Hartog, Laurens; Vissink, Arjan; Raghoobar, Gerry M

Published in:
Journal of Clinical Periodontology

DOI:
[10.1111/jcpe.12820](https://doi.org/10.1111/jcpe.12820)

IMPORTANT NOTE: You are advised to consult the publisher's version (publisher's PDF) if you wish to cite from it. Please check the document version below.

Document Version
Publisher's PDF, also known as Version of record

Publication date:
2018

[Link to publication in University of Groningen/UMCG research database](#)

Citation for published version (APA):

Zuiderveld, E. G., Meijer, H. J. A., den Hartog, L., Vissink, A., & Raghoobar, G. M. (2018). Effect of connective tissue grafting on peri-implant tissue in single immediate implant sites: A RCT. *Journal of Clinical Periodontology*, 45(2), 253-264. <https://doi.org/10.1111/jcpe.12820>

Copyright

Other than for strictly personal use, it is not permitted to download or to forward/distribute the text or part of it without the consent of the author(s) and/or copyright holder(s), unless the work is under an open content license (like Creative Commons).

The publication may also be distributed here under the terms of Article 25fa of the Dutch Copyright Act, indicated by the "Taverne" license. More information can be found on the University of Groningen website: <https://www.rug.nl/library/open-access/self-archiving-pure/taverne-amendment>.

Take-down policy

If you believe that this document breaches copyright please contact us providing details, and we will remove access to the work immediately and investigate your claim.

Downloaded from the University of Groningen/UMCG research database (Pure): <http://www.rug.nl/research/portal>. For technical reasons the number of authors shown on this cover page is limited to 10 maximum.

Effect of connective tissue grafting on peri-implant tissue in single immediate implant sites: A RCT

Elise G. Zuiderveld¹ | Henny J. A. Meijer^{1,2} | Laurens den Hartog¹ |
Arjan Vissink¹ | Gerry M. Raghoobar¹

¹Department of Oral and Maxillofacial Surgery, University of Groningen, University Medical Center Groningen, Groningen, The Netherlands

²Department of Implant Dentistry, Dental School, University of Groningen, University Medical Center Groningen, Groningen, The Netherlands

Correspondence

Elise G. Zuiderveld, Department of Oral and Maxillofacial Surgery, University Medical Center Groningen, Groningen, The Netherlands.

Email: e.zuiderveld@umcg.nl

Funding information

This study was supported by an unrestricted grant from Nobel Biocare Services AG (Gothenburg, Sweden) (implant materials were provided, research grant: 2012-1135).

Abstract

Aim: To assess the effect of connective tissue grafting on the mid-buccal mucosal level (MBML) of immediately placed and provisionalized single implants in the maxillofacial aesthetic zone.

Materials and methods: Sixty patients with a failing tooth were provided with an immediately placed and provisionalized implant. During implant placement, patients randomly received either a connective tissue graft from the maxillary tuberosity ($n = 30$, test group) or no graft ($n = 30$, control group). Follow-up visits were at one (T_1) and twelve months (T_{12}) after final crown placement. The primary outcome measure was any change in MBML compared to the pre-operative situation. In addition, gingival biotype, aesthetics (using the Pink Esthetic Score–White Esthetic Score), marginal bone level, soft tissue peri-implant parameters and patient satisfaction were assessed.

Results: The mean MBML change at T_{12} was -0.5 ± 1.1 mm in the control group and 0.1 ± 0.8 mm in the test group ($p = .03$). No significant differences regarding other outcome variables were observed, neither was gingival biotype associated with a gain or loss in MBML.

Conclusions: This one-year study shows that connective tissue grafting in single, immediately placed and provisionalized implants leads to less recession of the peri-implant soft tissue at the mid-buccal aspect, irrespective of the gingival biotype (www.trialregister.nl: TC3815).

KEYWORDS

connective tissue grafting, immediate implant treatment, implant aesthetics, single implant, soft tissue recession

1 | INTRODUCTION

Immediate single implant placement and provisionalization (IIPP) in the aesthetic zone is a viable treatment option for replacing failing teeth (Del Fabbro, Ceresoli, Taschieri, Ceci, & Testori, 2015; Slagter et al., 2014). Advantages and benefits for patients are reduced treatment time and employment of only one surgical intervention.

Recession and less favourable pink aesthetics of the mid-buccal mucosa when applying immediate implant placement are not uncommon (Chen & Buser, 2014; Cosyn et al., 2016; Tonetti et al., 2017). As demonstrated in animal studies, tooth extraction results in loss of bone and soft tissue, especially at the buccal side. This resorption process is not countered by immediate implant placement (Araujo, Sukekava, Wennstrom, & Lindhe, 2006; Merheb, Quirynen, & Teughels, 2014; Vignoletti et al., 2012). Presumed potential risk factors influencing ridge

resorption and mid-buccal mucosa recession are a thin or pre-existing defect of the buccal bone wall, buccal implant position and a thin gingival biotype (Chen & Buser, 2014; Del Fabbro et al., 2015; Morton & Pollini, 2017; Zuiderveld, den Hartog, Vissink, Raghoobar, & Meijer, 2014). To limit the effects of bone remodelling on the mid-buccal mucosa, it was proposed to place implants at least 2 mm from the internal buccal socket wall and to fill the implant-socket gap with a bone graft (Cardaropoli, Tamagnone, Roffredo, & Gaviglio, 2015; Lin, Chan, & Wang, 2014; Merheb et al., 2014). Additionally, it was suggested to place a connective tissue graft (CTG) during implant placement to thicken the soft tissue (Lee, Tao, & Stoupe, 2016; Lin et al., 2014).

Most studies assessing the use of a CTG in combination with IIPP are case series. They concluded that a connective tissue grafting procedure, with proper 3D implant positioning and bone grafting of the implant-socket gap, can minimize mid-buccal mucosa recession (Chung, Rungcharassaeng, Kan, Roe, & Lozada, 2011; Kan, Rungcharassaeng, & Lozada, 2005; Kan, Rungcharassaeng, Morimoto, & Lozada, 2009; Rungcharassaeng, Kan, Yoshino, Morimoto, & Zimmerman, 2012; Tsuda et al., 2011). The yet performed RCTs showed that a CTG resulted in fewer MBML changes (Migliorati, Amorfini, Signori, Biavati, & Benedicenti, 2015; Yoshino, Kan, Rungcharassaeng, Roe, & Lozada, 2014). Migliorati et al. (2015) also showed a better PES when applying a CTG. However, both RCTs have their limitations. Yoshino et al. (2014) included two small groups of 10 patients and only assessed the change in MBML to the nearest 0.5 mm, without measuring the outcome with aesthetic indices. Migliorati et al. (2015) only included patients with an aesthetically beneficial starting point, thereby reducing the external validity. Yet, a recent systematic review could not find any significant advantages of combining a CTG and a bone graft in relation to implant placement (Khazam et al., 2015). A retrospective study revealed that despite achieving favourable peri-implant soft tissue results through IIPP combined with soft tissue grafting, the buccal mucosa still recessed by ≥ 1 mm in 50% of the patients (Kolerman et al., 2016). This is in line with 5-year results showing increased recession despite CT grafting (Cosyn et al., 2016). Thus, well-designed RCTs are needed to establish the added value of a CTG. Therefore, we tested whether applying a CTG results in less mid-buccal mucosa recession in immediate implant cases.

2 | MATERIAL AND METHODS

2.1 | Study design

Consecutive patients (aged ≥ 18 years) referred for implant treatment between December 2012 and July 2015 due to a single failing tooth in the maxillary aesthetic zone (incisor, canine, first premolar) were considered for inclusion. Patients were eligible if they (i) showed adequate oral hygiene (i.e. modified plaque and sulcus bleeding index ≤ 1) (Mombelli, van Oosten, Schurch, & Land, 1987); (ii) had a diastema width of ≥ 6 mm and sufficient inter-occlusal space for a non-occluding provisional restoration; (iii) had no medical and general contraindications for the surgical procedure (i.e. ASA score $\geq III$ (Smeets, de Jong,

Clinical Relevance

Scientific rationale for the study: There is a paucity of well-designed randomized controlled clinical trials assessing the effect of connective tissue grafting on the aesthetic outcome of implants placed in the aesthetic zone.

Principal findings: One year after implant placement, the mid-buccal mucosal level gained, on average, 0.1 mm after a connective tissue graft was installed. In contrast, if no soft tissue graft was applied, there was an average recession of 0.5 mm, irrespective of the gingival biotype. The aesthetics were comparable in both groups.

Practical implications: Immediate implant placement and provisionalization, combined with connective tissue grafting, may preserve the buccal mucosa level better around dental implants.

& Abraham-Inpijn, 1998)); (iv) had no active and uncontrolled periodontal disease (probing pocket depths ≥ 4 mm and bleeding on probing [index score > 1]); (v) did not smoke; (vi) had not received head and neck radiation, and (vii) were not pregnant (Figure 1). Informed consent was obtained before enrolment. The study was approved by our Medical Ethical Committee (NL43085.042.13) and registered in a trial register (www.trialregister.nl: TC3815).

Patients were only included if the buccal socket wall had a bony defect of < 5 mm in a vertical direction. The height of the bone defect was measured after the failing tooth was extracted, using a periodontal probe at the mid-buccal, mesial and distal aspect of the failing tooth and the adjacent teeth (Slagter, Meijer, Bakker, Vissink, & Raghoobar, 2015). Random allocation was carried out by sealed envelopes opened by a research nurse not involved in the study. All patients were treated with tapered implants (NobelActive, Nobel Biocare AB, Gothenburg, Sweden) placed in the extraction socket and immediately restored in combination with

- no soft tissue graft (control group);
- a connective tissue graft harvested from the maxillary tuberosity region (test group).

2.2 | Intervention procedure

Patients started taking antibiotics (amoxicillin 500 mg, t.i.d. for 7 days or clindamycin 300 mg, q.i.d. for 7 days) a day before the operation. A 0.2% chlorhexidine mouthwash was used twice daily for 7 days.

All surgical procedures were performed under local anaesthesia by one oral and maxillofacial surgeon (G.M.R.). The failing tooth was removed as atraumatically as possible by detaching the periodontal ligament from the failing tooth without raising a flap. The implant site was prepared on the palatal side of the alveolus according to the manufacturer's manual using a surgical template representing the ideal position of the prospective implant crown. The last used implant drill was placed as a space maintainer to augment the gap between the drill

and peri-implant bone with a 1:1 mixture of autogenous and anorganic bovine bone (Geistlich Bio-Oss[®], Geistlich Pharma AG, Wolhusen, Switzerland) (Slagter et al., 2015). The autogenous bone was harvested from the maxillary tuberosity region. After careful removal of the implant drill, the implant was placed 3 mm apical to the most apical aspect of the prospective clinical crown (Figure 2a,b).

An implant-level impression was taken to fabricate a screw-retained laboratory-made provisional crown using engaging temporary abutment and composite. Then, a corresponding healing abutment was connected to the implant. Next, a split-thickness CTG was harvested from the test group's maxillary tuberosity region where the bone graft had been taken. The CTG was placed in a supraperiosteal envelope flap prepared at the buccal aspect without using vertical incisions. The CTG was secured with vertical and horizontal mattresses (4-0 vicryl, Johnson & Johnson Gateway, Piscataway, USA) (Figure 2c).

The wounds were closed with Ethilon 5-0 nylon sutures (Johnson & Johnson) in both groups.

The same day as implant placement, the healing abutment was removed and the screw-retained provisional crown was fitted directly onto the implant with 20Ncm and adjusted to free it from centric contacts with antagonist teeth. Patients were instructed to follow a soft diet and to avoid exerting force on the provisional restoration.

After a 3 months provisional phase, a final open-tray impression was taken at implant level using polyether impression material (Impregum Penta, 3M ESPE, Seefeld, Germany). Next, an individualized zirconia abutment (NobelProcera, Nobel Biocare AB) was made. Abutment screws were torqued with 35Ncm. Depending on the location of the screw access hole, the final crown was screw-retained or cement-retained with glass ionomer cement (Fuji Plus cement, GC Europe, Leuven, Belgium) (Slagter et al., 2015).

All prosthetic procedures were accomplished by two prosthodontists (H.J.A.M. and C.S.).

2.3 | Photographic assessment

The primary outcome, MBML change, was assessed one (T_1) and 12 months (T_{12}) after placement of the final implant crown and compared to baseline mucosal levels of the failing tooth (T_0) as measured on standardized intra-oral photographs (Canon EOS 650D with ring flash) (Meijndert, Meijer, Raghoobar, & Vissink, 2004). Any changes in inter-proximal mucosal levels (IML) were assessed using the same method. For calibration, photographs were taken with a periodontal probe (Williams Color-Coded probe; Hu-Friedy Chicago, IL, USA) held in close contact and parallel to the long axis of the tooth adjacent to the implant and analysed (Adobe Photoshop CS5.1, Adobe Systems Inc., San Jose, USA). At T_0 , a horizontal line was drawn through the incisal edges of the natural neighbouring teeth (reference line). Next, the distance between the reference line and the mucosal margin of the failing tooth was measured. The measurements were repeated at T_1 . For mid-buccal mucosal level changes between T_1 and T_{12} , the incisal edge of the implant crown was used as a reference (Figure 3a,b).

The aesthetics of the peri-implant mucosa and implant crown were assessed from photographs taken at T_{12} using the Pink Esthetic Score-White Esthetic Score (PES/WES) (Belser et al., 2009). When possible, the implant crown was captured in one picture with the neighbouring dentition and contra-lateral tooth.

2.4 | Radiographic assessment

A change in marginal bone level was measured from standardized digital intra-oral radiographs taken with an individualized laboratory-made

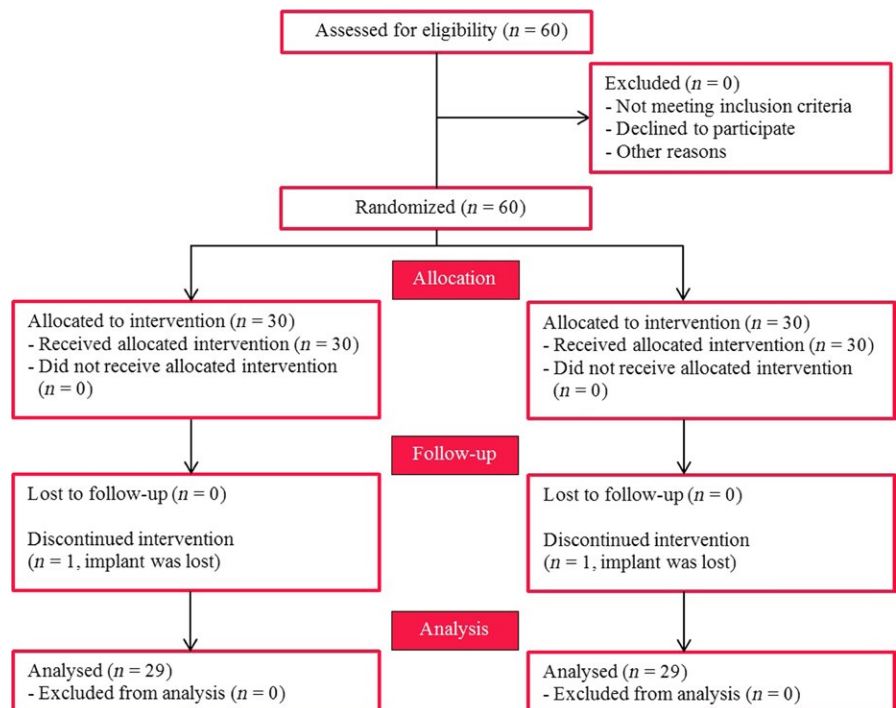


FIGURE 1 Cohort flow diagram

acrylic splint using the cast model of the dentition (Meijndert et al., 2004), at T_1 and T_{12} (Fig. S1). Specifically designed software was applied for full-screen analysis of the radiographs (Slagter et al., 2015). Bone exceeding the implant platform was scored as no bone loss.

2.5 | Clinical assessments

Clinical data were collected at T_0 , T_1 and T_{12} , viz.: (i) biotype, as measured by means of transparency of a periodontal probe through the gingival margin (only at T_0) (Kan, Morimoto, Rungcharassaeng, Roe, & Smith, 2010); (ii) probing pocket depth using a manual periodontal probe at the mesio-buccal, mid-buccal, and disto-buccal and

mid-palatal aspect; (iii) amount of plaque (modified plaque index) (Mombelli et al., 1987); (iv) bleeding after probing (modified sulcus bleeding index) (Mombelli et al., 1987); (v) gingival condition (gingival index) (Loe, 1967); (vi) width of the keratinized mucosa: no keratinized mucosa, <1 mm of keratinized mucosa, 1–2 mm of keratinized mucosa, ≥ 2 mm of keratinized mucosa; (vii) volume of the inter-proximal papilla, using the papilla index (Jemt, 1997); (viii) implant survival; (ix) implant success, defined as ≤ 1 mm marginal bone loss one-year postloading and ≤ 0.2 mm thereafter and the absence of pain, infection, mobility, peri-implant radiolucency and alteration in sensitivity (Albrektsson, Zarb, Worthington, & Eriksson, 1986). All the measurements were taken by a single examiner (E.G.Z.) who was blinded regarding the group allocation.

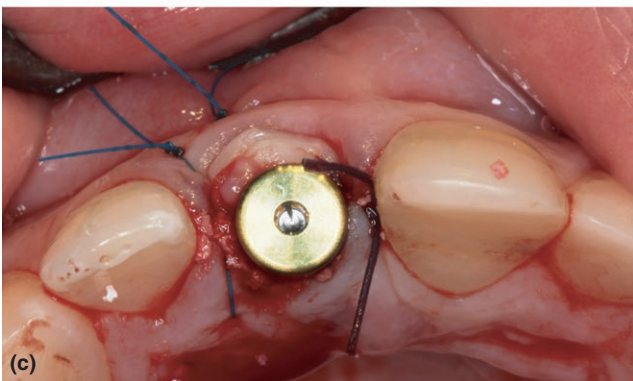
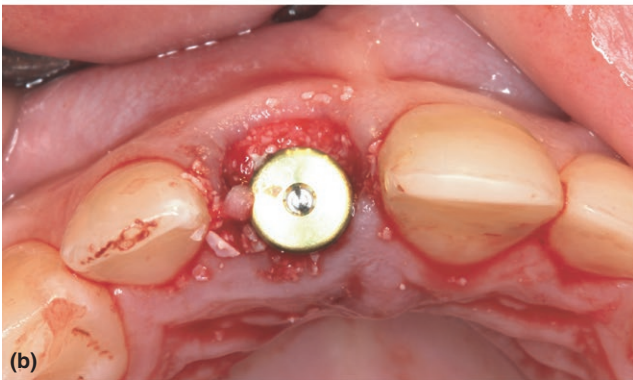
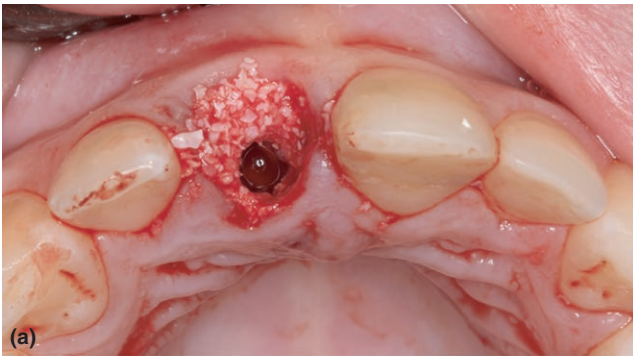


FIGURE 2 (a) Extraction socket with grafted buccal implant-socket gap. (b) Implant is placed in the grafted extraction socket without flap elevation and covered with a temporary abutment. (c) In addition, in the test group, a connective tissue graft is placed suprapariosteally in an envelope flap buccally from and on top of the grafted extraction socket. The flap and connective tissue graft are secured with sutures

2.6 | Patient satisfaction

Patient satisfaction was assessed at T_0 , T_1 and T_{12} using the OHIP-14 questionnaire (van der Meulen, John, Naeije, & Lobbezoo, 2012) complemented with questions about overall satisfaction with the current dentition compared to the pre-operative situation (Visual Analogue Scale: VAS). A questionnaire with items regarding aesthetics and satisfaction with the treatment procedure was also completed using VAS scales. All questionnaires were completed just before clinical data collection and in the absence of the examiner.

2.7 | Statistical analysis

G*power version 3.1 was used to determine the sample size (Faul, Erdfelder, Buchner, & Lang, 2009), and 0.5 mm recession of the mid-buccal mucosa from implant placement to 12 months after placement of the final implant crown was considered as a clinically relevant difference between groups. A minimum of 25 patients per group (one-sided significance level of 5%, power of 80%) was needed to cover the expected standard deviation of 0.7 mm, as derived from the literature (Slagter et al., 2015). Five additional patients were added to each of the groups to compensate for withdrawals.

The inter- and intra-observer reliability of the photographic, radiographic and aesthetic assessment, according to the twelve randomly selected photographs and radiographs (i.e. 15%) judged by two observers (E.G.Z. and L.d.H.) and again repeated by one observer (E.G.Z.) with a two-week interval, was calculated using the intraclass correlation coefficient (ICC). 95% limits of agreement were depicted.

Normality of the continuous variables was assessed with the Shapiro-Wilk test. Normal Q-Q plots were depicted. Inter-group differences of normal distributed variables were evaluated with independent t tests. Non-normal distributed variables were evaluated with Mann-Whitney tests. Categorical data were explored using Chi-square tests or Fisher's exact tests. Wilcoxon tests were used for within-group statistical analyses. A regression analysis was performed to check the possible confounding influence of gingival biotype and height of the bone defect. First, a crude analysis of the influence of soft tissue grafting on the change in MBML was performed for the

time interval T_0 – T_{12} . Next, two possible confounders were added to the crude analysis to assess their effect on the association. All analyses used $p < .05$ to indicate statistical significance (SPSS Statistics 23.0, SPSS Inc.; IBM Corporation, Chicago, IL, USA).

3 | RESULTS

The characteristics of the 60 included patients and treatment specifications are depicted in Table 1 and Figure 4a–f. No signs of soft tissue

complications at the donor site, or extensive bleeding or perforation through the maxillary sinuses, were observed. During follow-up, there were no objective signs of infection.

One implant in each group was lost due to failing osseointegration (96.7% implant survival in both groups). At T_{12} , no implants displayed marginal bone loss exceeding 1 mm, and all other success criteria were fulfilled, resulting in a success rate of 96.7% for both groups.

3.1 | Reliability of photographic and radiographic assessments

ICCs were 0.88 (95%CI 0.72–0.95) and 0.83 (95%CI 0.60–0.93) for the photographic intra- and inter-observer agreement, respectively. Regarding the radiographic assessment, respective ICCs for intra- and inter-observer agreement were 0.71 (95%CI 0.32–0.87) and 0.91 (95%CI 0.75–0.96).

PES/WES ICCs were 0.86 (95%CI 0.68–0.94) and 0.90 (95%CI 0.77–0.96) for intra-observer and inter-observer agreement, respectively.

3.2 | Change in mid-buccal and inter-proximal mucosal level

At T_{12} , MBML loss significantly differed between the control (-0.5 ± 1.1 mm) and test group (0.1 ± 0.8 mm; $p = .03$; Table 2). In both groups, the changes in MBML between T_1 and T_{12} , were negligible ($p = .74$).

IML at T_{12} at both sides of the implant was comparable for the control group and test group (mesial: $p = .65$, distal: $p = .27$; Table 2).

3.3 | Change in radiographic marginal bone level

Between T_1 and T_{12} , the average loss of marginal bone was 0.06 ± 0.42 mm and 0.04 ± 0.46 mm on the mesial side in the control group and test group, respectively. Distal sides of the control and test groups gained, on average, 0.03 ± 0.38 mm and 0.02 ± 0.37 mm, respectively. The inter-group results were comparable (control group: $p = .49$; test group: $p = .96$; Table 2).

TABLE 1 Patient characteristics and treatment specifications per study group

Variable	Control group	Test group
Male/female ratio	15/15	13/17
Age (years) mean \pm SD (range)	47.8 \pm 16.5 (20.9–82.2)	45.5 \pm 15.5 (19.5–67.8)
Gingival biotype thin/thick	15/15	20/10
Implant site location $I_1/I_2/C/P_1$	12/10/7/1	16/9/3/2
Pre-operative bone defect (mm) mean \pm SD	4.3 \pm 0.87	4.7 \pm 0.66
3–4/4–5 mm	6/24	3/27
Implant length (mm)	15/18	5/25
Implant diameter (mm)	3.5/4.3	14/16
		11/19

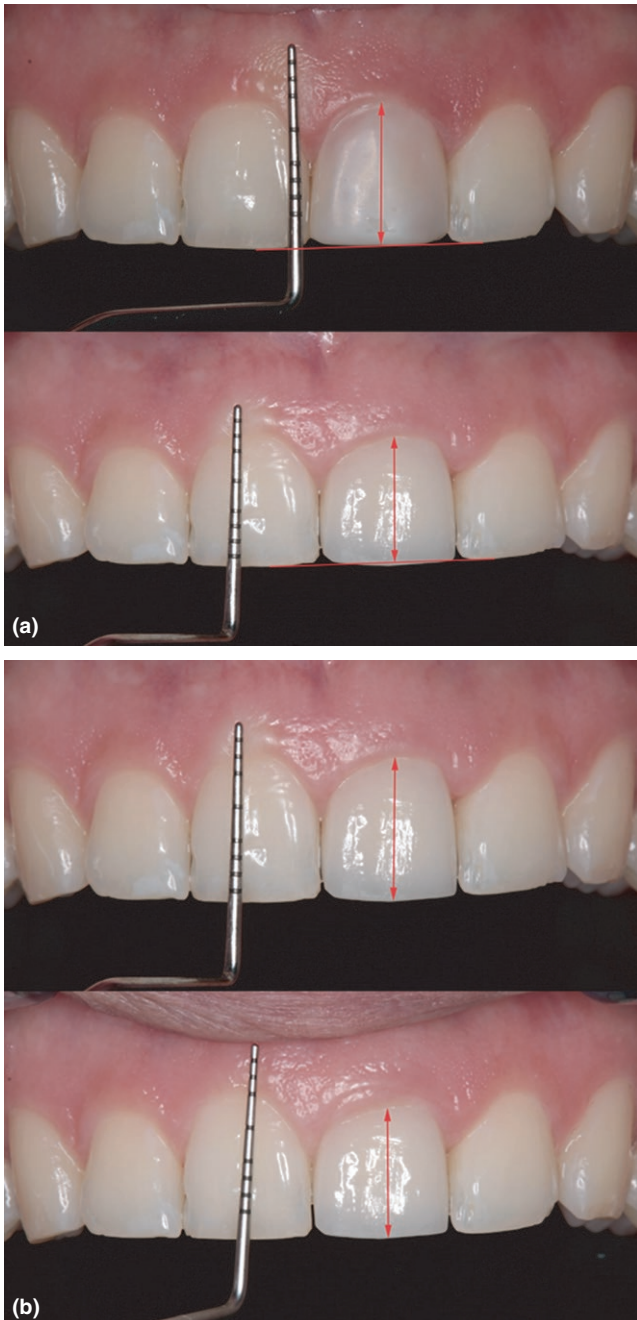


FIGURE 3 (a) Measurement of change in MBML between T_0 and T_1 . (b) Measurement of change in MBML between T_1 and T_{12}

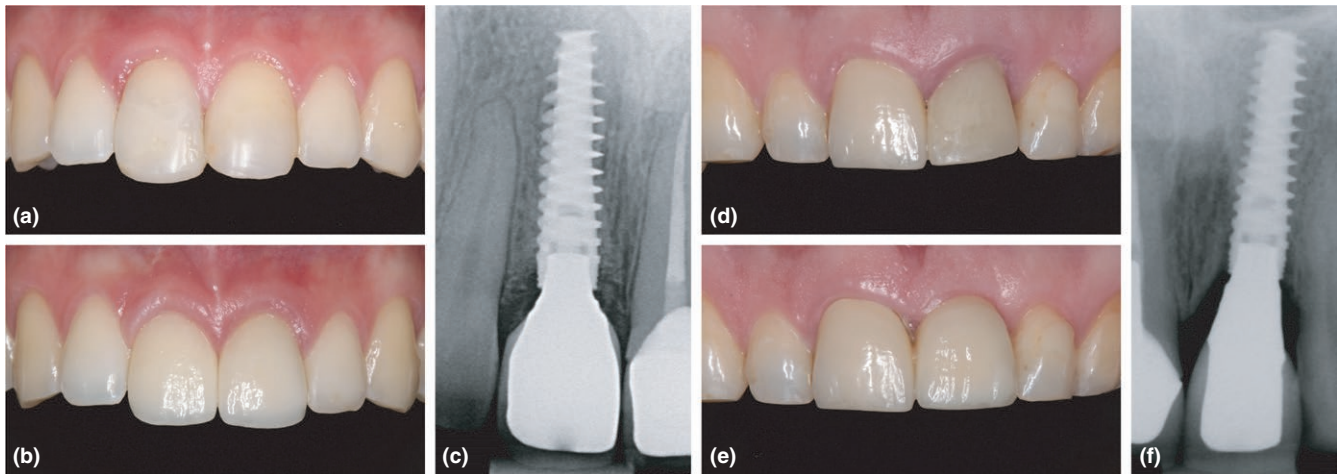


FIGURE 4 (a) Test group: pre-operative clinical situation of the failing right central incisor. (b) Test group: clinical situation one year after placement of the right central final crown. (c) Test group: dental radiograph one year after placement of the final crown. (d) Control group: pre-operative clinical situation of the left central incisor. (e) Control group: clinical situation one year after placement of the left central final crown. (f) Control group: dental radiograph one year after placement of the final crown

3.4 | Clinical outcome

Data regarding probing pocket depths and papilla volume around the failing tooth and implant crown are depicted in Table 2. No statistical significant differences were found between the groups. At T_{12} , more than 96% of the patients in both groups had no plaque around the implant crown (score 0). With respect to bleeding after probing, 45% of the control and 55% test group patients had none (score 0). Score 1 bleeding after probing (isolated bleeding spots) was encountered in 45% and 31% of the patients and score 2 (confluent red line) in 10% and 14% of the patients in the control group and test group, respectively.

At T_{12} , there were no signs of gingival inflammation (score 0) in 100% of the patients in the control group and in 93% of the test group. Two patients in the test group had a score 1 (mild inflammation).

At T_{12} , one patient in the test group had no keratinized mucosa at the buccal side of the implant (score 0), and one patient had a keratinized mucosa with a width of 1–2 mm (score 2). All other patients had a keratinized mucosa of >2 mm (score 3).

3.5 | Aesthetic assessment

No significant differences between both groups were noticed with respect to PES and WES total scores and separate items, with the exception of the surface texture of the implant crown in favour of the control group (Table 2). An acceptable level of aesthetics (PES/WES ≥ 6) was attained in 78.7% of the cases for the peri-implant mucosa and in 85.1% of the cases for the implant crown.

3.6 | Patient satisfaction

The VAS scores acquired during follow-up showed no differences in patient satisfaction between the groups (Table 3). Overall, patients reported high levels of satisfaction with the aesthetic outcome (VAS score of at least 9.0). 77% of the patients would recommend

the treatment to others. Within-group comparison of satisfaction with the current dental situation showed a favourable improvement ($p = .00$) between T_0 and T_1 . There was no difference in satisfaction between T_1 and T_{12} ($p = .06$). The same applies to satisfaction with the current dental situation compared to the situation before treatment ($p = .89$).

The total score for the OHIP-14 questionnaire did not reveal significant differences between the groups. Within-group comparisons revealed a significant improvement in satisfaction between T_0 and T_1 ($p = .00$) and between T_1 and T_{12} ($p = .00$).

3.7 | Regression analysis

Regression analysis revealed that CT grafting leads to a gain in MBML between T_0 and T_{12} (regression coefficient of 0.57; $p = .03$). The corrected analysis on including gingival biotype ($p = .91$) and height of the bone defect ($p = .71$) showed that both factors had no influence on the MBML as concluded from a negligible change of the regression coefficient to 0.54 ($p = .06$).

4 | DISCUSSION

The results of our study suggest that placing a CTG in IIPP leads to less recession of the mid-buccal mucosa. This finding is in line with that reported in two earlier RCTs (Migliorati et al., 2015; Yoshino et al., 2014), with a mean recession of 0.3 mm on applying a CTG versus 0.7 mm in which no graft was used. Our study even demonstrated a more favourable outcome, viz. a mean gain of 0.1 mm in patients receiving a connective tissue graft compared to a mean recession of 0.5 mm in the control group, without excluding patients with a disharmonious mucosal level at baseline as done by Migliorati et al. (2015). This suggests that CT grafting can limit the amount of recession and might at least maintain the MBML at the same height as the baseline levels.

TABLE 2 Changes in marginal soft tissue level, marginal bone level, aesthetic evaluation and clinical outcome from baseline to twelve months after final crown placement

Variable	Control group (n = 29)	Test group (n = 29)	p-value	Control group (n = 29)	Test group (n = 29)	p-value	Control group (n = 29)	Test group (n = 29)	p-value
	T ₀ -T ₁ (mean ± SD)	T ₀ -T ₁ (mean ± SD)		T ₁ -T ₁₂ (mean ± SD)	T ₁ -T ₁₂ (mean ± SD)		T ₀ -T ₁₂ (mean ± SD)	T ₀ -T ₁₂ (mean ± SD)	
MBML (mm)	-0.5 ± 1.0	0.1 ± 0.9	.02	0.0 ± 0.3	0.0 ± 0.3	.74	-0.5 ± 1.1	0.1 ± 0.8	.03
IML									
Mesial of implant (mm)	-0.3 ± 0.8	-0.4 ± 0.7	.80	-0.1 ± 0.5	0.2 ± 0.4	.21	-0.4 ± 1.0	-0.3 ± 0.7	.65
Distal of implant (mm)	-0.6 ± 0.7	-0.4 ± 0.6	.22	-0.0 ± 0.4	-0.1 ± 0.5	.86	-0.6 ± 0.6	-0.4 ± 0.7	.27
Marginal bone level									
Mesial of implant (mm)	T ₀ (median(IQR))		p-value	T ₁ (median (IQR))		p-value	T ₁₂ (median (IQR))		p-value
Distal of implant (mm)	0.9 (0.2-1.2)		.73	0.8 (0.0-1.5)		.73	0.8 (0.5-1.2)		.76
	0.5 (0.0-1.2)		.93	0.3 (0.0-1.1)		.93	0.8 (0.0-1.1)		.99
PES total									
	T ₀ (mean ± SD) (n = 30)		p-value	T ₁ (mean ± SD) (n = 29)		p-value	T ₁₂ (mean ± SD) (n = 29)		p-value
Mesial papilla	6.8 ± 1.5		.21	6.4 ± 1.5		.21	6.4 ± 1.5		.21
Distal papilla	1.5 ± 0.5		.60	1.5 ± 0.5		.60	1.5 ± 0.5		.60
Curvature of facial mucosa	1.6 ± 0.5		.29	1.4 ± 0.5		.29	1.4 ± 0.5		.29
Level of facial mucosa	1.5 ± 0.5		.37	1.3 ± 0.7		.37	1.3 ± 0.7		.37
Root convexity/soft tissue colour and texture	1.2 ± 0.5		.78	1.2 ± 0.5		.78	1.2 ± 0.5		.78
	1.1 ± 0.6		.30	0.9 ± 0.7		.30	0.9 ± 0.7		.30
WES total									
Tooth form	7.4 ± 1.3		.30	6.9 ± 1.9		.30	6.9 ± 1.9		.30
Outline/volume	1.2 ± 0.4		.69	1.2 ± 0.6		.69	1.2 ± 0.6		.69
Colour (hue/value)	1.5 ± 0.5		.11	1.7 ± 0.5		.11	1.7 ± 0.5		.11
Surface texture	1.6 ± 0.5		.13	1.3 ± 0.5		.13	1.3 ± 0.5		.13
Translucency/characterization	1.6 ± 0.5		.04	1.3 ± 0.5		.04	1.3 ± 0.5		.04
	1.5 ± 0.5		.13	1.3 ± 0.6		.13	1.3 ± 0.6		.13
PES/WES total	14.2 ± 2.4		.18	13.2 ± 2.9		.18	13.2 ± 2.9		.18

(Continues)

TABLE 2 (Continued)

	T_0 (mean \pm SD) (n = 30)	p-value	T_1 (mean \pm SD) (n = 29)	p-value	T_{12} (mean \pm SD) (n = 29)	p-value
Probing pocket depth (mm)						
Mesial of tooth/implant	2.6 \pm 0.9	.52	3.0 \pm 1.2	.90	3.0 \pm 0.9	2.8 \pm 1.1
Mid-buccal of tooth/implant	2.6 \pm 1.4	.37	2.2 \pm 1.0	.22	2.5 \pm 1.2	2.3 \pm 0.9
Distal of tooth/implant	2.5 \pm 1.1	.07	2.9 \pm 1.4	.50	2.9 \pm 1.4	2.9 \pm 0.9
Palatal of tooth/implant	2.2 \pm 1.0	.34	2.3 \pm 0.7	.64	2.3 \pm 0.8	2.2 \pm 0.7
Papilla volume (0/1/2/3/4)						
Mesial/distal of implant		0.74/0.5		1.00/0.66		0.52/1.00
No papilla (score 0)	3.6%/3.6%	0%/3.4%	0%/0%	0%/0%	0%/0%	0%/0%
Less than half papilla (score 1)	17.9%/14.3%	13.8%/6.9%	13.8%/3.4%	10.3%/10.3%	10.3%/6.9%	6.9%/6.9%
At least half papilla (score 2)	39.3%/46.4%	37.9%/34.5%	34.5%/37.9%	37.9%/31.0%	41.4%/27.6%	27.6%/24.1%
Entire papilla (score 3)	39.3%/35.7%	48.3%/55.2%	51.7%/58.6%	51.7%/58.6%	48.3%/65.5%	65.5%/69.0%
Hyperplastic papilla (score 4)	0%/0%	0%/0%	0%/0%	0%/0%	0%/0%	0%/0%

Resulting negative values on subtracting the baseline value (T_0) from the T_1 and the T_1 from the T_{12} means recession, positive values mean tissue gain. T_0 , pre-operative; T_1 , one month after final crown placement; T_{12} , 12 months after final crown placement.

TABLE 3 Patient satisfaction regarding general satisfaction, aesthetics and treatment procedure

	Control group (n = 30)	Test group (n = 30)	p-value	Control group (n = 30)	Test group (n = 30)	p-value	Control group (n = 29)	Test group (n = 29)	p-value
	T ₀ (median (IQR))	T ₁ (median (IQR))		T ₁ (median (IQR))	T ₁₂ (median (IQR))		T ₁₂ (median (IQR))		
VAS questions									
How satisfied are you with your current dental situation?	5.5 (3.8–7.0)*	5.3 (3.9–6.8)*	.75	8.3 (7.6–9.2)*	8.5 (7.4–8.9)*	.98	8.1 (6.9–8.8)	8.3 (6.3–9.2)	.77
How satisfied are you with your current dental situation compared to the situation before treatment?				8.5 (7.6–9.1)	8.3 (7.6–9.8)	.80	8.7 (8.1–9.6)	8.7 (6.7–9.6)	.54
How satisfied are you with the implant and the implant crown?				9.2 (8.1–9.8)	9.1 (7.9–9.6)	.70	9.2 (8.2–9.8)	9.3 (7.9–9.9)	.87
Aesthetics									
Colour of the crown				9.5 (8.3–9.9)	9.3 (7.9–10.0)	.88	9.6 (8.6–10.0)	9.4 (7.4–9.9)	.56
Form of the crown				9.3 (8.1–9.0)	9.2 (7.9–9.9)	.86	9.3 (8.4–9.9)	9.4 (8.8–9.9)	.72
Colour of the peri-implant mucosa				9.3 (8.1–9.9)	9.0 (7.3–9.6)	.53	9.5 (8.7–9.8)	9.2 (7.5–9.9)	.50
Form of the peri-implant mucosa				8.9 (7.8–9.8)	9.2 (7.2–9.5)	.94	9.4 (7.7–9.9)	8.9 (7.8–9.5)	.44
Treatment procedure									
I regret that I chose this treatment				0.1 (0.0–0.7)	0.1 (0.0–0.3)	.82	0.2 (0.0–0.7)	0.0 (0.0–0.5)	.41
I would recommend the treatment to other patients				9.7 (8.9–10.0)	9.8 (9.2–10.0)	.57	9.6 (8.5–10.0)	9.8 (9.4–10.0)	.21
Total OHIP score	10.0 (5.3–19.8)*	10.0 (6.0–16.0)*	.98	6.0 (0.8–1.0)*	3.0 (1.0–9.0)*	.55	2.0 (0.0–6.0)*	2.0 (1.0–5.0)*	.60

*p < .00 within-group comparison.

T₀, pre-operative; T₁, one month after final crown placement; T₁₂, twelve months after crown placement.

We did not find a more favourable PES in the connective tissue group, which is in contrast to Migliorati et al. (2015), who found a significantly higher PES in patients receiving a CTG. This might be explained by how the PES is constructed, using five different categorical variables, of which the level of the mid-buccal peri-implant mucosa in relation to the contra-lateral tooth is one. A variable is allocated the highest score of 2 when the mucosal level is identical to that of the contra-lateral tooth. A slight difference in mucosal level is judged with a score of 1, whereas a 1 mm or more discrepancy in mucosal level is given no points. Migliorati et al. (2015) only included cases in which the MBML of the failing tooth was at the same level as the contra-lateral tooth, thus having a baseline score of 2 on the MBML item. Finding and scoring a greater recession in cases where no tissue graft was applied probably had significant consequences on this item's score, and thereby the total PES. In our study, however, cases with a recession at baseline were also included, thus those with a score of 1 or 0. Even when the application of a soft tissue graft resulted in a gain of soft tissue, there may still remain a discrepancy in mucosal level in cases with a pre-operative recession, thus not leading to a higher postoperative PES compared to the group in which no graft was applied.

In our study, gingival biotype did not appear to be a predisposing factor for a change in MBML, irrespective of whether a CTG was used or not. Hence, contrary to Levine et al. (2014), the risk of advanced recession in patients with a thin biotype might not be high. This is in line with the Kan et al. (2009) consecutive study which reported successful maintenance of the MBML with CT grafting irrespective of the initial gingival biotype after a mean follow-up period of 2 years. It was also proposed that thickening of the mucosa could limit the degree of recession (Lee et al., 2016; Lin et al., 2014). Migliorati et al. (2015) confirmed the presumed beneficial effect of applying a CTG on the MBML in patients with a thin biotype, but excluded, in contrast to our study, patients with a discrepancy in MBML to the contra-lateral tooth. Our study's sample size might have been too small to detect the effect of gingival biotype on the effect of CT grafting in non-selected patients, but the difference observed by Migliorati et al. (2015) might also have been a coincidence. Another complexing factor with regard to assessing the true effect of the gingival biotype factor is the variety of methods applied to distinguish thick versus thin biotypes (Cabello, Rioboo, & Fabrega, 2013; Frost, Mealey, Jones, & Huynh-Ba, 2015). This variety in scoring methods compromises a valid comparison of the results of the various studies.

We consider that other factors, than gingival biotype, are more important for the final outcome, such as implant positioning. Placement of an implant too far to the buccal has been associated with more pronounced recession of the mid-buccal mucosa (Chen & Buser, 2014; Cosyn, Hooghe, & De Bruyn, 2012; Evans & Chen, 2008; Zuiderveld et al., 2014). We hypothesize that when the implant is placed along the palatal wall of the extraction socket and the implant-socket gap is grafted, as proposed in the literature (Lin et al., 2014; Merheb et al., 2014), the influence of gingival biotype is of secondary importance. This is because a sufficient amount of buccal bone thickness is achieved to support the peri-implant soft tissues. However, implant positioning was beyond the scope of our

study. Therefore, we advise future studies should measure the buccal bone thickness in time using cone beam computed tomography (CBCT) to assess the influence of buccal bone thickness on the amount of recession on the mid-buccal aspect. Benic et al. (2012) reported that the absence of buccal bone on CBCT images was associated with more recession of the mid-buccal mucosa compared to implants with an intact buccal bone wall.

We noted an implant survival of 96.7%, irrespective of using a CTG, which is comparable to survival rates reported in the literature (Del Fabbro et al., 2015; Slagter et al., 2014). With regard to IML, we found a comparable negligible recession in both groups. These results are also in line with the published literature on immediately placed and provisionalized implants (Lang, Pun, Lau, Li, & Wong, 2012; Slagter et al., 2014). The results of the marginal bone levels in our study are also in line with the other literature (Lang et al., 2012; Slagter et al., 2014). The systematic review by Slagter et al. (2014), however, mentioned a significant association between the placement of a CTG and a change in marginal bone level. This observation was not confirmed in our study with comparable results in both groups.

With respect to the effect of both treatments on patient satisfaction, all the patients were equally satisfied.

A shortcoming of this study is the relatively short follow-up of 1 year after placement of the final implant crown. A longer follow-up would provide valuable information about whether MBMLs remain stable over time. Changes in peri-implant soft tissue levels are likely to continue after 1 year, as the recent literature showed more pronounced soft tissue recession in a 5-year follow-up (Cosyn et al., 2016).

5 | CONCLUSION

This study shows that connective tissue grafting combined with single, immediately placed and provisionalized, implants, irrespective of the gingival biotype, leads to less mid-buccal mucosa recession. However, a connective tissue graft apparently had no beneficial effect regarding aesthetics, soft tissue health and patient satisfaction.

ACKNOWLEDGEMENTS

The authors thank Cees Stellingsma (C.S.) and Menno van der Veen (M.v.d.V.) for their assistance in fabricating the provisional and final implant crowns.

CONFLICT OF INTEREST

The authors declare that there is no conflict of interests in this study.

REFERENCES

Albrektsson, T., Zarb, G., Worthington, P., & Eriksson, A. R. (1986). The long-term efficacy of currently used dental implants: A review and proposed

- criteria of success. *The International Journal of Oral & Maxillofacial Implants*, 1, 11–25.
- Araujo, M. G., Sukekava, F., Wennstrom, J. L., & Lindhe, J. (2006). Tissue modeling following implant placement in fresh extraction sockets. *Clinical Oral Implants Research*, 17, 615–624.
- Belser, U. C., Grutter, L., Vailati, F., Bornstein, M. M., Weber, H. P., & Buser, D. (2009). Outcome evaluation of early placed maxillary anterior single-tooth implants using objective esthetic criteria: A cross-sectional, retrospective study in 45 patients with a 2- to 4-year follow-up using pink and white esthetic scores. *Journal of Periodontology*, 80, 140–151.
- Benic, G. I., Mokti, M., Chen, C. J., Weber, H. P., Hammerle, C. H., & Gallucci, G. O. (2012). Dimensions of buccal bone and mucosa at immediately placed implants after 7 years: A clinical and cone beam computed tomography study. *Clinical Oral Implants Research*, 23, 560–566.
- Cabello, G., Rioboo, M., & Fabrega, J. G. (2013). Immediate placement and restoration of implants in the aesthetic zone with a trimodal approach: Soft tissue alterations and its relation to gingival biotype. *Clinical Oral Implants Research*, 24, 1094–1100.
- Cardaropoli, D., Tamagnone, L., Roffredo, A., & Gaveglio, L. (2015). Soft tissue contour changes at immediate postextraction single-tooth implants with immediate restoration: A 12-month prospective cohort study. *The International Journal of Periodontics & Restorative Dentistry*, 35, 191–198.
- Chen, S. T., & Buser, D. (2014). Esthetic outcomes following immediate and early implant placement in the anterior maxilla—a systematic review. *The International Journal of Oral & Maxillofacial Implants*, 29(Suppl), 186–215.
- Chung, S., Rungcharassaeng, K., Kan, J. Y., Roe, P., & Lozada, J. L. (2011). Immediate single tooth replacement with subepithelial connective tissue graft using platform switching implants: A case series. *The Journal of Oral Implantology*, 37, 559–569.
- Cosyn, J., Eghbali, A., Hermans, A., Vervaeke, S., De Bruyn, H., & Cleymaet, R. (2016). A 5-year prospective study on single immediate implants in the aesthetic zone. *Journal of Clinical Periodontology*, 43, 702–709.
- Cosyn, J., Hooghe, N., & De Bruyn, H. (2012). A systematic review on the frequency of advanced recession following single immediate implant treatment. *Journal of Clinical Periodontology*, 39, 582–589.
- Del Fabbro, M., Ceresoli, V., Taschieri, S., Ceci, C., & Testori, T. (2015). Immediate loading of postextraction implants in the esthetic area: Systematic review of the literature. *Clinical Implant Dentistry and Related Research*, 17, 52–70.
- Evans, C. D., & Chen, S. T. (2008). Esthetic outcomes of immediate implant placements. *Clinical Oral Implants Research*, 19, 73–80.
- Faul, F., Erdfelder, E., Buchner, A., & Lang, A. G. (2009). Statistical power analyses using G*Power 3.1: Tests for correlation and regression analyses. *Behavior Research Methods*, 41, 1149–1160.
- Frost, N. A., Mealey, B. L., Jones, A. A., & Huynh-Ba, G. (2015). Periodontal Biotype: Gingival Thickness as It Relates to Probe Visibility and Buccal Plate Thickness. *Journal of Periodontology*, 86, 1141–1149.
- Jemt, T. (1997). Regeneration of gingival papillae after single-implant treatment. *The International Journal of Periodontics & Restorative Dentistry*, 17, 326–333.
- Kan, J. Y., Morimoto, T., Rungcharassaeng, K., Roe, P., & Smith, D. H. (2010). Gingival biotype assessment in the esthetic zone: Visual versus direct measurement. *The International Journal of Periodontics & Restorative Dentistry*, 30, 237–243.
- Kan, J. Y., Rungcharassaeng, K., & Lozada, J. L. (2005). Bilaminar subepithelial connective tissue grafts for immediate implant placement and provisionalization in the esthetic zone. *Journal of the California Dental Association*, 33, 865–871.
- Kan, J. Y., Rungcharassaeng, K., Morimoto, T., & Lozada, J. (2009). Facial gingival tissue stability after connective tissue graft with single immediate tooth replacement in the esthetic zone: Consecutive case report. *Journal of Oral and Maxillofacial Surgery: Official Journal of the American Association of Oral and Maxillofacial Surgeons*, 67, 40–48.
- Khzam, N., Arora, H., Kim, P., Fisher, A., Mattheos, N., & Ivanovski, S. (2015). Systematic Review of Soft Tissue Alterations and Esthetic Outcomes Following Immediate Implant Placement and Restoration of Single Implants in the Anterior Maxilla. *Journal of Periodontology*, 86, 1321–1330.
- Koleran, R., Nissan, J., Mijiritsky, E., Hamoudi, N., Mangano, C., & Tal, H. (2016). Esthetic assessment of immediately restored implants combined with GBR and free connective tissue graft. *Clinical Oral Implants Research*, 27, 1414–1422.
- Lang, N. P., Pun, L., Lau, K. Y., Li, K. Y., & Wong, M. C. (2012). A systematic review on survival and success rates of implants placed immediately into fresh extraction sockets after at least 1 year. *Clinical Oral Implants Research*, 23(Suppl 5), 39–66.
- Lee, C. T., Tao, C. Y., & Stoupe, J. (2016). The Effect of Subepithelial Connective Tissue Graft Placement on Esthetic Outcomes After Immediate Implant Placement: Systematic Review. *Journal of Periodontology*, 87, 156–167.
- Levine, R. A., Huynh-Ba, G., & Cochran, D. L. (2014). Soft tissue augmentation procedures for mucogingival defects in esthetic sites. *The International Journal of Oral & Maxillofacial Implants*, 29(Suppl), 155–185.
- Lin, G. H., Chan, H. L., & Wang, H. L. (2014). Effects of currently available surgical and restorative interventions on reducing midfacial mucosal recession of immediately placed single-tooth implants: A systematic review. *Journal of Periodontology*, 85, 92–102.
- Loe, H. (1967). The Gingival Index, the Plaque Index and the Retention Index Systems. *Journal of Periodontology*, 38(Suppl), 610–616.
- Meijndert, L., Meijer, H. J., Raghoobar, G. M., & Vissink, A. (2004). A technique for standardized evaluation of soft and hard peri-implant tissues in partially edentulous patients. *Journal of Periodontology*, 75, 646–651.
- Merheb, J., Quirynen, M., & Teughels, W. (2014). Critical buccal bone dimensions along implants. *Periodontology 2000*, 66, 97–105.
- van der Meulen, M. J., John, M. T., Naeije, M., & Lobbezoo, F. (2012). Developing abbreviated OHIP versions for use with TMD patients. *Journal of Oral Rehabilitation*, 39, 18–27.
- Migliorati, M., Amorfini, L., Signori, A., Biavati, A. S., & Benedicenti, S. (2015). Clinical and Aesthetic Outcome with Post-Extractive Implants with or without Soft Tissue Augmentation: A 2-Year Randomized Clinical Trial. *Clinical Implant Dentistry and Related Research*, 17, 983–995.
- Mombelli, A., van Oosten, M. A., Schurch, E. Jr, & Land, N. P. (1987). The microbiota associated with successful or failing osseointegrated titanium implants. *Oral Microbiology and Immunology*, 2, 145–151.
- Morton, D., & Pollini, A. (2017). Evolution of loading protocols in implant dentistry for partially dentate arches. *Periodontology 2000*, 73, 152–177.
- Rungcharassaeng, K., Kan, J. Y., Yoshino, S., Morimoto, T., & Zimmerman, G. (2012). Immediate implant placement and provisionalization with and without a connective tissue graft: An analysis of facial gingival tissue thickness. *The International Journal of Periodontics & Restorative Dentistry*, 32, 657–663.
- Slagter, K. W., den Hartog, L., Bakker, N. A., Vissink, A., Meijer, H. J., & Raghoobar, G. M. (2014). Immediate placement of dental implants in the esthetic zone: A systematic review and pooled analysis. *Journal of Periodontology*, 85, e241–e250.
- Slagter, K. W., Meijer, H. J., Bakker, N. A., Vissink, A., & Raghoobar, G. M. (2015). Feasibility of immediate placement of single-tooth implants in the aesthetic zone: A 1-year randomized controlled trial. *Journal of clinical periodontology*, 42, 773–782.
- Smeets, E. C., de Jong, K. J., & Abraham-Inpijn, L. (1998). Detecting the medically compromised patient in dentistry by means of the medical risk-related history. A survey of 29,424 dental patients in The Netherlands. *Preventive Medicine*, 27, 530–535.
- Tonetti, M. S., Cortellini, P., Graziani, F., Cairo, F., Lang, N. P., Abundo, R., ... Wetzell, A. (2017). Immediate versus delayed implant placement after anterior single tooth extraction: The timing randomized controlled clinical trial. *Journal of Clinical Periodontology*, 44, 215–224.

- Tsuda, H., Rungcharassaeng, K., Kan, J. Y., Roe, P., Lozada, J. L., & Zimmerman, G. (2011). Peri-implant tissue response following connective tissue and bone grafting in conjunction with immediate single-tooth replacement in the esthetic zone: A case series. *The International Journal of Oral & Maxillofacial Implants*, 26, 427–436.
- Vignoletti, F., Discepoli, N., Muller, A., de Sanctis, M., Munoz, F., & Sanz, M. (2012). Bone modelling at fresh extraction sockets: Immediate implant placement versus spontaneous healing: An experimental study in the beagle dog. *Journal of Clinical Periodontology*, 39, 91–97.
- Yoshino, S., Kan, J. Y., Rungcharassaeng, K., Roe, P., & Lozada, J. L. (2014). Effects of connective tissue grafting on the facial gingival level following single immediate implant placement and provisionalization in the esthetic zone: A 1-year randomized controlled prospective study. *The International Journal of Oral & Maxillofacial Implants*, 29, 432–440.
- Zuiderveld, E. G., den Hartog, L., Vissink, A., Raghoobar, G. M., & Meijer, H. J. (2014). Significance of buccopalatal implant position, biotype, platform switching, and pre-implant bone augmentation on the level

of the midbuccal mucosa. *The International journal of prosthodontics*, 27, 477–479.

SUPPORTING INFORMATION

Additional Supporting Information may be found online in the supporting information tab for this article.

How to cite this article: Zuiderveld EG, Meijer HJA, den Hartog L, Vissink A, Raghoobar GM. Effect of connective tissue grafting on peri-implant tissue in single immediate implant sites: A RCT. *J Clin Periodontol*. 2018;45:253–264.
<https://doi.org/10.1111/jcpe.12820>