

University of Groningen

Extreme delta brushes in anti NMDA receptor encephalitis - Muscle artefact or an EEG phenomenon?

van der Meulen, Anna A E; van der Hoeven, Johannes H; de Jong, Bauke M; Elting, Jan Willem J

Published in:
Clinical Neurophysiology

DOI:
[10.1016/j.clinph.2017.06.256](https://doi.org/10.1016/j.clinph.2017.06.256)

IMPORTANT NOTE: You are advised to consult the publisher's version (publisher's PDF) if you wish to cite from it. Please check the document version below.

Document Version
Publisher's PDF, also known as Version of record

Publication date:
2017

[Link to publication in University of Groningen/UMCG research database](#)

Citation for published version (APA):

van der Meulen, A. A. E., van der Hoeven, J. H., de Jong, B. M., & Elting, J. W. J. (2017). Extreme delta brushes in anti NMDA receptor encephalitis - Muscle artefact or an EEG phenomenon? A case report. *Clinical Neurophysiology*, 128(10), 1835-1836. <https://doi.org/10.1016/j.clinph.2017.06.256>

Copyright


Other than for strictly personal use, it is not permitted to download or to forward/distribute the text or part of it without the consent of the author(s) and/or copyright holder(s), unless the work is under an open content license (like Creative Commons).

The publication may also be distributed here under the terms of Article 25fa of the Dutch Copyright Act, indicated by the "Taverne" license. More information can be found on the University of Groningen website: <https://www.rug.nl/library/open-access/self-archiving-pure/taverne-amendment>.

Take-down policy

If you believe that this document breaches copyright please contact us providing details, and we will remove access to the work immediately and investigate your claim.

Downloaded from the University of Groningen/UMCG research database (Pure): <http://www.rug.nl/research/portal>. For technical reasons the number of authors shown on this cover page is limited to 10 maximum.



Letter to the Editor

Extreme delta brushes in anti NMDA receptor encephalitis – Muscle artefact or an EEG phenomenon? A case report



Extreme delta brushes have been described as an unique electroencephalographic (EEG) phenomenon in anti-NMDA receptor (anti-NMDA-R) encephalitis (Schmitt et al., 2012; da Silva-Junior et al., 2014; Veciana et al., 2015).

We present a patient with proven anti-NMDA-R encephalitis with long-term EEG monitoring. Additional electromyographic (EMG) co-registration demonstrated that extreme delta brushes resulted from superposition of frontalis muscle EMG signal on rhythmic delta activity.

Case description: A 42-year-old woman with a history of sleep apnea syndrome presented with confusion, hallucinations, cognitive impairment and facial dyskinesias combined with fever, headache, diarrhea and vomiting. Infectious (viral) encephalitis was excluded, while positive anti-NMDA-R antibodies in serum and CSF confirmed the diagnosis auto-immune encephalitis. MRI showed FLAIR hyperintensity in the insular and mesiotemporal cortex, bilaterally, and in the anterior cingulate. The development of generalized seizures required intubation and temporary sedation. The following Glasgow Coma Scale (GCS) score was E1M5V-tube and stereotypical movements of the hands were seen.

The first EEG registration (day 13) showed diffuse rhythmic frontal delta activity (encephalopathic pattern). Despite treatment with 1000 mg/day methylprednisone (day 13–17), and intravenous immunoglobins 0.4 g/kg/day (day 20–24) the rhythmic delta activity persisted (day 27).

A clinically visible movement pattern consisted of left hand jerks, repetitive chin movements, pursing of the lips and blinking, which could occur simultaneously or independently with the delta activity in the EEG. Status epilepticus was assumed for which AEDs were started: sodium valproate (max 50 mg/kg/day), phenytoin (20 mg/kg startup dose) and levetiracetam (max 60 mg/kg/day) combined with high dose (max 18 mg/h) intravenous midazolam. As the rhythmic frontal delta activity persisted, thiopental (max 9 mg/kg) was given inducing a coma with burst suppression EEG pattern for 48 hours (day 35–37). After this period, the rhythmic delta activity reappeared. EEG with video and surface EMG coregistration of the orbicularis oculi and frontalis muscles during an episode of orofacial movements showed a delta brush pattern (Fig. 1A). Video and EMG recordings revealed that the orbicularis oculi and frontalis muscle contractions were also rhythmic in nature, with the same frequency, but mostly asynchronous and in anti-phase, of which the frontalis EMG activity was in-phase with the brush component of the delta pattern. From the combined video and EMG recordings we concluded that the brush component of the delta brush most likely represented frontalis muscle activity during the orofacial movements. Moreover, although neu-

romuscular blocking agents were not administered, the occurrence of delta activity without brushes in the circumstance without rhythmic frontalis muscle EMG activity, strongly supports the muscular origin of the brushes (Fig. 1B).

The subsequent course of disease included identification of an abdominal teratoma followed by removal of both adnexes (day 40), treatment with plasmapheresis (day 43–46), rituximab (4 weeks 375 mg/m² weekly) and cyclophosphamide (6 months 750 mg/m² every month) (from day 48). Clinical improvement became evident around day 55 (E4M6V4) with initial persistence of hallucinations and paranoia. After six months of cognitive rehabilitation, improvements enabled the patient to return home.

Discussion

While extreme delta brushes have been recently described as an unique EEG phenomenon in anti NMDA-R encephalitis (Schmitt et al 2012; da Silva-Junior et al 2014; Veciana et al 2015) we propose that the “brush” may alternatively represent an EMG artifact due to rhythmic contractions of the frontalis muscle, occurring in synchrony with frontal delta activity. The alternating contractions of the frontalis and orbicularis oculi muscles, synchronously with the EEG delta activity, suggests that both phenomena may arise from a common generator mechanism, probably involving subcortical structures. The alternating muscle activations also argues against a (cortical) epileptic origin of the oro-lingual-facial movements. Instead, they could be interpreted a subcortical release phenomenon arising as a consequence of a severely disturbed arousal system. Although this casts doubt on whether the rhythmic delta activity indeed reflects a status epilepticus, the single case observation of persistent delta brushes after neuromuscular paralysis (Schmitt et al 2012) and case report of delta brushes without correlation with orofacial dyskinesias (Shi 2016) argue in favor of an epileptic origin. We acknowledge that a final proof of the relation between the brushes and muscular activity by neuromuscular blocking agents was not performed in our patient. On the other hand, the frequent presence of oro-lingual-facial dyskinesias in anti-NMDA-R encephalitis (Dalmau et al 2011), which may occur both clinically and subclinically as demonstrated in our patient, underscores the plausibility of muscle activity generating the brushes, particularly as the brushes disappeared in the absence of EMG activity. This consideration is particularly urgent because previous publications did not report additional EMG co-registration to the EEG. Therefore, since the rhythmic frontalis muscle contractions were not always clinically visible in our patient, we emphasize that for assigning extreme delta brushes as an EEG pattern, EMG co-registration is required to exclude an EMG ‘artifact’. Studies with EEG-EMG co-registration and administration of a neuromuscular blocking agent are useful to investigate the nature of extreme delta brushes.

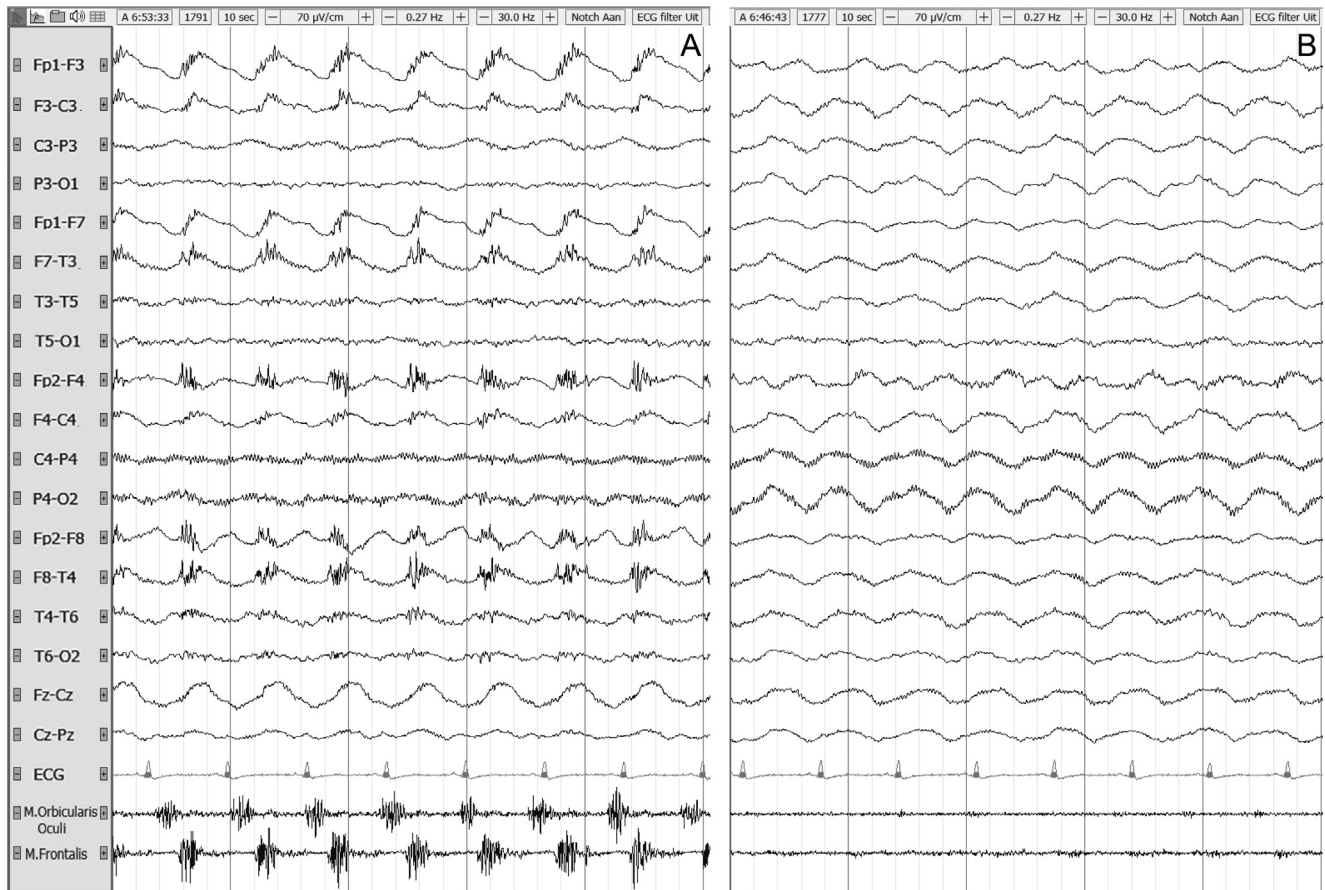

Fig. 1. EEG with video and orbicularis oculi and frontalis muscle EMG coregistration during a five second episode of orofacial dyskinesias showing a delta brush pattern (A). The M. frontalis EMG channel was derived from the frontopolar EEG electrodes. EMG activity of the orbicularis oculi and facial videorecording including the frontalis muscles was rhythmic with the same frequency, with contraction of these muscles that were mostly asynchronous and in anti-phase, and of which the frontalis muscle activity coincided with the brush component of the delta brushes. During a five second episode without EMG activity, the delta brushes are absent (B).

Conflict of interest

None of the authors have potential conflicts of interest to be disclosed.

This study was not sponsored.

References

- Dalmau J, Lancaster E, Martinez-hernandez E, Rosenfeld MR, Balice-Gordon R. Clinical experience and laboratory investigations in patients with anti-NMDAR encephalitis. *Lancet Neurol* 2011;10:63–74. [http://dx.doi.org/10.1016/S1474-4422\(10\)70253-2](http://dx.doi.org/10.1016/S1474-4422(10)70253-2).
- da Silva-Junior FP, Castro LH, Andrade JQ, Bastos CG, Moreire CH, Valerio RM, et al. Serial and prolonged EEG monitoring in anti-N-Methyl-d-Aspartate receptor encephalitis. *Clin Neurophysiol* 2014;125:1541–4. <http://dx.doi.org/10.1016/j.clinph.2014.01.001>.
- Schmitt SE, Pargeon K, Frechette ES, Hirsch LJ, Dalmau J, Friedman D. A unique EEG pattern in adults with anti-NMDA receptor encephalitis. *Neurology* 2012;79:1094–100. <http://dx.doi.org/10.1212/WNL.0b013e3182698cd8>.
- Shi Y. Serial EEG monitoring in a patient with Anti-NMDA Receptor Encephalitis. *Clin EEG Neurosci* 2016;1–3. <http://dx.doi.org/10.1177/1550059416677398>.
- Veciana M, Becerra JL, Fossas P, Muriana D, Sansa G, Santamaina E, et al. EEG extreme delta brush: an ictal pattern in patients with anti-NMDA receptor encephalitis. *Epilepsy Behav* 2015;49:280–5. <http://dx.doi.org/10.1016/j.yebeh.2015.04.032>.

Anna A.E. van der Meulen*
Johannes H. van der Hoeven
Bauke M. de Jong
Jan Willem J Elting

Department of Neurology, University Medical Center Groningen,
University of Groningen, The Netherlands

* Corresponding author at: Department of Neurology, University
Medical Center Groningen, University of Groningen, Hanzplein 1,
9713 GZ Groningen, The Netherlands.

E-mail addresses: a.a.e.van.der.meulen@umcg.nl (A.A.E. van der Meulen), j.h.van.der.hoeven@umcg.nl (J.H. van der Hoeven), b.m.de.jong@umcg.nl (B.M. de Jong), j.w.j.elting@umcg.nl (J.W.J. Elting)

Available online 17 July 2017