

University of Groningen

## Neuroanatomical changes in patients with loss of visual function

Prins, Doety

**IMPORTANT NOTE: You are advised to consult the publisher's version (publisher's PDF) if you wish to cite from it. Please check the document version below.**

*Document Version*

Publisher's PDF, also known as Version of record

*Publication date:*  
2016

[Link to publication in University of Groningen/UMCG research database](#)

*Citation for published version (APA):*

Prins, D. (2016). *Neuroanatomical changes in patients with loss of visual function*. [Thesis fully internal (DIV), University of Groningen]. Rijksuniversiteit Groningen.

**Copyright**

Other than for strictly personal use, it is not permitted to download or to forward/distribute the text or part of it without the consent of the author(s) and/or copyright holder(s), unless the work is under an open content license (like Creative Commons).

The publication may also be distributed here under the terms of Article 25fa of the Dutch Copyright Act, indicated by the "Taverne" license. More information can be found on the University of Groningen website: <https://www.rug.nl/library/open-access/self-archiving-pure/taverne-amendment>.

**Take-down policy**

If you believe that this document breaches copyright please contact us providing details, and we will remove access to the work immediately and investigate your claim.

*Downloaded from the University of Groningen/UMCG research database (Pure): <http://www.rug.nl/research/portal>. For technical reasons the number of authors shown on this cover page is limited to 10 maximum.*

# **NEUROANATOMICAL CHANGES IN PATIENTS WITH LOSS OF VISUAL FUNCTION**

Doety Prins

The research described in this thesis was supported by the MD/PhD programme of the Junior Scientific Masterclass, and by a research grant from Stichting Nederlands Oogheelkundig Onderzoek (SNOO).

Publication of this thesis was financially supported by the Graduate School for Behavioral and Cognitive Neurosciences, the University of Groningen, and the Professor Mulder Stichting.

Layout: Douwe Oppewal, [www.oppewal.nl](http://www.oppewal.nl)

Printing: Netzdruk

ISBN printed version: 978-90-367-9330-8

ISBN digital version: 978-90-367-9329-2

© 2016 D. Prins

All rights reserved. No part of this publication may be reproduced, stored in a retrieval system, or transmitted in any form or by any means without permission of the author.



rijksuniversiteit  
groningen

# Neuroanatomical changes in patients with loss of visual function

## Proefschrift

ter verkrijging van de graad van doctor aan de  
Rijksuniversiteit Groningen  
op gezag van de  
rector magnificus prof. dr. E. Sterken  
en volgens besluit van het College voor Promoties

De openbare verdediging zal plaatsvinden op

woensdag 23 november 2016 om 12:45 uur

door

**Doety Prins**

geboren op 24 oktober 1986  
te Sneek

**Promotores**

Prof. dr. F.W. Cornelissen

Prof. dr. J.M.M. Hooymans

Prof. dr. N.M. Jansonius

**Beoordelingscommissie**

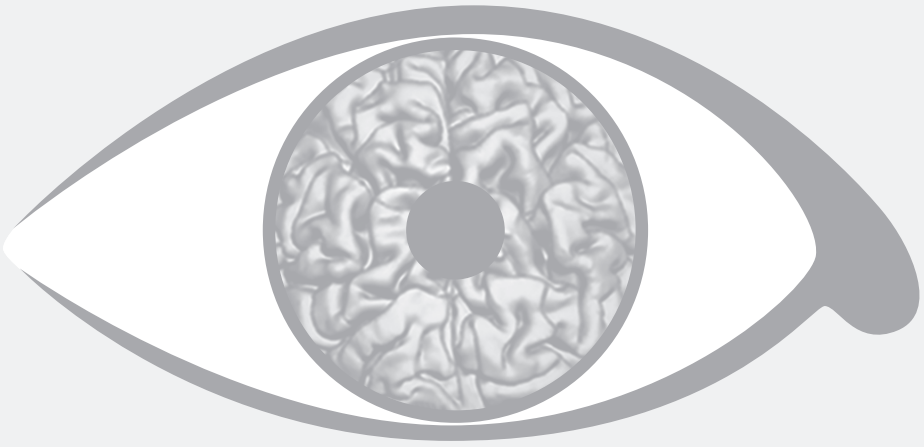
Prof. dr. P. van Dijk

Prof. dr. A.V. van den Berg

Prof. dr. T. van Laar

# Contents

Introduction of the thesis	7
1. General introduction of the topic and review of the literature <i>Published in Acta Ophthalmologica, 2016</i>	13
2. Morphometric analyses of the visual pathways in macular degeneration <i>Published in Cortex, 2014</i>	25
3. Surface-based analyses of the anatomical properties of the visual cortex in macular degeneration <i>Published in Plos One, 2016</i>	45
4. Loss of binocular vision in monocularly blind patients causes selective degeneration of the superior lateral occipital cortices <i>Submitted</i>	61
5. Neuroanatomical changes of the visual pathways in patients with amonocular visual field defect due to primary open angle glaucoma <i>Submitted</i>	77
6. General discussion of the topic <i>Published in Acta Ophthalmologica, 2016</i>	91
Conclusions	99
References	103
Summary	125
Nederlandse samenvatting	129
Dankwoord	133
Curriculum vitae	137



# Introduction of the thesis



## **Introduction of the thesis**

Vision is one of the most important senses for human beings. The eye gives us a detailed perception of the world around us. We use it continuously in our daily activities. Loss of visual function can therefore cause a substantial decrease in quality of life. Light emitted by a light source or reflected by a surface enters the eye through the cornea, which refracts the light through the pupil to the lens, which in turns refracts the light through the vitreous body, to project it onto the retina. The light projected onto the retina is converted into electrical signals by the photoreceptors and further processed in the various layers of the retina. From the retina, electrical pulses pass on to the optic nerve, which transports the signal further along the visual pathways. At the optic chiasm, the optic nerves split. The nerve fibres from the right half of the retina of both eyes, which contain information from the left visual field, continue on to the right hemisphere of the brain, whereas the fibres from the left half of the retina of both eyes continue on to the left hemisphere. From the chiasm, the visual information is transferred through the optic tract to the lateral geniculate bodies, from which the optic radiations transport the signal to the visual cortex, in which the input is processed resulting in us perceiving a certain object.

### ***Association between ocular pathology and neuroanatomical changes***

In the last decade, numerous studies have found an association between eye diseases and changes in the neuroanatomical properties of the visual pathways. This has most often been studied in eye diseases that cause a loss of visual input as a consequence of visual field defects, such as macular degeneration and glaucoma. Why are these findings important? And are the outcomes of these studies clinically relevant for patients suffering from these eye diseases?

A topic of high interest in ophthalmology is the treatment of blindness through vision restoration. Over the past two decades, developments in the fields of genetics, stem-cell therapy and retinal prosthesis have accelerated, such that treatment of blindness may become a reality in the relatively near future for at least some types of ocular pathology. In the context of these developments, it is important to gain knowledge about the chances of success of such vision restoration treatments, and to determine which factors affect their success. One of these factors might be the remaining capability of the visual pathways and the central visual system to guide the visual information from the eye towards the visual cortex and process it appropriately. Without a properly functioning central visual system, one cannot accurately perceive the visual information, even though the visual input might still be intact or might have been restored. Therefore, it is important to investigate what happens in the central visual system in eye diseases that can cause – partial – blindness. Furthermore, such research can provide more insight in the pathophysiology of the investigated eye disease. This, in turn, can give directions to

future research on the treatment of the eye disease (e.g. moving from treatment of the eye alone towards treatment of both the eye and brain).

There are several factors that can explain the association between ocular pathology and neuroanatomical changes:

- Functional deprivation: the ocular pathology may reduce the activity in the visual pathways – for example as a result of overlapping visual field defects in both eyes – which, in turn, may lead to neuroanatomical changes;
- Anterograde transsynaptic degeneration. This process might cause neuroanatomical changes by “passing on” the pregeniculate degeneration of axons from the eye towards postgeniculate neurons and even to the visual cortex.
- Ocular pathology, such as glaucoma and macular degeneration, could be part of a more generalized neurodegenerative disorder that affects the brain as well as the eye.

## **Aim of the thesis**

The aim of my thesis was to discover which of the above described mechanisms can explain the association between ocular pathology and neuroanatomical changes in general. To achieve this aim, I addressed a number of sub-questions:

- *Is macular degeneration associated with neuroanatomical alterations? (Chapter 2 and 3)*  
 Juvenile macular degeneration (JMD) and age-related macular degeneration (AMD) are degenerative retinal diseases that cause central visual field defects. The retinotopic organisation of the visual cortex, i.e. the projection of the visual field onto the visual cortex is well known. Specifically, the centre of the visual field is located in the occipital pole. Therefore, in macular degeneration, the expected locations of neuroanatomical changes that would result from functional deprivation or transsynaptic degeneration are also in the occipital pole. Degeneration beyond these expected locations would suggest an influence of more general neurodegenerative processes.

- *Is monocular blindness associated with neuroanatomical alterations? (Chapter 4)*  
 Monocular blindness due to, for example, a trauma, in the absence of a degenerative ocular disease, constitutes a unique model in which the loss of visual input is well-defined and in which stereopsis is lost. All other visual functions are still supported by input from the contralateral eye. Moreover, as there is no further pathology, we can exclude that general neurodegenerative processes affect the visual pathways and brain. The presence of neuroanatomical changes in monocular blindness can therefore provide insight in whether these are caused by functional deprivation or transsynaptic degeneration.

- *Is primary open-angle glaucoma with a monocular visual field defect associated with neuroanatomical alterations? (Chapter 5)*

Primary open-angle glaucoma (POAG) with a monocular visual field defect combines the consequences of suffering from a degenerative ocular disease with partial loss of visual input from one eye. In this specific group, functional deprivation is not expected to play a role as visual functions are still fully supported by the intact visual input from the contralateral eye and stereopsis is mostly preserved. The presence of neuroanatomical changes might therefore reveal whether these are caused by transsynaptic degeneration or by more general neurodegenerative processes affecting the visual pathways and brain.

## Outline of the thesis

**Chapter 1** introduces the topic of this thesis in depth. It contains a review of the currently existing literature on this topic. It gives an overview of the findings of structural brain MRI-studies in patients with compromised visual acuity and/or a visual field defect, due to glaucoma, AMD, hereditary retinal dystrophies, albinism or amblyopia. This chapter also addresses the question of the causality of the structural changes in the brain in patients suffering from one of the aforementioned diseases.

**Chapter 2** describes an international multi-centre VBM-study in AMD and JMD patients, addressing the question whether these pathologies are associated with volumetric alterations of the visual pathways.

**Chapter 3** is a follow-up on the study described in chapter 2, which additionally uses SBM-analysis to study cortical thickness, surface area and mean curvature in AMD and JMD patients.

**Chapter 4** addresses the question whether monocular blindness affects neuroanatomical properties of the visual pathways. The neuroanatomical properties were defined by grey and white matter volume, cortical thickness, surface area and mean curvature.

In **Chapter 5**, I assess the neuroanatomical properties of the visual pathways of POAG patients with a monocular visual field defect. I compared these patients to age-matched healthy controls and age-matched monocularly blind controls.

**Chapter 6** integrates the results of the experimental chapters of this thesis into a broader general discussion of structural brain MRI-studies in ocular pathology. I discuss the outcomes of these studies and present the most parsimonious theory that can explain the association between ocular pathology and neuroanatomical changes in general. Furthermore, I discuss the clinical relevance of these brain MRI-studies in eye diseases in the context of future vision restorative therapies and suggest directions for future research in the field.

***Structural brain magnetic resonance imaging (MRI) analysis***

The research questions of this thesis were addressed using structural MRI of the brain. In structural MRI, one can measure neuroanatomical properties of a subject's brain, such as grey and white matter volume, surface area, cortical thickness and mean curvature. To determine whether these neuroanatomical properties statistically differ one has to compare these between various groups of subjects – for example a group of patients and a group of healthy controls. There are several techniques that can be used to extract and compare the neuroanatomical properties from the structural MRI images. The volumes of the grey and white matter can be determined using voxel-based morphometry (VBM). Cortical thickness, gyrification pattern and surface area of the cortex can be determined using surface-based morphometry (SBM).

***Voxel-based morphometry (VBM)***

VBM is a method that compares structural MR-images in a voxel-by-voxel manner. A voxel is the 3D equivalent of a pixel, and can have different dimensions. In this thesis, the size of a voxel is 1 mm x 1 mm x 1 mm. VBM overlays a grid of these voxels over the brain, and thus divides the brain into tiny cubes. After separating the brain structures in the image from all non-brain tissue, the brain is segmented into grey matter, white matter and cerebrospinal fluid. The likelihood that the tissue represented by a voxel belongs to one of these tissue classes is determined by assessing the intensity of a voxel. This results in the three tissue segments. Next, the segments of the individual brains are registered to an average template brain to make them approximately equal in size. Subsequently, a comparison of the grey and white matter volumes can be performed between patients and controls. This can be done for the entire brain (whole brain analysis) or be limited to specific regions of interest (ROI) analysis.

***Surface-based morphometry (SBM)***

SBM is a technique that determines several neuroanatomical properties based on estimating the grey/white matter boundary and the grey/pial boundary. SBM can use these estimates to measure the thickness of the cortex, the gyrification pattern and the surface area of the cortex. SBM first removes the non-brain tissue, performs intensity normalisation and segments the brain into grey and white matter. It registers all the individual cortices to a sphere and inflates them for visualization purposes. After these steps, comparison of the neuroanatomical properties can be performed for the whole brain or in particular ROIs. SBM is limited to analysing properties of the cortex only.

