

University of Groningen

Balance between herpes viruses and immunosuppression after lung transplantation

Verschuuren, Erik Alfons Maria

IMPORTANT NOTE: You are advised to consult the publisher's version (publisher's PDF) if you wish to cite from it. Please check the document version below.

Document Version

Publisher's PDF, also known as Version of record

Publication date:

2006

[Link to publication in University of Groningen/UMCG research database](#)

Citation for published version (APA):

Verschuuren, E. A. M. (2006). *Balance between herpes viruses and immunosuppression after lung transplantation*. s.n.

Copyright

Other than for strictly personal use, it is not permitted to download or to forward/distribute the text or part of it without the consent of the author(s) and/or copyright holder(s), unless the work is under an open content license (like Creative Commons).

The publication may also be distributed here under the terms of Article 25fa of the Dutch Copyright Act, indicated by the "Taverne" license. More information can be found on the University of Groningen website: <https://www.rug.nl/library/open-access/self-archiving-pure/taverne-amendment>.

Take-down policy

If you believe that this document breaches copyright please contact us providing details, and we will remove access to the work immediately and investigate your claim.

Downloaded from the University of Groningen/UMCG research database (Pure): <http://www.rug.nl/research/portal>. For technical reasons the number of authors shown on this cover page is limited to 10 maximum.

Chapter 9

Treatment of Post-Transplant Lymphoproliferative Disease with Rituximab: the Remission, the Relapse and the Complication.

Erik A.M. Verschuuren, Servi J.C. Stevens, Gustaaf W. van Imhoff, Jaap M. Middeldorp, Conny de Boer, Gerard Koëter, T.Hauw The and Wim van der Bij

Transplantation 2002;73(1):100-104

Abbreviations

BOS	Bronchiolitis Obliterans Syndrome
CD20	pan B-cell surface antigen
CD19	pan B-cell surface antigen
CsA	cyclosporine-A
EBV	Epstein-Barr virus
EBER	Epstein-Barr virus Encoded RNA
MHC	Major Histocompatibility Complex
MMF	Mycophenolate Mofetil
PTLD	Post Transplant Lymphoproliferative Disease
qPCR	quantitative-competitive PCR
RISH	RNA in situ hybridization

Abstract

Background. Rituximab, a humanized anti-CD20 monoclonal antibody, is a promising new tool for the treatment of post transplant Lymphoproliferative disease (PTLD), especially for patients transplanted with rejection prone transplants of vital organs, such as patients after lung transplantation. Thus far, no major complications have been described. We treated three lung transplant recipients with Rituximab because of PTLD.

Methods. Patients were treated with four weekly doses of 375 mg/m² of Rituximab. Epstein-Barr virus (EBV) DNA was monitored with quantitative-competitive polymerase chain reaction and circulating B cells with flowcytometry.

Results. Treatment with Rituximab resulted in a complete remission in all patients without signs of or progression of bronchiolitis obliterans syndrome. Patient 1 relapsed after 2 months with a partly CD20-negative PTLD but is in stable remission after radiotherapy. Patient 2 is in complete remission 16 months after treatment, but patient 3 developed a hypogammaglobulinemia and died of invasive aspergillosis after 6 months. EBV DNA was detectable in the blood samples of patients 2 and 3 before treatment with Rituximab and became negative instantly after Rituximab. In all three patients, B cells are absent in the peripheral blood 7 months (at death), 16 months, and 16 months after treatment with Rituximab. Antiproliferating agents, such as mycophenolate mofetil (MMF), might prolong B-cell depletion.

Conclusions. Rituximab was effective for the treatment of PTLD without progression of transplant dysfunction in our patients. Complications were a partly CD20-negative relapse of PTLD and a hypogammaglobulinemia. Attention should be paid to immunoglobulin G (IgG) levels, especially in patients treated with antiproliferating agents such as MMF.

Introduction

Epstein-Barr virus (EBV) infection is ubiquitous, leading to lifelong infection in over 90% of the adult population. The virus resides in epithelial cells of the pharynx and B cells of the human host (1,2). In immune-competent individuals, it is controlled by virus-specific CD8+, major histocompatibility (MHC) class I restricted cytotoxic T lymphocytes (3,4). These T lymphocytes lyse EBV-infected B cells if viral protein fragments, in the context of MHC class I, are presented at the cell surface.

In the immune-compromised host, such as lung transplant recipients, impairment of the cytotoxic T-cell response is thought to be mainly responsible for the failing control of EBV infection resulting in EBV-driven B-cell proliferation and subsequently post transplant lymphoproliferative disease (PTLD) (5). PTLD is a severe complication, afflicting 8% of the lung transplant recipients (6). No consensus exists about the best approach and treatment for PTLD (7). However, most authors agree that the first step should be reduction in immunosuppression with or without an antiviral drug (7). This first step, however, holds the risk for transplant rejection and graft failure. In case of lung transplantation, this means the death of the patient. The second step of therapy used to be chemotherapy, but because of the increased risk of sepsis and death in the immune compromised patient (8), alternative approaches are badly needed.

Several studies report about the effectiveness of anti-B-cell antibodies as an alternative treatment for PTLD (9-15). Recently a humanized mouse-anti-human CD20 antibody (Rituximab) has become commercially available and has been used with a response rate of 65% in solid-organ transplant recipients (10). Because most PTLDs are CD20-positive, the advantage of an immunological treatment for transplant recipients with high risk for rejection becomes clear. Here we describe the effectiveness of the treatment with Rituximab in three lung transplant patients with PTLD and discuss the results and complications of this therapy.

Patients and Methods

Patients

In the University Hospital Groningen, 142 lung transplantations were performed from 1990 until 2000. In 1999, three lung transplant recipients presented themselves 6 months, 19 months, and 78 months after transplantation

Treatment of PTLD

with an EBV-positive, CD20-positive, monoclonal PTLD. EBV was demonstrated by RNA in situ hybridization (RISH) for Epstein-Barr virus encoded RNA (EBER RNA) expression. They were all EBV seropositive before transplantation (data not shown).

Standard immunosuppression

The standard immunosuppression included: rabbit-Anti-Thymocyte Globulin (r-ATG, Merieux, 3 mg/kg, 2-5 infusions postoperatively), azathioprine (1.5-3 mg/kg/day), cyclosporine A (Neoral, Novartis, dose adjusted to trough levels of 400 µg/l, within 3 weeks tapered to levels of 150 µg/l), prednisolone (3 times 125 mg the first day and 0.2 mg/kg/day from day 2 to the third month and 0.1 mg/kg/day thereafter). Pneumocystis carinii prophylaxis consisted of Cotrimoxazole (960 mg on alternate days) and herpes prophylaxis of aciclovir (200 mg qd for 6 months). Acute rejection episodes were treated with pulse therapy of methylprednisolone (500-1000 mg iv for 3 days). Recurrent rejection was treated by replacement of cyclosporine by tacrolimus (Prograf, Fujisawa, trough levels 10-15 µg/l) and subsequently with conversion from azathioprine to Mycophenolate Mofetil (cellcept, Roche, 500-1000 mg bd). Cytomegalovirus-related disease was treated with Ganciclovir i.v. or Foscarnet until pp65-antigenemia levels dropped below limit of detection (16).

Rituximab protocol

Treatment protocol included reduction of calcineurin inhibitor (cyclosporine or FK506) for 14 days at diagnosis of PTLD to obtain 50% of standard trough levels (75-100 µg/l). Rituximab (375 mg/m² of body surface area, Mabthera, Roche) was given at day 7, 14, 21 and 28. Valaciclovir 1000 mg tid was given for six month after diagnosis of PTLD.

Quantitative EBV DNA PCR

Quantitative EBV DNA PCR (qPCR) was performed as recently described (17). In short, the DNA equivalent of 5 µl whole blood was amplified in qualitative EBNA-1 PCR, using the QP1/QP2 primer pair. All negative samples were subsequently tested by beta-globin PCR to check for DNA quality and sample inhibition, and if negative, DNA isolation was repeated and qualitative PCR performed on the new isolated sample (17). The EBV DNA load in positive samples was subsequently determined by quantitative competitive EBNA-1 PCR (QP1/QP2 primer pair) (17). As internal control for accuracy and reproducibility of quantification, a fixed amount of calibrator plasmid DNA, containing an internally randomized sequence of 23 nucleotides, was co-amplified in each

experiment in duplicate. In addition, all samples were screened blindly and appropriate negative and positive controls for DNA isolation, preparation of PCR master mix and EIA detection were included (one negative control for each ten tested samples and one positive control per experiment).

Results

All three patients reached complete remissions of PTLD without signs or progression of Bronchiolitis Obliterans Syndrome.

Patient 1 (Table 1), a 52 year old EBV-seropositive female, underwent a bilateral lung transplantation because of α 1-antitrypsin deficiency and emphysema. She had an uneventful postoperative course, was treated according to standard protocol, and presented with multiple nodules on the chest x-ray 6 months after transplantation. There were no symptoms of infectious or other complications and her lung function was still improving. Fine needle aspiration of a nodule gave no definitive diagnosis and open lung biopsy was performed. A monoclonal, CD20 positive, EBER-RISH positive, polymorphous, large B-cell lymphoma was diagnosed. CT scan showed multiple nodules in both lungs.

Table 1: Patient characteristics of the 3 patients treated with Rituximab. * IgG is 9.8 gr/l 12 months after Rituximab and ** IgG is 7.7 gr/l 16 months after treatment with Rituximab.

B-cells remain absent in the peripheral blood respectively 16 and 16 months after treatment with Rituximab in patient 1 and 2 and in patient 3 until death after 7 months.

CsA = Cyclosporine A, aza = azathioprine, P = prednisolone, Tac = tacrolimus, MMF= Mycophenolate Mofetil

Pt	Age/ sex	Ltx indication	Immuno- suppression	Presentation of PTLD treated with Rituximab		Serum IgG 7 months after Rit Gr/l
				Months after Ltx	Localization	
1	52/F	α 1-antitrypsin deficiency	CsA/aza/P	6	Lungs	9.9*
2	57/F	Pulmonary Fibrosis	Tac/aza/P	19	Stomach	6.9**
3	60/F	α 1-antitrypsin deficiency	Tac/MMF/P	78	Stomach	3.2

Abdominal CT-scan and bilateral bone marrow biopsy showed no PTLD. LDH was within normal range and she was considered stage IV (Ann Arbor). EBV qPCR remained negative at all times measured from transplantation until 2 weeks after presentation of PTLD (15 samples all EBV DNA negative). She was treated according to the Rituximab protocol and all lesions disappeared. Only a density

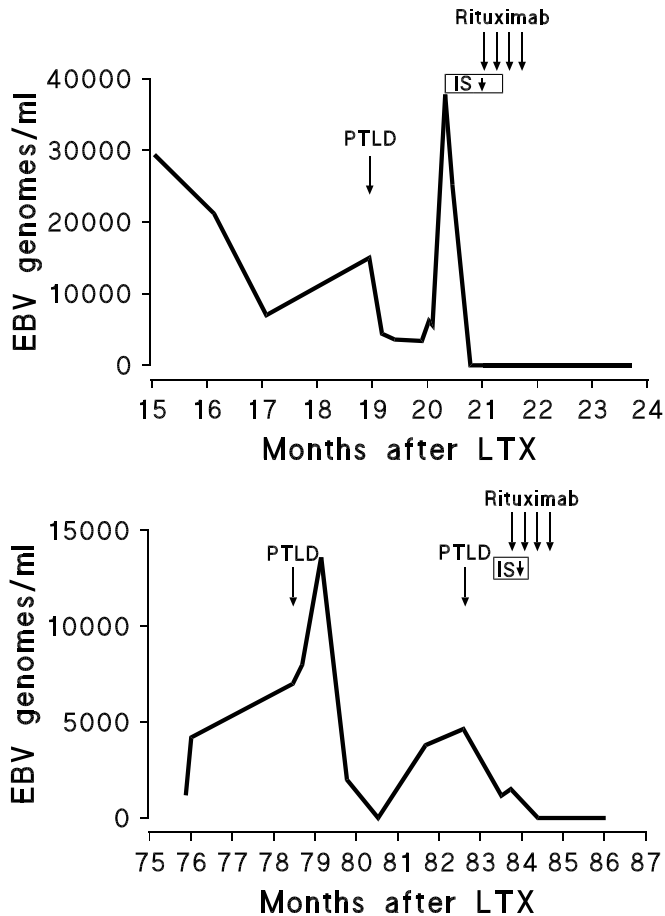
at the site of the open lung biopsy remained. Two months later she presented with night sweats, low grade fever between 37.5C and 38.5C and an increase in size of the density at the operation site. CT scan showed an abscess but with needle biopsy only necrotic material was obtained. A second open lung biopsy revealed a partly CD20 negative partly CD45 positive large B-cell lymphoma, uniformly EBER-RISH positive. She was subsequently treated with local radiotherapy (20 Gy) and reduction of immune suppression. Presently 16 months after Rituximab therapy she is in stable remission without signs of rejection or symptoms of infections. Peripheral blood B-cells are still not detectable with flowcytometry and qPCR for EBV-DNA remains negative.

Patient 2, a 57 year old female, developed a bleeding ulcer of the body of the stomach 19 months after Ltx and 6 months after conversion from cyclosporine to tacrolimus. Biopsy of the ulcer demonstrated a monoclonal EBER-RISH positive, CD20 positive large cell B-cell lymphoma. CT scans of the abdomen and the thorax were negative, as was bilateral bone marrow biopsy. LDH was within normal range and she was stage IIE (Ann Arbor). She was treated with Rituximab according to protocol and is free of symptoms now 16 month after treatment. Repeated endoscopy was performed and random biopsies did not show any sign of PTLD. Flowcytometry for CD19 positive cells is still negative in the peripheral blood 16 months after administration of Rituximab. Q-PCR for EBV-DNA in whole blood was positive from 2 months after transplantation and turned negative after reduction of the immune suppression. It continued to remain negative during and since treatment with Rituximab (Fig. 1a).

Patient 3, a 60 year old female, was also converted from cyclosporine to tacrolimus because of Bronchiolitis Obliterans syndrome (BOS) at 72 months after Ltx and 2 months later from azathioprine to MMF for progressive decrease in lung function without signs of infection. Three months after conversion she was readmitted because of toxic levels of tacrolimus (>20 ngr/l) and oral aphthous ulcers. Biopsy of a lip showed an EBV positive, CD20 positive, large B-cell lymphoma. No other localization was demonstrated with CT scans of the thorax and the abdomen and bilateral bone marrow biopsy.

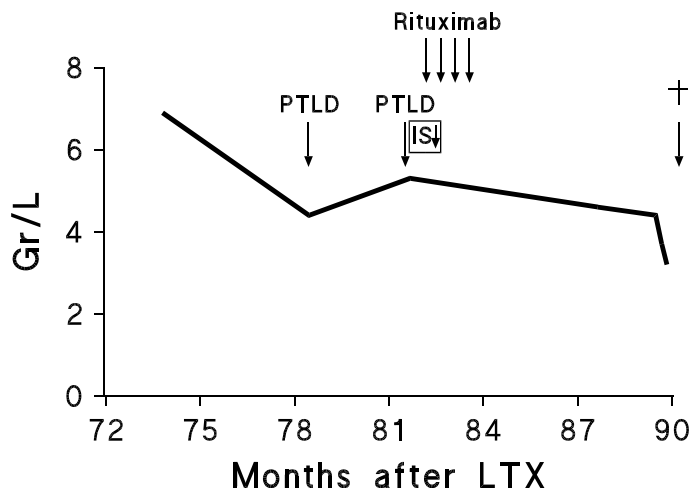
Immunosuppression was lowered to standard levels and high dose oral aciclovir (1000 mg qid) was started. All lesions disappeared. Five months later she was readmitted because of abdominal discomfort and, endoscopy revealed multiple ulcers in the body of the stomach. Biopsies showed a monoclonal EBV positive, CD20 positive large cell B-cell-lymphoma.

Figure 1a and 1b: Results of quantitative-competitive-EBV-DNA PCR before and after treatment with Rituximab in patient 2 (1A) and patient 3 (1B)



Her LDH was within normal range and she was stage IV (Ann Arbor). She was treated with Rituximab and became free of symptoms. Three months later she presented with fever, dyspnea and cough. *Escherichia Coli* was cultured from the sputum and transbronchial biopsy showed Actinomyces. She was treated with penicillin G iv. One month later she was again admitted because of fever. Broncho-alveolar lavage showed gram negative rods and *Aspergillus Fumigatus*. Flowcytometric analysis of peripheral blood for B-cells was still negative and serum immunoglobulin levels had gradually dropped to 3,2 gr/l (Fig. 2). Initially she responded to intravenous administration of liposomal Amphotericin B with normalization of temperature, but 2 weeks later the temperature rose again to 38.5°C.

Figure 2: Serum IgG levels of patient 3 after treatment with Rituximab, IS↓ = Reduction of Immunosuppression



Because of the hypogammaglobulinaemia intravenous administration of immunoglobulines was started. She died 7 month after Rituximab due to invasive Aspergillosis. Q-PCR for EBV-DNA was positive from 71 months after Ltx (first sample tested). It remained positive thereafter and fluctuated with immunosuppression. EBV-DNA level decreased after reduction in the immunosuppression and turned negative from the first sample taken after Rituximab (Fig. 1b).

Discussion

In spite of the initial successful response of PTLD to Rituximab of these patients (they all reached initially a complete remission of their PTLD without signs of or progression of Bronchiolitis Obliterans syndrome) they also show some pitfalls of this treatment.

The first patient relapsed with a partly CD20 negative PTLD. It was striking that all nodules vanished following Rituximab treatment and that the relapse presented at the site of the operation. The occurrence of a CD20 negative relapse has been described previously after treatment with Rituximab (18) but in our patient we think that two factors might have contributed. The first factor might be the insufficient penetration of antibodies in the haematoma caused by the open lung biopsy. Sixteen months after treatment with Rituximab still no circulating B-cells can be demonstrated and all nodules on the chest x-ray

disappeared with the exception of the site of the open lung biopsy where a relapse with CD20 positive cells developed. The second factor is the early manifestation of the PTLD.

The chance of selecting a plasmacytic differentiated CD20 negative population might be higher in early, polymorphous, presentations of PTLD (19). The reason could be that they consist of a more diverse population of maturation stages of EBV infected B-cells. The treatment with Rituximab in that case may not cover plasmacytic stages of B-cells because plasmacells have become CD20 negative. An alternative explanation could be that the dose of Rituximab was too low for the bulk of the disease in this patient seems unlikely regarding the complete and still ongoing depletion of all B-cells now over 16 months after treatment.

The second and third patients demonstrate clearly the advantages of treatment with Rituximab. Both had shown previous rejection episodes and thus reduction of immunosuppression was not an attractive option. Chemotherapy, with a high risk of infectious complications in these patients with damaged lungs and previous infections was also not an attractive alternative. Rituximab proved to be an effective treatment without the need of longterm reduction of immunosuppression. Both patients reached a complete remission with only a relative short period of reduction of immunosuppression. The rationale behind this reduction was to enable the immune system to recuperate before the administration of Rituximab. With reduced immunosuppression, the immune system might be better able to respond to the EBV antigens from the lysed EBV-positive B cells. Patient 2 remained in complete remission with a stable lung function since treatment of the PTLD, now 16 months ago.

Patient 3 developed a hypogammaglobulinemia. Severe hypogammaglobulinemia with an increased infection frequency has not been described after treatment with Rituximab. It has been described during treatment with MMF, and indeed in this patient, IgG levels decreased from normal (6.9 gr/L) to low levels (5.3 gr/L) after start of the MMF 10 months before Rituximab. But before Rituximab was given, the patient had no infections and serum IgG levels were stable (although at persistently low levels). After treatment with Rituximab, while dosage of MMF was decreased to 250 mg, t.i.d., the IgG levels decreased to 3.2 gr/L and infections appeared. This suggests that Rituximab at least contributed to the development of hypogammaglobulinemia.

Striking was also the very long-term depletion of B-cells from the peripheral blood. B-cell depletion up to 6 months has been described (20) but 2 of our patients were depleted of B-cells for over 16 months.

The explanation might be twofold: First, the advised dosage of Rituximab (375 mg/kg) was tested in non-transplant patients with low grade B-cell Non-Hodgkin Lymphomas (NHL) who usually have a high burden of tumor cells. Our patients did not have a high tumor burden and the dosage might be too high for our patients which could result in prolonged circulation of Rituximab. Second, and in our view a more likely explanation is the continuing of the administration of immunosuppressive medication and particular proliferation inhibitors such as azathioprine and MMF. These drugs, and in particularly MMF, inhibit restoration of the peripheral B-cell pool. Measurement of Rituximab titers and rate of decline may be able to differentiate between these hypotheses.

We also retrospectively monitored the EBV viral load of our patients, and although the viral load could have predicted the PTLD many months before clinical diagnosis in patients 2 and 3, the usefulness of monitoring EBV levels in the peripheral blood after treatment with Rituximab is questionable. Both patients 2 and 3 became rapidly negative for EBV DNA after reduction of immunosuppression and treatment with Rituximab. Previously, we demonstrated that EBV DNA in blood is highly restricted to B cells (21). Therefore, the absence of EBV DNA in the peripheral blood in our view reflects more the absence of B cells in the circulation than immune control of tissue localized EBV driven proliferation. Only when B cells are restored in the circulation, EBVDNA measurement in blood may be informative again to determine whether we accomplished only a temporary depletion of B cells or a long-term improvement of EBV control by the immune system.

In conclusion, Rituximab is effective for the treatment of PTLD without progression of transplant dysfunction. However, relapses do occur and attention should be paid to IgG levels, especially in patients treated with antiproliferating agents such as MMF.

References

1. Miyashita EM, Yang B, Lam KM, Crawford DH, Thorley-Lawson DA. A novel form of Epstein-Barr virus latency in normal B cells in vivo. *Cell* 1995;80: 593-601.
2. Sixbey JW, Nedrud JG, Raab-Traub N, Hanes RA, Pagano JS. Epstein-Barr virus replication in oropharyngeal epithelial cells. *N.Engl.J.Med.* 310, 1225. 1984.
3. Moss DJ, Wallace LE, Rickinson AB, Epstein MA. Cytotoxic T cell recognition of Epstein-Barr virus-infected B cells. I. Specificity and HLA restriction of effector cells reactivated in vitro. *Eur J Immunol* 1981;11: 686-693.
4. Rickinson AB, Moss DJ. Human cytotoxic T lymphocyte responses to Epstein-Barr virus infection. *Annu Rev Immunol* 1997;15: 405-431.
5. Rickinson AB, Kieff E. Epstein-Barr virus. In: Fields BN, Knipe DM, Howley PM, eds. *Field's virology*. Philadelphia: Lipincott-Raven, 1996: 2397-2446.
6. Kaye MP. The Registry of the International Society for Heart and Lung Transplantation: tenth official report--1993. *J Heart Lung Transplant* 1993;12: 541-548.
7. Paya CV, Fung JJ, Nalesnik MA et al. Epstein-Barr virus-induced posttransplant lymphoproliferative disorders. ASTS/ASTP EBV-PTLD Task Force and The Mayo Clinic Organized International Consensus Development Meeting. *Transplantation* 1999;68: 1517-1525.
8. Nalesnik MA, Makowka L, Starzl TE. The diagnosis and treatment of posttransplant lymphoproliferative disorders. *Curr Probl Surg* 1988;25: 367-472.
9. Leblond V, Sutton L, Dorent R et al. Lymphoproliferative disorders after organ transplantation: a report of 24 cases observed in a single center. *J Clin Oncol* 1995;13: 961-968.
10. Milpied N, Vasseur B, Parquet N et al. Humanized anti-CD20 monoclonal antibody (Rituximab) in post transplant B-lymphoproliferative disorder: a retrospective analysis on 32 patients. *Ann Oncol* 2000;11 Suppl 1: 113-116.
11. Stephan JL, Le Deist F, Blanche S et al. Treatment of central nervous system B lymphoproliferative syndrome by local infusion of a B cell-specific monoclonal antibody. *Transplantation* 1992;54: 246-249.
12. Benkerrou M, Jais JP, Leblond V et al. Anti-B-cell monoclonal antibody treatment of severe posttransplant B- lymphoproliferative disorder: prognostic factors and long-term outcome. *Blood* 1998;92: 3137-3147.
13. Fischer A, Blanche S, Le Bidois J et al. Anti-B-cell monoclonal antibodies in the treatment of severe B-cell lymphoproliferative syndrome following bone marrow and organ transplantation. *N Engl J Med* 1991;324: 1451-1456.
14. Cook RC, Connors JM, Gascoyne RD, Fradet G, Levy RD. Treatment of post-transplant lymphoproliferative disease with rituximab monoclonal antibody after lung transplantation. *Lancet* 1999;354: 1698-1699.
15. Kuehnle I, Huls MH, Liu Z et al. CD20 monoclonal antibody (rituximab) for therapy of Epstein-Barr virus lymphoma after hemopoietic stem-cell transplantation. *Blood* 2000;95: 1502-1505.
16. van den Berg AP, Tegzess AM, Scholten-Sampson A et al. Monitoring antigenemia is useful in guiding treatment of severe Cytomegalovirus disease after organ transplantation. *Transpl Int* 1992;5: 101-106.
17. Stevens SJ, Vervoort MB, van den Brule AJ, Meenhorst PL, Meijer CJ, Middeldorp JM. Monitoring of Epstein-Barr virus DNA load in peripheral blood by quantitative competitive PCR. *J Clin Microbiol* 1999;37: 2852-2857.

Treatment of PTLD

18. Kinoshita T, Nagai H, Murate T, Saito H. CD20-negative relapse in B-cell lymphoma after treatment with Rituximab. *J Clin Oncol* 1998;16: 3916.
19. Nalesnik MA, Starzl TE. Epstein-Barr virus, infectious mononucleosis, and posttransplant lymphoproliferative disorders. *Transplant Sci* 1994;4: 61-79.
20. Maloney DG, Grillo-Lopez AJ, White CA et al. IDEC-C2B8 (Rituximab) anti-CD20 monoclonal antibody therapy in patients with relapsed low-grade non-Hodgkin's lymphoma. *Blood* 1997;90: 2188-2195.
21. Stevens, S. J. C., Verschuuren, E. A. M., Pronk, I., Bij, van der W., Harmsen, M. C., The, T. H., Meijer, C. J., Brule, van den A. J. C., and Middeldorp, J. M. Frequent monitoring of Epstein-Barr virus DNA load in unfractionated whole blood is essential for early detection of posttransplant lymphoproliferative disease in high risk patients. *Blood* 97(5), 1165-1171. 2001.