

University of Groningen

## Clinical translation of laser speckle contrast imaging

Heeman, Wido

DOI:  
[10.33612/diss.256850700](https://doi.org/10.33612/diss.256850700)

**IMPORTANT NOTE: You are advised to consult the publisher's version (publisher's PDF) if you wish to cite from it. Please check the document version below.**

*Document Version*  
Publisher's PDF, also known as Version of record

*Publication date:*  
2022

[Link to publication in University of Groningen/UMCG research database](#)

*Citation for published version (APA):*  
Heeman, W. (2022). *Clinical translation of laser speckle contrast imaging*. [Thesis fully internal (DIV), University of Groningen]. University of Groningen. <https://doi.org/10.33612/diss.256850700>

### Copyright

Other than for strictly personal use, it is not permitted to download or to forward/distribute the text or part of it without the consent of the author(s) and/or copyright holder(s), unless the work is under an open content license (like Creative Commons).

The publication may also be distributed here under the terms of Article 25fa of the Dutch Copyright Act, indicated by the "Taverne" license. More information can be found on the University of Groningen website: <https://www.rug.nl/library/open-access/self-archiving-pure/taverne-amendment>.

### Take-down policy

If you believe that this document breaches copyright please contact us providing details, and we will remove access to the work immediately and investigate your claim.

Downloaded from the University of Groningen/UMCG research database (Pure): <http://www.rug.nl/research/portal>. For technical reasons the number of authors shown on this cover page is limited to 10 maximum.

# APPLICATION OF LASER SPECKLE CONTRAST IMAGING IN LAPAROSCOPIC SURGERY

---

**Wido Heeman**, Klaas Dijkstra, Christiaan Hoff, Sietze Koopal, Jean-Pierre Pierie, Hessel Bouma, E. Christiaan Boerma

**BIOMEDICAL OPTICS EXPRESS, 2019**

## ABSTRACT

Anastomotic leakage is a worldwide problem in gastrointestinal surgery which seems to be related to the state of microcirculation. Laser speckle contrast imaging (LSCI) could give surgeons insight in the state of microcirculation to attune the site of anastomosis. This work studies the feasibility of LSCI as a tool for this purpose. An experimental setup was developed using a commercially available laparoscopic video system. Laser speckle contrast imaging is capable of detecting ischemic areas on the large intestine. Further research and development are required before adaptation of this technique in the operating room.



# 1 INTRODUCTION

Anastomotic leakage (AL) is a major problem in gastrointestinal surgery with rates reported ranging from 3.8% [1] to 9.8% [2] depending on site of the anastomosis in the gastrointestinal tract [3] and the definition of anastomotic leakage [4]. This leads to an enormous burden for both the patient and the hospital. The average increased intensive care unit (ICU) time is 9 days [5] which results in an extra cost of 10k\$ to 50k\$ per case of AL [6]. The multi-factorial origin of AL plays a major role in this complication. Many of these factors such as smoking, age, sex, nutritional status and premorbid conditions cannot be controlled by the surgeon [1,7-9]. However, some factors that have an impact on the postoperative outcome can be controlled such as a good surgical technique, adherence to the principles of anastomosis construction, duration of surgery, open or laparoscopic surgery and blood transfusion requirements [9]. The mortality of AL is reported as high as 12.9% which increases when multiple risk factors are present [8]. The general consensus is that an important factor regarding AL is the state of microcirculation at the site of the anastomosis [7,9]. It is expected that a better state of microcirculation contributes to a fast healing process which in term leads to a lower incidence of anastomotic leakage [10-13]. The current intraoperative selection of an optimal site for the anastomosis is based on subjective clinical indicators of intestinal viability. This can range from the bleeding of the edges of resected margins, palpable pulsations of mesenteric arteries to the color of the bowel wall [3]. As indicated by others [14] there is a need for a gold standard in determining the state of microcirculation of the intestines. This method should be suitable for laparoscopic use, robust and preferably non-invasive. Current techniques that are applied during a surgical procedure to analyze the state of microcirculation are laser Doppler flowmetry (LDF) [15,16], indocyanine green imaging (ICG) [17,18], laser speckle contrast imaging (LSCI) in open- [19-21] and, more recently, laparoscopic- surgery [22]. Others have already proven that insight in the state of microcirculation decreases the rate of anastomotic leakage [11,17].

Currently only ICG is widely used in minimally invasive surgery but it has its limits. As described by others [23] the estimate of flow using ICG is determined by the concentration of the contrast agent in the blood plasma meaning that large vessels will give a higher readout. The intensity difference measured could as well be a difference in dye concentration rather than a change in physiology (i.e. ischemic areas) which might lead to erroneous information to the surgeon when solely the change in ICG signal is investigated.

LDF has been used to image the microcirculation both on the skin and intraoperatively during esophagectomy and colonic perfusion [24] and has shown to have great reproducibility in a controlled environment. However, LDF has the disadvantage that it is very sensitive to fast, small movements due to the scanning motion during data acquisition which makes it unsuitable for laparoscopic use on the intestines.



LSCI is, unlike LDF, a full field technique and, unlike ICG, without contrast agents. It is a non-contact method and can deliver real-time assessment of the microcirculation [25-29]. The advantages are its' low cost and high spatial and temporal resolution [30]. The laser generates a random speckle pattern which is changed by movement of the underlying particles such as red blood cells. This results in a loss of contrast which can be linked to the amount of blood flow [31]. LSCI could help reduce the occurrence of anastomotic leakage by identifying ischemic areas so the surgeon can determine the site of the anastomosis.

In this paper we present a setup that is capable of measuring intra-abdominal blood flow using a laparoscope and laser speckle contrast imaging. To validate the setup, we developed a vascular occlusion test that is executable intraoperatively during laparoscopic surgery on the large intestine. Our results are compared with a vascular occlusion test on the finger using an inflatable cuff as has been done by others [32]. Lastly, we make a comparison between a 680nm and 532nm wavelength laser for both anatomical sites.

## 2 MATERIALS AND METHODS

### 2.1 Subjects

The study was approved by the medical ethics research board and informed consent was obtained for each subject, according to all local laws and regulations. In this prospective observational two center study fourteen (n=14) measurements from ten (n=10) subjects with colon cancer were included. The subjects, man (n=6) and female (n=4) had a mean  $\pm$ SD age of 69  $\pm$  9 years. Heart rate was 72  $\pm$  11 beats/min and systolic and diastolic blood pressures were 122  $\pm$  18 and 73  $\pm$  14 mm Hg, respectively with an average mean arterial pressure of 87  $\pm$  13 mmHg. Subjects underwent right hemicolectomy (n=6), lower anterior resection (n=1), subtotal colectomy (n=1) and sigmoid resections (n=2). One (n=1) subject was a smoker, four (n=4) had some form of cardiovascular disease and two (n=2) subjects were diabetic.

For the vascular occlusion test on the human nail fold ten (n=10) healthy, non-smoking subjects receiving no medication participated in the experiments. The subjects, man (n=6) and female (n=4) had an age of 33  $\pm$  12 years and weight of 67  $\pm$  10 kg. Heart rate was 67  $\pm$  9 beats/min and systolic and diastolic blood pressures were 120  $\pm$  12 and 77  $\pm$  13 mmHg, respectively. The subjects refrained from caffeine the day of the experiment.

### 2.2 Laser speckle contrast imaging setup

A LSCI setup typically consists of a low-powered laser with a diffuser and a charge coupled device (CCD). To prove that LSCI is feasible laparoscopically an experimental setup was built. The 680nm and 532nm lasers are chosen for this study to examine the effect of different pen-

etration depths. Traditionally a 785nm near infrared laser is used in commercial laser speckle products, however, this wavelength was filtered out by the infrared filter from the laparoscope. To this end we chose a somewhat different wavelength in the red spectrum. The red fiber coupled laser diode ( $\lambda=680$  nm, 200 mW; Lionix International, Enschede, The Netherlands) and green fiber coupled laser diode ( $\lambda=532$  nm, 200 mW; Lionix International, Enschede, The Netherlands) were coupled into an optical fiber with a collimating lens at the distal end. A custom y-cable allows the surgeon to switch between white light and coherent light during measurements. The laparoscope (Endoeye®, Olympus, Hamburg, Germany) and video tower (Viscera Elite®, Olympus, Hamburg, Germany) were not modified. The laparoscope was held steady using a surgical tripod (Unitrack®, Bbraun, Melsungen, Germany). The camera exposure time was kept constant at 40ms for all measurements. The aperture could not be determined due to the use of a commercially available system but was kept constant for all measurements. The images were acquired at 10 Hz using a frame grabber and were saved on a computer for post-processing using custom software developed in cooperation with the NHL Stenden University of Applied Sciences (Leeuwarden, The Netherlands). A 150- by 150-pixel region of interest was chosen in post-processing in all experiments. During post-processing the images were converted to pseudo-color images where flow was indicated from red (high flow) to blue (low flow).

## **2.3 Image analysis**

Laser speckle contrast imaging is based on the random interference pattern produced when coherent light scatters from a random medium which is then imaged onto a camera detector. Due to the penetration depth of 0.4mm to 1mm [28,33] the speckle pattern becomes blurred in areas with high blood flow. The objective speckle pattern randomly changes in a rate which corresponds to the amount of blood flow. The blurring is caused by integrating the randomly changing objective speckle pattern. The blurring of the speckle pattern or speckle contrast is defined as the ratio of the standard deviation by the mean intensity [34].

$$LSCI = K = \frac{\sigma}{I} \quad (1)$$

Depending on the application speckle contrast can be calculated using either temporal contrast, by integrating pixels over time, or by using spatial contrast, by integration over multiple neighboring pixels. Spatial contrast offers superior temporal resolution at the expense of the spatial resolution and vice versa for temporal contrast [25].

Since it is impossible to keep (components of) the abdomen completely still a compromise was made between temporal and spatial resolution using a 5x5 sliding window. The specific detail of the mathematical compensation to attenuate movement artefacts will be published in a separate article.



## **2.4 Vascular occlusion test on the large intestines**

A schematic representation of the laparoscopic LSCI system setup can be found in figure 1a. Subjects underwent surgery in operating rooms kept at an ambient temperature of  $20\pm 1^{\circ}\text{C}$  and rested in a reverse Trendelenburg position. Induction of general anesthesia with propofol sufentanil and a regional epidural anesthesia according to local protocols took place. Throughout the surgical procedure mean arterial pressure was maintained at a minimal level 65mmHg with fluid administration and norepinephrine if deemed necessary. Peripheral oxygen saturation was maintained at a minimal level of 95%.

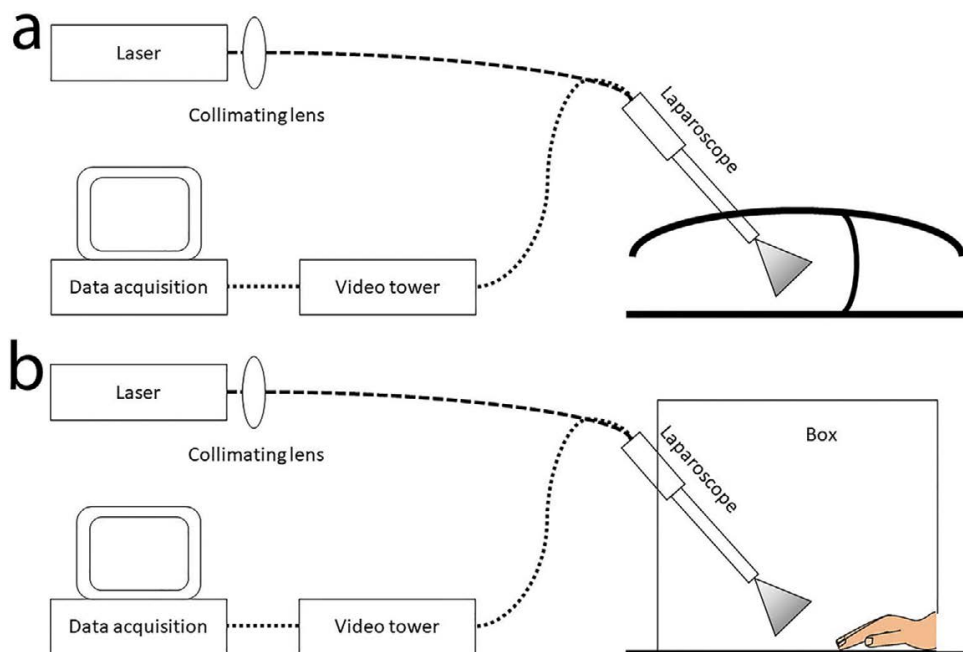
After introduction of the endoscopic trocar and instruments all collateral mesenteric vasculature was dissected with the exception of the main feeding artery. This concerns the ileocolic artery for a right hemicolectomy and the inferior mesenteric artery in case of a sigmoidectomy or anterior resection. Prior to the final colonic resection LSCI measurements were performed. A region of interest (ROI) with the least amount of fat was identified by the surgeon. Subsequently the scope was positioned and stabilized with the aid of a dedicated surgical tripod. One ROI per subject was deemed sufficient to detect flow changes during complete occlusion. The surgical tripod was deemed necessary for these long measurements to minimize camera movement compared to a handheld setup. By means of a surgical vascular clamp a minimum period of occlusion of 20 seconds was accomplished. Together with baseline and post-occlusion the total observation period was 50 seconds. Mechanical ventilation was held throughout the complete experiment, avoiding a peripheral saturation level of 95%. After the experiment the surgeon continued the colon resection according to routine. Estimated extra surgery time was around ten minutes for four measurements using two different lasers at two different positions.

## **2.5 Vascular occlusion test on the human nailfold**

The vascular occlusion test (VOT) on the human nailfold is a classical test to assess the microvascular function and results in an increased microvascular flow after an ischemic period. The VOT on the human nailfold has been performed before using LSCI and correlated well compared to intravital microscopy by means of sidestream darkfield imaging. Aim of this part of the experiment is to reproduce a similar ischemia-reperfusion flow pattern as described by others [32,35].

The test subjects were placed in a room to rest and acclimatize to the room temperature of 21 degrees for ten minutes. The right arm rested and was kept stable on a table during the complete experiment. Measurements consisted of a 45 second baseline, a three-minute occlusion and then two-minutes of post occlusion. During the three-minute VOT the occlusion was caused by a cuff pressure, exceeding the subjects' own blood pressure by at least 50 mmHg. In addition, the subjects' lower arm was placed inside a dark box with approximately three-centimeter distance between the laparoscope and the nailfold. A schematic representation of the laparoscopic LSCI system setup can be found in figure 1b.





**Fig. 1** Endoscopic laser speckle contrast imaging (LSCI) system setup. **a.** As used during colon resections and **b.** as used for the nail fold experiment

## 2.6 Statistical analysis

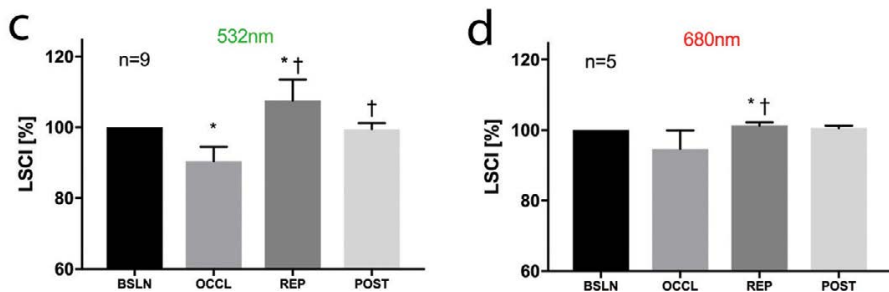
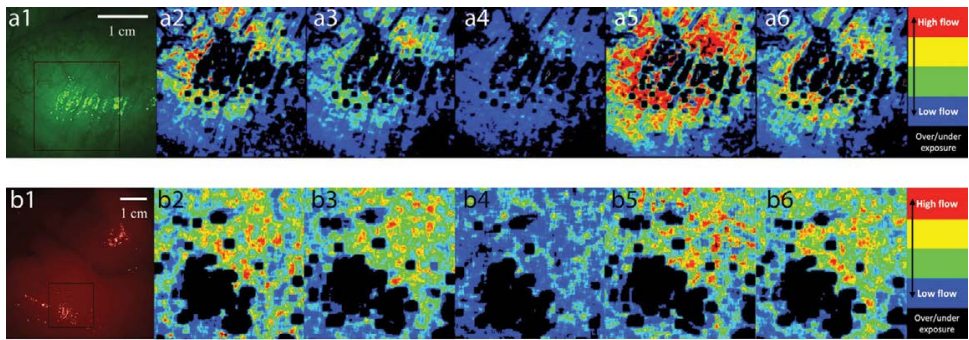
Graphpad Prism (Prism 7<sup>®</sup>, La Jolla, United States of America) was used for statistical analysis. All data are presented as mean  $\pm$  standard deviation. Due to the small sample size applicable non-parametrical paired tests were used. A two-sided p-value  $<0.05$  was considered statistically significant.

## 3 RESULTS

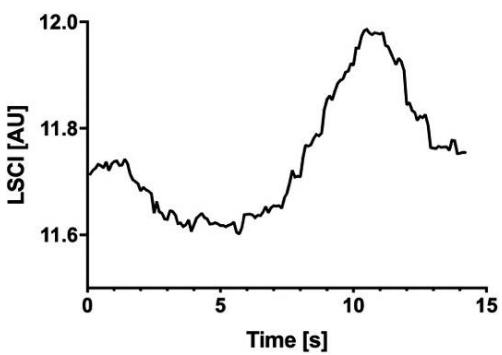
### 3.1 Vascular occlusion test on the large intestines

A pseudo-color image of the VOT on the large intestines is represented in figure 2a and 2b. A typical ischemia reperfusion trace can be found in figure 3. In figure 2c and 2d, perfusion measurements with LSCI are shown for the four different stages of the VOT for the green and red laser respectively. LSCI units were normalized using baseline as standard; hence the SD of baseline values is zero. Baseline and post-intervention values were calculated over a 15 second period, whereas the occlusion and reperfusion values are the minimum and maximum values during the corresponding periods.





**Fig. 2 a.** The pseudo-color images of the vascular occlusion test on the colon. a1 and b1 show a color image of the large intestine with green and red laser light respectively. a2/b2-a6/b6 are perfusion maps of the region of interest found in a1 and b1. a2/b2 is during baseline, a3/b3 and a4/b4 are during occlusion, a5/b5 is during reperfusion and a6/b6 is during post occlusion. Red indicates high flow, blue indicates low flow. Black means over/under exposure. The brightness of b1 was increased for illustrative purposes. Also, the laser speckle contrast imaging values normalized on baseline as measured in the 150x150 pixel region of interest using c. a green laser (532nm, n=9) and d. a red laser (680nm, n=5) during the vascular occlusion test in the large intestines. Results are normalized using their own baseline level. \*p<0.05 compared to baseline †p<0.05 compared to previous timepoint.



**Fig. 3** An ischemia-reperfusion trace found with laser speckle contrast imaging analysis after a short occlusion of  $\pm 7$  seconds on the large intestine.

Using the green laser, perfusion during VOT was significantly reduced to  $90.46 \pm 3.78\%$  ( $p < 0.0001$ ) when compared to baseline. In the reperfusion period LSCI was significantly increased by 17.04% to  $107.51 \pm 5.56\%$  ( $p = 0.005$ ) when compared baseline. Post-occlusion LSCI showed a non-significant decrease to  $99.48 \pm 1.68\%$  ( $p = 0.4$ ) compared to baseline.

Using the red laser, perfusion during VOT was non-significantly reduced to  $94.72 \pm 4.67\%$  ( $p = 0.09$ ) when compared to baseline. In the reperfusion period LSCI was significantly increased by 6.59% to  $101.3 \pm 0.82\%$  ( $p = 0.03$ ) when compared baseline. Post-occlusion LSCI showed a non-significant decrease to  $100.57 \pm 0.60\%$  ( $p = 0.13$ ) compared to baseline.

### **3.2 Vascular occlusion test on the human nail fold**

A pseudo-color image of the VOT on the human nail fold is represented in figure 4a and 4b. In figure 4c and 4d, perfusion measurements with LSCI are shown for the four different stages of the VOT for the green and red laser respectively. LSCI units were normalized using baseline as standard; hence the SD of baseline values is zero. Baseline and post-intervention values were calculated over a 45 second period, whereas the occlusion and reperfusion values are the minimum and maximum values during the corresponding periods.

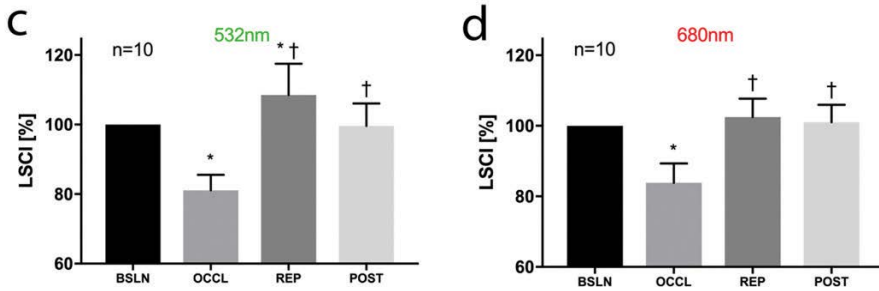
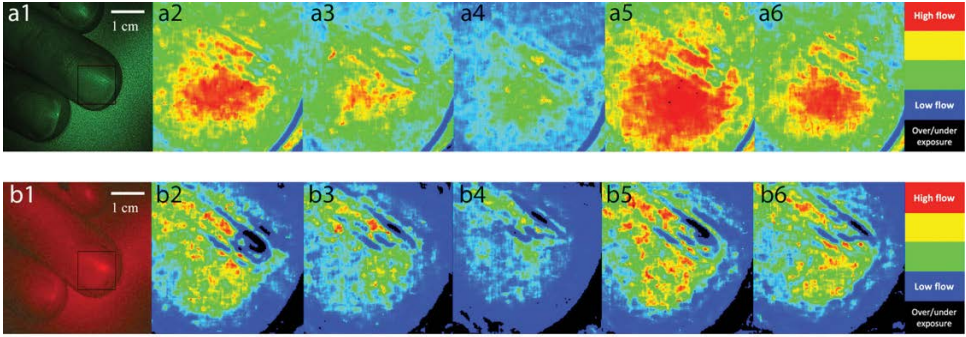
Using the green laser, perfusion during VOT was significantly reduced to  $81.08 \pm 4.22\%$  ( $p < 0.0001$ ) when compared to baseline. In the reperfusion period LSCI was significantly increased by 27.44% to  $108.53 \pm 8.51\%$  ( $p = 0.0148$ ) when compared baseline. Post-occlusion LSCI showed a non-significant decrease to  $99.64 \pm 6.11\%$  ( $p = 0.86$ ) compared to baseline.

Using the red laser, perfusion during VOT was significantly reduced to  $83.87 \pm 5.19\%$  ( $p < 0.0001$ ) when compared to baseline. In the reperfusion period LSCI was non-significantly increased by 18.62 to  $102.49 \pm 4.95\%$  ( $p = 0.16$ ) when compared baseline. Post-occlusion LSCI showed a non-significant decrease to  $101.02 \pm 4.69\%$  ( $p = 0.53$ ) compared to baseline.

## **4 DISCUSSION**

In this paper we report on the first experiences in ten ( $n = 10$ ) subjects with the endoscopic intra-abdominal application of LSCI. The data show that this setup is capable of imaging blood flow intra-abdominally using a standard laparoscopic video tower and laser speckle contrast imaging. Our measurements on the large intestines correlate well with nail fold LSCI of ten ( $n = 10$ ) healthy volunteers using the same setup. This finding is of utmost importance since it has recently been confirmed to give an accurate representation of blood flow in comparison to side-stream dark field microscopy, to be considered a golden standard [26,32]. The experiments proof that LSCI is capable of detecting ischemic areas on the large intestines and that the spatial and temporal resolution are suitable to detect changes in the microcirculation during a VOT.





**Fig. 4** The pseudo-color images of the vascular occlusion test on the nail fold. a1 and b1 show a color image of the finger with green and red laser light respectively. a2/b2-a6/b6 are perfusion maps of the region of interest found in a1 and b1 for the green and red laser respectively. a2b/2 is during baseline, a3/b3 and a4/b4 are during occlusion, a5/b5 is during reperfusion and a6/b6 is during post occlusion. Red indicates high flow, blue indicates low flow. Black means over/under exposure. The brightness of b1 was increased for illustrative purposes. Also, the laser speckle contrast imaging values normalized on baseline as measured in the 150x150 pixel region of interest using c. a green laser (532nm, n=10) and d. a red laser (680nm, n=10) during the vascular occlusion test in the large intestines. Results are normalized using their own baseline level. \*p<0.05 compared to baseline †p<0.05 compared to previous timepoint.

Overall, our data is in line with the existing experimental data on LSCI in relation to organ perfusion. Sturesson and co-workers were one of the first to report the applicability of LSCI to measure blood flow of visceral organs in an open-abdomen animal experiment [26]. Subsequently, several authors reported on the use of LSCI in the open-abdomen clinical setting of esophagectomy [20,21]. Zheng *et al.* [22] recently demonstrated the first application of laparoscopic LSCI using a similar preclinical setup in rats and swines. Both the reported illumination profile bias due to suboptimal light distribution and the inevitable effect of specular reflections were found in our data as is illustrated by figures 2a, 2b, 4a and 4b. However, we also do believe that these limitations do not impede the application of LSCI in minimal invasive surgery. To our knowledge we are the first to extend this field of research into a clinical abdominal laparoscopic setting. In comparison to the nail fold VOT experiments of Bezemer *et al.* [32] our LSCI perfusion traces



seem to be comparable. After a reduction in LSCI values during occlusion an overshoot in comparison with baseline is observed,  $108.53 \pm 8.51\%$  ( $p=0.0148$ ), using the green laser. However, it is of note that during our nail fold experiments with the red laser the overshoot did not reach statistical significance ( $102.49 \pm 4.95\%$  ( $p=0.16$ )). This may be explained by the difference in wavelength of the laser (680nm vs 785nm). The wavelength is related to the penetration depth and displays specific optical properties, as illustrated by the subtle differences in our observations between the red and green laser. To our knowledge there are no data on VOT experiments in human visceral organs. Although Stureson performed a VOT on animal livers, reperfusion was not described. Others performed similar VOT experiments in rat liver; however, these data are not comparable with our setting due to the very long occlusion time (120 minutes) [36].

In addition, small but significant differences in response to VOT between the nail fold and the large intestines, as well as differences between the red and green laser need to be addressed. Firstly, the overall decrease in LSCI during occlusion in the large intestines,  $90.46 \pm 3.78\%$  ( $p<0.0001$ ) and  $94.72 \pm 4.67\%$  ( $p=0.09$ ), is roughly ten percent less than on the finger,  $81.08 \pm 4.22\%$  ( $p<0.0001$ ) and  $83.87 \pm 5.19\%$  ( $p<0.0001$ ) for green and red respectively. We speculate that this is due to the limited occlusion time during VOT on the large intestines; due to the need for a respiratory hold and the potential negative effects of a prolonged ischemic period of the gut we considered a 20 second period optimal. Similarly, the overshoot during gut reperfusion was attenuated in comparison to the nail fold. This may be due to the fact that the hypoxic upstream signaling pathway to the feeding artery is not stimulated to the full extent [37].

Second, the observed disparity between the LSCI values measured for both lasers must at least be partly attributable to the optical characteristics of the wavelength itself, since the same phenomenon was apparent at both anatomical sites. The difference in wavelength has implications for the penetration depth and the interaction with the optical properties of the red blood cells, as well as the surrounding tissues. Literature suggests a penetration depth of 0.4mm and 1mm respectively for green and red light [28,33,38]. This effect can be influenced by the illuminated surrounding anatomical structures. Most of the light is scattered from red blood cells when tissues are illuminated with red light, whereas most of the light is absorbed with the green laser [38].

Clearly some limitations of this study need to be addressed. As stated above, for obvious reasons the occlusion period of the large intestine could not be extended to the usual reference periods [39-42]. In contrast to the nail fold experiment, it was impossible to perform repeated measurements in the same ROI of the large intestines. The surgeons approximated the ROI to the best of their ability however, the inevitable anatomical differences did not lead to larger standard deviations compared to the nailfold experiment. Furthermore, achieving full occlusion of arterial blood flow of the large intestine is more complex than in the finger due to the rather complex nature of the collateral vasculature.



## 5 CONCLUSION

This two-center study with ten ( $n=10$ ) subjects undergoing a colonic resection illustrates that laser speckle contrast imaging is capable of identifying ischemic areas on the large intestine in a standard laparoscopic setup with a measured flow decrease of up to 10% compared to baseline level. LSCI is a fast, non-contact, full-field and cheap technique and the availability of this technique in the operating room may have many applications far beyond the setting of colonic resections. Future studies are needed to validate the additional clinical value of LSCI as a tool to reduce perioperative morbidity and mortality such as anastomotic leakage.

### ACKNOWLEDGMENTS

We would like to thank all the staff of the OR in the Medical Centre Leeuwarden. We would also like to personally thank Afonda Koop for all her help with the inclusion of the patients.



## REFERENCES

1. E.F. Midura, D. Hanseman, B.R. Davis, S.J. Atkinson, D.E. Abbott, S.A. Shah, I.M. Paquette. "Risk factors and consequences of anastomotic leak after colectomy: a national analysis," *Dis Colon Rectum*. **58**(3) 333-338 (2015).
2. P. Ambrosetti, J. Robert, P. Mathey, A. Rohner. "Left-sided colon and colorectal anastomoses: Doppler ultrasound as an aid to assess bowel vascularization. A prospective evaluation of 200 consecutive elective cases," *Int J Colorectal Dis*. **9**(4) 211-214 (1994).
3. A. Karliczek, D.A. Benaron, P.C. Baas, C.J. Zeebregts, A. van der Stoel, T. Wiggers, J.T.M. Plukker, G.M. van Dam. "Intraoperative assessment of microperfusion with visible light spectroscopy in esophageal and colorectal anastomoses," *Eur Surg Res*. **41**(3) 303-311 (2008).
4. J. Bruce, Z.H. Krukowski, G. Al-Khairy, E.M. Russell, K.G. Park. "Systematic review of the definition and measurement of anastomotic leak after gastrointestinal surgery," *Br J Surg*. **88**(9) 1157-1168 (2001).
5. A. Karliczek, D.A. Benaron, C.J. Zeebregts, T. Wiggers, G.M. van Dam. "Intraoperative ischemia of the distal end of colon anastomoses as detected with visible light spectroscopy causes reduction of anastomotic strength," *J Surg Res*. **152**(2) 288-295 (2009).
6. J. van den Bos, M. Al-Taher, R.M. Schols, S. van Kuijk, N.D. Bouvy, L.P.S. Stassen. "Near-Infrared Fluorescence Imaging for Real-Time Intraoperative Guidance in Anastomotic Colorectal Surgery: A Systematic Review of Literature," *J Laparoendosc Adv Surg Tech A*. **28**(2) 157-167 (2018).
7. H.C. Pommergaard, M.P. Achiam, J. Burcharth, J. Rosenberg. "Impaired blood supply in the colonic anastomosis in mice compromises healing," *Int Surg*. **100**(1) 70-76 (2015).
8. N.C. Buchs, P. Gervaz, M. Secic, P. Bucher, B. Mugnier-Konrad, P. Morel. "Incidence, consequences, and risk factors for anastomotic dehiscence after colorectal surgery: a prospective monocentric study," *Int J Colorectal Dis*. **23**(3) 265-270 (2008).
9. S. Nachiappan, A. Askari, A. Currie, R.H. Kennedy, O. Faiz. "Intraoperative assessment of colorectal anastomotic integrity: a systematic review," *Surg Endosc*. **28**(9) 2513-2530 (2014).
10. M. Kologlu, K. Yorganci, N. Renda, I. Sayek. "Effect of local and remote ischemia-reperfusion injury on healing of colonic anastomoses," *Surgery*. **128**(1) 99-104 (2000).
11. L.A.E. Pasma, R.P. Bleichrodt, H. van Goor, T. Hendriks. "Transient profound mesenteric ischemia strongly affects the strength of intestinal anastomoses in the rat," *Dis Colon Rectum*. **50**(7) 1070-1079 (2007).
12. J.G. Garcia, F.J. Criado, M.A. Persona, A.G. Alonso. "Healing of colonic ischemic anastomoses in the rat: role of superoxide radicals," *Dis Colon Rectum*. **41**(7) 892-895 (1998).
13. A.C. van der Ham, W.J. Kort, I.M. Weijma, H.F. van den Ingh, H. Jeekel. "Healing of ischemic colonic anastomosis: fibrin sealant does not improve wound healing," *Dis Colon Rectum*. **35**(9) 884-891 (1992).
14. A. Karliczek, N.J. Harlaar, C.J. Zeebregts, T. Wiggers, P.C. Baas, G.M. van Dam. "Surgeons lack predictive accuracy for anastomotic leakage in gastrointestinal surgery," *Int J Colorectal Dis*. **24**(5) 569-576 (2009).
15. N.H. Boyle, D. Manifold, M.H. Jordan, R.C. Mason. "Intraoperative assessment of colonic perfusion using scanning laser Doppler flowmetry during colonic resection," *J Am Coll Surg*. **191**(5) 504-510 (2000).
16. M.K. Schilling, C. Redaelli, C. Maurer, H. Friess, M.W. Büchler. "Gastric microcirculatory changes during gastric tube formation: assessment with laser Doppler flowmetry," *J Surg Res*. **62**(1) 125-129 (1996).



17. S. Kudzus, C. Roesel, A. Schachtrupp, J.J. Höer. "Intraoperative laser fluorescence angiography in colorectal surgery: a noninvasive analysis to reduce the rate of anastomotic leakage," *Langenbeck's archives of surgery*. **395**(8) 1025-1030 (2010).
18. M.D. Jafari, K.H. Lee, W.J. Halabi, S.D. Mills, J.C. Carmichael, M.J. Stamos, A. Pigazzi. "The use of indocyanine green fluorescence to assess anastomotic perfusion during robotic assisted laparoscopic rectal surgery," *Surg Endosc*. **27**(8) 3003-3008 (2013).
19. E. Klijn, S. Niehof, J. de Jonge, D. Gommers, C. Ince, J. van Bommel. "The effect of perfusion pressure on gastric tissue blood flow in an experimental gastric tube model," *Anesth Analg*. **110**(2) 541-546 (2010).
20. D.M.J. Milstein, C. Ince, S.S. Gisbertz, K.B. Boateng, B.F. Geerts, M.W. Hollmann, M.I. van Berge Henegouwen, D.P. Veelo. "Laser speckle contrast imaging identifies ischemic areas on gastric tube reconstructions following esophagectomy," *Medicine (Baltimore)*. **95**(25) e3875 (2016).
21. R. Ambrus, M. Achiam, N. Secher, M. Svendsen, K. Rünitz. "Evaluation of Gastric Microcirculation by Laser Speckle Contrast Imaging during Esophagectomy," *«J Am Coll Surg»*. **225**(2017).
22. C. Zheng, L. Wai Lau, J. Cha. "Dual-display laparoscopic laser speckle contrast imaging for real-time surgical assistance," *Biomedical Optics Express*. **9**(12) 5962-5981 (2018).
23. E.L. Towle, L.M. Richards, S.M.S. Kazmi, D.J. Fox, A.K. Dunn. "Comparison of indocyanine green angiography and laser speckle contrast imaging for the assessment of vasculature perfusion," *Neurosurgery*. **71**(5) 1023-30; discussion 1030 (2012).
24. J.D. Briers. "Laser Doppler, speckle and related techniques for blood perfusion mapping and imaging," *Physiol Meas*. **22**(4) R35-R66 (2001).
25. D.A. Boas, A.K. Dunn. "Laser speckle contrast imaging in biomedical optics," *J Biomed Opt*. **15**(1) 011109 (2010).
26. C. Stureson, D.M.J. Milstein, I.C.J.H. Post, A.M. Maas, T.M. van Gulik. "Laser speckle contrast imaging for assessment of liver microcirculation," *Microvasc Res*. **87** 34-40 (2013).
27. R. Ambrus, R.B. Strandby, L.B. Svendsen, M.P. Achiam, J.F. Steffensen, M.B. Søndergaard Svendsen. "Laser Speckle Contrast Imaging for Monitoring Changes in Microvascular Blood Flow," *Eur Surg Res*. **56**(3-4) 87-96 (2016).
28. A.K. Dunn, H. Bolay, M.A. Moskowitz, D.A. Boas. "Dynamic imaging of cerebral blood flow using laser speckle," *J Cereb Blood Flow Metab*. **21**(3) 195-201 (2001).
29. J. O'Doherty, P. McNamara, N.T. Clancy, J.G. Enfield, M.J. Leahy. "Comparison of instruments for investigation of microcirculatory blood flow and red blood cell concentration," *J Biomed Opt*. **14**(3) 034025 (2009).
30. L.M. Richards, S.M.S. Kazmi, J.L. Davis, K.E. Olin, A.K. Dunn. "Low-cost laser speckle contrast imaging of blood flow using a webcam," *Biomedical optics express*. **4**(10) 2269-2283 (2013).
31. J. David Briers. "Laser speckle contrast imaging for measuring blood flow," *Optica Applicata*. **37**(1-2) 139-152 (2007).
32. R. Bezemer, E. Klijn, M. Khalilzada, A. Lima, M. Heger, J. van Bommel, C. Ince. "Validation of near-infrared laser speckle imaging for assessing microvascular (re)perfusion," *Microvasc Res*. **79**(2) 139-143 (2010).
33. P. Avci, A. Gupta, M. Sadasivam, D. Vecchio, Z. Pam, N. Pam, M.R. Hamblin. "Low-level laser (light) therapy (LLLT) in skin: stimulating, healing, restoring," *Semin Cutan Med Surg*. **32**(1) 41-52 (2013).
34. D. Briers, D.D. Duncan, E. Hirst, S.J. Kirkpatrick, M. Larsson, W. Steenbergen, T. Stromberg, O.B. Thompson. "Laser speckle contrast imaging: theoretical and practical limitations," *J Biomed Opt*. **18**(6) 066018 (2013).



35. A. Nadort, K. Kalkman, T. Leeuwen, D. Faber. "Quantitative blood flow velocity imaging using laser speckle flowmetry," *Sci Rep*. **6**(2016).
36. C.H. Li, H.D. Wang, J.J. Hu, X.L. Ge, K. Pan, A.Q. Zhang, J.H. Dong. "The monitoring of microvascular liver blood flow changes during ischemia and reperfusion using laser speckle contrast imaging," *Microvasc Res*. **94** 28-35 (2014).
37. P. Bagher, S.S. Segal. "Regulation of blood flow in the microcirculation: role of conducted vasodilation," *Acta Physiol (Oxf)*. **202**(3) 271-284 (2011).
38. A.N. Obeid, D.M. Boggett, N.J. Barnett, G. Dougherty, P. Rolfe. "Depth discrimination in laser Doppler skin blood flow measurement using different lasers," *Med Biol Eng Comput*. **26**(4) 415-419 (1988).
39. R. Bezemer, A. Lima, D. Myers, E. Klijn, M. Heger, P.T. Goedhart, J. Bakker, C. Ince. "Assessment of tissue oxygen saturation during a vascular occlusion test using near-infrared spectroscopy: the role of probe spacing and measurement site studied in healthy volunteers," *Crit Care*. **13 Suppl 5** S4 (2009).
40. M. Hassan, T. Togawa. "Observation of skin thermal inertia distribution during reactive hyperaemia using a single-hood measurement system," *Physiol Meas*. **22**(1) 187-200 (2001).
41. D.E. Skarda, K.E. Mulier, D.E. Myers, J.H. Taylor, G.J. Beilman. "Dynamic near-infrared spectroscopy measurements in patients with severe sepsis," *Shock*. **27**(4) 348-353 (2007).
42. K.C. Doerschug, A.S. Delsing, G.A. Schmidt, W.G. Haynes. "Impairments in microvascular reactivity are related to organ failure in human sepsis," *Am J Physiol Heart Circ Physiol*. **293**(2) H1065-H1071 (2007).





