

University of Groningen

## Placental histopathology after *Coxiella burnetii* infection during pregnancy

Munster, J. M.; Leenders, A. C. A. P.; Hamilton, C. J. C. M.; Hak, E.; Aarnoudse, J. G.;  
Timmer, A.

*Published in:*  
Placenta

*DOI:*  
[10.1016/j.placenta.2011.11.012](https://doi.org/10.1016/j.placenta.2011.11.012)

**IMPORTANT NOTE:** You are advised to consult the publisher's version (publisher's PDF) if you wish to cite from it. Please check the document version below.

*Document Version*  
Publisher's PDF, also known as Version of record

*Publication date:*  
2012

[Link to publication in University of Groningen/UMCG research database](#)

*Citation for published version (APA):*

Munster, J. M., Leenders, A. C. A. P., Hamilton, C. J. C. M., Hak, E., Aarnoudse, J. G., & Timmer, A. (2012). Placental histopathology after *Coxiella burnetii* infection during pregnancy. *Placenta*, 33(2), 128-131. <https://doi.org/10.1016/j.placenta.2011.11.012>

### Copyright

Other than for strictly personal use, it is not permitted to download or to forward/distribute the text or part of it without the consent of the author(s) and/or copyright holder(s), unless the work is under an open content license (like Creative Commons).

The publication may also be distributed here under the terms of Article 25fa of the Dutch Copyright Act, indicated by the "Taverne" license. More information can be found on the University of Groningen website: <https://www.rug.nl/library/open-access/self-archiving-pure/taverne-amendment>.

### Take-down policy

If you believe that this document breaches copyright please contact us providing details, and we will remove access to the work immediately and investigate your claim.

*Downloaded from the University of Groningen/UMCG research database (Pure): <http://www.rug.nl/research/portal>. For technical reasons the number of authors shown on this cover page is limited to 10 maximum.*



## Short communication

Placental histopathology after *Coxiella burnetii* infection during pregnancyJ.M. Munster<sup>a,\*</sup>, A.C.A.P. Leenders<sup>b</sup>, C.J.C.M. Hamilton<sup>c</sup>, E. Hak<sup>d</sup>, J.G. Aarnoudse<sup>a</sup>, A. Timmer<sup>e</sup><sup>a</sup> University of Groningen, University Medical Centre Groningen, Department of Obstetrics and Gynaecology, Hanzeplein 1, 9713 GZ, Groningen, The Netherlands<sup>b</sup> Jeroen Bosch Hospital, Department of Medical Microbiology and Infection Prevention, Henri Dunantstraat 1, 5223 GZ, 's-Hertogenbosch, The Netherlands<sup>c</sup> Jeroen Bosch Hospital, Department of Obstetrics and Gynaecology, Henri Dunantstraat 1, 5223 GZ, 's-Hertogenbosch, The Netherlands<sup>d</sup> University of Groningen, University Centre for Pharmacy, PharmacoEpidemiology & PharmacoEconomics, Antonius Deusinglaan 1, 9713 AV, Groningen, The Netherlands<sup>e</sup> University of Groningen, University Medical Centre Groningen, Department of Pathology and Medical Biology, Hanzeplein 1, 9713 GZ, Groningen, The Netherlands

## ARTICLE INFO

## Article history:

Accepted 17 November 2011

## Keywords:

Q fever  
*Coxiella burnetii*  
Asymptomatic  
Placental histopathology

## ABSTRACT

Symptomatic and asymptomatic *Coxiella burnetii* infection during pregnancy have been associated with obstetric complications. We described placental histopathology and clinical outcome of five cases with asymptomatic *C. burnetii* infection during pregnancy and compared these cases with four symptomatic cases from the literature. In contrast with the symptomatic cases, we did not observe necrosis or active inflammation in the placentas of the asymptomatic women. Obstetrical outcome was more favourable in the asymptomatic cases than in the symptomatic cases. Asymptomatic and symptomatic *C. burnetii* infection during pregnancy are different entities with respect to placental histopathology and the risk of obstetric complications.

© 2011 Elsevier Ltd. All rights reserved.

## 1. Introduction

Several European countries notified increasing numbers of human Q fever since 2007 [1,2]. Q fever is a zoonosis caused by the intracellular bacterium *Coxiella burnetii*. It primarily infects ruminants and rodents, in which the infection is mainly associated with miscarriage and stillbirth [3]. Humans are predominantly infected by inhalation of contaminated aerosols [4].

Up to 90% of pregnant women with antibodies suggesting recent infection with *C. burnetii* remain asymptomatic [5]. However, symptomatic and asymptomatic *C. burnetii* infection during pregnancy have been associated with obstetric complications, including miscarriage, preterm delivery and fetal death [6,7]. Placental infection assessed by polymerase chain reaction (PCR) or culture has been strongly related to these complications [6]. However, information about placental histopathology, in particular in asymptomatic cases, is lacking. Therefore, we described placental histopathology from women with asymptomatic *C. burnetii*

infection during pregnancy. Subsequently, we compared our results with symptomatic cases described in the literature.

## 2. Patients and methods

## 2.1. Setting and participants

This study was embedded in a clustered randomised controlled trial about the effectiveness of a screening program for *C. burnetii* infection during pregnancy. In that study pregnant women living in Q fever high-risk areas in The Netherlands were serologically screened for *C. burnetii* infection. Details about the screening study are described elsewhere [8]. The study protocol was approved by the Medical Ethical Review Board of the University Medical Centre Groningen (UMCG). All participants included in this study gave written informed consent to collect and analyse placental tissue and clinical outcome data.

## 2.2. Design

From women who participated in the intervention group of the screening trial and who had serological evidence for an acute infection, placentas were collected. An acute infection was defined as the presence (cut-off titre  $\geq 1:32$ ) of immunoglobulin (Ig)M accompanied with (rising) IgG during follow-up. Serology was performed with indirect immunofluorescence assay (IFA, Focus Diagnostics, Cypress, CA, USA). Placentas were histopathologically analysed by one pathologist (AT) from the UMCG. Furthermore, *C. burnetii* specific real-time PCR was performed. Primers and probes used have been described earlier [9], other technical details are available on request.

## 2.3. Systematic review

A systematic review of the literature was done by searching PubMed and the references of the included papers following the PRISMA-guidelines. Our search was limited to human studies in English or Dutch. The search strategy was: "Q fever OR

**Abbreviations:** g, grams; IFA, indirect immunofluorescence assay; Ig, immunoglobulin; NA, not applicable; PCR, polymerase chain reaction; PPROM, preterm premature rupture of membranes; UMCG, University Medical Centre Groningen; wks, weeks; y, years.

\* Corresponding author. Tel.: +31 503613174, +31 626890978(home); fax: +31 503611806.

**E-mail addresses:** [j.munster@umcg.nl](mailto:j.munster@umcg.nl) (J.M. Munster), [a.leenders@jbz.nl](mailto:a.leenders@jbz.nl) (A.C.A.P. Leenders), [c.hamilton@jbz.nl](mailto:c.hamilton@jbz.nl) (C.J.C.M. Hamilton), [e.hak@rug.nl](mailto:e.hak@rug.nl) (E. Hak), [j.aarnoudse@inter.nl.net](mailto:j.aarnoudse@inter.nl.net) (J.G. Aarnoudse), [a.timmer@umcg.nl](mailto:a.timmer@umcg.nl) (A. Timmer).

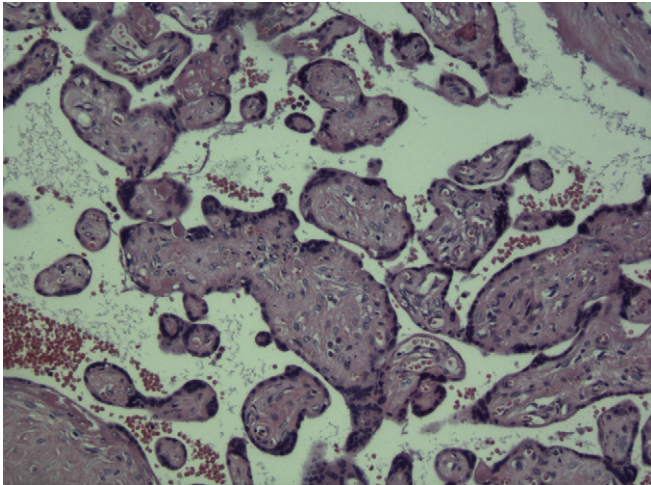
**Table 1**

Summary of patient characteristics and placental histopathology.

	Age (y)	Parity	Symptoms	Initial serological values <sup>a</sup>				Treatment	Gestational age at delivery (wks + days)	Birth weight (g/percentile)	Clinical outcome	<i>C. burnetii</i> present in placenta tissue?	Placental weight (g/percentile)	Summary of placenta histology
				IgM II	IgM I	IgG II	IgG I							
Asymptomatic patients														
1	31	0	None	1:1024	1:32	1:512	<1:32	Erythromycin	42 + 0	4030/50–80th	Arrest of second stage of labour; uncomplicated caesarean section at term	PCR negative	Unknown	No significant pathology
2	32	0	None	1:256	1:32	1:1024	1:128	Erythromycin	37 + 0	2930/50–80th	Suspicion of solution placenta at term; emergency caesarean section	PCR negative	540/75–90th	No significant pathology
3	31	0	None	1:512	1:64	1:256	<1:32	Erythromycin	34 + 1	2170/50–80th	PPROM, retained placenta, postpartum haemorrhage	PCR negative	337/10–25th	Maternal vascular underperfusion; fibromuscular hyperplasia of stemvillus vessels; scattered fibrotic villi, low grade chronic villitis (Fig. 1)
4	34	0	None	1:512	<1:32	1:128	<1:32	None	39 + 6	3535/50–80th	Uncomplicated, at term	PCR negative	425/<10th	Placental hypoplasia
5	33	1	None	1:256	<1:32	1:128	<1:32	None	40 + 2	3535/20–50th	Congenital hydronephrosis, meconium stained amniotic fluid at term	NA	528/25–50th	Low grade chronic villitis
Symptomatic cases from the literature														
1 Reich-man et al., 1988	29	2	Fever, headache, weakness, sweating, purpuric rash	1:400	1:1600	1:1600	1:400	Tetracycline	28	1000/unknown	Induced labour because of maternal illness	Immunofluorescent stain positive	Unknown	Areas of necrosis
2 Raoult et al., 1994	26	Unknown	Fever, cough	Unknown; seroconversion				Cotrimoxazole	24	Unknown	Miscarriage	Immunofluorescent stain positive	Unknown	Multiple foci of necrosis
3 Friedland et al., 1994	26	Unknown	Fever, fatigue, dyspnoea	Unknown; rising antibodies				Erythromycin postpartum	25	Unknown	Oligohydramnios, intrauterine fetal death	Immunocytochemical stain positive	Unknown	Severe necrotising villitis in 40% of the placental tissue
4 Bental et al., 1995	28	Unknown	Fever, cough, arthralgia	1:1600	1:200	1:800	1:25000	Erythromycin/rifampicin	30	1300/unknown	Premature labour, caesarean section because of transverse lie of the fetus	PCR positive	Unknown	No areas of necrosis or other gross pathology

y, years Ig, immunoglobulin wks, weeks g, grams PCR, polymerase chain reaction NA, not applicable due to PCR inhibition PPROM, preterm premature rupture of membranes.

<sup>a</sup> Serology of the asymptomatic cases was performed with indirect immunofluorescence assay (IFA, Focus Diagnostics, Cypress, CA, USA), measuring both IgM and IgG against phase I and II antigens. Serology of the symptomatic cases was performed with in-house assays.



**Fig. 1.** Hematoxylin and eosin stain of placental tissue from asymptomatic case no 3, demonstrating fibrotic chorionvilli, loss of capillaries, stromal karyorrhexis and haemorrhage (magnification 10 $\times$ ).

*C. burnetii*" AND "placenta". First we pre-screened the titles and the abstracts; afterwards the eligibility of the studies was judged by reading the full-texts. Only studies describing human placental histopathology were included.

### 3. Results

Seven of the 536 women in the intervention group of the screening trial had serological profiles suggesting an acute *C. burnetii* infection and were treated with antibiotics. Overall, five placentas were stored and sent for re-evaluation to the UMCG, including two placentas from women with follow-up serology suggesting a previous infection. All cases were asymptomatic at the moment of screening. Clinical outcome and placental histopathology are summarised in the first part of Table 1.

The PubMed search resulted in 30 hits. Only 2 papers included data on human placental histopathology and were included. Two other reports were included based on the references. All included papers concerned case-reports of symptomatic acute or chronic Q fever cases [10–13]. Clinical outcome and placental histopathology of these cases are summarised in the second part of Table 1.

### 4. Discussion

We showed that asymptomatic and symptomatic *C. burnetii* infection during pregnancy are different entities with respect to placental pathology and the risk of obstetric complications. Placental histology in the asymptomatic cases showed, in contrast with the symptomatic cases, no foci of necrosis or active inflammation. We only observed a few scattered fibrotic villi, which could be a result of interruption of fetal blood flow or destruction of capillaries due to previous villitis [14]. The presence of low grade chronic villitis is a frequent finding in third trimester placentas and probably related to a maternal immune response directed against fetal antigens inherited from the father. Until present no microbiological pathogens have been linked to chronic villitis [15]. Whether placenta hypoplasia and pathology consistent with maternal vascular underperfusion are linked to *C. burnetii* infection is to our knowledge unknown.

In none of the placentas from asymptomatic cases *C. burnetii* could be detected with PCR. Previously this also has been shown for a larger cohort of 153 asymptomatic seropositive women [7],

suggesting that the rate of placental infection during asymptomatic *C. burnetii* infection is very low.

Our findings are in line with animal studies. In cows, where Q fever is usually not clinically apparent, positive PCR on bulk tank milk is only rarely associated with histopathological inflammation of placentas [16]. On the other hand, in goats and sheep, in which *C. burnetii* infection is often associated with miscarriage and still-birth, necrotising inflammation of placental tissue is a common finding [17,18].

Various factors, including host immune response, cytokines and different strains of *C. burnetii*, have been suggested to play a role in the clinical manifestation and outcome of *C. burnetii* infection in both animals and humans, but further research is needed to find target points for prevention and treatment [18–20].

In conclusion, after asymptomatic *C. burnetii* infection during pregnancy placental examination reveals no major pathology related to previous villitis, which is associated with a favourable clinical outcome. Symptomatic infection is a different entity. Obstetric complications in these cases can very well be explained by colonisation with *C. burnetii* and massive necrosis of the placenta.

### Authors' contributions

JMM: I declare that I participated in the design of the study, performed the study, analysed and interpreted the data and drafted the manuscript; ACAPL: I declare that I participated in the study as an expert in laboratory testing and performed the serology; CJCMH: I declare that I participated in the study as an expert on obstetric care; EH: I declare that I initiated and designed the screening trial, wrote the grant application, and supervised the data collection, analysis and report; JGA: I declare that I participated in the study as an expert on obstetric care and supervised the analysis and report; AT: I declare that I performed the histopathological re-evaluation of the placentas, and supervised the analysis and report. All authors commented on the manuscript and approved the final manuscript.

### Funding

The clustered randomised controlled trial about the effectiveness of a screening program for *C. burnetii* infection during pregnancy was financed by ZonMw, The Netherlands Organization for Health Research and Development; programme "Effectiviteits- en Doelmatigheidsonderzoek" (grantnumber 125030014). The funder had no role in the study design; in the collection, analysis and interpretation of data; in the writing of the report; and in the decision to submit the article for publication.

### Conflict of interests

JGA and EH are members of the Health Council of the Netherlands on a non-profit base.

### Ethical approval

The study was conducted according to the principles of the Declaration of Helsinki. The study protocol of the randomised controlled trial about the effectiveness of a screening program for *C. burnetii* infection during pregnancy was approved by the Medical Ethical Review Board of the University Medical Centre Groningen (number 2009.323). Written informed consent was obtained from all participants before placentas were collected and analysed.

## Acknowledgements

The authors gratefully thank all midwives, residents, obstetricians, medical microbiologists and pathologists of the participating centres for their help in patient recruitment, and data and placenta collection.

## References

- [1] Roest HI, Tilburg JJ, Van der Hoek W, Vellema P, Van Zijderveld FG, Klaassen CHW, et al. The Q fever epidemic in The Netherlands: history, onset, response and reflection. *Epidemiol Infect* 2011;139:1–12.
- [2] European Centre for Disease Prevention and Control (ECDC). Annual epidemiological report on communicable diseases in Europe 2010. [[http://www.ecdc.europa.eu/en/publications/Publications/1011\\_SUR\\_Annual\\_Epidemiological\\_Report\\_on\\_Communicable\\_Diseases\\_in\\_Europe.pdf](http://www.ecdc.europa.eu/en/publications/Publications/1011_SUR_Annual_Epidemiological_Report_on_Communicable_Diseases_in_Europe.pdf)] Last accessed September 7, 2011.
- [3] Hartzell JD, Wood-Morris RN, Martinez LJ, Trotta RF. Q fever: epidemiology, diagnosis and treatment. *Mayo Clin Proc* 2008;83:574–9.
- [4] Parker NR, Barralet JH, Bell AM. Q fever. *Lancet* 2006;367:679–88.
- [5] Tissot-Dupont H, Vaillant V, Rey S, Raoult D. Role of sex, age, previous valve lesion and pregnancy in the clinical expression and outcome of Q fever after a large outbreak. *Clin Infect Dis* 2007;44:232–7.
- [6] Carcopino X, Raoult D, Bretelle F, Boubli L, Stein A. Managing Q fever during pregnancy: the benefits of long-term cotrimoxazole therapy. *Clin Infect Dis* 2007;45:548–55.
- [7] Langley JM, Marrie TJ, Le Blanc JC, Almudevar A, Resch L, Raoult D. Coxiella burnetii seropositivity in parturient women is associated with adverse pregnancy outcomes. *Am J Obstet Gynecol* 2003;189:228–32.
- [8] Munster JM, Leenders ACAP, Van der Hoek W, Schneeberger PM, Rietveld A, Riphagen-Dalhuisen J, et al. Cost-effectiveness of a screening strategy for Q fever among pregnant women in risk areas: a clustered randomized controlled trial. *BMC Women's Health* 2010;10:32.
- [9] Schneeberger PM, Hermans MH, van Hannen EJ, Schellekens JJ, Leenders AC, Wever PC. Real-time PCR with serum samples is indispensable for early diagnosis of acute Q fever. *Clin Vaccine Immunol* 2010;17:286–90.
- [10] Riechman N, Raz R, Keysary A, Goldwasser R, Flatau E. Chronic Q fever and severe thrombocytopenia in a pregnant woman. *Am J Med* 1988;85:253–4.
- [11] Raoult D, Stein A. Q fever during pregnancy – a risk for women, fetuses, and obstetricians. *N Engl J Med* 1994;330:371.
- [12] Friedland JS, Jeffrey I, Griffin GE, Booker M, Courtenay-Evans R. Q fever and intrauterine death. *Lancet* 1994;343:288.
- [13] Bental T, Fejgin M, Keysary S, Rzotkiewicz S, Oron C, Nachum R, et al. Chronic Q fever of pregnancy presenting as Coxiella burnetii placentitis: successful outcome following therapy with erythromycin and rifampin. *Clin Infect Dis* 1995;21:1318–21.
- [14] Redline RW, Ariel I, Baergen RN, Desa DJ, Kraus FT, Roberts DJ, et al. Fetal vascular obstructive lesions: nosology and reproducibility of placental reaction patterns. *Pediatr Dev Pathol* 2004;7:443–52.
- [15] Redline RW. Villitis of unknown etiology: noninfectious chronic villitis in the placenta. *Hum Pathol* 2007;38:1439–46.
- [16] Hansen MS, Rodolakis A, Cochonneau D, Agger JF, Christoffersen AB, Jensen TK, et al. Coxiella burnetii associated placental lesions and infection level in parturient cows. *Vet J*; 2011 Feb 1 [Epub ahead of print].
- [17] Woude W, Dercksen DP. Abortion and stillbirth among dairy goats as a consequence of Coxiella burnetii. *Tijdschr Diergeneeskd* 2007;132:908–11 [In Dutch with abstract in English].
- [18] Van Moll P, Baumgärtner W, Eskens U, Hänichen T. Immunocytochemical demonstration of Coxiella burnetii antigen in the fetal placenta of naturally infected sheep and cattle. *J Comp Pathol* 1993;109:295–301.
- [19] Klaassen CH, Nabuurs-Franssen MH, Tilburg JJ, Hamans MA, Horrevorts AM. Multigenotype Q fever outbreak, the Netherlands. *Emerg Infect Dis* 2009;15:613–4.
- [20] Andoh M, Zhang G, Russell-Lodrigue KE, Shive HR, Weeks BR, Samuel JE. T cells are essential for bacterial clearance, and gamma interferon, tumor necrosis factor alpha, and B cells are crucial for disease development in Coxiella burnetii infection in mice. *Infect Immun* 2007;75:3245–55.