

University of Groningen

## Timing of diagnosis of fetal structural abnormalities after the introduction of universal cell-free DNA in the absence of first-trimester anatomical screening

Bardi, Francesca; Beekhuis, Anne Marie; Bakker, Marian K.; Elvan-Taşpınar, Ayten; Bilardo, Caterina Maddalena

*Published in:*  
Prenatal Diagnosis

*DOI:*  
[10.1002/pd.6224](https://doi.org/10.1002/pd.6224)

**IMPORTANT NOTE: You are advised to consult the publisher's version (publisher's PDF) if you wish to cite from it. Please check the document version below.**

*Document Version*  
Publisher's PDF, also known as Version of record

*Publication date:*  
2022

[Link to publication in University of Groningen/UMCG research database](#)

### *Citation for published version (APA):*

Bardi, F., Beekhuis, A. M., Bakker, M. K., Elvan-Taşpınar, A., & Bilardo, C. M. (2022). Timing of diagnosis of fetal structural abnormalities after the introduction of universal cell-free DNA in the absence of first-trimester anatomical screening. *Prenatal Diagnosis*, 42(10), 1242-1252. <https://doi.org/10.1002/pd.6224>

### **Copyright**

Other than for strictly personal use, it is not permitted to download or to forward/distribute the text or part of it without the consent of the author(s) and/or copyright holder(s), unless the work is under an open content license (like Creative Commons).

The publication may also be distributed here under the terms of Article 25fa of the Dutch Copyright Act, indicated by the "Taverne" license. More information can be found on the University of Groningen website: <https://www.rug.nl/library/open-access/self-archiving-pure/taverne-amendment>.

### **Take-down policy**

If you believe that this document breaches copyright please contact us providing details, and we will remove access to the work immediately and investigate your claim.

Downloaded from the University of Groningen/UMCG research database (Pure): <http://www.rug.nl/research/portal>. For technical reasons the number of authors shown on this cover page is limited to 10 maximum.

# Timing of diagnosis of fetal structural abnormalities after the introduction of universal cell-free DNA in the absence of first-trimester anatomical screening

Francesca Bardi<sup>1</sup>  | Anne Marie Beekhuis<sup>1</sup> | Marian K. Bakker<sup>1</sup>  |  
Ayten Elvan-Taşpınar<sup>1</sup> | Caterina Maddalena Bilardo<sup>2</sup>

<sup>1</sup>Department of Obstetrics and Gynecology, University Medical Center Groningen, University of Groningen, Groningen, The Netherlands

<sup>2</sup>Department of Obstetrics and Gynecology, Amsterdam University Medical Centers, Amsterdam, The Netherlands

## Correspondence

Francesca Bardi, Fetal Medicine Unit, Department of Obstetrics & Gynecology, University Medical Center Groningen (UMCG), University of Groningen, Hanzeplein 1, Groningen 9700 RB, The Netherlands.  
Email: [f.bardi@umcg.nl](mailto:f.bardi@umcg.nl)

## Abstract

**Introduction:** Since 2021, first-trimester anatomical screening (FTAS) is offered in the Netherlands alongside genome-wide cell-free DNA (cfDNA). Previously, only second-trimester anatomical screening (STAS) was offered. This study identifies structural abnormalities amenable to first-trimester diagnosis detected at/after STAS in the period following cfDNA implementation and preceding FTAS introduction.

**Methods:** This retrospective cohort includes 547 fetuses referred between 2017 and 2020 because of suspected structural abnormalities before/at/after STAS. Additional prenatal investigations and postnatal follow-up were searched. Abnormalities were classified into “always”, “sometimes”, and “never” detectable in the first-trimester based on a previously suggested classification.

**Results:** Of the 547 pregnancies, 13 (2.6%) received FTAS and 534 (97.6%) received a dating ultrasound and STAS. In 492/534 (92.1%) anomalies were confirmed; 66 (13.4%) belonged to the “always detectable” group in the first trimester, 303 (61.6%) to the “sometimes detectable”, and 123 (25.0%) to the never detectable. Of the “always detectable” anomalies 29/66 (44%) were diagnosed during dating ultrasounds and 37 (56%) during STAS. The rate of termination of pregnancy for anomalies detected during FTAS and at/after STAS was 84.6% ( $n = 11/13$ ) and 29.3% ( $n = 144/492$ ) ( $p < 0.01$ ).

**Conclusion:** When FTAS is not part of screening paradigms, most fetal anomalies remain undetected until the second trimester or later in pregnancy, including 56% of anomalies “always detectable” in the first trimester.

## Key points

### What's already known about this topic?

- About one-third of all prenatally detectable fetal congenital abnormalities can be diagnosed in the first trimester of pregnancy. Especially major and lethal defects are amenable to early diagnosis.

This is an open access article under the terms of the Creative Commons Attribution-NonCommercial License, which permits use, distribution and reproduction in any medium, provided the original work is properly cited and is not used for commercial purposes.

© 2022 The Authors. Prenatal Diagnosis published by John Wiley & Sons Ltd.

**What does this study add?**

- This study shows the evident delay in the timing of diagnosis of fetal structural abnormalities when first-trimester anatomical screening (FTAS) is not routinely offered. The findings of this study strongly support the implementation of a regulated FTAS program in addition to universal screening by cell-free DNA.

## 1 | INTRODUCTION

The world of prenatal screening is rapidly evolving and cell-free DNA (cfDNA) is already widely used to screen for trisomy 21, 18, 13, and, less often, for sex-chromosome aberrations.<sup>1</sup> In 2017, the Netherlands was the first country to implement genome-wide cfDNA as a first-tier screening test for fetal chromosomal abnormalities.<sup>2</sup> With the introduction of cfDNA, the overall national uptake of first-trimester screening increased from 32% to 45% with only 2% of women choosing for the combined test (CT).<sup>3,4</sup> Although the official purpose of the CT was aneuploidy screening rather than the detection of structural abnormalities, previous studies showed that about one-fourth of fetal structural abnormalities can already be seen during nuchal translucency (NT) measurement.<sup>5,6</sup> The dramatic drop in the number of CTs and contemporary lack of an alternative first-trimester anatomical screening (FTAS) meant that in the Netherlands, besides a dating ultrasound at around 10 weeks of gestation, the first fetal anatomical assessment took place at 18–20 weeks, at the time of second-trimester anatomical screening (STAS). Meanwhile, there has been growing evidence on the effectiveness of FTAS and on women's attitude regarding early diagnosis of structural anomalies.<sup>7–9</sup> Hence, the Dutch minister of health has granted permission to introduce FTAS next to cfDNA in research setting from September 2021.<sup>10</sup> If the study proves that FTAS is effective in detecting severe anomalies at a low false positive rate and women's attitude is favorable, a conclusive decision on the offer of FTAS as an integral part of the prenatal screening program will be taken. Awaiting these results, this study was designed to assess the gestational age (GA) at diagnosis of fetal structural anomalies referred to our unit, in order to identify which anomalies detected by STAS could have theoretically been diagnosed in the first trimester, had FTAS been offered to all women in this cohort.

## 2 | METHODS

### 2.1 | Prenatal screening in the Netherlands

Prenatal screening was introduced in the Netherlands in 2007. The screening paradigm included the CT, with maternal serum biochemistry (PAPP-A and b-hCG) plus NT measurement, as screening for chromosomal abnormalities, and STAS for structural anomalies. Both ultrasounds were performed in first-line extra-mural ultrasound clinics by trained sonographers. Only women with a high

a priori risk of fetal anomalies were offered a protocolled FTAS at the Fetal Medicine Unit (FMU) to exclude (re-)occurrence of fetal anomalies. Because of the dramatic drop in first-trimester ultrasounds, following the replacement of the CT by cfDNA, only very few women received a scan between 11 and 14 weeks. Next to STAS, a dating ultrasound with CRL-measurement, usually performed at about 10–11 weeks of gestation, is offered to all pregnant women. Occasionally, during these examinations, obvious ultrasound abnormalities are observed and women are referred to a FMU for further investigations.

### 2.2 | Study design

This retrospective observational study includes data from pregnant women referred to the FMU of the University Medical Center of Groningen between 2017 and 2020. All women in the cohort were referred for an advanced anatomical survey due to suspicion of fetal structural abnormalities on ultrasound following either the early dating ultrasound, FTAS or STAS. FTAS was only performed in women with a high a priori risk of congenital anomalies, based on the following indications:

- Monochorionic twin pregnancy (or multiple pregnancy with more than two fetuses).
- First-degree relative of the fetus (including siblings from previous pregnancies) with structural abnormalities.
- Two second-degree or other, further relatives with a comparable abnormality in the same bloodline. The indication is determined after consultation with a clinical geneticist.
- Preexisting diabetes mellitus or diabetes mellitus diagnosed in the first trimester.
- High Titer thyroid stimulating hormone Receptor Antibodies.
- Use of teratogenic medication or stimulants.
- High radiation exposure >0.50 Gy (Link Centers for Disease control<sup>20</sup>).

For all cases, information on additional examinations, invasive testing, and pregnancy outcome was collected. Postpartum follow-up was obtained for each case to confirm the diagnosis. In cases of elective termination of pregnancy (TOP), intrauterine fetal death or stillbirth, post-mortem examination was performed to verify the prenatal findings. The time of diagnosis was defined as the GA at the earliest advanced ultrasound during which fetal structural abnormalities were seen.

## 2.3 | Exclusion criteria

Cases referred for an advanced anatomical survey due to an abnormal cfDNA result or increased risk at the CT based on biochemical serum markers (with normal NT) were excluded. Also, pregnancies referred in view of suspicion of anomalies detected at gender-revealing ultrasounds performed by sonographers in private practices were excluded. Variants of normal anatomy such as persistent left superior vena cava and cavum veli interpositi and isolated soft markers such as increased NT ( $\geq$ P95–P99), abnormal flow in the ductus venosus, hypoplastic or absent nasal bone, single umbilical artery, echogenic bowel, mild pyelectasis, mild ventriculomegaly, femur or humerus length  $<$ P2.3, and plexus choroid cysts were also excluded. Isolated cardiac arrhythmias without underlying cardiac defect were also excluded. Some referrals occurred after a so-called “gender revealing ultrasound” performed usually at around 16 weeks. As this ultrasound which does not belong to routine investigations is performed without a protocol and happens outside the pregnancy care/screening, these cases were excluded as well. After application of the exclusion criteria, a total of 547 pregnancies were included in the study.

## 2.4 | Imaging protocol

First-trimester anatomical screening in view of an increased risk of congenital anomalies was performed at the University Medical Center of Groningen following a structured imaging protocol shown in Table S1. All FTAS were performed transabdominally by FMF-certified fetal medicine specialists and, when required, completed by transvaginal ultrasonography. STAS was performed in extramural ultrasound practices by sonographers who were certified to perform STAS in the Netherlands. The anatomical protocol of STAS can also be found in Table S1. Quality control of STAS is regulated by national guidelines and all sonographers performing STAS need to meet pre-defined quality standards including the successful completion of a theoretical and practical educational module and a minimum number of examinations performed each year.

## 2.5 | Classification of abnormalities

Timing of detection of fetal abnormalities was divided into two groups depending on whether they were diagnosed in pregnancies in which FTAS was performed or not. Also, all abnormalities were classified based on the affected organ systems into the following groups: central nervous system, facial, thoracic, abnormalities, gastro-intestinal, abdominal wall, genitourinary, skeletal/limbs abnormalities, other abnormalities, and multiple congenital abnormalities (MCA). Cases with two structural abnormalities were classified based on the most severe one. Cases with more than two structural abnormalities in at least two different organ systems were labeled as MCA. Ventriculomegaly was included as a structural abnormality

when the atrial width was 10 mm or more during the second trimester. Microcephaly was included when the head circumference was  $<$ P2.3. Hydronephrosis was included in case of pelvicalyceal dilatation with an anteroposterior (AP) diameter of 10 mm or more in the second trimester and an AP diameter of 15 mm or more in the third trimester. An absent stomach on multiple ultrasounds was labeled as esophageal atresia and an evident double bubble was labeled as duodenal atresia. Finally, diagnosed fetal abnormalities were classified into three groups depending on whether they were “always”, “sometimes”, or “never” detectable in the first trimester, according to the classification suggested by Syngelaki and colleagues.<sup>9</sup> Cases with MCA were labeled as “always detectable” when at least one of the abnormalities belonged to the group of abnormalities “always detectable” in the first trimester, as “sometimes detectable” when at least one abnormality belonged to the group of abnormalities “sometimes detectable” in the first trimester and as “never detectable” if none of the abnormalities could have been detected in the first trimester. We defined as transient or false-positives all cases of structural abnormalities documented at advanced anatomical surveys, but not confirmed at a later ultrasound scans and/or postpartum. In all these cases, neonatal follow-up was searched. In particular, we collected information on cerebral ultrasound and/or MRI for CNS abnormalities, renal ultrasound and renal function assessment for all renal abnormalities, echocardiography for cardiac abnormalities, and investigations by a clinical geneticist including postnatal QF-PCR, array-CHG, and targeted sequencing.

## 2.6 | Data analysis

Data used in this study were collected using the clinical ultrasound software Astraia GmbH and electronic patient dossiers (EPIC). All clinical data were exported into a research database. Descriptive and comparative statistical analyses were performed using SPSS version 27 (IBM-Corporation).

## 3 | RESULTS

During the inclusion period, a total of 1178 pregnant women underwent advanced fetal anatomical assessment by ultrasound at the University Medical Center of Groningen due to the suspicion of fetal abnormalities. First, 59 (5.0%) cases referred in view of high risk at the CT or at cfDNA were excluded. Secondly, another 544 (46.2%) cases with isolated soft markers were also excluded. Additionally, 28 (2.4%) cases with suspected anomalies referred following a gender-revealing ultrasound in private practices were excluded as well. Structural abnormalities were confirmed in 547 cases with complete postnatal follow-up. Mean maternal age was  $29 \pm 5.3$  years, median BMI was  $25.1 \text{ kg/m}^2$  (IQR 21.4–27.6), and mean GA at the advanced anatomical survey was  $21.4 \pm 5.4$  weeks. FTAS was performed in 13 (2.4%) pregnancies, while in the remaining 534 (97.6%) only the dating ultrasound scan and STAS were performed (Figure 1).

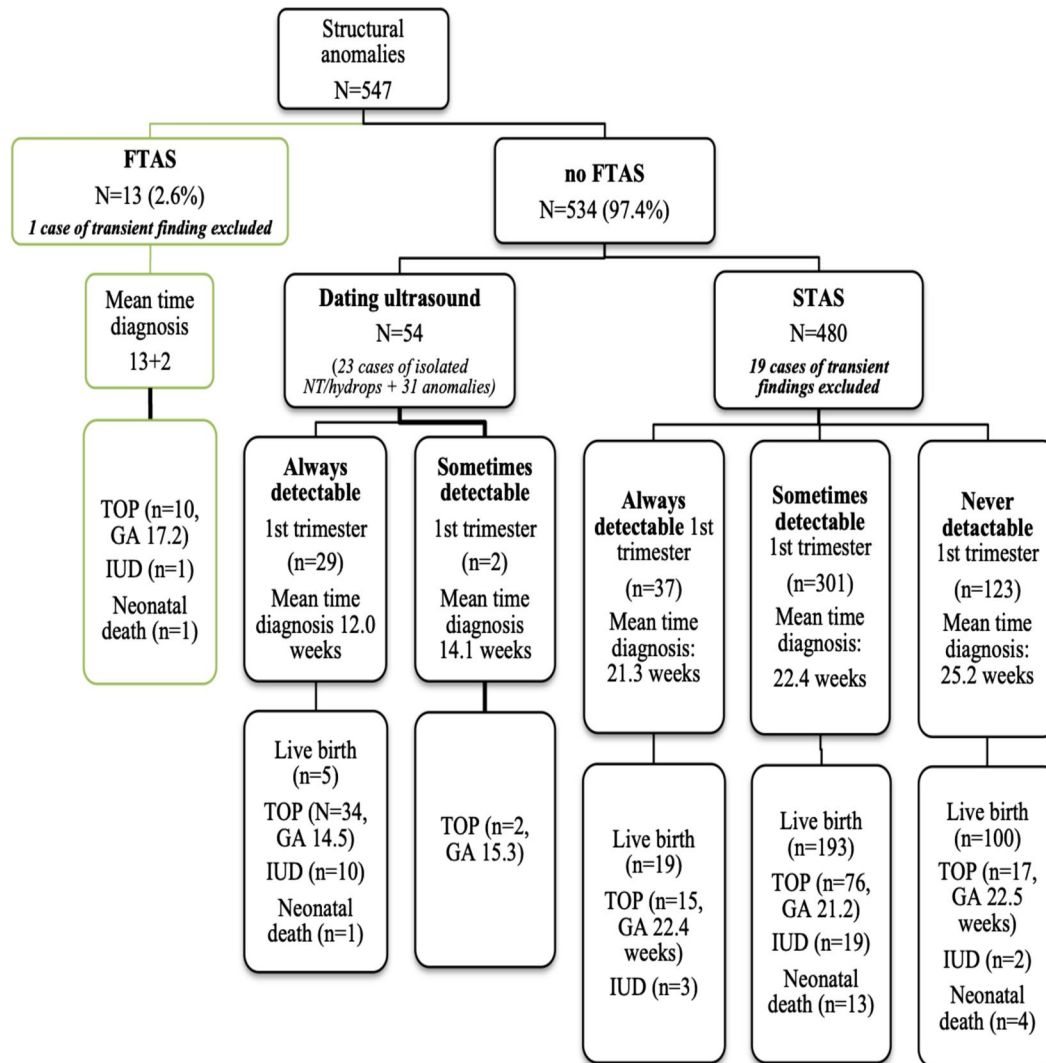


FIGURE 1 Study population with time of referral to the FMU, diagnosed structural abnormalities, and pregnancy outcomes. FMU, Fetal Medicine Unit; FTAS, first-trimester anatomical screening; GA, gestational age; STAS, second-trimester anatomical screening; TOP, termination of pregnancy

### 3.1 | Fetal abnormalities in pregnancies with FTAS

FTAS was performed in 13 (2.4%) high-risk pregnancies at the FMU. Anomalies were confirmed in 12 fetuses, presented in Table 1. In the remaining case, transient findings of generalized edema resolved and the fetus was healthy. In 11/12 pregnancies (91.7%) fetal anomalies were suspected during FTAS and the final diagnosis was made in the (late) first trimester. Only in one (8.3%) pregnancy the definite diagnosis of MCA was made after STAS, at 19.4 weeks. However, the first suspicion of anomalies occurred at 13.2 weeks when an increased NT was seen during FTAS. The multiple congenital anomalies in this case were micrognathia, Blake's pouch cyst, and right aortic arch. In 4/12 (33.3%) cases the anomalies detected during FTAS belonged to the group "always detectable" in the first trimester (3 cases of anencephaly and 1 MCA) and in the remaining 8/12 (66.6%) to the "sometimes detectable" group (1 case of spina bifida, 1 cheilopalatoschisis, 3 cardiac defects, 1 suspected intra-abdominal cyst, and 1 MCA) (Table 1).

### 3.2 | Fetal abnormalities detected when FTAS was not performed

In 534 (97.6%) pregnancies FTAS was not performed. These pregnancies only received a dating ultrasound and FTAS. In 23 (4.3%) fetuses isolated enlarged NT (with or without generalized edema) was seen during pregnancy. These cases were referred at the dating ultrasound at a mean GA of 12.1 weeks. Additionally, in 19 (3.6%) pregnancies other transient findings resolved during pregnancy. In the remaining 492 (92.1%) fetuses structural anomalies were confirmed. In total, in pregnancies that did not receive FTAS (dating ultrasound + STAS together), 66 (13.4%) anomalies belonged to the group "always detectable" in the first trimester, 303 (61.6%) to the "sometimes detectable", and 123 (25.0%) to the "never detectable" group (Table 2).

A minority of these cases ( $n = 31$ , 6.3%) were referred in view of fetal abnormalities suspected at the dating ultrasound (mean GA at

TABLE 1 Diagnosis of fetal structural abnormalities by advanced ultrasonography in pregnancies in which FTAS was performed

Structural abnormality	Cases detected n (%)	Time at definitive diagnosis (weeks)	Detectable 1st trimester <sup>a</sup>
Central nervous system	4		
Acrania/anencephaly	3	12.6	Y
Spina bifida	1	12.8	S
Face	1		
Cheilopalatoschisis	1	14.2	S
Heart	4		
Hypoplastic left heart syndrome	1	16.0	S
Atrioventricular septal defect <sup>c</sup>	2	13.2	S
Tetralogy of Fallot <sup>b</sup>	1	12.6	S
Gastro-intestinal tract	1		
Intra-abdominal cyst <sup>d</sup>	1	13.2	S
Multiple congenital abnormalities			
Clubfoot, scoliosis, Blake's pouch cyst	1	14.3	Y
Micrognathia, right aortic arch, Blake's pouch cyst**	1	19.4	S
Total	12		4 (Y) 8 (S)

Note: This table does not include 1 case with transient finding of generalized edema. S (sometimes): indicates abnormalities that are sometimes detectable in the first trimester.

Abbreviation: FTAS, first-trimester anatomical screening.

<sup>a</sup>Y (yes): indicates abnormalities that are always detectable in the first trimester.

<sup>b</sup>One case of Tetralogy of Fallot confirmed at 19 weeks +5 days. First suspicion during FTAS at 12 weeks + 5 days by generalized edema and suspicion of ventricular septal defect and pulmonary stenosis.

<sup>c</sup>One case of FTAS generalized edema and increased NT. At 20 weeks diagnosis of complex cor vitium (hypoplastic right heart with absent right atrioventricular connection).

<sup>d</sup>On ultrasound at 13.2 weeks fluid collection in the abdomen. Diagnosis of intra-abdominal cyst confirmed at 18 weeks.

referral: 11.4 weeks). Of these 31 cases, 29 (93.5%) were classified as “always detectable” (5 cases of anencephaly, 1 case of holoprosencephaly, 6 cases of omphalocele, 4 cases of gastroschisis, 6 cases of megacystis, 1 body-stalk anomaly, 1 Pentalogy of Cantrell, 1 omphalocele-exstrophy-imperforated anus-spinal defects (OEIS-complex), and 4 cases of MCA) and the other 2 (6.5%) as “sometimes detectable” (both cases of MCA).

All remaining anomalies ( $n = 461$ , 93.7%) were suspected at or after STAS. Mean GA at diagnosis in this group was 22.8 weeks (SD 4.1). A total of 37 (8.0%) belonged to the group of abnormalities “always detectable” in the first trimester and were diagnosed at a GA of 21.4 (SD 3.2) (3 cases of anencephaly, 1 case of holoprosencephaly, 4 cases of encephalocele, 3 cases of tricuspid atresia, 4 cases of pulmonary atresia, 7 cases of omphalocele, 5 cases of gastroschisis, one megacystis, one body-stalk anomaly, and 8 cases of MCA). Also, 301 (65.3%) abnormalities belonged to the first trimester “sometimes detectable” group and were diagnosed at a mean 22.4 weeks (SD 3.3). These were mainly cardiac abnormalities ( $n = 141$ , 46.8%) and skeletal abnormalities ( $n = 46$ , 15.3%). Moreover, we also diagnosed 47 (15.6%) cases of renal abnormalities, 2 (0.7%) cases of bladder exstrophy, 19 (6.3%) cases of CNS abnormalities, 12 (4.0%) cases of facial abnormalities, 11 (3.6%) cases of

thoracic abnormalities, 10 (3.3%) cases of generalized edema, 12 (4.0%) cases of MCA, and 1 (0.3%) tumor. Finally, 123 (26.6%) of the abnormalities diagnosed following the STAS belonged to the “never detectable” group in the first trimester (Tables 2 and 3). Abnormalities were referred and diagnosed at later ultrasound examinations (mean GA 25.3 weeks, SD 4.9).

### 3.3 | Transient findings

In the cohort 20 (3.6%) diagnosis appeared to be transient findings that were not confirmed at follow-up ultrasound or after birth. Except for one case of generalized edema detected at 13.3 weeks, all other cases were diagnosed in the second or third trimester (Table 4).

### 3.4 | Pregnancy outcome

A total of 11/13 (84.6%) pregnancies that had undergone FTAS were terminated. The TOP rate was 144/492 (29.3%) for pregnancies that did not undergo FTAS. This difference was statistically significant ( $p < 0.01$ ). In the group of pregnancies referred after the dating

TABLE 2 Diagnosis of fetal structural abnormalities by advanced ultrasonography in pregnancies in which FTAS was not performed

Structural abnormality	Tot cases detected n (%)	Time at definitive diagnosis (weeks)	Type of scan at suspicion, n (%)		Detectable 1st trimester
			Dating ultrasound	STAS	
Central nervous system	50				
Acrania/anencephaly	8	14.6	5	3	Y
Holoprosencephaly	2	16.6	1	1	Y
Encephalocele	4	20.6	-	4	Y
Spina bifida	14	20.6	-	14	S
Hydrocephaly	4	24.5	-	4	S
Hypoplastic cerebellum	1	21.1	-	1	S
Corpus callosum agenesis	9	21.8	-	9	N
Ventriculomegaly	4	25.9	-	4	N
Arachnoid cyst (midline cyst)	2	29.1	-	2	N
Blake's pouch cysts	1	23.0	-	1	N
Microcephaly	1	20.3	-	1	N
Face	31				
Cheilopalatoschisis	11	20.6	-	11	S
Cheiloschisis	17	22.8	-	17	N
Micrognathia/rethrogathia	1	19.0	-	1	S
Anophtalmia/microphtalmia	2	23.0	-	2	N
Thorax	19				
Diaphragmatic hernia	11	21.9	-	11	S
Congenital pulmonary airway malformation	7	23.2	-	7	N
Mediastinal cyst	1	22.3	-	1	N
Heart	174				
Tricuspid atresia	3	21.1	-	3	Y
Pulmonary atresia	4	23.3	-	4	Y
Hypoplastic left heart syndrome	15	21.0	-	15	S
AVSD	17	21.4	-	17	S
Complex heart defect	33	22.6	-	33	S
Tetralogy of Fallot	26	22.0	-	26	S
Aortic coarctation	6	22.6	-	6	S
Transposition of the great arteries	17	22.0	-	17	S
Dextrocardia	1	18.7	-	1	S
Situs inversus	1	21.1	-	1	S
Cardiomegaly	2	25.6	-	2	S
Double/right aortic arch	15	21.4	-	15	S
Common arterial trunk	8	21.6	-	8	S
Aortic stenosis	6	23.4	-	6	N
Pulmonary stenosis	2	20.2	-	2	N
Rhabdomyoma	2	27.9	-	2	N
VSD	16	24.1	-	16	N

TABLE 2 (Continued)

Structural abnormality	Tot cases detected n (%)	Time at definitive diagnosis (weeks)	Type of scan at suspicion, n (%)		
			Dating ultrasound	STAS	Detectable 1st trimester
Gastro-intestinal tract	17				
Hepatic, splenic or adrenal cyst	4	30.2	-	4	N
Esophageal atresia	7	26.1	-	7	N
Duodenal atresia	6	33.0	-	6	N
Abdominal wall	24				
Omphalocele with bowel and/or liver	13	17.9	6	7	Y
Gastroschisis	9	18.4	4	5	Y
Bladder exstrophy	2	21.4	-	2	S
Genitourinary	81				
Megacystis	7	13.6	6	1	Y
Lower urinary tract obstruction	2	27.6	-	2	S
Bilateral renal agenesis	3	20.2	-	3	S
Bilateral polycystic kidneys	1	19.7	-	1	S
Unilateral pelvic kidney/agenesis	14	22.6	-	14	S
Duplex kidney	27	26.5	-	27	S
Multicystic kidney unilateral	6	22.6	-	6	N
Multicystic kidney bilateral	1	24.3	-	1	N
Severe hydronephrosis	15	27.6	-	15	N
Ovarian cyst	1	33.1	-	1	N
Ambiguous genitalia	3	23.1	-	3	N
Renal hypoplasia unilateral	1	32.0	-	1	N
Skeleton	52				
Reduction defect (absent arm, hand, leg or foot)	2	20.4	-	2	S
Polydactyly	3	22.2	-	3	S
Hemivertebrae/scoliosis	1	29.3	-	1	S
Club foot	40	21.3	-	40	S
Nonlethal skeletal dysplasia	6	24.3	-	6	N
Tumor	2				
Sacrococcygeal teratoma	1	21.3	-	1	S
Lymphangioma	1	35.6	-	1	N
Other	16				
Body-stalk anomaly	2	15.9	1	1	Y
Pentalogy of cantrell	1	11.7	1	-	Y
OEIS complex	2	13.4	1	1	Y
Generalized edema/Hydrops	10	23.9	-	10	S
Fetal neck mass	1	26.7	-	1	N
Multiple congenital abnormalities	26				
Holoprosencephaly, abnormal position of the fingers, unspecified heart defect	1	12.7	1	-	Y

(Continues)



TABLE 2 (Continued)

Structural abnormality	Tot cases detected n (%)	Time at definitive diagnosis (weeks)	Type of scan at suspicion, n (%)		
			Dating ultrasound	STAS	Detectable 1st trimester
Omphalocele, anophthalmia, hydrocephalus, unilateral renal agenesis	1	11.7	1	-	Y
Omphalocele, kyphosis, skeletal dysplasia	1	10.3	1	-	Y
Omphalocele, abnormal digits, spina bifida	1	11.9	1	-	Y
Cheiloschisis, midline cyst, hypoplastic cerebellum, generalized edema	1	13.6	1	-	S
Unilateral renal agenesis, complex heart defect, abnormal fingers	1	14.7	1	-	S
Holoprosencephaly, anophthalmia, AVSD	1	19.9	-	1	Y
Tricuspid atresia, micrognathia, clubfeet, polydactyly	1	21.1	-	1	Y
Holoprosencephaly, AVSD, horseshoe kidney, microcephaly	1	19.6	-	1	Y
Omphalocele, abnormal positioning fingers, clubfeet, AVSD	1	21.6	-	1	Y
Holoprosencephaly, cleft lip, microcephaly, polydactyly	1	20.4	-	1	Y
Holoprosencephaly, common arterial trunk, cleft lip	1	20.4	-	1	Y
Holoprosencephaly, complex heart defect, cleft lip, abnormal fingers (unspecified)	1	21.6	-	1	Y
Holoprosencephaly, encephalocele, cleft lip	1	19.7	-	1	Y
Complex heart defect, unilateral renal agenesis, agenesis of the corpus callosum	1	32.1	-	1	S
Dolichocephaly, clubfeet, cardiomegaly	1	21.9	-	1	S
Diaphragmatic hernia, cheilopalatoschisis, horseshoe kidney	1	21.0	-	1	S
Complex heart disease, cheilopalatoschisis, esophageal atresia	1	22.0	-	1	S
Hypoplastic vermis, AVSD, abnormal positioning fingers	1	21.3	-	1	S
Complex heart defect, cheiloschisis, ambiguous genitalia	1	20.3	-	1	S
Pelvic kidney/agenesis, dextrocardia, polydactyly, agenesis right lung	1	20.7	-	1	S
Severe ventriculomegaly, micrognathia, AVSD	1	19.7	-	1	S
VSD, clubfeet, abnormal digital positioning, dolichocephaly	1	20.4	-	1	S
Ventriculomegaly, cheiloschisis, double outlet right ventricle, esophageal atresia	1	19.6	-	1	S
Renal agenesis, clubfeet, esophageal atresia	1	20.9	-	1	S
Lung hypoplasia, VSD, microphtalmia	1	20.7	-	1	N
Total	492		31 (6.3)	461 (93.7)	66 (Y)
			29 (Y)	37 (Y)	303 (S)
			2 (S)	301 (S)	123 (N)
				123 (N)	

Abbreviations: AVSD, atrioventricular septal defect; FTAS, first-trimester anatomical screening; OEIS, omphalocele-exstrophy-imperforated anus-spinal defects; STAS, second-trimester anatomical screening; VSD, ventricular septal defect.

TABLE 3 Moment of diagnosis of structural anomalies related to their detectability in the first trimester of pregnancy

Type of anomaly	Total (n, %)	Dating ultrasound	FTAS	STAS	After STAS
Always detectable	70 <sup>a</sup> (13.9)	29 (41.4)	4 (5.7)	37 (52.8)	-
Sometimes detectable	311 (61.7)	2 (0.8)	8 (3.1)	254 (81.6)	47 (15.1)
Never detectable	123 (24.4)	-	-	55 (44.7)	68 (55.2)
Total <sup>b</sup>	504	32 (6.3)	12 (2.4)	346 (68.6)	115 (22.8)

Abbreviations: FTAS, first-trimester anatomical screening; STAS, second-trimester anatomical screening.

<sup>a</sup>Not including the 23 cases of isolated enlarged NT/hygroma colli.

<sup>b</sup>Not including the 20 cases with transient findings.

TABLE 4 Cases in which the initial diagnosis was not confirmed at follow-up

Structural abnormality	Cases	Mean GA detection	Mean time abnormality not confirmed/resolved (GA or postpartum)
Central nervous system	9		
Severe ventriculomegaly	2	33.0	Postpartum
Microcephaly <P2.3	3	25.1	30.6 (2 postpartum)
Midline cyst	1	21.0	27.3
Megacisterna magna	1	21.0	Postpartum
Blake's pouch cyst	1	20.3	23.0
Fossa posterior cyst	1	20.0	Postpartum
Face	1		
Rethrognathia	1	19.7	Postpartum
Cardiac	2		
Aneurysm ascending aorta	1	20.6	Postpartum
Right ventricular hypertrophy	1	22.4	30.5
Urogenital	5		
Severe hydronephrosis	2	32.6	Postpartum
Unilateral pelvic kidney	1	20.9	30.4
Unilateral renal agenesis	2	23.0	Postpartum <sup>a</sup>
Skeletal	2		
Club foot	1	21.6	Postpartum
Abnormal position fingers	1	28.0	Postpartum
Other	1		
Generalized edema	1	13.3	18.3
Total	20		

Abbreviation: GA, gestational age.

<sup>a</sup>Post-partum 1 case of dysplastic kidney.

ultrasound (in which FTAS was not performed), TOP was chosen by 36/53 (67.9%) cases. The mean GA at TOP was 14.6 weeks (SD 2.0). The mean interval between diagnosis and TOP was 2.0 weeks (SD 1.9). Among the 461 cases with structural abnormalities diagnosed during/following STAS, parents chose TOP in 108/461 (22.7%) and this occurred at a mean GA of 22.2 weeks (SD 1.9). The interval between diagnosis and TOP was 1.6 weeks (SD 0.9) (Figure 1). TOP was performed significantly earlier in the group of anomalies detected at the FTAS compared to at the STAS ( $17.1 \pm 2.10$  weeks vs.

$22.2 \pm 1.9$  weeks,  $p < 0.01$ ). The time between diagnosis and TOP was not significantly different between the two groups ( $p = 0.29$ ).

#### 4 | DISCUSSION

This study shows that when FTAS is not part of the routine prenatal screening offer, an inevitable shift is observed in the moment of diagnosis of some anomalies which are in principle amenable to early

detection. In our cohort, this concerned 338 of the 461 (73.3%) anomalies diagnosed during/following the STAS, of which 37 (8%) belonged to the anomalies “always detectable” and 301 (65.3%) to the “sometimes detectable” in the first trimester. If these two groups are considered together, a hypothetical maximum of 73% of the anomalies detected in the second half of pregnancy could have potentially been recognized earlier. Although this detection rate is theoretically possible, it is very unlikely that in a real-life setting all of the “sometimes detectable” anomalies would have been diagnosed at FTAS. Multiple studies have shown that about half of the structural anomalies diagnosed at STAS can already be detected at FTAS.<sup>5,9</sup> Therefore, we estimate that, next to the 8% of “always detectable” anomalies, a proportion of the “sometimes detectable” could have been diagnosed at FTAS. In our cohort, only 13 women (2.6%) had undergone FTAS in view of an increased a priori risk of fetal abnormalities. All other women only received a dating ultrasound scan at around 11 weeks of gestation. At this examination, some obvious defects ( $n = 31$ ) could already be recognized. Of the 31, 29 (93.5%) belonged to the theoretically “always detectable” in the first trimester, such as anencephaly, alobar holoprosencephaly, megacystis, and abdominal wall defects. However, irrespective of the contribution of the dating ultrasound, 37 of the 66 (56%) “always detectable” abnormalities in the cohort that did not undergo FTAS were only diagnosed at the STAS. This underscores the importance of a routine FTAS and confirms that dating ultrasounds performed before 12 weeks cannot reach the same diagnostic yield of a routine anatomy survey at 12–13 weeks of gestation. In fact, among the 37 late-diagnosed “always detectable” anomalies, there were obvious anomalies such as acrania (3 cases), alobar holoprosencephaly (1 case), encephalocele (4 cases), megacystis (1 case), and abdominal wall defects (12 cases), all amenable to diagnosis at the FTAS. This indicates that even very obvious defects, alongside more “subtle” abnormalities, are missed when the fetus is examined too early and not systematically.<sup>5</sup>

It is of note that early diagnosis of anomalies during FTAS led to a higher rate of TOP compared to STAS (84.6% vs. 29.3%), likely due to the severity of the conditions and the earlier moment of diagnosis during pregnancy. The lack of FTAS delayed this option in the 37 women with late detection of “always detectable” anomalies and in (part of) the 301 with “sometimes detectable” anomalies. It is known that second-trimester TOP is more often associated with long-lasting psychological sequelae and post-traumatic stress syndrome compared to when TOP takes place at earlier stages in pregnancy.<sup>8,11</sup> Also, the delay in the diagnosis of severe abnormalities allows little time left for invasive testing and for an informed decision on continuation/TOP, given the legal limit for TOP of 24 weeks in The Netherlands. In our study, all cases of limb reduction defects, upper limb abnormalities and diaphragmatic hernias, and most cases of spina bifida and renal anomalies, belonging to the “sometimes detectable” in the first trimester, were diagnosed at the STAS or even later. While the visualization of the fetal kidneys in the first trimester might be challenging, other organ systems, such as the hands, can even be easier and better visualized

at this stage when the fetus usually shows extended and spread fingers.

A number of studies on detection of structural abnormalities in the first trimester have shown that detection rates range between 27% and 64% of all antenatally diagnosed defects, depending mostly on the selected population (high vs. low risk) and the use of a structured protocol for anatomical investigation. Other factors influencing detection rates are GA, the use of the transabdominal/transvaginal route, time allocated for the scan, ultrasound equipment used, and experience of the sonographer.<sup>5,9,12–15</sup> In our previous study, where women in a low-risk population were prospectively offered FTAS between 12 and 13 + 6 weeks, we achieved a first-trimester detection rate of 45% of all prenatally diagnosed abnormalities, therefore showing consistency with the literature.<sup>15</sup> In a recent Chinese study of an unselected cohort of 59,063 fetuses, 43% of all structural abnormalities were diagnosed in the first trimester of pregnancy. The sonographers used a structured protocol consisting of 14 planes to examine fetal anatomy. By using this protocol, they achieved a first-trimester detection rate even higher than the 27% described by Syngelaki et al.<sup>16</sup> Further confirmation of the essential role of an imaging protocol comes from a recent systematic review on first-trimester detection of fetal cardiac defects, which showed that 64% of all major prenatally diagnosed cardiac abnormalities were already recognized in the first trimester. The rate was even higher (80%) when fetal echocardiography was performed in high-risk patients. The authors showed that the use of outflow-tract views and color-flow Doppler imaging increased first-trimester detection rates.<sup>17</sup> Notably, the only four cases of cardiac defects detected before the STAS in our study were in women who received FTAS and were assessed following a structured imaging protocol, which included Doppler assessment. All remaining cardiac defects were detected in the second trimester. This is not surprising as the dating ultrasound is performed in the Netherlands too early for appropriate assessment of the fetal heart. Also, Doppler investigation, next to not being recommended before 11 weeks, is not part of this examination.<sup>18</sup> The results may be different if a dating ultrasound would be postponed to after 12 weeks.

This study has some limitations. Although the classification of abnormalities into “always”, “sometimes”, and “never” detectable in the first-trimester is based on the largest and most comprehensive cohort available in the literature, there may be a variance between theoretically expected and observed detection rates. This study also clearly shows that not all anomalies can be diagnosed at the STAS. In fact, in 123 (25%) cases the referral took place after a later ultrasound examination, after STAS. This confirms the findings of the study of Syngelaki et al. that about 20% of all the structural anomalies present in a fetal cohort will be diagnosed after the STAS, either in the late second or third trimester or even after birth.<sup>9</sup> These late diagnoses concern especially gastro-intestinal and some renal and skeletal anomalies. The goal of this study was not to assess the diagnostic ability of ultrasound, but rather to identify the moment of diagnosis of anomalies in pregnancy and correlate this to a reported pattern of diagnosis in the first trimester.

## 5 | CONCLUSION

This study shows the consequences of the lack of a FTAS in the prenatal screening paradigm on time of detection of fetal structural defects (after referral to a tertiary center). More than half of the anomalies “always detectable” in the first trimester that would likely lead to the decision to terminate the pregnancy were diagnosed after the STAS. The results call for the introduction of an early anatomical survey next to noninvasive screening for aneuploidies.

## ACKNOWLEDGMENTS

None.

## CONFLICT OF INTEREST

All authors declare that they have no conflicts of interest.

## DATA AVAILABILITY STATEMENT

The data that support the findings of this study are available from the corresponding author upon reasonable request.

## ORCID

Francesca Bardi  <https://orcid.org/0000-0001-5311-2207>

Marian K. Bakker  <https://orcid.org/0000-0001-5098-6400>

## REFERENCES

1. Minear MA, Lewis C, Pradhan S, Chandrasekharan S. Global perspectives on clinical adoption of NIPT. *Prenat Diagn*. 2015;35(10):959-967. <https://doi.org/10.1002/pd.4637>
2. van der Meij KRM, Sistermans EA, Macville MVE, et al. TRIDENT-2: national implementation of genome-wide non-invasive prenatal testing as a first-tier screening test in the Netherlands. *Am J Hum Genet*. 2019;105(6):1091-1101. <https://doi.org/10.1016/j.ajhg.2019.10.005>
3. Bakker M, Birnie E, Pajkrt E, Bilardo CM, Snijders RJM. Low uptake of the combined test in the Netherlands – which factors contribute? *Prenat Diagn*. 2012;32(13):1305-1312. <https://doi.org/10.1002/pd.4001>
4. van der Meij KRM, de Groot-van Mooren M, Carbo EWS, et al. Uptake of fetal aneuploidy screening after the introduction of the non-invasive prenatal test: a national population-based register study. *Acta Obstet Gynecol Scand*. 2021;100:0-2. <https://doi.org/10.1111/aogs.14091>
5. Bardi F, Smith E, Kuilman M, Snijders R, Bilardo C. Early detection of structural anomalies in a primary care setting in the Netherlands. *Fetal Diagn Ther*. 2018;46(1):1-8. <https://doi.org/10.1159/000490723>
6. Bardi F, Bosschieter P, Verheij J, et al. Is there still a role for nuchal translucency measurement in the changing paradigm of first trimester screening? *Prenat Diagn*. 2020;40(2):197-205. <https://doi.org/10.1002/pd.5590>
7. Maiz N, Burgos J, Barbazán MJ, Recio V, Martínez-Astorquiza T. Maternal attitude towards first trimester screening for fetal abnormalities. *Prenat Diagn*. 2016;36(5):449-455. <https://doi.org/10.1002/pd.4802>
8. Bardi F, Bakker M, Kenkhuis MJA, et al. Psychological outcomes, knowledge and preferences of pregnant women on first-trimester screening for fetal structural abnormalities: a prospective cohort study. *PLoS One*. 2021;16(1):e0245938. <https://doi.org/10.1371/journal.pone.0245938>
9. Syngelaki A, Hammami A, Bower S, Zidere V, Akolekar R, Nicolaides KH. Diagnosis of fetal non-chromosomal abnormalities on routine ultrasound examination at 11–13 weeks' gestation. *Ultrasound Obstet Gynecol*. 2019;54(4):468-476. <https://doi.org/10.1002/uog.20844>
10. Rijksinstituut voor Volksgezondheid en Milieu, Ministerie van Volksgezondheid W en S. Her eerste trimester SEO. Accessed November 24, 2021. <https://www.pns.nl/professionals/nipt-seo/eerste-trimester-seo/>
11. Korenromp MJ, Page-Christiaens GC, van den Bout J, Mulder EJ, Visser GH. Adjustment to termination of pregnancy for fetal anomaly: a longitudinal study in women at 4, 8, and 16 months. *Am J Obstet Gynecol*. 2009;201(2):160.e1-160.e7. <https://doi.org/10.1016/j.ajog.2009.04.007>
12. Kenkhuis MJA, Bakker M, Bardi F, et al. Effectiveness of a 12–13 week scan for the early diagnosis of fetal congenital anomalies in the cell-free DNA era. *Ultrasound Obstet Gynecol*. 2017;51(4):463-469. <https://doi.org/10.1002/uog.17487>
13. Grande M, Arigita M, Borobio V, Jimenez JM, Fernandez S, Borrell A. First-trimester detection of structural abnormalities and the role of aneuploidy markers. *Ultrasound Obstet Gynecol*. 2012;39(2):157-163. <https://doi.org/10.1002/uog.10070>
14. Syngelaki A, Chelemen T, Dagklis T, Allan L, Nicolaides KH. Challenges in the diagnosis of fetal non-chromosomal abnormalities at 11–13 weeks. *Prenat Diagn*. 2011;31(1):90-102. <https://doi.org/10.1002/pd.2642>
15. Karim JN, Roberts NW, Salomon LJ, Papageorghiu AT. Systematic review of first-trimester ultrasound screening for detection of fetal structural anomalies and factors that affect screening performance. *Ultrasound Obstet Gynecol*. 2017;50(4):429-441. <https://doi.org/10.1002/uog.17246>
16. Liao Y, Wen H, Ouyang S, et al. Routine first-trimester ultrasound screening using a standardized anatomical protocol. *Am J Obstet Gynecol*. 2021;224(4):396.e1-396.e15. <https://doi.org/10.1016/j.ajog.2020.10.037>
17. Karim JN, Bradburn E, Roberts N, Papageorghiu AT. First trimester ultrasound for the detection of fetal heart anomalies: a systematic review and meta-analysis. *Ultrasound Obstet Gynecol*. 2021. (in press).
18. Salvesen K, Abramowicz J, Ter Haar G, et al. ISUOG statement on the safe use of Doppler for fetal ultrasound examination in the first 13 + 6 weeks of pregnancy (updated). *Ultrasound Obstet Gynecol*. 2021;57:1020. <https://doi.org/10.1002/uog.23610>

## SUPPORTING INFORMATION

Additional supporting information can be found online in the Supporting Information section at the end of this article.

**How to cite this article:** Bardi F, Beekhuis AM, Bakker MK, Elvan-Taşpınar A, Bilardo CM. Timing of diagnosis of fetal structural abnormalities after the introduction of universal cell-free DNA in the absence of first-trimester anatomical screening. *Prenat Diagn*. 2022;1-11. <https://doi.org/10.1002/pd.6224>