

University of Groningen

Recovery of TES-MEPs During Surgical Decompression of the Spine

Visser, Jetze; Verra, Wiebe C.; Kuijlen, Jos M.; Horsting, Philip P.; Journee, Henricus L.

Published in:
Journal of Clinical Neurophysiology

DOI:
[10.1097/WNP.000000000000099](https://doi.org/10.1097/WNP.000000000000099)

IMPORTANT NOTE: You are advised to consult the publisher's version (publisher's PDF) if you wish to cite from it. Please check the document version below.

Document Version
Publisher's PDF, also known as Version of record

Publication date:
2014

[Link to publication in University of Groningen/UMCG research database](#)

Citation for published version (APA):

Visser, J., Verra, W. C., Kuijlen, J. M., Horsting, P. P., & Journee, H. L. (2014). Recovery of TES-MEPs During Surgical Decompression of the Spine: A Case Series of Eight Patients. *Journal of Clinical Neurophysiology*, 31(6), 568-574. <https://doi.org/10.1097/WNP.000000000000099>

Copyright

Other than for strictly personal use, it is not permitted to download or to forward/distribute the text or part of it without the consent of the author(s) and/or copyright holder(s), unless the work is under an open content license (like Creative Commons).

The publication may also be distributed here under the terms of Article 25fa of the Dutch Copyright Act, indicated by the "Taverne" license. More information can be found on the University of Groningen website: <https://www.rug.nl/library/open-access/self-archiving-pure/taverne-amendment>.

Take-down policy

If you believe that this document breaches copyright please contact us providing details, and we will remove access to the work immediately and investigate your claim.

Downloaded from the University of Groningen/UMCG research database (Pure): <http://www.rug.nl/research/portal>. For technical reasons the number of authors shown on this cover page is limited to 10 maximum.

Recovery of TES-MEPs During Surgical Decompression of the Spine: A Case Series of Eight Patients

Jetze Visser,* Wiebe C. Verra,* Jos M. Kuijlen,† Philip P. Horsting,* and Henricus L. Journée*†

Purpose: This study aimed to illustrate the recovery of transcranial electrical stimulation motor evoked potentials during surgical decompression of the spinal cord in patients with impaired motor function preoperatively. Specific attention was paid to the duration of neurologic symptoms before surgery and the postoperative clinical recovery.

Methods: A case series of eight patients was selected from a cohort of 74 patients that underwent spine surgery. The selected patients initially had low or absent transcranial electrical stimulation motor evoked potentials followed by a significant increase after surgical decompression of the spinal cord.

Results: A significant intraoperative increase in amplitude of motor evoked potentials was detected after decompression of the spinal cord or cauda equina in patients suffering from spinal canal stenosis ($n = 2$), extradural meningioma ($n = 3$), or a herniated nucleus pulposus ($n = 3$). This was related to an enhanced neurologic outcome only if patients ($n = 6$) had a short onset (less than $\frac{1}{2}$ year) of neurologic impairment before surgery.

Conclusions: In patients with a short onset of neurologic impairment because of compression of the spinal cord or caudal fibers, an intraoperative recovery of transcranial electrical stimulation motor evoked potentials can indicate an improvement of motor function postoperatively. Therefore, transcranial electrical stimulation motor evoked potentials can be considered as a useful tool to the surgeon to monitor the quality of decompression of the spinal cord.

Key Words: TES-MEP, Intraoperative monitoring, Spine, Spinal cord, Decompression, Recovery of potentials.

(*J Clin Neurophysiol* 2014;31: 568–574)

Corrective surgery of the spinal cord or cauda equina carries the risk of impairment of the motor and sensory function in the lower extremities. The majority of spine surgery is performed on patients without neurologic deficits. Intraoperative neurophysiological monitoring (IONM) of the motor system by transcranial electrical stimulation has been recognized as a reliable and sensitive technique to detect imminent damage to the nervous system (Deletis and Sala, 2008; Langeloo et al., 2003; MacDonald et al., 2003; Macdonald et al., 2013; Malhotra and Shaffrey, 2010; Padberg et al., 1998; Rajshekhar et al., 2011; Schwartz et al., 2007). The surgeon can usually take corrective actions before paresis or paralysis occurs. The success ratio of eliciting motor evoked potentials (MEP) in neurologically normal patients and under optimum anesthetic conditions is nearly 100% with multipulse single or double train

stimulation (Journée et al., 2004, 2007; Macdonald et al., 2007). Monitoring criteria are based on decreases of MEP amplitudes, which may relate to motor impairment (Avila et al., 2013; Clark et al., 2013; Deletis and Sala, 2008; Langeloo et al., 2003; MacDonald et al., 2003; Schwartz et al., 2007). However, when neurologic symptoms were present before surgery, because of compression of the spinal cord or nerve roots, transcranial electrical stimulation MEPs (TES-MEPs) may be small or absent at the start of IONM. Recovery of motor potentials may occur after releasing the impacted neural structures. This might indicate the efficacy of decompression and hence can be of value to the surgeon. Since this improvement of MEPs after decompression indicates better conduction of nerve potentials along the corticospinal tract, we expect this to be a predictor of an enhanced postoperative neurologic function of the patient.

A case series of eight patients is presented, who all had preoperative impaired motor or sensory functions from spinal cord compression and in which intraoperative TES-MEPs significantly improved during surgical decompression of the spinal cord. Patient characteristics are listed, with a special focus on the duration of symptoms before surgery and neurologic outcome after surgery.

MATERIALS AND METHODS

Measurement of TES-MEP

Transcranial electrical stimulation was performed following a standard procedure applying a custom-made voltage stimulator (NeuroGuard; JS Center, Bedum, The Netherlands). Needle electrodes were placed subcutaneously on the head: one at the anatomic location Cz (anode) and two at C3-C4 positions (EEG 10-20 system). The Fz cathode, a split half of a universal electrosurgical pad (3M, Diegem, Belgium; type 9160F), was placed across the forehead. To obtain optimal, symmetrical MEP responses, stimulation was performed over either Cz-Fz with monophasic pulse trains or C3-C4 with biphasic pulse trains. Surface electrodes (3M ECG) were used to record bilateral MEPs from four muscle groups. Before the onset of the operation, optimal muscle action potentials were acquired using a few different techniques (Deletis and Sala, 2008; Journée et al., 2004, 2007; van Hal et al., 2013). A voltage curve at the optimal parameter settings was performed preoperatively. When muscle groups revealed nonelicitable potentials as a result of paresis or paralysis while no responses in alternative muscle groups at same root levels were obtainable, these were also monitored to detect possible recovery of responses on surgical decompression of the spinal cord or nerve roots. In thoracolumbar surgery any three of the following four sites were used depending on the exact level of surgery: the quadriceps muscle (L2-L4), the tibialis anterior muscle (L4-L5), the hamstrings (L5-S1), or the gastrocnemius muscle (S1-S2). The activity of the abductor polices brevis muscle or the

From the *Department of Orthopaedics, Sint Maartenskliniek, Nijmegen, The Netherlands; and †Department of Neurosurgery, University Medical Center Groningen, Groningen, The Netherlands.

The authors have full control of all primary data and agree to allow the journal to review their data if requested.

Address correspondence and reprint requests to Philip P. Horsting, MD, Department of Orthopaedics, Sint Maartenskliniek, Hengstdal 3, PO Box 9011, 6500GM Nijmegen, The Netherlands; e-mail: p.horsting@maartenskliniek.nl.

Copyright © 2014 by the American Clinical Neurophysiology Society
ISSN: 0736-0258/14/3106-0568

abductor digitus V muscle was used as a control value to detect systemic effects on MEPs. During cervical procedures, the bilateral trapezoid muscle (C2-C4), the biceps (C5-C6), and triceps muscle (C7-C8) of the arm; the extensor muscles of the forearm (C6-C7); or the abductor digitus V muscle (C6-C8) were monitored. Here, the trapezius muscle or sometimes muscle groups being innervated by cranial nerves, usually the orbicularis oris muscle, were used as a control value.

Other Modalities

In most patients, only TES-MEPs were monitored. Bulbocavernosus reflexes were incidentally monitored in conus-cauda region for checking motor and sensory integrity of lower sacral levels down to S3. Somatosensory evoked potentials (SEPs) were not included in the protocol.

Anesthetics

A strict anesthetic regime was maintained to enable adequate muscle responses (Macdonald et al., 2013). Patients were orally premedicated with midazolam (0.1 mg/kg) and on intubation some were administered rocuronium (0.6 mg/kg), a short-acting neuromuscular blocking agent. All patients received opiates for sedation (sufentanil or remifentanyl). General anesthesia was induced with a bolus dose of propofol (2 mg/kg) and remifentanyl (2 µg/kg), followed by continuous infusion of propofol (4–8 mg⁻¹·kg⁻¹·h⁻¹), ketamine (2.5 µg·kg⁻¹·min⁻¹), and remifentanyl (0.05–0.5 µg·kg⁻¹·min⁻¹). Gas ventilation occurred with a mixture of 70%/30% O₂/room air. No further muscle relaxants, benzodiazepines and barbiturates were used because these would influence the muscle responses.

Patient Sample

Seventy-four patient files and neuromonitoring reports of surgical sessions were screened in which the spinal cord or cauda equina was decompressed (Fig. 1). In these patients (aged 18–73, mean 51 years), surgeries were performed on all levels of the spinal cord or cauda equina. Pathologies were intra- and extramedullary spinal tumors (n = 46), herniated nucleus pulposus (n = 15), spinal canal stenosis (n = 10), and listhesis (n = 3). Eight patients who showed a significant recovery of initially absent TES-MEPs during spine surgery were selected for further study in this case series. Cases were obtained from two different institutions (SMK and

UMCG) where IONM was performed using the same methodology by identically educated technologists supervised by one neurophysiologist (H.L.J.). The MEP amplitude in each of the four monitored muscle groups was measured exactly at the start and the end of the surgical procedure. When the initial MEP amplitude was more than 10 µV, the relative increase or decrease was computed as a percentage. When no initial MEP amplitude was present and when responses were less than 10 µV, then the MEP recovery was expressed as “response appearance after absence.” To minimize the effect of other factors that can cause a variation in MEP amplitude (i.e., anesthesia, blood loss), an MEP change was considered a significant increase when the amplitude after decompression was more than 200% (equals 100% improvement) from the starting value. Patients were analyzed for age, gender, medical history, onset of neurologic symptoms, neurologic function before and 3 months after surgery, pathology, type of surgery, anesthetic details during the surgical session, and peroperative blood loss. The moment of surgical decompression of the impacted neural structures and the moment as well as anatomic location of intraoperative MEP recovery were analyzed. The MEP recovery was correlated with the duration of neurologic symptoms before surgery as well as with neurologic improvement after surgery. Neurologic function parameters were motor function, stated as strength of a muscle group or limb ranging from 0 to 5 on the Medical Research Council scale for muscle strength, sensory function, neurogenic pain, and walking distance. The postoperative improvement or relief from one or more of these symptoms that could be related to the spine pathology was defined as a neurologic improvement. This improvement was considered to have a positive relation with MEP recovery if it concerned an anatomically related muscle group or limb.

RESULTS

This case series included four men and four women who ranged in age from 19 to 67 years (mean, 46 years). Table 1 lists the characteristics of these eight patients. One patient underwent a laminectomy and deformity correction for a lumbar scoliosis with spinal canal stenosis (patient 1); three of them underwent a resection of a cervical or thoracic meningioma (patients 2, 3, and 8); three had a discectomy of a cervical herniated nucleus pulposus (patients 4, 5, and 7), and one patient underwent a corpectomy and deformity correction for a post-traumatic cervical canal stenosis (patient 6). No significant alterations

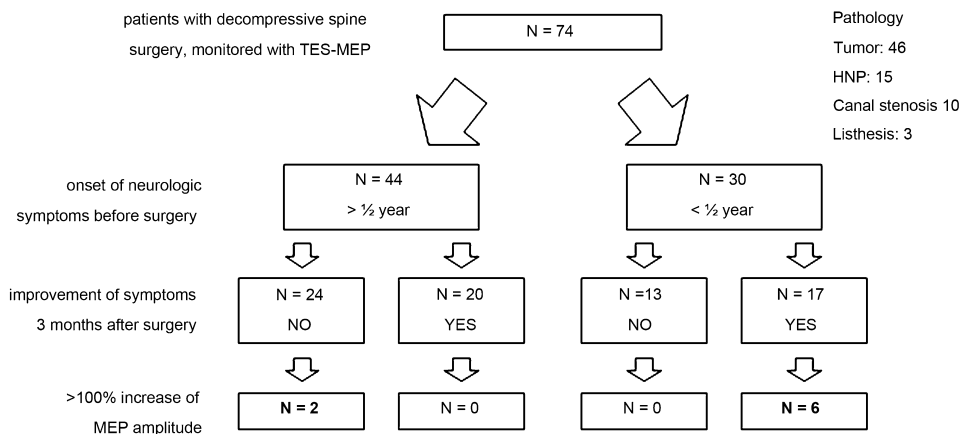


FIG. 1. Seventy-four neuromonitoring reports of decompressive spine surgeries were retrospectively screened. In eight cases, transcranial electrical stimulation motor evoked potential (TES-MEP) increased more than 100% during the surgical session. Six of these patients had a clinical recovery of neurologic symptoms. These patients had a short onset (<1/2 year) of neurologic symptoms. Two other patients had a tetrapyramidal syndrome already some years before surgery. They showed an intraoperative improvement of TES-MEP without enhanced clinical outcome.

Downloaded from http://jcn.aph.org/ on 09/12/2022

TABLE 1. Characteristics of Patients With Intraoperative Improvement of MEPs

Age, Gender	Pathology	Surgery	Onset of Symptoms Before Surgery	MRC Scale; Neuro Function Preoperative	Neuro Function; 3 Months Postoperative	Muscle Group; Relative Recovery (%); Final Amplitude (μ V)	
						Left	Right
1 67 F	Thoracolumbar scoliosis with spinal canal stenosis L2-L3	Deformity correction Th11-L5 + laminectomy L2-L3	4 months	R leg 2–3/5; unable to walk and increasing pain	R psoas 4/5, other muscles 5/5 walks	Gastroc.; 403%; 151 μ V	TA; RAAA; 679 μ V. Gastroc.; RAAA; 448 μ V
2 53 F	Intradural extramedullar meningioma C3-C5	Resection of meningioma	4 months	R arm 2/5; R leg 4/5; loss of sensory and motor function R arm + leg; gait: limping	R arm 4/5; R leg 5/5	TA; RAAA; 350 μ V. APB; 1,300%; 3,737 μ V. Trap; 122%; 1,988 μ V	APB; 266; 1,521 μ V. TA; 239%; 651 μ V
3 42 M	Intradural extramedullar meningioma C1-C2	Resection of meningioma	4 months	L arm 4/5; loss of sensory and motor function L arm	L arm 5/5	TA; RAAA; 1,086 μ V. APB; 640%; 1,931 μ V	TA; RAAA; 1,284 μ V. Delt; RAAA; 228 μ V. APB; 924%; 676 μ V. Delt; 252%; 761 μ V
4 67 F	HNP C5-C6 with spinal cord compression	Anterior discectomy	36 months; progressive immobility	Legs 2/5; tetrapyramidal syndrome	No improvement	APB; 307%; 2,811 μ V	APB; 307%; 2,811 μ V
5 38 F	HNP C4-C5 with spinal cord compression	Anterior discectomy	2 months	Legs and arms 5/5; pain and paresthesia	Cure from pain and paresthesia	TA; RAAA; 436 μ V. Trap; 617%; 1,964 μ V. Delt; 417%; 1,707 μ V. APB; 383%; 2,830 μ V	TA; RAAA; 134 μ V. APB; 732%; 1,705 μ V. Trap; 179%; 1,874 μ V
6 30 M	Posttraumatic spinal canal stenosis C4-C6; cervical kyphotic deformity	Corpectomy C5-C6 with spondylodesis C4-C7	24 months; progressive spastic gait	L + R arms + legs, diffuse 2/5–5/5; tetrapyramidal syndrome	No improvement of motor function and mobility	APB; 186%; 526 μ V. Delt; 158%; 1,486 μ V	APB; 239%; 403 μ V. Delt; 136%; 2,788 μ V
7 48 M	HNP C6-C7 with spinal cord compression	Anterior discectomy + fusion C6-C7	6 months	Legs 4/5; numbness + ataxia legs; bipyramidal syndrome	Legs 5/5 normal walking	ADV; 255%; 3,999 μ V	Ext. FA; 161%; 3,741 μ V
8 19 M	Relapse extradural meningioma Th8-9	Resection of meningioma	6 months	Legs 5/5; walking distance: 100 m	Legs 5/5 normal walking	TA; RAAA; 621 μ V. APB; 163%; 2,971 μ V	TA; 191%; 303 μ V

Intraoperative improvement of MEPs was associated with positive neurologic outcome after surgery only in patients with a short onset of neurologic symptoms (1, 2, 3, 5, 7, and 8). The improved MEPs were found at or under the level of spine compression.

ADV, abductor digitus V muscle (hand); APB, abductor pollicis brevis muscle; C, cervical spine level; delt, deltoid muscle; F, female; gastroc, gastrocnemius muscle; HNP, herniated nucleus pulposus; L, lumbar spine level; L arm, left arm; M, male; MEP, motor evoked potential; MRC scale, Medical Research Council scale for muscle strength; R, right; RAAA, response appearance after absence: initial MEP amplitude was not elicitable or less than 100 μ V; TA, tibialis anterior muscle; Th, thoracic spine level; trap, trapezoid muscle.

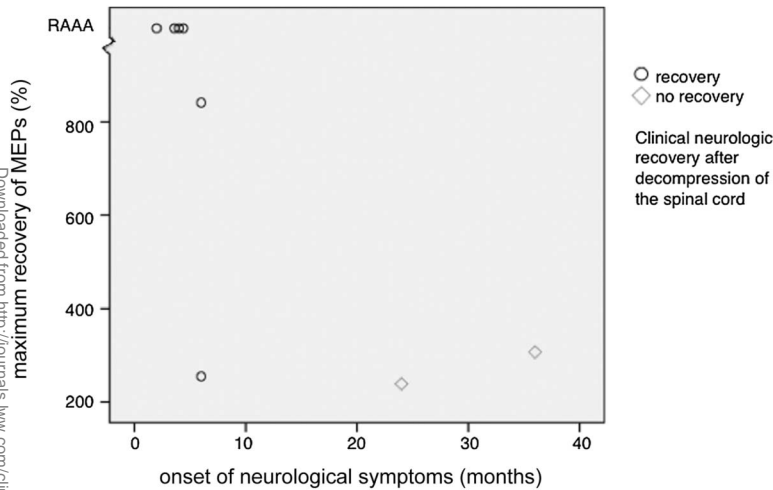


FIG. 2. The percentage of MEPs recovery after decompression of the spinal cord or cauda equina is higher when a patient had neurologic impairment shorter than 6 months before surgery. In this group, the neurologic function recovered within 3 months after surgery, as marked by (O). Cases of RAAA were always followed by clinical postoperative recovery. MEPs, motor evoked potentials; TES-MEP, transcranial electrical stimulation motor evoked potential; RAAA, response appearance after absence.

in blood pressure were observed during surgery relating to changes in MEP amplitudes; blood loss was 230 to 1,600 mL (mean, 688 mL) and no anesthetic complications occurred. Six of these eight patients had progressive neurologic symptoms for less than half a year (2–6 months) before surgery. The two other patients had neurologic symptoms for 2 and 3 years, both diagnosed as a pyramidal syndrome, which was deteriorating in the last few months before surgery. The group with symptoms for less than half a year before surgery all showed significant improvement after surgery. The neurologic function of the two patients with longer lasting symptoms did not improve after surgery.

Table 1 also shows the muscle groups of these eight patients that improved more than 100% in MEP amplitude. Some MEPs were nonelicitable or lower than 10 μ V at the start of the surgical session, but reappeared after decompression (Table 1, response appearance after absence). The presence of response appearance after absence or a relatively high percentage of MEP improvement was seen in patients

with a short onset of neurologic symptoms (Fig. 2). The increase of MEPs was related to the specific limbs in which subsequent clinical improvement was seen, except for the legs of patient 7. Along with the clinically improved limb, some contralateral limbs and some muscle groups distal from the site of spine compression showed an MEP increase as well. The control muscle groups maintained stable potentials during the surgical procedure, excluding the influence of anesthetic events.

Case Description

Patient 1 is described in further detail as a representative of the group of six patients showing recovery of originally low or absent motor responses after spinal decompression. This 67-year-old Caucasian female patient was referred with predominantly lumbar pain with radiation to both legs and muscle weakness in mainly the right leg, resulting in a limited walking distance.

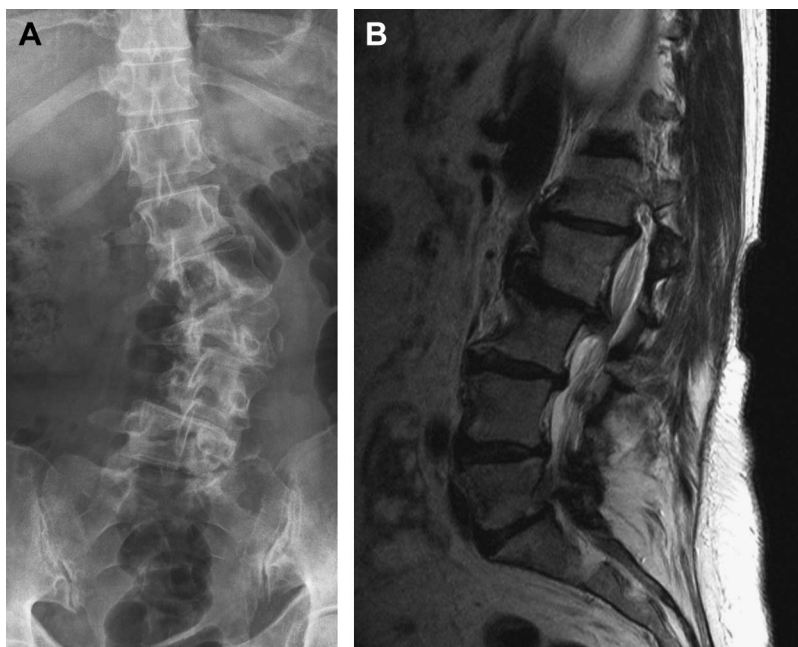


FIG. 3. A, An anteroposterior x-ray of the lumbar spine of patient 1 showed a lumbar torsion scoliosis with a Cobbs angle of 48°. (B) MRI scanning showed discopathy at all lumbar levels, with loss of height at L2-L3 and L3-L4. At level L1-L2 left and L2-L3, a right subforaminal herniation with spondylosis can be seen with caudal impression and bulging at level L3-L4. This lumbar pathology resulted in a severe motor impairment of the legs.

Downloaded from http://journals.lww.com/clinicalneurophys by BHDMS68F8KAVTZE0umt1QIN4a+kLLNEZ9psiH04 XM10HCW/CX1AWWYQp/IIQIH3D3000R9Y7TVSFI4C3VVC1y0abgqQZXdvHFKZBYtws= on 09/12/2022

Micturition was normal as well as the sensibility in thoracic and lower sacral segments. Knee and Achilles tendon reflexes were absent on the right side and present on the left. The straight leg raising test was negative. Standing AP radiographs showed a lumbar scoliosis with a Cobbs angle of 48° (Fig. 3A). A lumbar MRI scan showed disk degeneration at all lumbar levels, with loss of disk height at L2-L3 and L3-L4 (Fig. 3B). At level L1-L2 left and L2-L3, a right subforaminal herniation was seen with conal and caudal impression, respectively. There was bulging at level L3-L4 and an absolute canal stenosis at level L3-L4 and L4-L5 caused by the spinal deformity. In the few months after this diagnosis, there was a rapid deterioration of motor function of all muscles of the right leg to Medical Research Council scale of 2 to 3/5 and 4 to 5/5 in the left leg; the patient was no longer able to walk.

Four months after initial diagnosis, a posterior deformity correction at level Th11 to L5 with decompression of L2-L3 was performed. In Fig. 4, the full IONM course of the surgical session is given. Before surgery, the motor responses of the right tibialis anterior and gastrocnemius muscle were absent. Through a dorsal approach, screws were then placed under x-ray guidance in the pedicles of T11, T12, L1, L4, and L5. One hundred minutes from the onset of the surgical session, an extensive laminectomy was performed at level L2-L3 with undercutting of the adjacent segments to fully decompress the cauda equina. Motor responses with amplitudes between 400 and 700 μ V appeared instantaneously. Additional pedicle screws were then placed at level L2-L3 and a precurved rod (Universal Spinal System; Synthes, Bettlach, Switzerland) was connected to the screws. The lumbar scoliosis was then corrected through derotation of the rods. Motor responses remained present until the end of the surgery. Figure 5 shows the appearance of the MEPs of the right tibial and gastrocnemius muscles in a landscape plot. The improvements have been quantified in Table

1. The first day after surgery sensibility was normal, strength in the right leg was 3/5, left 5/5. Four days postoperatively, the patient was able to walk again; the strength of the right psoas muscle had further increased to 4/5 and all the other muscle groups of both legs had a score of 5/5.

DISCUSSION

The present case series illustrates a role for IONM using TES-MEPs for detecting an improvement of potentials after decompression of the spinal cord or cauda equina. This case series included patients with a wide variety of pathologies, which all led to a compromised spinal cord with clinical symptoms. The observed improvement was more likely to be followed by an enhanced neurologic outcome when the neural structures had been compromised for a relatively short period (<6 months), which here was set as an arbitrary limit for a short onset of preoperative neurologic symptoms.

It is important to note that the presented case series (n = 8) was sampled from 74 patient files. This cohort indicates that a recovery of TES-MEPs only occurred in some patients, resulting in a low specificity of this event. Unfortunately, the large group of patients was too heterogenic to be presented in a cohort study. Hence, a case series was presented to illustrate the event of a recovery of potentials after surgical decompression. In addition, the authors remark that this study does not address the possible difference in mechanism between the recovery of potentials after decompression of the spinal cord and the cauda equina. The cauda equina, like peripheral nerve fibers, consists of myelinated nerves, whereas the spine also contains gray matter containing the motor neurons. Furthermore, blood supply of both structures has a different anatomy and physiology. Direct mechanical compression of neurologic structures as well as their blood supply could cause

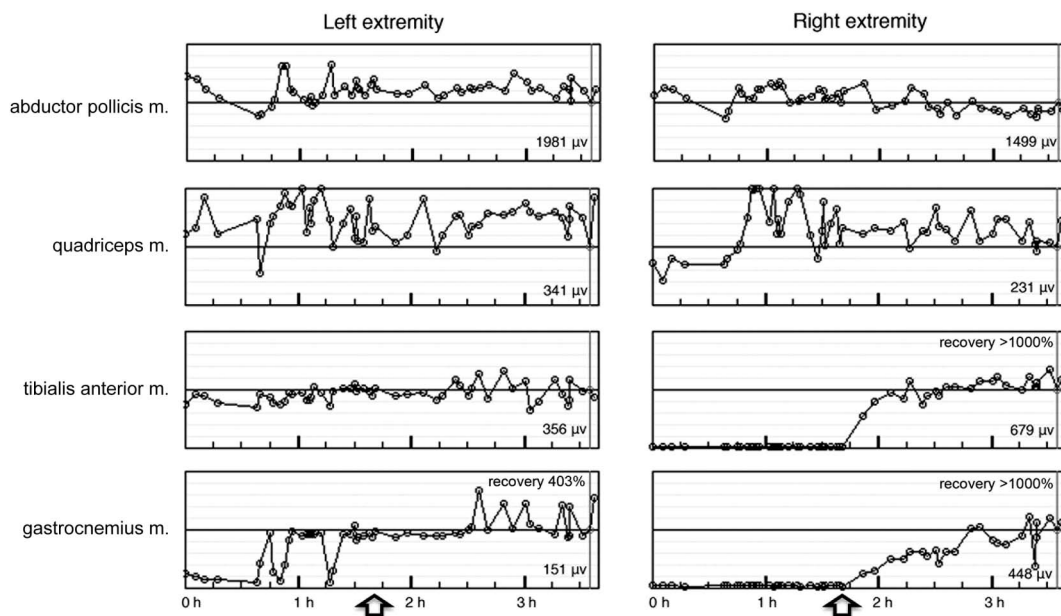


FIG. 4. Motor evoked potentials (MEPs) of patient 1 during the surgical procedure. At 100 minutes from the onset of surgery, a laminectomy L2-L3 was performed (marked with arrow) and potentials recovered in the gastrocnemius muscle of both legs and of the tibial anterior muscle of the right leg. The abductor pollicis muscle serves as a reference value and shows a constant response. MEP changes as a result of hemodynamic alterations are thereby very unlikely. Absolute amplitudes of the MEPs were defined for the end of the surgical session as marked by the vertical gray line and were stated at the bottom right of the plot.

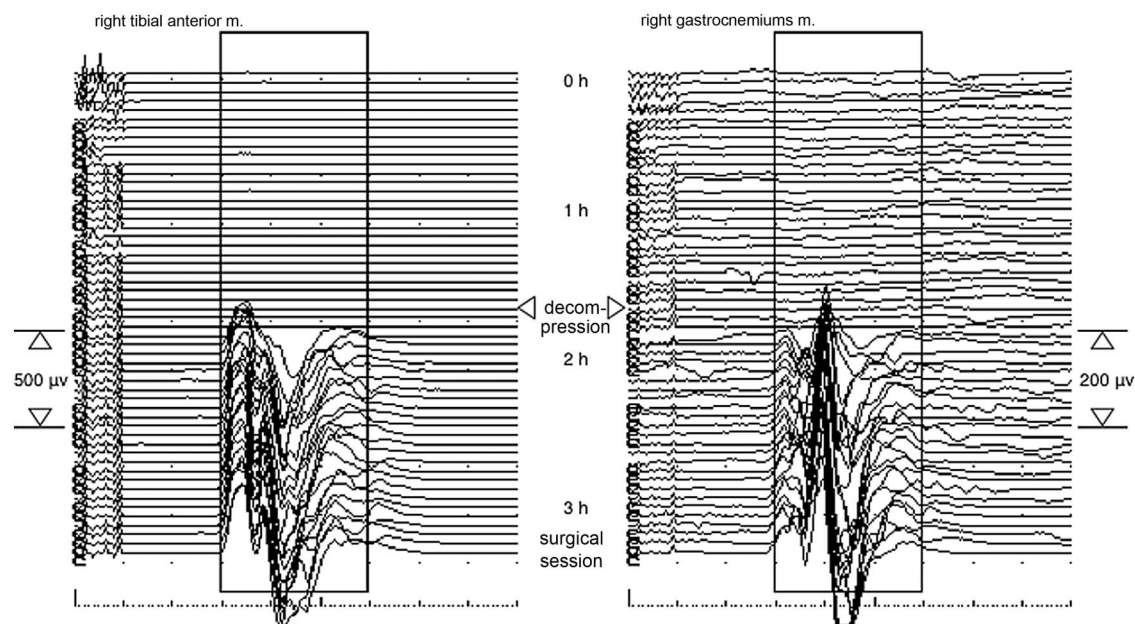


FIG. 5. In patient 1, the motor evoked potentials (MEPs) of the right lower leg emerged after the complete cauda equina was decompressed. m., muscle; TES-MEP specifications: 250 V, multipulse, $n = 7$, pulse width 100 microseconds, interpulse interval 1.4 milliseconds.

neurologic impairment, which is hard to differentiate in a clinical setting, although a reciprocal relationship can be expected between the period of compression and physiologic recovery from both structures (Barley et al., 2010; Lieberman et al., 2008; Lips et al., 2002; Pelosi et al., 2002; Skinner et al., 2009). Remarkable is the fact that patient 5 showed significant improvement in MEPs in the absence of motor impairment before surgery. Probably, there was compression of motor and sensory units in the spinal cord, which had clinically only resulted in sensory deficits.

Most MEP recoveries have been reported on a previous reduction or disappearance of MEPs that were normally present at the beginning of the surgical procedure (Avila et al., 2013; Clark et al., 2013; Lieberman et al., 2008; Pelosi et al., 2002; Skinner et al., 2009). Restoration of the temporary MEP reduction during the surgical session resulted in unaltered, normal neurologic outcome, whereas a persistent loss of potentials indicated a worse outcome. Only two studies have reported an improvement of MEPs that were low or nonelicitable at the start of surgery (Barley et al., 2010; Voulgaris et al., 2010). Voulgaris et al. (2010) reported 25 patients who underwent surgery for lumbar spinal stenosis. A 50% increase of MEP amplitude after decompression was seen in 17 patients. These patients had a greater postoperative improvement than those without an increase of MEP amplitude, based on the visual analog scale for pain 1 year after surgery. Unfortunately, pain was the only outcome parameter reported; the course of motor and sensory function before and after surgery was not reported. Yet, this would be the causative relation one would like to prove, regarding the pathophysiology of an improving muscle potential. A recent case report is the only literature describing an intraoperative recovery of MEPs together with an improvement of neurologic function after surgical decompression (Barley et al., 2010). This concerned a 15-month-old boy with a lumbar level myelodysplasia, Chiari II malformation, severe scoliosis, and a tethered cord that had resulted in a short-

onset partial paralysis of the left upper extremity. After untethering the spinal cord, initially absent TES-MEPs of the left arm became present and continued to improve during the surgery. Immediately postoperatively, the child showed a significantly improved motor function of the affected limb. In contrast to the present study and the discussed literature so far, other researchers did not observe a recovery of potentials after decompression of the spine (Castellon et al., 2009; Haghghi, 2002). This concerned a small number of patients who were monitored using somatosensory evoked potentials (SEPs) or MEPs. Unfortunately, duration and progression of symptoms and neurologic outcome are unknown.

CONCLUSIONS

From the present study, we can conclude that in patients with compression of the spinal cord or cauda equina, resulting in low or absent MEP at the start of surgery, an increase in potentials after surgical decompression may predict a recovery of clinical function. Therefore, IONM should not only focus on decreases of motor potentials but also consider a recovery of MEPs of muscle groups not responding before surgery. Patients with a short onset of deteriorating neurologic function seem to be the best candidates for this potential added focus of IONM. Nonetheless, the likelihood of a recovery of potentials as well as the relation to the type of pathology and the neurologic symptoms need to be investigated in a prospective cohort study. In this way, the neurophysiologist may sometimes be able to give the surgeon positive feedback on the quality of the decompression of the spinal cord.

ACKNOWLEDGMENTS

The authors thank H. E. Polak for performing IONM and for his ideas leading to this article and Peter Levett for proofreading the manuscript.

REFERENCES

- Avila EK, Elder JB, Singh P, et al. Intraoperative neurophysiologic monitoring and neurologic outcomes in patients with epidural spine tumors. *Clin Neurol Neurosurg* 2013;115:2147–2152.
- Barley JL, Mooney JF, Glazier SS, et al. Sudden appearance of new upper extremity motor function while performing neurophysiologic intraoperative monitoring during tethered cord release: a case report. *J Pediatr Orthop* 2010;30:624–628.
- Castellon AT, Meves R, Avanzi O. Intraoperative neurophysiologic spinal cord monitoring in thoracolumbar burst fractures. *Spine (Phila Pa 1976)* 2009;34:2662–2668.
- Clark AJ, Ziewacz JE, Safae M, et al. Intraoperative neuromonitoring with MEPs and prediction of postoperative neurological deficits in patients undergoing surgery for cervical and cervicothoracic myelopathy. *Neurosurg Focus* 2013;35:E7.
- Deletis V, Sala F. Intraoperative neurophysiological monitoring of the spinal cord during spinal cord and spine surgery: a review focus on the corticospinal tracts. *Clin Neurophysiol* 2008;119:248–264.
- Haghighi SS. Monitoring of motor evoked potentials with high intensity repetitive transcranial electrical stimulation during spinal surgery. *J Clin Monit Comput* 2002;17:301–308.
- Journee HL, Polak HE, de Kleuver M, et al. Improved neuromonitoring during spinal surgery using double-train transcranial electrical stimulation. *Med Biol Eng Comput* 2004;42:110–113.
- Journee HL, Polak HE, De Kleuver M. Conditioning stimulation techniques for enhancement of transcranially elicited evoked motor responses. *Neurophysiol Clin* 2007;37:423–430.
- Langeloo DD, Lelivelt A, Louis Journee H, et al. Transcranial electrical motor-evoked potential monitoring during surgery for spinal deformity: a study of 145 patients. *Spine (Phila Pa 1976)* 2003;28:1043–1050.
- Lieberman JA, Lyon R, Feiner J, et al. The efficacy of motor evoked potentials in fixed sagittal imbalance deformity correction surgery. *Spine (Phila Pa 1976)* 2008;33:E414–E424.
- Lips J, de Haan P, de Jager SW, et al. The role of transcranial motor evoked potentials in predicting neurologic and histopathologic outcome after experimental spinal cord ischemia. *Anesthesiology* 2002;97:183–191.
- MacDonald DB, Al Zayed Z, Khoudeir I, Stigsby B. Monitoring scoliosis surgery with combined multiple pulse transcranial electric motor and cortical somatosensory-evoked potentials from the lower and upper extremities. *Spine (Phila Pa 1976)* 2003;28:194–203.
- Macdonald DB, Al Zayed Z, Al Saddigi A. Four-limb muscle motor evoked potential and optimized somatosensory evoked potential monitoring with decussation assessment: results in 206 thoracolumbar spine surgeries. *Eur Spine J* 2007;16(suppl 2):S171–S187.
- Macdonald DB, Skinner S, Shils J, Yingling C. Intraoperative motor evoked potential monitoring: a position statement by the American Society of Neurophysiological Monitoring. *Clin Neurophysiol* 2013;124:2291–2316.
- Malhotra NR, Shaffrey CI. Intraoperative electrophysiological monitoring in spine surgery. *Spine (Phila Pa 1976)* 2010;35:2167–2179.
- Padberg AM, Wilson-Holden TJ, Lenke LG, Bridwell KH. Somatosensory- and motor-evoked potential monitoring without a wake-up test during idiopathic scoliosis surgery. An accepted standard of care. *Spine (Phila Pa 1976)* 1998;23:1392–1400.
- Pelosi L, Lamb J, Grevitt M, et al. Combined monitoring of motor and somatosensory evoked potentials in orthopaedic spinal surgery. *Clin Neurophysiol* 2002;113:1082–1091.
- Rajshekhkar V, Velayutham P, Joseph M, Babu KS. Factors predicting the feasibility of monitoring lower-limb muscle motor evoked potentials in patients undergoing excision of spinal cord tumors. *J Neurosurg Spine* 2011;14:748–753.
- Schwartz DM, Auerbach JD, Dormans JP, et al. Neurophysiological detection of impending spinal cord injury during scoliosis surgery. *J Bone Joint Surg Am* 2007;89:2440–2449.
- Skinner SA, Transfeldt EE, Mehbod AA, et al. Electromyography detects mechanically-induced suprasegmental spinal motor tract injury: review of decompression at spinal cord level. *Clin Neurophysiol* 2009;120:754–764.
- van Hal C, Hoebink E, Polak HE, et al. Optimum interpulse interval for transcranial electrical train stimulation to elicit motor evoked potentials of maximal amplitude in both upper and lower extremity target muscles. *Clin Neurophysiol* 2013;124:2054–2059.
- Voulgaris S, Karagiorgiadis D, Alexiou GA, et al. Continuous intraoperative electromyographic and transcranial motor evoked potential recordings in spinal stenosis surgery. *J Clin Neurosci* 2010;17:274–276.