

University of Groningen

Maxillary first molar extraction in Class II malocclusion

Livas, Christos

IMPORTANT NOTE: You are advised to consult the publisher's version (publisher's PDF) if you wish to cite from it. Please check the document version below.

Document Version

Publisher's PDF, also known as Version of record

Publication date:

2015

[Link to publication in University of Groningen/UMCG research database](#)

Citation for published version (APA):

Livas, C. (2015). *Maxillary first molar extraction in Class II malocclusion: Follow-up studies on treatment effects*. [Thesis fully internal (DIV), University of Groningen]. University of Groningen.

Copyright

Other than for strictly personal use, it is not permitted to download or to forward/distribute the text or part of it without the consent of the author(s) and/or copyright holder(s), unless the work is under an open content license (like Creative Commons).

The publication may also be distributed here under the terms of Article 25fa of the Dutch Copyright Act, indicated by the "Taverne" license. More information can be found on the University of Groningen website: <https://www.rug.nl/library/open-access/self-archiving-pure/taverne-amendment>.

Take-down policy

If you believe that this document breaches copyright please contact us providing details, and we will remove access to the work immediately and investigate your claim.

Downloaded from the University of Groningen/UMCG research database (Pure): <http://www.rug.nl/research/portal>. For technical reasons the number of authors shown on this cover page is limited to 10 maximum.

CHAPTER 5

**MAXILLARY SINUS FLOOR EXTENSION AND POSTERIOR
TOOTH INCLINATION IN ADOLESCENT PATIENTS WITH
CLASS II DIVISION 1 MALOCCLUSION TREATED WITH
MAXILLARY FIRST MOLAR EXTRACTIONS**

LIVAS C
HALAZONETIS DJ
BOOIJ JW
PANDIS N
TU YK
KATSAROS C

SUMMARY

Introduction: Our objective was to investigate potential associations between maxillary sinus floor extension and inclination of maxillary second premolars and second molars in patients with Class II Division 1 malocclusion whose orthodontic treatment included maxillary first molar extractions.

Materials and Methods: The records of 37 patients (18 boys, 19 girls; mean age, 13.2 years; SD, 1.62 years), treated between 1998 and 2004 by 1 orthodontist with full Begg appliances were used in this study. Inclusion criteria were: white patients with Class II Division 1 malocclusion, sagittal overjet of ≥ 4 mm, treatment plan including extraction of the maxillary first permanent molars, no missing teeth, and no agenesis. Maxillary posterior tooth inclination and lower maxillary sinus area in relation to the palatal plane were measured on lateral cephalograms at 3 time points: at the start and end of treatment, and on average 2.5 years posttreatment. Data was analyzed for the second premolar and second molar inclinations by using mixed linear models.

Results: The analysis showed that the second molar inclination angle decreased by 7° after orthodontic treatment, compared with pretreatment values, and by 11.5° at the latest follow-up, compared with pretreatment. There was evidence that maxillary sinus volume was negatively correlated with second molar inclination angle; the greater the volume, the smaller the inclination angle. For premolars, inclination increased by 15.4° after orthodontic treatment compared with pretreatment, and by 8.1° at the latest follow-up compared with baseline. The volume of maxillary sinus was not associated with premolar inclination.

Conclusions: We found evidence of an association between maxillary second molar inclination and surface area of the lower sinus in patients treated with maxillary first molar extractions. Clinicians who undertake such an extraction scheme in Class II patients should be aware of this potential association, and consider appropriate biomechanics to control root uprighting.

5.1 INTRODUCTION

The maxillary sinus, the largest of the paranasal sinuses, begins to develop at the ethmoidal infundibulum in the third month of fetal life.¹ After birth, it undergoes rapid growth, extending both laterally and inferiorly, during the first 3 years and from 7 to 12 years of age.² In approximately 50% of the adult population, the sinus invades the maxillary alveolar process, coming in close proximity to the roots of the second premolar and the first and second permanent molars. Occasionally, the sinus floor can extend as far as the region of the canine root.³ Tooth roots that protrude into the maxillary sinus may induce complications in extractions, implantation, endodontic procedures and orthodontic mechanics.⁴

Orthodontic intrusion and bodily movement of teeth across the sinus floor have been found to cause moderate apical root resorption and variable degrees of tipping in experimental and clinical studies.⁵⁻⁷ Up to date the interaction of maxillary sinus development and posterior tooth axial inclinations has not been assessed longitudinally in orthodontic patients. Therefore, the aim of this cephalometric study was to investigate the possible association between maxillary sinus extent and inclination of maxillary second molars and second premolars, in Class II adolescents before and after active orthodontic treatment with extraction of maxillary first molars.

5.2 MATERIALS AND METHODS

The records of 37 patients (18 boys, 19 girls; mean age, 13.2 years; SD, 1.62 years), treated between 1998 and 2004 with extraction of maxillary first permanent molars and full Begg appliances in 1 orthodontist practice were collected.⁸ They represented a subsample from a prospective clinical study with the following inclusion criteria: Caucasians, Class II Division 1 malocclusion, sagittal overjet ≥ 4 mm, no missing teeth, or no agenesis, including maxillary third molars.¹⁰ Standardized lateral cephalograms before and after treatment, and for an average follow-up period of 2.5 years were evaluated by 1 author (C.L.).

The scanning and digitization of all available lateral headfilms were carried out with cephalometric analysis software (Viewbox 3.0; dHAL Software, Kifissia, Greece). Preselected anatomic and dental landmarks were digitized to enable the calculation of the maxillary second premolar (P2) and second molar (M2) inclinations, and lower sinus area (LSA) in relation to the palatal plane (PP). These measurements were defined as follows (Figure 1):

P2-PP, the angle between P2 long axis and PP; M2-PP, the average of the angles constructed by lines crossing the mesiobuccal and distobuccal root apexes and the re-

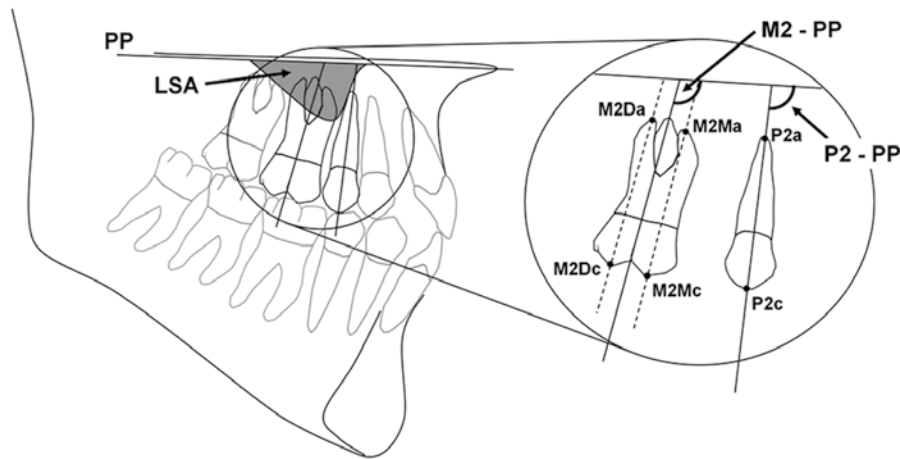


Figure 1. Representation of cephalometric points and measurements (P2-PP, M2-PP, LSA) used in the study (in magnified image: M2Mc, mesial cusp of the maxillary second molar; M2Ma, mesiobuccal root apex of the maxillary second molar; M2Dc, distal cusp of the maxillary second molar; M2Da, distobuccal root apex of the maxillary second molar; P2c, midpoint of the cusp of the maxillary second premolar; P2a, Root apex of the maxillary second premolar). This figure shows the situation after treatment.

spective occlusal cusps, and PP; and LSA, the area established by the outline of the inferior wall of the sinus and PP.

To assess intraexaminer reliability, 30 randomly selected cephalograms were retraced and remeasured by the same investigator after a 2-week interval.

Statistical analysis

Summary values (means, standard deviations) were calculated for age, M2-PP, P2-PP, and LSA for the 3 time points. The effects on tooth inclination, age and lower sinus size on the 3 points (before and after treatment, and at follow-up) were investigated using multilevel modeling, where level 1 was the 3 time points and level 2 was the patients. Multilevel modeling allows for the correlated nature of the data resulting from multiple measurements in the same patients to be considered during the analysis. Statistical significance was set at 5%. All analyses were undertaken by using a statistical software package (version 12.1; StataCorp, College Station, Tx, US).

5.3 RESULTS

Random errors, calculated according to the method of Houston,¹⁰ were 1.08°, 1.48°, and 21.69 mm² for P2, M2, and LSA respectively. Paired t tests on the repeated tracings showed no systematic errors (P>0.05).

Table I displays mean values and standard deviations for age, M2-PP, P2-PP, and LSA by sex and for the 3 time points.

Table II shows the results of the statistical analyses for M2 and P2. Figure 2 displays individual trends for M2 and P2 inclinations at the 3 time points (To-T2).

Specifically for molars, the inclination angles decreased by 7° from before to after treatment, and by 11.5° at the latest follow-up. The difference in baseline angles between boys and girls was very small (0.22°, P=0.83). Age had a negative relation to the inclination angles: ie, older children tended to have smaller inclination angles. The volume of maxillary sinus had a negative association with the inclination angles at each time point, and those associations were statistically significant before and after treatment. This suggests that the greater the volume, the smaller the inclination angles.

	To mean (SD)	T1 mean (SD)	T2 mean (SD)	T1-To mean (SD)	T2-T1 mean (SD)
Boys (n=18)					
Age (y)	13.2 (1.3)	16.1 (1.5)	18.6 (1.5)		
M2-PP (°)	112.3 (5.1)	101.1 (5.4)	96.5 (3.5)	-11.2 (4.7)	-4.6 (3.3)
P2-PP (°)	98.4 (5.0)	106.2 (4.0)	103.8 (3.8)	7.8 (4.0)	-2.4 (3.0)
LSA (mm ²)	48.7 (38.6)	91.6 (33.3)	108.4 (40.1)	42.9 (35.1)	16.8 (14.3)
Girls (n=19)					
Age (y)	13.2 (1.9)	15.6 (2.1)	18.1 (2.2)		
M2-PP (°)	112.4 (4.5)	101.0 (5.5)	97.1 (5.6)	-11.4 (5.8)	-3.9 (4.3)
P2-PP (°)	97.4 (5.1)	106.9 (6.1)	103.7 (5.4)	9.5 (6.5)	-3.2 (3.3)
LSA (mm ²)	62.0 (43.7)	100.5 (43.5)	123.0 (47.3)	38.5 (26.6)	22.5 (18.5)

To, Pretreatment; T1, posttreatment; T2, follow-up.

Table I. Means and SDs in parentheses of age, tooth inclinations, and lower sinus area at 3 time points.

For premolars, the inclination angles increased by 15.4° after active treatment compared with baseline angles, and by 8.1° at posttreatment. The difference in baseline angles between boys and girls was very small (0.3°, P=0.82).

Age also had a negative relationship to premolar inclination angles, meaning that older patients had smaller premolar angles. However, none of these associations were statistically significant. The volume of maxillary sinus did not seem to be associated with premolar axial inclination.

The higher level in the multilevel models was patients whose number was 37, and each patient had 3 repeated observations (the lower level). These are usually sufficient to estimate the random effects at both levels, and Table II shows that the standard errors for the random effects in both models are relatively small, indicating the random-effects estimation is robust.

	M ₂			P ₂		
	β	95% CI	P value	β	95% CI	P value
Fixed effects						
Time						
To-T ₁	-7.02	-19.64 to 5.59	0.28	15.43	2.45 to 28.41	0.02
T ₁ -T ₂	-11.52	-25.46 to 2.42	0.11	8.09	-6.32 to 22.49	0.27
Male	0.22	-1.85 to 2.29	0.83	0.30	-2.27 to 2.87	0.82
Age_To	-0.94	-1.73 to -0.15	0.02	-0.27	-1.15 to 0.61	0.54
Age_T ₁	-0.69	-1.41 to 0.03	0.06	-0.70	-1.50 to 0.10	0.09
Age_T ₂	-0.62	-1.30 to 0.07	0.08	-0.39	-1.15 to 0.37	0.32
LSA_To	-0.01	-0.03 to 0.01	0.54	0.00	-0.02 to 0.03	0.84
LSA_T ₁	-0.05	-0.08 to -0.03	0.00	0.01	-0.02 to 0.03	0.55
LSA_T ₂	-0.04	-0.07 to -0.02	0.00	0.01	-0.02 to 0.04	0.43
_cons*	125.12	114.66 to 135.58	0.00	101.16	89.53 to 112.79	0.00
Random effects						
Level 2 (subjects)	2.62	0.47		3.50	0.54	
Level 1 (residuals)	3.16	0.26		3.24	0.27	

To, Pretreatment; T₂, posttreatment; T₃, follow-up; _cons*, constant.

Table II. Multilevel analysis-derived coefficients (β) and 95% confidence intervals (CIs) for the adjusted effect of LSA on second molar and second premolar inclinations (coefficients correspond to degrees).

5.4 DISCUSSION

This study aimed to document potential changes in the location of the lower surface of the maxillary sinus and the inclinations of the posterior teeth during treatment with maxillary first molar extractions. It is known that a close relationship between the dental roots and the inferior wall of the sinus can impede orthodontic tooth movement.^{5,11}

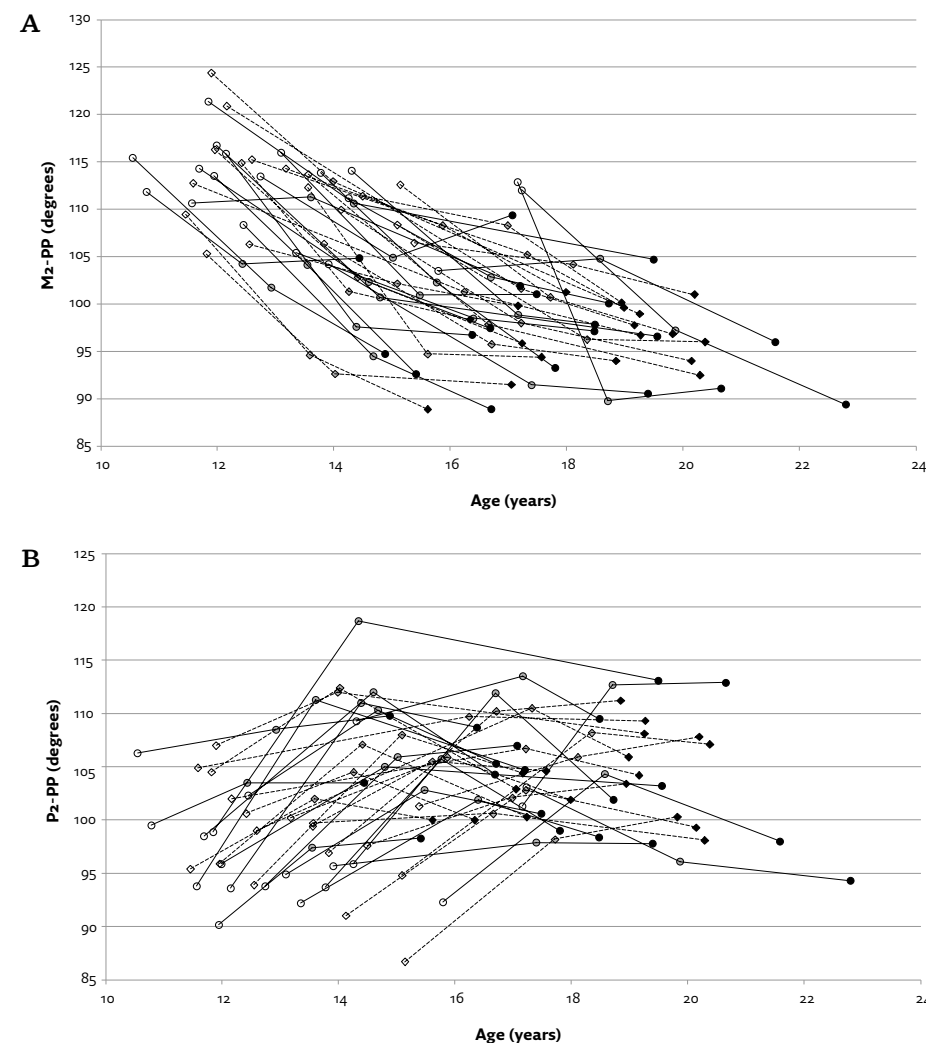


Figure 2. The trends observed in **A**, second molar; **B**, second premolar inclination angles with time (circles and solid lines: females; diamonds and broken lines: males; lighter to darker color signifies treatment stage, To to T₂; lines connect data of the same patient).

Despite the increasing popularity of 3-dimensional radiographic techniques, such as computed tomography and cone-beam computed tomography in orthodontic research, the systematic use of 3-dimensional imaging for diagnostic procedures and treatment planning is still not considered standard care, and it is limited to select clinical conditions.¹² On the other hand, lateral cephalograms are prescribed for most orthodontic patients on a routine basis. At the time this study was conducted, a limited number of cephalometric studies on maxillary sinuses were indexed in elec-

tronic databases. Robinson et al,¹³ by measuring the maxillary sinus on cephalometric radiographs of patients with cleft palate and normal subjects, found no significant differences with respect to size, shape and rate of development. Similarly, a recent cephalometric study in adolescents with different malocclusion classes reported no significant association between maxillary sinus size and sagittal skeletal jaw relationship.¹⁴

However, cephalograms present inherent disadvantages for measuring 3-dimensional structures; distortion, superimposition and differential magnification can lead to misidentification of the sinus outline and measurement errors.¹⁵ Measurement accuracy can also be compromised by volumetric differences between the right and left sides.¹⁶ To minimize such errors, we chose to consider only the sinus outline that extended below the palatal plane. This lower sinus component is closely related to the periapical region of maxillary posterior teeth, and therefore, was considered to be most related to orthodontic intervention. If we had selected the total sinus area, we would not have been able to differentiate between potentially relevant area changes close to the teeth and changes at other distant locations, not related to the dentition.

Statistical analysis showed no evidence of an association between sex and second premolar inclination and molar inclination. The lack of sexual dimorphism on sinus size is consistent with the results of previous cephalometric studies,^{14,17,18} but computed tomography volumetric evaluation has shown sex-specific differences.^{19,20} LSA exhibited expansion between treatment stages, continuing up to the follow-up period, which extended beyond 18 years for most subjects. The age of termination of sinus growth is debatable; some studies have shown cessation by 15 years of age,^{21,22} and others have shown continuing growth in volume during the second decade of life in both sexes.^{19,23} As expected from the aims and biomechanics of treatment, statistically significant changes were identified for posterior tooth inclinations.²⁴ During treatment, P2 inclined distally and M2 mesially; the premolar showed partial relapse during the follow-up period, whereas the molar continued its mesial inclination.

The available literature on orthodontic tooth movement in the region of the maxillary sinus has so far been scarce and comprises mainly case reports²⁵⁻²⁸ and histological analyses of the side effects on bone and dental tissues.^{29,30} Wehrbein et al⁶ found a correlation between the depth of maxillary sinus recess and the degree of tipping of the teeth adjacent to the extraction site; ie, the more vertically extended the sinus, the larger the tooth inclination. We could not establish a correlation between maxillary lower sinus area and second premolar inclination during our observation period. This outcome might have been expected because the maxillary sinus in our sample appeared not to extend exceptionally to the periapical area distal to the second premolar, a finding that is generally reported in the literature.^{31,32}

On the other hand, the statistical analysis demonstrated that LSA was a significant predictor of molar inclination. Of course, this association is indeterminate for a cause-and-effect sequence of events; whether the descent of the sinus was exaggerated because of incomplete molar uprighting or the inferior antral extension inhibited mesial bodily molar movement remains unclear. Nonetheless, given the potential effect of dentition on maxillary sinus development, the second scenario might be more applicable. In particular, tooth extraction seems to result in increase of sinus size³³⁻³⁷ even though opposite views do exist.^{23,38} Extraction studies with³⁴ or without treatment³⁷ have concluded that inferior sinus expansion is greater in first and second maxillary molar extraction cases, in comparison to premolars. The explanation may lie in the large residual osseous defect in the extraction site, and the subsequent reduced bone resistance because of the long healing period of the alveolar socket that allows the sinus to expand.³⁷ Wehrbein and Diedrich³⁴ proposed space closure to be initiated during the healing phase of the alveolar socket in order to restrain further maxillary sinus extension. Our study group experienced a significant increase of maxillary sinus size even during the follow-up phase long after space closure.

The sample of this investigation was unique in that it involved extractions of first molars and longitudinal data was available, covering a considerable posttreatment period. Unfortunately, the retrospective and cross-sectional nature of the records and the lack of control group impose important limitations on this study. Due to the lack of a control group, variability in root inclination might be attributed to factors other than treatment objectives, such as inadvertent differences in mechanotherapy, variability in biological response, and anatomical variations, including sinus development. Nevertheless, the value of this study lies with the unique sample and the fact that allows hypotheses generation that can be tested in a prospective manner in the future. In forthcoming studies, it would also be advantageous to utilize 3-dimensional cone-beam computed tomography data for volumetric evaluation, and a wider age range for assessing sinus development.

5.5 CONCLUSION

Our study demonstrated a significant correlation between extension of the maxillary sinus floor and posttreatment second molar inclination. Diagnosis of a vertically extended maxillary sinus in patients having maxillary first molar extractions should prompt clinicians to plan appropriate space closure and uprighting mechanics.

REFERENCES

1. Scuderi AJ, Harnsberger HR, Boyer RS. Pneumatization of the paranasal sinuses: normal features of importance to the accurate interpretation of CT scans and MR images. *AJR Am J Roentgenol.* 1993;160:1101-1104.
2. Graney DO, Rice DH. Anatomy. In: Cummings CW, Fredrickson JM, Harker LA, Krause CJ, Schuller DE, editors. *Otolaryngology: head and neck surgery*, 2nd ed. St. Louis: Mosby Year Book; 1993. p. 901-906.
3. Hauman CH, Chandler NP, Tong DC. Endodontic implications of the maxillary sinus: a review. *Int Endod J.* 2002;35:127-141.
4. Sharan A, Madjar D. Correlation between maxillary sinus floor topography and related root position of posterior teeth using panoramic and cross-sectional computed tomography imaging. *Oral Surg Oral Med Oral Pathol Oral Radiol Endod.* 2006;102:375-381.
5. Wehrbein H, Bauer W, Schneider B, Diedrich P. Experimental bodily tooth movement through the bony floor of the nose—a pilot study [in German]. *Fortschr Kieferorthop.* 1990;51:271-276.
6. Wehrbein H, Bauer W, Wessing G, Diedrich P. The effect of the maxillary sinus floor on orthodontic tooth movement [in German]. *Fortschr Kieferorthop.* 1990;51:345-351.
7. Daimaruya T, Takahashi I, Nagasaka H, Umemori M, Sugawara J, Mitani H. Effects of maxillary molar intrusion on the nasal floor and tooth root using the skeletal anchorage system in dogs. *Angle Orthod.* 2003;73:158-166.
8. Boonij JW, Kuijpers-Jagtman AM, Katsaros C. A treatment method for Class II Division 1 patients with extraction of permanent maxillary first molars. *World J Orthod.* 2009;10:41-48.
9. Stalpers MJP, Boonij JW, Bronkhorst EM, Kuijpers-Jagtman AM, Katsaros C. Extraction of maxillary first permanent molars in patients with Class II Division 1 malocclusion. *Am J Orthod Dentofacial Orthop.* 2007;132:316-323.
10. Houston WJB. The analysis of errors in orthodontic measurements. *Am J Orthod.* 1983;83:382-389.
11. Fuhrmann R, Bucker A, Diedrich. Radiological assessment of artificial bone defects in the floor of the maxillary sinus. *Dentomaxillofac Radiol.* 1997;26:112-116.
12. Pazera P, Bornstein MM, Pazera A, Sendi P, Katsaros C. Incidental maxillary sinus findings in orthodontic patients: a radiographic analysis using cone-beam computed tomography (CBCT). *Orthod Craniofac Res.* 2011;14:17-24.
13. Robinson HE, Zerlin GK, Passy V. Maxillary sinus development in patients with cleft palates as compared to those with normal palates. *Laryngoscope.* 1982;92:183-187.
14. Endo T, Abe R, Kuroki H, Kojima K, Oka K, Shimooka S. Cephalometric evaluation of maxillary sinus sizes in different malocclusion classes. *Odontology.* 2010;98:65-72.
15. Farronato G, Garagiola U, Dominici A, Periti G, de Nardi S, Carletti V, Farronato D. BHG 'Ten-point' 3D cephalometric analysis using low-dosage cone beam computed tomography. *Prog Orthod.* 2010;11:2-12.
16. Spaeth J, Krügelstein U, Schlöndorff G. The paranasal sinuses in CT-imaging: development from birth to age 25. *Int J Pediatr Otorhinolaryngol.* 1997;39:25-40.
17. Oktay H. The study of the maxillary sinus areas in different orthodontic malocclusions. *Am J Orthod Dentofacial Orthop.* 1992;102:143-145.
18. Barghouth G, Prior JO, Lepori D, Duvoisin B, Schnyder P, Gudinchet F. Paranasal sinuses in children: size evaluation of maxillary, sphenoid, and frontal sinuses by magnetic resonance imaging and proposal of volume index percentile curves. *Eur Radiol.* 2002;12:1451-1458.
19. Jun BC, Song SW, Park CS, Lee DH, Cho KJ, Cho JH. The analysis of maxillary sinus aeration according to aging process; volume assessment by 3-dimensional reconstruction by high-resolution CT scanning. *Otolaryngol Head Neck Surg.* 2005;132:429-434.
20. Emirzeoglu M, Sahin B, Bilgic S, Celebi M, Uzun A. Volumetric evaluation of the paranasal sinuses in normal subjects using computer tomography images: a stereological study. *Auris Nasus Larynx.* 2007;34:191-195.
21. Ikeda A. Volumetric measurement of the maxillary sinus by coronal CT scan. *Nihon Jibiinkoka Gakkai Kaiho.* 1996;99:1136-1143.
22. Park IH, Song JS, Choi H, Kim TH, Hoon S, Lee SH, Lee HM. Volumetric study in the development of paranasal sinuses by CT imaging in Asian: a pilot study. *Int J Pediatr Otorhinolaryngol.* 2010;74:1347-1350.
23. Arijji Y, Kuroki T, Moriguchi S, Arijji E, Kanda S. Age changes in the volume of the human maxillary sinus: a study using computed tomography. *Dentomaxillofac Radiol.* 1994;23:163-168.
24. Boonij JW, Goeke J, Bronkhorst EM, Panchez H, Ruf S, Katsaros C. Overjet correction and space closure mechanisms for Class II treatment by extracting the maxillary first molars. *J Orofac Orthop.* 2011;72:196-203.
25. Cacciafesta V, Melsen B. Mesial bodily movement of maxillary and mandibular molars with segmented mechanics. *Clin Orthod Res.* 2001;4:182-188.
26. Re S, Cardaropoli D, Corrente G, Abundo R. Bodily tooth movement through the maxillary sinus with implant anchorage for single tooth replacement. *Clin Orthod Res.* 2001;4:177-181.
27. Kravitz ND, Kusnoto B, Tsay PT, Hohlt WF. Intrusion of overerupted upper first molar using two orthodontic miniscrews. A case report. *Angle Orthod.* 2007;77:915-922.
28. Park HS, Jang BK, Kyung HM. Maxillary molar intrusion with micro-implant anchorage (MIA). *Aust Orthod J.* 2005;21:129-135.
29. Wehrbein H, Fuhrmann RA, Diedrich PR. Human histologic tissue response after long-term orthodontic tooth movement. *Am J Orthod Dentofacial Orthop.* 1995;107:360-371.
30. Fuhrmann R. Three-dimensional interpretation of periodontal lesions and remodeling during orthodontic treatment. Part III. *J Orofac Orthop.* 1996;57:224-237.
31. Eberhardt JA, Torabinejad M, Christiansen EL. A computed tomographic study of the distances between the maxillary sinus floor and the apices of the maxillary posterior teeth. *Oral Surg Oral Med Oral Pathol.* 1992;73:345-346.
32. Kwak HH, Park HD, Yoon HR, Kang MK, Koh KS, Kim HJ. Topographic anatomy of the inferior wall of the maxillary sinus in Koreans. *Int J Oral Maxillofac Surg.* 2004;33:382-388.
33. Rosen MD, Sarnat BG. Change of volume of the maxillary sinus of the dog after extraction of adjacent teeth. *Oral Surg Oral Med Oral Pathol.* 1955;8:420-429.

34. Wehrbein H, Diedrich P. Progressive pneumatization of the basal maxillary sinus after extraction and space closure [in German]. *Fortschr Kieferorthop.* 1992;53:77-83.
35. Harorh A, Bocutoglu O. The comparison of vertical height and width of maxillary sinus by means of Waters' view radiograms taken from dentate and edentulous cases. *Ann Dent.* 1995;54:47-49.
36. Ohba T, Langlais RP, Morimoto Y, Tanaka T, Hashimoto K. Maxillary sinus floor in edentulous and dentate patients. *Indian J Dent Res.* 2001;12:121-125.
37. Sharan A, Madjar D. Maxillary sinus pneumatization following extractions: a radiographic study. *Int J Oral Maxillofac Implants.* 2008;23:48-56.
38. Arijji Y, Arijji E, Yoshiura K, Kanda S. Computed tomographic indices for maxillary sinus size in comparison with the sinus volume. *Dentomaxillofac Radiol.* 1996;25:19-24.