

University of Groningen

Maxillary first molar extraction in Class II malocclusion

Livas, Christos

IMPORTANT NOTE: You are advised to consult the publisher's version (publisher's PDF) if you wish to cite from it. Please check the document version below.

Document Version

Publisher's PDF, also known as Version of record

Publication date:

2015

[Link to publication in University of Groningen/UMCG research database](#)

Citation for published version (APA):

Livas, C. (2015). *Maxillary first molar extraction in Class II malocclusion: Follow-up studies on treatment effects*. [Thesis fully internal (DIV), University of Groningen]. University of Groningen.

Copyright

Other than for strictly personal use, it is not permitted to download or to forward/distribute the text or part of it without the consent of the author(s) and/or copyright holder(s), unless the work is under an open content license (like Creative Commons).

The publication may also be distributed here under the terms of Article 25fa of the Dutch Copyright Act, indicated by the "Taverne" license. More information can be found on the University of Groningen website: <https://www.rug.nl/library/open-access/self-archiving-pure/taverne-amendment>.

Take-down policy

If you believe that this document breaches copyright please contact us providing details, and we will remove access to the work immediately and investigate your claim.

Downloaded from the University of Groningen/UMCG research database (Pure): <http://www.rug.nl/research/portal>. For technical reasons the number of authors shown on this cover page is limited to 10 maximum.

CHAPTER 3

**INFLUENCE OF UNILATERAL MAXILLARY FIRST
MOLAR EXTRACTION ON SECOND AND THIRD MOLAR
INCLINATION IN CLASS II SUBDIVISION PATIENTS**

LIVAS C
PANDIS N
BOOIJ JW
HALAZONETIS DJ
KATSAROS C
REN Y

SUMMARY

Introduction: To assess the maxillary second molar (M2) and third molar (M3) inclination following orthodontic treatment of Class II subdivision malocclusion with unilateral maxillary first molar (M1) extraction.

Materials and Methods: Panoramic radiographs of 21 Class II subdivision adolescents (8 boys, 13 girls; mean age, 12.8 years; standard deviation, 1.7 years) before treatment, after treatment with extraction of one maxillary first molar and Begg appliances and after at least 1.8 years in retention were retrospectively collected from a private practice. M2 and M3 inclination angles (M2/ITP, M2/IOP, M3/ITP, M3/IOP), constructed by intertuberosity (ITP) and interorbital planes (IOP), were calculated for the extracted and nonextracted segments. Random effects regression analysis was performed to evaluate the effect on the molar angulation of extraction, time, and gender after adjusting for baseline measurements.

Results: Time and extraction status were significant predictors for M2 angulation. M2/ITP and M2/IOP decreased by 4.04° (95% confidence interval [CI]: -6.93, -1.16; $P = 0.001$) and 3.67° (95% CI: -6.76, -0.58; $P = 0.020$) in the extraction group compared to the nonextraction group after adjusting for time and gender. The adjusted analysis showed that extraction was the only predictor for M3 angulation that reached statistical significance. M3 mesial inclination increased by 7.38° (95% CI: -11.2, -3.54; $P < 0.001$) and 7.33° (95% CI: -11.48, -3.19; $P = 0.001$).

Conclusions: M2 and M3 uprighting significantly improved in the extraction side after orthodontic treatment with unilateral maxillary M1 extraction. There was a significant increase in mesial tipping of maxillary second molar crowns over time.

3.1 INTRODUCTION

The prognosis of the third molar (M3) eruption is one of the clinical issues encountered by orthodontists while treating adolescents. M3 impaction represents the most common tooth impaction in contemporary populations.¹ Controversies have been reported with regard to the incidence of M3 impaction related to gender, ethnicity, and location.² There is evidence that factors such as vertical growth pattern, reduced mandibular length, molar axial inclination, and delayed maturation may influence the likelihood of M3 eruption.^{3,4} Overall, impacted maxillary third molars do not remain static; however, their position over time may be considered unpredictable, as indicated by the limited longitudinal data.⁵

In theory, extraction of posterior teeth followed by orthodontic mesialization of the buccal segments may enhance the mesioangular inclination, and therefore the eruption status, of M3s. Orthodontic treatment involving extraction of two maxillary first premolars,⁶ four first premolars,⁷ or four first molars⁸ resulted in significant improvement in the developing M3 position compared to nonextraction therapy. Other researchers observed no significant differences on the final M3 angulation between subjects orthodontically treated with either first premolar extraction and nonextraction^{1,9} or first premolar and second molar (M2) extractions.¹⁰

To date, M3 mesiodistal angulation after asymmetric extraction has been scarcely subjected to investigation.^{11,12} A retrospective study¹² of spontaneous positional changes in mandibular M3s after unilateral mandibular first molar (M1) extraction for non-orthodontic purposes demonstrated improved positions of the M3s. Furthermore, in an asymmetric extraction subgroup of orthodontic patients undergoing maxillary M2 extractions, the eruption rate of third molars was accelerated on the extraction side.¹¹

The objective of this study was to determine the posttreatment angulation changes of maxillary second and third molars in a sample of Class II subdivision adolescents treated with unilateral maxillary M1 extraction and fixed orthodontic appliances.

3.2 MATERIALS AND METHODS

A sample of 21 Class II subdivision adolescents (8 boys, 13 girls; mean age, 12.8 years; SD, 1.7 years) consecutively treated with unilateral extraction of a maxillary M1 and Begg technique was retrospectively collected from the archives of a private practice in Gorinchem, The Netherlands.¹³⁻¹⁵ The rest of the inclusion criteria were as follows: whites; Class II $\geq 1/2$ premolar width molar occlusion on one buccal segment and Class I on the contralateral segment; up to mild crowding in the mandibular arch; full complement of permanent teeth; and panoramic radiographs of good quality ob-

tained pretreatment (T₁), posttreatment (T₂), and at a minimum follow-up period (T₃) of 1.8 years (mean follow-up, 2.6 years; SD, 1.0 years) (Table I). The right maxillary M1 was extracted in 14 subjects, whereas the left M1 was extracted in seven of the cases. The nonextraction side served as the control.

	Males (n=8)	Females (n=13)
Age T ₁	13.2 (0.8)	12.6 (2.0)
Age T ₂	15.5 (1.0)	14.8 (2.1)
Age T ₃	17.5 (1.0)	17.8 (2.4)
T ₂ -T ₁	2.2 (0.4)	
T ₃ -T ₂	2.6 (1.0)	

Table I. Age of subjects and time intervals in years (means, SDs in parentheses), T₁ indicates pre-treatment; T₂, posttreatment; and T₃, minimum follow-up period.

Scanning of the panoramic radiographs (Epson Expression 1680 Pro, Suwa, Nagano, Japan; resolution of 600 dpi) and digitization of landmarks by means of specialized software (Viewbox 3.0; dHAL Software, Kifissia, Greece) were performed by the first author. The landmarks, reference planes, and angular measurements⁶ used for the study are displayed in Figure 1. Molar inclination was estimated using the following angles: M₂/IOP, the angle between the M₂ long axis and the interorbital plane (IOP); M₃/IOP, the angle between the M₃ long axis and the IOP; M₂/ITP, the angle between the M₂ long axis and the inter-tuberosity plane (ITP); M₃/ITP, the angle between the M₃ long axis and the ITP (Figure 1). Given the stage of the root development, the most apical point visible on the panoramic radiograph was selected as the midpoint of the root apex. To determine intraobserver agreement, 14 randomly selected sets of variables were remeasured 2 weeks after the initial assessment.

Statistical Analysis

Means and SDs were estimated for all four molar angular measurements. The intra-class correlation coefficient (ICC) was calculated to assess intraobserver reliability. The Pearson's correlation coefficient (r) was calculated between the two different plane-defined measurements. Random effects regression analysis was implemented in order to assess the effect on the molar angulation of extraction, time, and gender after adjusting for baseline measurements. A 0.05 level of significance was used to determine statistically significant effects. Statistical analysis was carried out with the STATA statistical software package (STATA[®] 13, Stata Corporation, College Station, Tx, US).

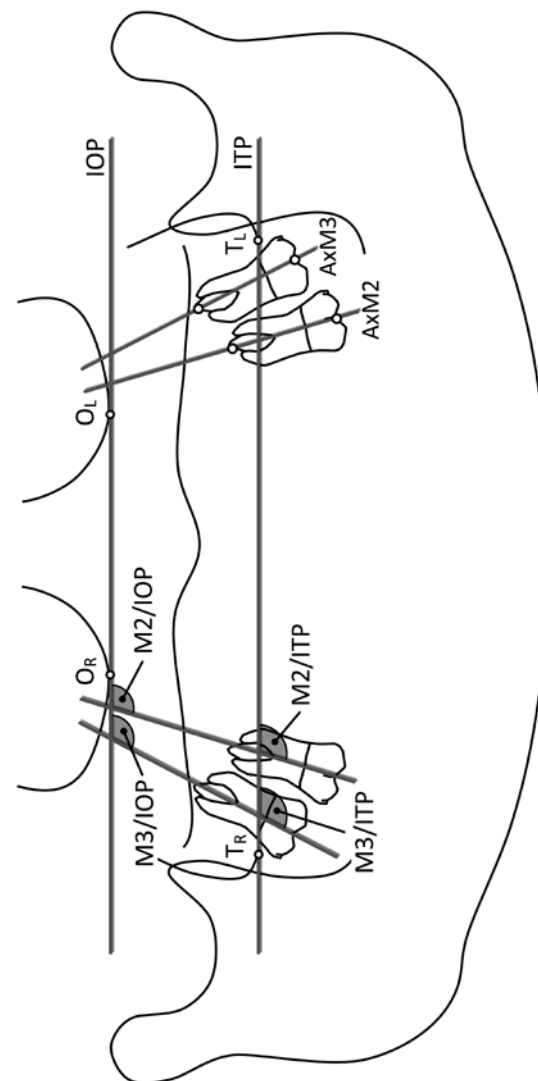


Figure 1. Landmarks: Right orbital (OR) indicates most inferior point of the right orbital cavity; left orbital (OL), most inferior point of the left orbital cavity; right tuberosity (TR), most inferior point of the right maxillary tuberosity; and left tuberosity (TL), most inferior point of the left maxillary tuberosity. Reference planes: interorbital plane (IOP), plane defined by OR and OL; intertuberosity plane (ITP), plane defined by TR and TL; AxM2, AxM3: M₂ and M₃ long axes constructed by the midpoints of the occlusal surfaces and root apices of the molars. M₂ and M₃ inclination angles: M₂/IOP, M₃/IOP, M₂/ITP, and M₃/ITP.

3.3 RESULTS

The ICC values ranged from 0.95 to 0.97 for all angular variables, reflecting excellent intraobserver reliability. All measurements conducted using both planes were highly correlated ($r = 0.99-1.00$).

Descriptive statistics (means, SDs) are summarized in Table I. Means and SDs of the measured angular variables are presented for the extraction and nonextraction sides in Table II.

All molar measurements exhibited increasingly improved mesial inclination (ie, smaller angular values between T1-T2) regardless of whether teeth had been extracted or not. This tendency for an increase in the mesial tipping of the molar crowns was more evident in the segments in which the M1 had been extracted (Figure 2).

The statistical analysis (Table III) indicated that for M2 angulations both extraction and time were significant predictors of the final outcome, whereas gender was not. In more detail, for M2/ITP and M2/IOP there was a decrease of 4.04° in the extraction group (95% CI: $-6.93, -1.16$; $P = 0.001$) and of 3.67° (95% CI: $-6.76, -0.58$; $P = 0.020$), respectively, compared to the nonextraction group, after adjusting for time and gender.

The adjusted analysis also showed that extraction was the only predictor for the angulation of maxillary third molars related to the intertuberosity and interorbital planes that reached statistical significance. M3 mesial inclination increased by 7.38° (95% CI: $-11.22, -3.54$; $P < 0.001$) and 7.33° (95% CI: $-11.48, -3.19$; $P = 0.001$). There was evi-

Variable	T ₁		T ₂		T ₃		
	Extraction	Nonextraction	Extraction	Nonextraction	Extraction	Nonextraction	
M2/IOP (°)	113.3 (7.3)	114.3 (7.3)	105.2 (8.4)	108.5 (8.0)	101.1 (7.9)	105.9 (10.0)	
M3/IOP (°)	126.5 (13.7)	123.2 (11.1)	107.7 (11.3)	117.2 (11.9)	107.3 (8.6)	112.7 (13.5)	
M2/ITP (°)	113.6 (7.4)	114.0 (7.1)	105.2 (8.3)	108.7 (7.7)	101.0 (7.6)	105.9 (9.6)	
M3/ITP (°)	126.8 (13.8)	122.9 (10.9)	107.6 (10.5)	117.3 (11.5)	107.2 (8.8)	112.7 (12.9)	
		T ₂ -T ₁		T ₃ -T ₂		T ₃ -T ₁	
M2/IOP (°)	-8.1 (12.0)	-5.7 (7.4)	-4.1 (8.5)	-2.7 (6.4)	-12.3 (9.9)	-8.4 (8.0)	
M3/IOP (°)	-18.8 (17.3)	-6.0 (16.5)	-0.4 (11.3)	-4.5 (10.2)	-19.3 (16.0)	-10.5 (15.0)	
M2/ITP (°)	-8.4 (11.5)	-5.4 (7.7)	-4.1 (8.2)	-2.7 (6.8)	-12.6 (9.4)	-8.1 (7.8)	
M3/ITP (°)	-19.2 (16.9)	-5.6 (16.3)	-0.4 (10.6)	-4.6 (10.2)	-19.6 (16.6)	-10.2 (14.6)	

Table II. Means and SDs of the angular measurements for the extraction (n=21) and nonextraction (n=21) sides, T₁ indicates pretreatment; T₂, posttreatment; T₃, minimum follow-up period; M₂, second molar; M₃, third molar; ITP, intertuberosity; and IOP, interorbital planes.

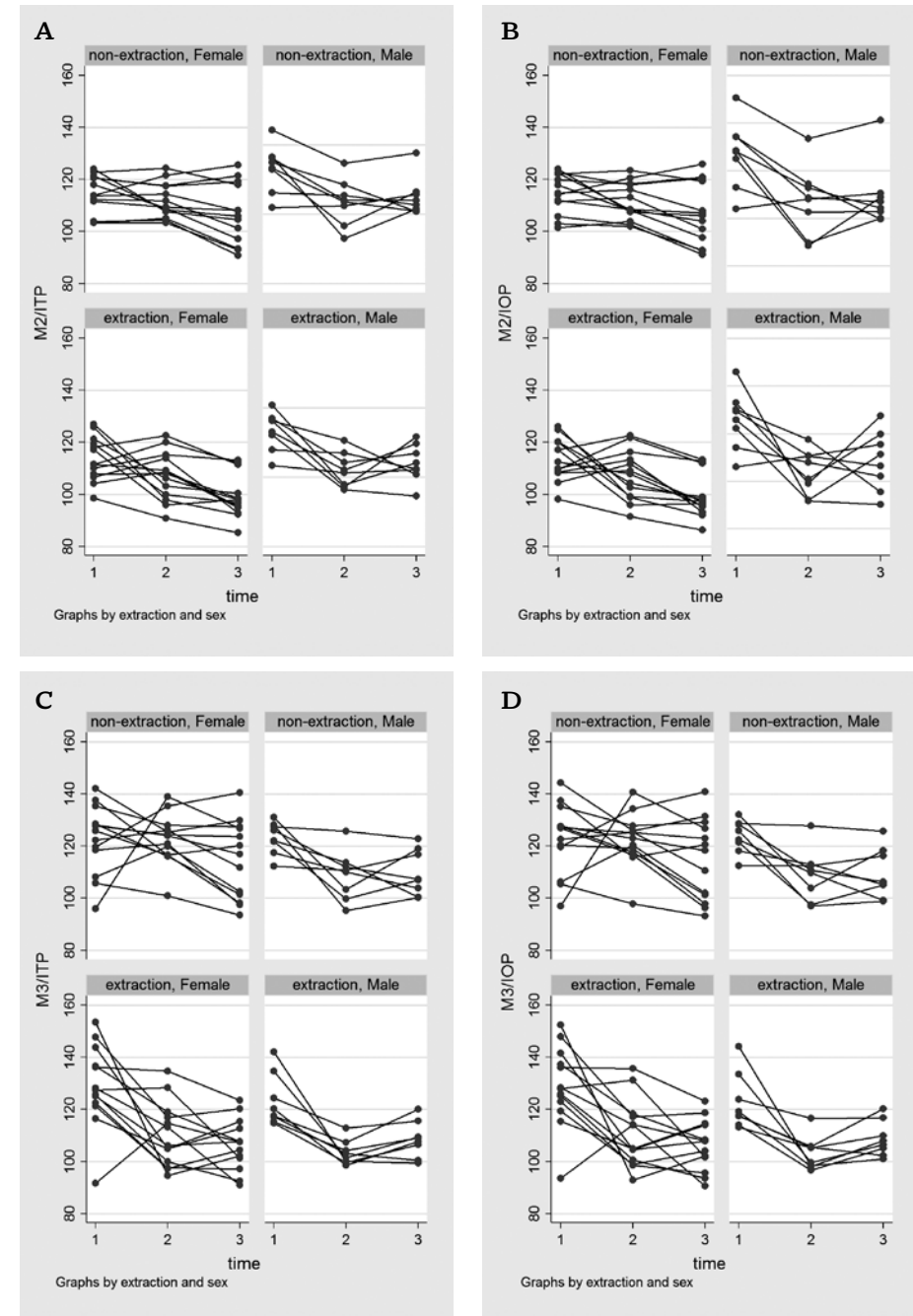


Figure 2. Angulation changes of second and third molars by extraction-nonextraction group, sex, and time point per patient (A: M₂/ITP; B: M₂/IOP; C: M₃/ITP; and D: M₃/IOP).

dence that gender was associated with third molar angulations; however, this difference did not reach statistical significance at the 5% level. Age appeared similar among treatment groups and was not found to be a significant predictor, and, therefore, it was not included in the final analysis.

3.4 DISCUSSION

Our study shows that maxillary second and third molars moved to more favourable positions after treatment regardless of the M1 extraction. These M3 angulation findings are in line with comparative studies^{1,9} of samples treated with first premolar extraction and nonextraction approaches. However, maxillary second molars in the extraction side became 1.4–1.6 times more upright than the contralateral teeth at T2, whereas the mesial inclination of maxillary third molars increased by 3.1–3.4 times. Likewise, bilateral M1 extraction and fixed orthodontic treatment with Begg appliances in Class II Division 1 patients led to a fourfold uprighting of maxillary third molars in comparison to nonextraction controls.¹⁶ On the other hand, Class II individuals treated with two maxillary first premolar extractions demonstrated a double increase in the mesial inclination of maxillary third molars compared with those treated via the nonextraction route.⁶ In extraction treatment planning (premolars or molars), differences in the intra-arch location of the extraction site and in the amount of tooth mass removed should be considered.⁶ The closer the position of the extracted tooth to the maxillary third molar, the more influential will be the extraction on the M3 development.¹⁷ In this context, molar extraction protocols may produce more favourable conditions for M3 uprighting than do premolar extractions. Nevertheless, the available eruption space may be drastically reduced during orthodontic management of severe Class II malocclusion and crowded cases.

Based on the regression analysis results, improved inclinations of maxillary second and third molars may be expected after Class II subdivision treatment with a single M1 extraction. In addition to this, time was a significant predictor for second molar angulation. Thus, maxillary second molars involved in fixed orthodontic treatment of asymmetric Class II malocclusion are likely to present smaller inclination angles over time, notwithstanding whether or not the maxillary first molars are extracted in one segment.

Direct comparison of published studies on the effect of orthodontic extractions on M3 eruption may not be feasible as a result of methodological issues such as lack of control groups,^{11,18–21} unclear definition of malocclusion, discrepancies in anchorage requirements, mixed extraction protocols,^{11,21,22} examination of radiographic records other than panoramic radiographs,^{11,15,21} or inclusion of linear rather than angular measurements.^{8,11,21}

M2/ITP	Coefficient	P value	95% CI
Time	-3.42	0.020	-6.30, -0.54
M2/ITP (T1)	0.42	0.002	0.15, 0.69
Gender			
Female	Reference		
Male	-2.20	0.330	-6.63, 2.23
Extraction			
No	Reference		
Yes	-4.04	0.006	-6.93, -1.16
M2/IOP	Coefficient	P value	95% CI
Time	-3.42	0.029	-6.50, -0.35
M2/IOP (T1)	0.40	0.004	0.13, 0.68
Gender			
Female	Reference		
Male	-2.20	0.328	-6.61, 2.21
Extraction			
No	Reference		
Yes	-3.67	0.020	-6.76, -0.58
M3/ITP	Coefficient	P value	95% CI
Time	-2.48	0.197	-6.25, 1.28
M3/ITP (T1)	-0.06	0.535	-0.26, 0.13
Gender			
Female	Reference		
Male	-6.03	0.063	-12.39, 0.34
Extraction			
No	Reference		
Yes	-7.38	<0.001	-11.22, -3.54
M3/IOP	Coefficient	P value	95% CI
Time	-2.47	0.237	-6.55, 1.62
M3/IOP (T1)	-0.04	0.733	-0.24, 0.17
Gender			
Female	Reference		
Male	-5.96	0.063	-12.24, 0.32
Extraction			
No	Reference		
Yes	-7.33	0.001	-11.48, -3.19

Table III. Coefficients, associated confidence intervals (95% CIs), and P values from the random effects analysis for second and third molars; M2/ITP (T1), M2/IOP (T1), M3/ITP (T1), M3/IOP (T1), baseline values of M2 and M3 Inclination, T1 indicates pretreatment; M2, second molar; M3, third molar; ITP, intertuberosity; and IOP, interorbital planes.

Use of consistently identifiable reference landmarks is a matter of concern in consecutive measurements. Jain and Valiathan⁷ defined angulation of mandibular second and third molars in relation to a horizontal palatal plane constructed from the anterior nasal spine and the nasal spectrum. However, these authors omitted assessment of the reproducibility in terms of locating the definition landmarks. Others^{1,8-10,12,20} used the occlusal plane to measure tooth inclination changes, in spite of its reliance on treatment mechanics. In our study, we selected instead two horizontal reference planes based on skeletal structures, of which the repeatability had been validated by previous research.⁶ Despite the high correlation between the measurements defined by the two planes, we decided to use both types to increase measurement validity.

We aimed to measure on orthopantomograms molar angular changes in the sagittal plane following extraction of a maxillary M1 and orthodontics. However, variations of the molar position in the buccolingual direction or rotations around the tooth long axis could not be considered because of the inherent panoramic image distortions.²³⁻²⁶ Increased buccal root may resemble distal tipping, while increased lingual root torque may appear as more mesial tipping on panoramic radiographs.²⁶ Therefore, the use of panoramic images to assess root angulation should be approached with extreme caution and understanding of the technical limitations. In this sense, rotated, buccally or lingually displaced molars may need to undergo a second short fixed appliance treatment to obtain proper occlusal contacts.

Another point of discussion may be related to the length of the observation period. Our follow-up did not extend beyond the expected eruption time of maxillary third molars, and, thus, the actual improvement in M3 position might have been underestimated. A second follow-up study may yield more useful conclusions on the treatment effect on the eruption success of maxillary third molars.

To our knowledge, this is the first study of split-mouth design to examine the influence of asymmetric maxillary M1 extraction on the axial inclination of adjacent molars. The split-mouth design reduces interindividual variability from estimates of the treatment effect, and therefore may be considered advantageous.²⁷

3.5 CONCLUSIONS

- Orthodontic treatment with unilateral maxillary M1 extraction resulted in a significant increase in the mesial inclination of maxillary second and third molars.
- Maxillary second molar crowns significantly tipped over time on both extraction and nonextraction sides.

REFERENCES

1. Saysel MY, Meral GD, Kocadereli I, Tasar F. The effects of first premolar extractions on third molar angulations. *Angle Orthod.* 2005;75:719-722.
2. Topkara A, Sari Z. Investigation of third molar impaction in Turkish orthodontic patients: prevalence, depth and angular positions. *Eur J Dent.* 2013;7:S94-98.
3. Björk A, Jensen E, Palling M. Mandibular growth and third molar impaction. *Acta Odontol Scand.* 1956;14:231-272.
4. Capelli J Jr. Mandibular growth and third molar impaction in extraction cases. *Angle Orthod.* 1991;61:223-229.
5. Phillips C, White RP Jr. How predictable is the position of third molars over time? *J Oral Maxillofac Surg.* 2012;70:S11-14.
6. Janson G, Putrick LM, Henriques JF, de Freitas MR, Henriques RP. Maxillary third molar position in Class II malocclusions: the effect of treatment with and without maxillary premolar extractions. *Eur J Orthod.* 2006;28:573-579.
7. Jain S, Valiathan A. Influence of first premolar extraction on mandibular third molar angulation. *Angle Orthod.* 2009;79:1143-1148.
8. Bayram M, Ozer M, Arici S. Effects of first molar extraction on third molar angulation and eruption space. *Oral Surg Oral Med Oral Pathol Oral Radiol Endod.* 2009;107:e14-20.
9. Staggers JA, Germane N, Fortson WM. A comparison of the effects of first premolar extractions on third molar angulation. *Angle Orthod.* 1992;62:135-138.
10. Staggers JA. A comparison of results of second molar and first premolar extraction treatment. *Am J Orthod Dentofacial Orthop.* 1990;98:430-436.
11. Moffitt AH. Eruption and function of maxillary third molars after extraction of second molars. *Angle Orthod.* 1998;68:147-152.
12. Ay S, Agar U, Biçakçı AA, Köşger HH. Changes in mandibular third molar angle and position after unilateral mandibular first molar extraction. *Am J Orthod Dentofacial Orthop.* 2006;129:36-41.
13. Livas C, Pandis N, Booij JW, Katsaros C, Ren Y. Long-term evaluation of Class II subdivision treatment with unilateral maxillary first molar extraction. *Angle Orthod.* 2014 Nov 11. [Epub ahead of print]
14. Booij JW, Kuijpers-Jagtman AM, Katsaros C. A treatment method for Class II division 1 patients with extraction of permanent maxillary first molars. *World J Orthod.* 2009;10:41-48.
15. Mock L, Booij JW. Correction of an Angle Class II/subdivision with unilateral maxillary molar extraction. *Inf Orthod Kieferorthop.* 2010;42:63-67.

16. Livas C, Halazonetis DJ, Boonij JW, Katsaros C. Extraction of maxillary first molars improves second and third molar inclinations in Class II division 1 malocclusion. *Am J Orthod Dentofacial Orthop.* 2011;140:377-382.
17. Yavuz I, Baydaş B, İkbal A, Dağsuyu IM, Ceylan I. Effects of early loss of permanent first molars on the development of third molars. *Am J Orthod Dentofacial Orthop.* 2006;130: 634-638.
18. Jager A, el-Kabarity A, Singelmann C. Evaluation of orthodontic treatment with early extraction of second molars. *J Orofac Orthop.* 1997;58:30-43.
19. Elsey MJ, Rock WP. Influence of orthodontic treatment on development of third molars. *Br J Oral Maxillofac Surg.* 2000;38:350-353.
20. Orton-Gibbs S, Crow V, Orton HS. Eruption of third permanent molars after the extraction of second permanent molars. Part 1: assessment of third molar position and size. *Am J Orthod Dentofacial Orthop.* 2001;119:226-238.
21. De-la-Rosa-Gay C, Valmaseda-Castellón E, Gay-Escoda C. Spontaneous third-molar eruption after second-molar extraction in orthodontic patients. *Am J Orthod Dentofacial Orthop.* 2006;129:337-344.
22. Kim TW, Årtun J, Behbehani F, Artese F. Prevalence of third molar impaction in orthodontic patients treated nonextraction and with extraction of 4 premolars. *Am J Orthod Dentofacial Orthop.* 2003;123:138-145.
23. Scarfe WC, Nummikoski P, McDavid WD, Welander U, Tronje G. Radiographic interproximal angulations: implications for rotational panoramic radiography. *Oral Surg Oral Med Oral Pathol.* 1993;76:664-672.
24. Mckee IW, Williamson PC, Lam EW, Heo G, Glover KE, Major PW. The accuracy of panoramic units in the projection of mesiodistal tooth angulations. *Am J Orthod Dentofacial Orthop.* 2002;121:166-175.
25. Garcia-Figueroa MA, Raboud DW, Lam EW, Heo G, Major PW. Effect of buccolingual root angulation on the mesiodistal angulation shown on panoramic radiographs. *Am J Orthod Dentofacial Orthop.* 2008;134:93-99.
26. Bouwens DG, Cevitanes L, Ludlow JB, Phillips C. Comparison of mesiodistal root angulation with posttreatment panoramic radiographs and cone-beam computed tomography. *Am J Orthod Dentofacial Orthop.* 2011;139:126-132.
27. Lesaffre E, Philstrom B, Needleman I, Worthington H. The design and analysis of split mouth studies: what statisticians and clinicians should know. *Stat Med.* 2009;28:3470-3482.