

University of Groningen

Today's Mistakes and Tomorrow's Wisdom in Endoscopic Imaging of Barrett's Esophagus

van Heijst, Lianne; Zhao, Xiaojuan; Gabriels, Ruben; Nagengast, Wouter

Published in:
Visceral Medicine

DOI:
[10.1159/000523907](https://doi.org/10.1159/000523907)

IMPORTANT NOTE: You are advised to consult the publisher's version (publisher's PDF) if you wish to cite from it. Please check the document version below.

Document Version
Publisher's PDF, also known as Version of record

Publication date:
2022

[Link to publication in University of Groningen/UMCG research database](#)

Citation for published version (APA):
van Heijst, L., Zhao, X., Gabriels, R., & Nagengast, W. (2022). Today's Mistakes and Tomorrow's Wisdom in Endoscopic Imaging of Barrett's Esophagus. *Visceral Medicine*, 38(3), 182–188.
<https://doi.org/10.1159/000523907>

Copyright

Other than for strictly personal use, it is not permitted to download or to forward/distribute the text or part of it without the consent of the author(s) and/or copyright holder(s), unless the work is under an open content license (like Creative Commons).

The publication may also be distributed here under the terms of Article 25fa of the Dutch Copyright Act, indicated by the "Taverne" license. More information can be found on the University of Groningen website: <https://www.rug.nl/library/open-access/self-archiving-pure/taverne-amendment>.

Take-down policy

If you believe that this document breaches copyright please contact us providing details, and we will remove access to the work immediately and investigate your claim.

Downloaded from the University of Groningen/UMCG research database (Pure): <http://www.rug.nl/research/portal>. For technical reasons the number of authors shown on this cover page is limited to 10 maximum.

Today's Mistakes and Tomorrow's Wisdom in Endoscopic Imaging of Barrett's Esophagus

Lisanne E. van Heijst^a Xiaojuan Zhao^{a,b} Ruben Y. Gabriëls^a
Wouter B. Nagengast^a

^aDepartment of Gastroenterology and Hepatology, University Medical Center Groningen, University of Groningen, Groningen, The Netherlands; ^bDepartment of Gastroenterology, The Fifth Affiliated Hospital, Sun Yat-sen University, Zhuhai, China

Keywords

Barrett's esophagus · Chromoendoscopy · Computer-aided detection · Esophageal adenocarcinoma · Molecular imaging

Abstract

Background: Esophageal adenocarcinoma (EAC) is one of the main causes of cancer-related deaths worldwide and its incidence is rising. Barrett's esophagus (BE) can develop low- and high-grade dysplasia which can progress to EAC overtime. The golden standard to detect dysplastic BE (DBE) or EAC is surveillance with high-definition white-light endoscopy (HD-WLE) and random biopsies according to the Seattle protocol. However, this method is time-consuming and associated with a remarkable miss rate. Therefore, there is great need for the development of novel reliable techniques to optimize surveillance strategies and improve detection rates. **Summary:** Optical chromoendoscopy (OC) techniques like narrow-band imaging have shown improved detection of DBE and EAC compared to HD-WLE and random biopsies. Most recent OC techniques, including the iSCAN optical enhancement system and linked color imaging, showed improved characterization of DBE and EAC retrospectively. Fluorescence molecular endoscopy (FME) presented promising results to highlight DBE and EAC. Moreover, with the establishment of well-performing delineation computer-aided detection (CAD) algorithms and the first real-time CAD sys-

tem for EAC, we expect clinical application of CAD in the near future. **Key Messages:** Despite impressive progress made in the development of advanced endoscopic techniques, combined HD-WLE/OC followed by random biopsies remains the golden standard for BE surveillance. Surveillance depends on appropriate mucosal cleansing, sufficient inspection time, and competence of the performing gastroenterologist to improve detection of EAC. In addition, to facilitate the clinical implementation of advanced endoscopic techniques, multicenter prospective clinical studies are demanded for OC and FME. Meanwhile, further optimization of CAD algorithms, the education of gastroenterologists, and analysis of the interaction between the clinician and the computer should be performed.

© 2022 The Author(s).
Published by S. Karger AG, Basel

Introduction

Esophageal cancer is the sixth leading cause of cancer-related mortality worldwide while rising in terms of incidence [1]. Esophageal adenocarcinoma (EAC) follows a devastating prognosis with an estimated 5-year survival between 15 and 20% [2]. Barrett's esophagus (BE) predisposes EAC. Screening and surveillance endoscopy is the

Lisanne E. van Heijst and Xiaojuan Zhao: shared co-first authorship.
Ruben Y. Gabriëls and Wouter B. Nagengast: shared last authorship.

golden standard to detect dysplastic BE (DBE) and early stage EAC to improve patient outcomes [3]. This is momentarily achieved with high-definition white-light endoscopy (HD-WLE) and collecting biopsies according to the Seattle protocol. This protocol is costly and time-consuming while risking a potential high miss rate of 9–35% [4, 5]. Meanwhile, poor adherence to surveillance guidelines is observed in clinical practice resulting in variable sensitivity and specificity of the current standards [6]. Optical chromoendoscopy (OC) has been implemented in many medical centers; however, inconsistent results compared to HD-WLE are reported for detection of DBE and EAC [4, 7, 8]. Therefore, there remains a great need for novel reliable imaging techniques to improve surveillance protocols and thereby improving detection rates of DBE and early stage EAC. In this review, several promising novel techniques are discussed and evaluated.

Chromoendoscopy

Chromoendoscopy includes dye-based chromoendoscopy and OC. After being sprayed onto the surface mucosa, the dye methylene blue, acetic acid, or indigo carmine enhances visualization of esophagus mucosal patterns to improve distinction of dysplasia and cancer [9, 10]. Dye-based chromoendoscopy has been available since the late 1980s; however, large and recent validation studies on BE surveillance remain nonexistent [10]. A

meta-analysis on methylene blue-based chromoendoscopy reported no significant improvement in the diagnostic yield of DBE compared to HD-WLE and random biopsies [11]. Limitations such as additional costs and procedure time as well as poor surface coating are reported consistently [11, 12]. Different from dye-based chromoendoscopy, OC often focuses mainly on lesion characterization more than improving detection of lesions. However, a meta-analysis showed 34% increase of detecting DBE and EAC compared to HD-WLE and random biopsies, consequently decreasing the risk of missing dysplasia which signifies its role in BE surveillance [13].

OC includes narrow-band imaging (NBI), flexible spectral imaging color enhancement (FICE), I-SCAN, blue-light imaging (BLI) (Fujifilm, Tokyo, Japan), and linked color imaging (LCI). All major manufacturers incorporate OC within the standard endoscope, explaining its widespread use [14]. NBI (Olympus, Tokyo, Japan) uses an optical filter to highlight microvascular structures of the esophageal mucosa. This technique is associated with an improved sensitivity of 80% and specificity of 88% in predicting the absence or presence of dysplasia and EAC after the new NBI classification system was introduced [15]. Unlike NBI, FICE (Fujifilm) and I-SCAN (Pentax, Tokyo, Japan) enhance mucosal and microvascular patterns by modifying the spectrum of collected white-light images. In a prospective pilot study, a sensitivity of 92% for detection of DBE by FICE was reported compared to the dysplastic lesions found by acetic acid

Table 1. Overview of the different OC systems, their geographic distribution, and manufactures [14]

Technique	Company	Name	Geographic distribution
NBI	Olympus	LUCERA SPECTRUM/LUCERA ELITE EXERA II/EXERA III	Japan, the UK Rest of the world
FICE (also Fujinon intelligent chromoendoscopy)	Fujifilm	EXP-4400 system	Worldwide
i-scan digital contrast (I-SCAN)	PENTAX	EPK-i	Worldwide
BLI	Fujifilm	LASEREO	Japan, China, South America, Asian-Pacific, Europe
TXI	Olympus	EVIS X1	Worldwide

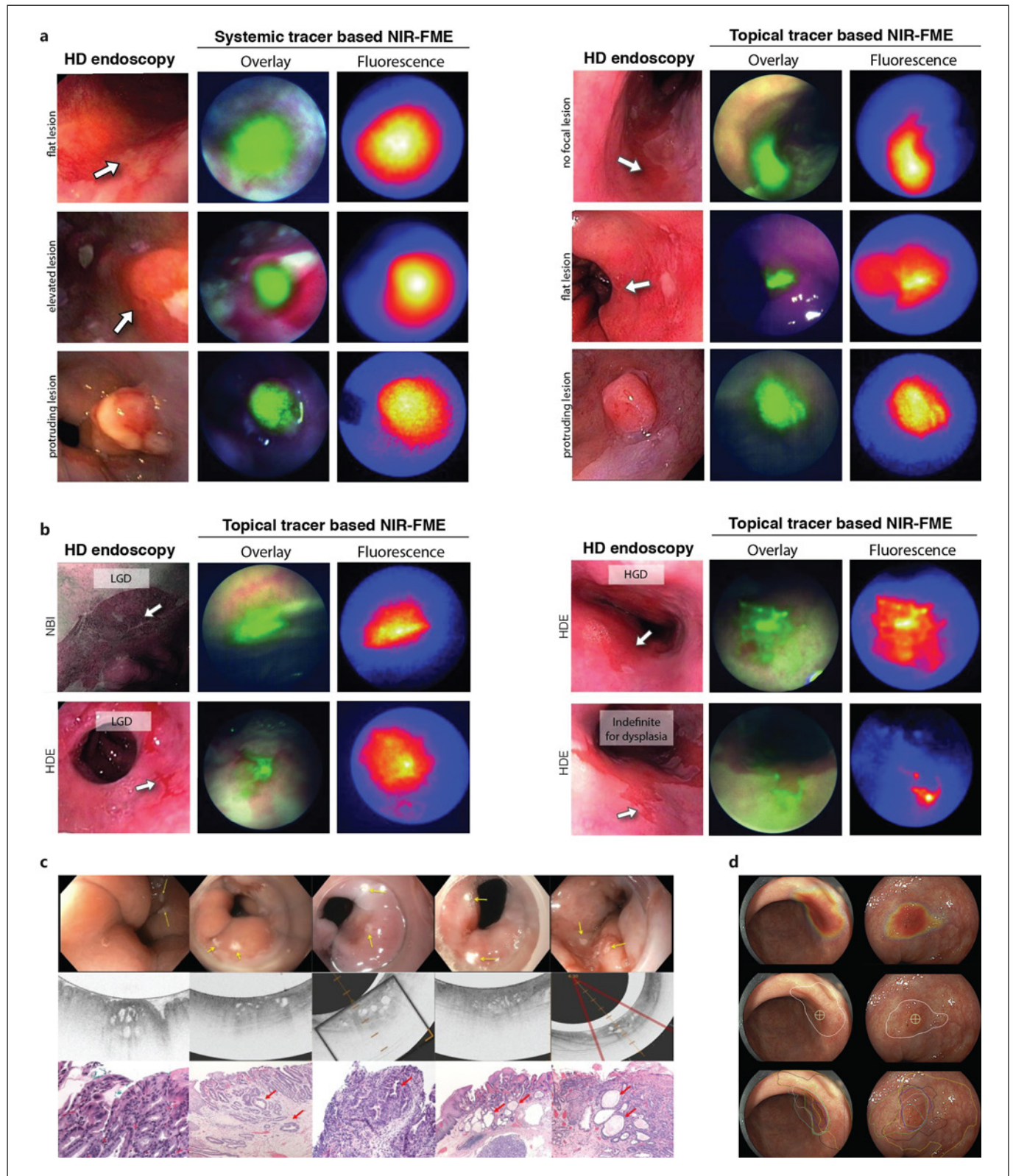
Fig. 1. a Examples of the systemic tracer based and the topical tracer results, summarizing that all lesions could be visualized with real-time VEGFA-targeted NIR-FME, including one EAC area which was not visible during HD inspection (displayed in the first row, right panel); reprinted with permission from Nagengast et al. [22]. **b** Additionally identified dysplastic areas during real-time VEGFA-targeted NIR-FME, which were missed during HD-NBI inspection. All fluorescence signals presented here are uncorrected; overlay images display the high intensities only; reprinted with permission from Nagengast et al. [22]. **c** Five examples of complex glands seen on VLE with the corresponding laser marks and histology. The top row is the endoscopic images with laser marks (yellow arrows). The middle row is the VLE images that correspond to the above endoscopy image. The bottom row is the H&E-stained his-

tology images that correlate to the VLE images above them. Red arrows refer to complex glands. Columns 1, 2, 4, and 5 are from the endoscopic mucosal resection images. Column 3 is from a biopsy; reprinted with permission from Trindade et al. [23]. **d** Example of 2 neoplastic lesions with the heatmap visualization by the CAD system (the top row) and its corresponding delineation and biopsy site indicator (the middle row). Ground truth is established by expert delineations (the bottom row); reprinted with permission from de Groof et al. [24]. CAD, computer-aided detection; EAC, esophageal adenocarcinoma; HD, high-definition; HGD, high-grade dysplasia; LGD, low-grade dysplasia; NIR-FME, near-infrared fluorescence molecular endoscopy; NBI, narrow-band imaging; VEGFA, vascular endothelial growth factor A; VLE, volumetric laser endomicroscopy.

(For figure see next page.)

chromoendoscopy and FICE together [10]. A recent retrospective study applied the updated I-SCAN system, namely iSCAN optical enhancement system. This showed an improved sensitivity and specificity of 78% and 81% for I-SCAN compared to 69% and 70% for HD-WLE con-

cerning the detection of dysplasia [16]. Prospective clinical results with regard to the surveillance of BE lesions with either FICE or I-SCAN remain rather limited. The latest BLI platform integrated LCI, enabling both narrow-spectrum illumination and computational image modifi-



cation. Although improved visualization on DBE was shown with this platform, results on diagnostic sensitivity and specificity are still lacking [17]. An overview of the different systems and manufactures is given in Table 1.

Endomicroscopy

Confocal laser endomicroscopy (CLE) provides endoscopists with real-time *in vivo* visualization of superficial mucosal layers at high magnification which results in a real-time microscopy image. Endoscope-based CLE (Pentax) provides a wider field of view, higher resolution images, and better performance compared to probe-based CLE (pCLE; Mauna Kea Technologies, Paris, France). However, endoscope-based CLE is not commercially available anymore. Targeted biopsies guided by pCLE showed a pooled sensitivity of 90% and specificity of 77% [18]. The reported sensitivity and specificity of real-time pCLE optical biopsy was 67% and 98%, respectively [19]. Therefore, in accordance with the Preservation and Incorporation of Valuable Endoscopic Innovations [20], neither pCLE real-time optical biopsy nor targeted biopsy could replace random biopsies following the Seattle protocol at this moment. However, pCLE can add value, like OC, in providing histological information of suspected lesions detected by HD-WLE to assist in differentiating between DBE and non-DBE (NDBE) [21].

Volumetric Laser Endomicroscopy

Unlike the narrow-field magnified imaging of pCLE, volumetric laser endomicroscopy (VLE) provides wide-field magnified imaging at high speed. VLE incorporates optical frequency domain imaging technology and provides *in vivo* cross-sectional structural information at real-time, shown in Figure 1. After inserting the balloon-centered probe through the working channel, the inflated balloon circumferentially scans 6 cm of the esophagus in 90 s, to a depth of around 3 mm [25]. Histologically correlated VLE results showed a sensitivity of 83–86% and a specificity of 71–88% [26, 27]. Larger clinical trials are warranted to validate these preliminary results. However, the company NinePoint Medical filed for bankruptcy in 2020, consequently making VLE currently unavailable.

Fluorescence Molecular Endoscopy

Molecular imaging could potentially improve the sensitivity and specificity compared to HD-WLE by targeting disease-specific molecules to highlight neoplastic changes at the molecular level even before macroscopic

morphological changes occur, hereby providing additional information compared to HD-WLE [28]. Initially, *ex vivo* fluorescence imaging using lectins in the visible spectrum was performed which identified lower fluorescence signals in DBE due to reduced cell-surface glycans [29]. One of the first *in vivo* studies evaluating fluorescence molecular endoscopy (FME) in BE was with topical administration of ASY – fluorescein isothiocyanate – which operated in the visible spectrum (400–700 nm). With this, a sensitivity of 76% and a specificity of 94% in detecting high-grade dysplasia and EAC were reported [30].

Compared to the visible spectrum, the near-infrared (NIR) spectrum (700–1,700 nm) shows deeper tissue penetration and lower background noise signals due to less tissue absorption, autofluorescence and scattering [31]. NIR-FME could highlight specific targets at real-time *in vivo* and minimizes noise signal. A phase I trial with NIR-FME targeting vascular endothelial growth factor A (VEGFA) showed a promising 33% improved detection of early EAC through topical application of bevacizumab-800CW when compared to HD-WLE and NBI [22]. Different lesion types in this study visualized with FME in combination with the tracer bevacizumab are shown in Figure 1. The phase-II trial is ongoing (NCT03877601) to assess sensitivity and specificity of NIR-FME targeting VEGFA for detection of early EAC within 60 patients.

One of the advantages of fluorescence imaging is that multiple fluorophores exciting light at different wavelengths could be potentially used, and thus, multiple targets of dysplasia can be highlighted. A multispectral FME system that enables concurrent targeting of multiple molecules was recently developed and seems promising for molecular imaging to improve the sensitivity and specificity [32]. A phase I trial confirmed the feasibility of multispectral imaging to detect early EAC by targeting two different molecules [32]. However, the tissue optical properties, scattering and absorption, were not corrected for within this trial. Integrating fluorescence imaging into standard endoscopes as well as further validation with larger sample sizes are examples of technical improvements that are needed to translate multispectral FME into clinical practice.

Computer-Aided Detection

Advanced endoscopic techniques generate a myriad of detailed images that are overwhelming to endoscopists for real-time interpretation. Computer-aided detection (CAD) enables automatic characterization and classification of millions of endoscopic images which are impossible for the human brain to process. CAD could also cap-

ture subtle or invisible variation which might be missed by the human eyes.

A newly developed CAD system of deep residual learning performs better at EAC detection than general endoscopists do with HD-WLE images, resulting in a sensitivity of 93% versus 72% and a specificity of 83% versus 74%. This CAD system also delineates EAC comparable to BE experts [24]. Another CAD algorithm showed improvement to a sensitivity of 96% and a specificity of 94%, with the potential for real-time diagnosis. The system localizes EAC with annotated boxes, thereby not providing information about the delineation of lesions but is sufficient for lesion detection [33]. The first real-time CAD system to differentiate EAC from NDBE was built in 2020. The cancerous probability is shown as the spatial distribution of color density overlapped on HD-WLE images. However, the image sets of BE and EAC which are applied to fine-tune the algorithm are still rather small. The promising 83% sensitivity and 100% specificity are based on validation within a small cohort with elevated BE lesions [34]. CAD assessment of HD-WLE images compared to expert assessment is shown in Figure 1.

Discussion

OC outclasses dye-based chromoendoscopy as it avoids uneven distribution of dyes and is less dependent on operator experience [11]. Dye-based chromoendoscopy uses nontargeted dyes and merely visualizes the mucosal pattern of the esophagus. In contrast, OC visualizes the mucosal patterns and enables detailed microvascular characterization when adjusted to the magnified mode [14]. NBI and BLI differ from computational post-processing of white-light images in I-SCAN and FICE. The spectrum of I-SCAN and FICE images are flexible, in contrast with the fixed spectrum of NBI and BLI images [14]. NBI is the most frequently studied OC method. However, generalized analysis of NBI-based studies on BE is hampered by the variations of classification criteria [35]. Another limitation is that the majority of studies on OC are based on retrospectively collected data with mostly still images [15, 16]. Nevertheless, a large meta-analysis showed improved detection of OC compared to HD-WLE [13]. In addition, consistent results indicate that OC can assist in characterization of BE lesions [18].

Recently, texture and color enhancement imaging (TXI) was embedded into HD-WLE. TXI aims to increase brightness in dark areas, improve color contrast, and enhance subtle tissue morphology differences [36]. Despite lack of TXI research in BE surveillance, superior visibility compared to HD-WLE was shown in serrated colorectal polyps [37]. TXI combined with dye-based chromoendoscopy or OC might be able to improve detailed visualization and BE lesion detection [38].

In contrast to chromoendoscopy and endomicroscopy techniques, which are limited to morphology changes in lesions, FME could target underlying biological processes of dysplasia or specific tumor subtypes and serve as a wide-field “red-flag” technique for endoscopists. To transform FME systems widely into clinical practice, the major hurdles are integration of fluorescence imaging in standard endoscopes, correction of noise signals at the video rate, interpretation of signals by for instance artificial intelligence, and real-time semi-quantification of fluorescence intensities to prevent operator-dependent interpretation [39].

Regardless of imaging techniques used, it has been shown that BE expert centers achieve a significantly higher detection rate of DBE and EAC compared to community hospitals, 87% versus 60%, respectively [40]. As the performance of CAD could reach the level of BE experts in image interpretation, the implementation of CAD in community hospitals could bridge the gap with BE expert centers [24]. HD-WLE images and NBI images were assessed with the same CAD algorithm. It was found that the NBI-based CAD system outperformed the HD-WLE-based CAD system regarding binary classification between DBE and NDBE, showing sensitivity and specificity per image of 92% versus 99% and 99% versus 89%, respectively [33]. The algorithm trained on HD-WLE images with improved image sharpness displayed better performance in DBE and NDBE classification, with a specificity of 98% versus 90% [33]. Therefore, besides optimization of artificial intelligence algorithms, development of endoscopes that show better image quality with improved visualization of cancerous tissue seems promising. Current CAD systems of BE feasible for real-time application still need to be validated in prospective multicenter large cohort studies and evaluated by different manufacturers for implementation. To facilitate clinical implementation of CAD, education of clinicians on artificial intelligence and further research on interaction between clinicians and CAD systems are of vital importance [41].

Despite many advances that have been made in current endoscopic imaging and upcoming promising techniques, several parameters always need to be considered to reach optimal surveillance of BE. The clear visibility of esophageal mucosa is often impaired by bubbles and mucus on the surface of the esophagus. Pre-endoscopy cleansing with defoaming and mucolytic solution improved the mucosal visibility necessary for optimal assessment of the mucosa [42]. In addition, longer endoscopic inspection time was associated with higher detection rates of DBE. Inspecting over 1 min/cm of BE segment was suggested to improve the surveillance quality [43]. Frequent cardiac peristalsis increases the difficulty of endoscopic visualization. HD-WLE biopsies assisted by a

transparent cap improved the detection accuracy of BE by suctioning and stabilizing the mucosa compared to non-cap-assisted biopsies [44].

Conclusion

Implementation of novel imaging techniques is promising and might result in a multimodality strategy for BE surveillance. Currently, HD-WLE combined with OC and random biopsies is still the standard in BE surveillance. OC techniques are improving, such as I-SCAN and LCI, showing enhanced capability for detailed characterization of BE lesions. In addition, HD-WLE and OC might be combined in the future with FME to improve wide-field surveillance. These techniques assisted by artificial intelligence show potential to improve detection rates of DBE and to make the Seattle protocol redundant. However, until well-designed clinical trials show clear improvements in performance, BE surveillance outcomes depend on appropriate mucosal cleansing, sufficient inspection time, and subsequent random biopsies.

References

- 1 Sung H, Ferlay J, Siegel RL, Laversanne M, Soerjomataram I, Jemal A, et al. Global cancer statistics 2020: GLOBOCAN estimates of incidence and mortality worldwide for 36 cancers in 185 countries. *CA Cancer J Clin*. 2021 May;71(3):209–49.
- 2 Alsop BR, Sharma P. Esophageal cancer. *Gastroenterol Clin North Am*. 2016 Sep;45(3):399–412.
- 3 van Munster S, Nieuwenhuis E, Weusten BLAM, Alvarez Herrero L, Bogte A, Alkhalaf A, et al. Long-term outcomes after endoscopic treatment for Barrett's neoplasia with radiofrequency ablation ± endoscopic resection: results from the national Dutch database in a 10-year period. *Gut*. 2022. 71(2):265–76.
- 4 Sharma P, Hawes RH, Bansal A, Gupta N, Curvers W, Rastogi A, et al. Standard endoscopy with random biopsies versus narrow band imaging targeted biopsies in Barrett's oesophagus: a prospective, international, randomised controlled trial. *Gut*. 2013 Jan;62(1):15–21.
- 5 Dhaliwal L, Codipilly DC, Gandhi P, Johnson ML, Lansing R, Wang KK, et al. Neoplasia detection rate in Barrett's esophagus and its impact on missed dysplasia: results from a large population-based database. *Clin Gastroenterol Hepatol*. 2021 May;19(5):922–9.
- 6 Roumans CAM, Van Der Bogt RD, Steyerberg EW, Rizopoulos D, Lansdorp-Vogelaar I, Sharma P, et al. Adherence to recommendations of Barrett's esophagus surveillance guidelines: a systematic review and meta-analysis. *Endoscopy*. 2020 Jan;52(1):17–28.
- 7 Pascarenco OD, Coroş MF, Pascarenco G, Boeriu AM, Draşovean SC, Onişor DM, et al. A preliminary feasibility study: narrow-band imaging targeted versus standard white light endoscopy non-targeted biopsies in a surveillance Barrett's population. *Dig Liver Dis*. 2016 Sep;48(9):1048–53.
- 8 Kara MA, Peters FP, Rosmolen WD, Krishnadhath KK, ten Kate FJW, Fockens P, et al. High-resolution endoscopy plus chromoendoscopy or narrow-band imaging in Barrett's esophagus: a prospective randomized crossover study. *Endoscopy*. 2005 Oct;37(10):929–36.
- 9 Longcroft-Wheaton G, Duku M, Mead R, Poller D, Bhandari P. Acetic acid spray is an effective tool for the endoscopic detection of neoplasia in patients with Barrett's esophagus. *Clin Gastroenterol Hepatol*. 2010 Oct;8(10):843–7.
- 10 Pohl J, May A, Rabenstein T, Pech O, Nguyen-Tat M, Fissler-Eckhoff A, et al. Comparison of computed virtual chromoendoscopy and conventional chromoendoscopy with acetic acid for detection of neoplasia in Barrett's esophagus. *Endoscopy*. 2007 Jul;39(7):594–8.
- 11 Ngamruengphong S, Sharma VK, Das A. Diagnostic yield of methylene blue chromoendoscopy for detecting specialized intestinal metaplasia and dysplasia in Barrett's esophagus: a meta-analysis. *Gastrointest Endosc*. 2009 May;69(6):1021–8.
- 12 Hoffman A, Korczynski O, Tresch A, Hansen T, Rahman F, Goetz M, et al. Acetic acid compared with i-scan imaging for detecting Barrett's esophagus: a randomized, comparative trial. *Gastrointest Endosc*. 2014 Jan;79(1):46–54.
- 13 Qumseya BJ, Wang H, Badie N, Uzomba RN, Parasa S, White DL, et al. Advanced imaging technologies increase detection of dysplasia and neoplasia in patients with Barrett's esophagus: a meta-analysis and systematic review. *Clin Gastroenterol Hepatol*. 2013 Dec;11(12):1562–2.
- 14 East JE, Vleugels JL, Roelandt P, Bhandari P, Bisschops R, Dekker E, et al. Advanced endoscopic imaging: European Society of Gastrointestinal Endoscopy (ESGE) technology review. *Endoscopy*. 2016 Nov;48(11):1029–45.
- 15 Sharma P, Bergman JJ, Goda K, Kato M, Messmann H, Alsop BR, et al. Development and validation of a classification system to identify high-grade dysplasia and esophageal adenocarcinoma in Barrett's esophagus using narrow-band imaging. *Gastroenterology*. 2016 Mar;150(3):591–8.
- 16 Everson MA, Lovat LB, Graham DG, Bassett P, Magee C, Alzoubaidi D, et al. Virtual chromoendoscopy by using optical enhancement improves the detection of Barrett's esophagus-associated neoplasia. *Gastrointest Endosc*. 2019 Feb;89(2):247–56.e4.
- 17 de Groof AJ, Fockens KN, Struyvenberg MR, Pouw RE, Weusten BLAM, Schoon EJ, et al. Blue-light imaging and linked-color imaging improve visualization of Barrett's neoplasia by nonexpert endoscopists. *Gastrointest Endosc*. 2020 May;91(5):1050–7.
- 18 Thosani N, Abu Dayyeh BK, Sharma P, Aslanian HR, Enestvedt BK, Komanduri S, et al. ASGE Technology Committee systematic review and meta-analysis assessing the ASGE Preservation and Incorporation of Valuable Endoscopic Innovations thresholds for adopting real-time imaging-assisted endoscopic targeted biopsy during endoscopic surveillance of Barrett's esophagus. *Gastrointest Endosc*. 2016 Apr;83(4):684–98.e7.

Conflict of Interest Statement

The authors have no conflicts of interest to declare.

Funding Sources

The research position of the authors is supported by the Dutch Cancer Society, Amsterdam, the Netherlands, TRANSCAN-2 (project TRANSCAN-147, ESCEND).

Author Contributions

Shared co-first authors X.Z. and L.E.H. performed the selection of the papers by reading titles, abstracts, and full-text articles, and they both contributed to the writing. L.E.H. oversaw the overall formatting of the manuscript. R.Y.G. was supervising during data selection and analysis and reviewed drafts of the paper by suggesting contextual changes. R.Y.G. and W.B.N. supervised the process and revised the manuscript. All the authors contributed to manuscript revision and read and approved the final version of the manuscript to be submitted for publication.

- 19 Shah T, Lippman R, Kohli D, Mutha P, Solomon S, Zfass A. Accuracy of probe-based confocal laser endomicroscopy (pCLE) compared to random biopsies during endoscopic surveillance of Barrett's esophagus. *Endosc Int Open*. 2018 Apr;6(4):E414–20.
- 20 Sharma P, Savides TJ, Canto MI, Corley DA, Falk GW, Goldblum JR, et al. The American Society for Gastrointestinal Endoscopy PIVI (Preservation and Incorporation of Valuable Endoscopic Innovations) on imaging in Barrett's esophagus. *Gastrointest Endosc*. 2012 Aug;76(2):252–4.
- 21 Richardson C, Colavita P, Dunst C, Bagnato J, Billing P, Birkenhagen K, et al. Real-time diagnosis of Barrett's esophagus: a prospective, multicenter study comparing confocal laser endomicroscopy with conventional histology for the identification of intestinal metaplasia in new users. *Surg Endosc*. 2019 May;33(5):1585–91.
- 22 Nagengast WB, Hartmans E, Garcia-Allende PB, Peters FTM, Linssen MD, Koch M, et al. Near-infrared fluorescence molecular endoscopy detects dysplastic oesophageal lesions using topical and systemic tracer of vascular endothelial growth factor A. *Gut*. 2019 Jan; 68(1):7–10.
- 23 Trindade AJ, Raphael KL, Inamdar S, Stewart M, Berkowitz J, Vegesna A, et al. Volumetric laser endomicroscopy features of dysplasia at the gastric cardia in Barrett's oesophagus: results from an observational cohort study. *BMJ Open Gastroenterol*. 2019 Oct 23;6(1):e000340.
- 24 de Groof AJ, Struyvenberg MR, van der Putten J, van der Sommen F, Fockens KN, Curvers WL, et al. Deep-learning system detects neoplasia in patients with Barrett's esophagus with higher accuracy than endoscopists in a multistep training and validation study with benchmarking. *Gastroenterology*. 2020 Mar; 158(4):915–29.e4.
- 25 Vakoc BJ, Shishko M, Yun SH, Oh WY, Suter MJ, Desjardins AE, et al. Comprehensive esophageal microscopy by using optical frequency-domain imaging (with video). *Gastrointest Endosc*. 2007 May;65(6):898–905.
- 26 Swager AF, Tearney GJ, Leggett CL, van Oijen MGH, Meijer SL, Weusten BL, et al. Identification of volumetric laser endomicroscopy features predictive for early neoplasia in Barrett's esophagus using high-quality histological correlation. *Gastrointest Endosc*. 2017 May;85(5):918–26.e7.
- 27 Leggett CL, Gorospe EC, Chan DK, Muppa P, Owens V, Smyrk TC, et al. Comparative diagnostic performance of volumetric laser endomicroscopy and confocal laser endomicroscopy in the detection of dysplasia associated with Barrett's esophagus. *Gastrointest Endosc*. 2016 May;83(5):880–8.e2.
- 28 Curvers WL, Van Vilsteren FG, Baak LC, Böhmer C, Mallant-Hent RC, Naber AH, et al. Endoscopic trimodal imaging versus standard video endoscopy for detection of early Barrett's neoplasia: a multicenter, randomized, crossover study in general practice. *Gastrointest Endosc*. 2011 Feb;73(2): 195–203.
- 29 Bird-Lieberman EL, Neves AA, Lao-Sirieix P, O'Donovan M, Novelli M, Lovat LB, et al. Molecular imaging using fluorescent lectins permits rapid endoscopic identification of dysplasia in Barrett's esophagus. *Nat Med*. 2012 Jan;18(2):315–21.
- 30 Joshi BP, Duan X, Kwon RS, Piraka C, Elmunzer BJ, Lu S, et al. Multimodal endoscopy can quantify wide-field fluorescence detection of Barrett's neoplasia. *Endoscopy*. 2016 Feb; 48(2):A1–13.
- 31 James ML, Gambhir SS. A molecular imaging primer: modalities, imaging agents, and applications. *Physiol Rev*. 2012 Apr;92(2):897–965.
- 32 Chen J, Jiang Y, Chang TS, Joshi B, Zhou J, Rubenstein JH, et al. Multiplexed endoscopic imaging of Barrett's neoplasia using targeted fluorescent heptapeptides in a phase 1 proof-of-concept study. *Gut*. 2021 Jun;70(6):1010–3.
- 33 Hashimoto R, Requa J, Dao T, Ninh A, Tran E, Mai D, et al. Artificial intelligence using convolutional neural networks for real-time detection of early esophageal neoplasia in Barrett's esophagus (with video). *Gastrointest Endosc*. 2020 Jun;91(6):1264–71.e1.
- 34 Ebigbo A, Mendel R, Probst A, Manzeneder J, Prinz F, de Souza LA Jr, et al. Real-time use of artificial intelligence in the evaluation of cancer in Barrett's oesophagus. *Gut*. 2020 Apr; 69(4):615–6.
- 35 Chiam KH, Shin SH, Choi KC, Leiria F, Militz M, Singh R. Current status of mucosal imaging with narrow-band imaging in the esophagus. *Gut Liver*. 2021 Jul 15;15(4):492–9.
- 36 Sato T. TXI: texture and color enhancement imaging for endoscopic image enhancement. *J Healthc Eng*. 2021;2021(9):1–11.
- 37 Nishizawa T, Toyoshima O, Yoshida S, Uekura C, Kurokawa K, Munkhjargal M, et al. TXI (texture and color enhancement imaging) for serrated colorectal lesions. *J Clin Med*. 2021 Dec 27;11(1):119.
- 38 Waki K, Kanetsaka T, Michida T, Ishihara R, Tanaka Y. Improved visibility of early gastric cancer using a combination of chromoendoscopy and texture and color enhancement imaging. *Gastrointest Endosc*. 2022;95(4):800. <http://dx.doi.org/10.1016/j.gie.2021.12.016>.
- 39 van der Sommen F, Curvers WL, Nagengast WB. Novel developments in endoscopic mucosal imaging. *Gastroenterology*. 2018 May; 154(7):1876–86.
- 40 Schölvinck DW, van der Meulen K, Bergman JJGHM, Weusten BLAM. Detection of lesions in dysplastic Barrett's esophagus by community and expert endoscopists. *Endoscopy*. 2017 Feb;49(2):113–20.
- 41 Keane PA, Topol EJ. AI-facilitated health care requires education of clinicians. *Lancet*. 2021 Apr 3;397(10281):1254.
- 42 Basford PJ, Brown J, Gadeke L, Fogg C, Hayson-Newport B, Ogollah R, et al. A randomized controlled trial of pre-procedure simethicone and N-acetylcysteine to improve mucosal visibility during gastroscopy: NICEVIS. *Endosc Int Open*. 2016 Nov;4(11):E1197–202.
- 43 Gupta N, Gaddam S, Wani SB, Bansal A, Rastogi A, Sharma P. Longer inspection time is associated with increased detection of high-grade dysplasia and esophageal adenocarcinoma in Barrett's esophagus. *Gastrointest Endosc*. 2012 Sep;76(3):531–8.
- 44 Chen BL, Xing XB, Wang JH, Feng T, Xiong LS, Wang JP, et al. Improved biopsy accuracy in Barrett's esophagus with a transparent cap. *World J Gastroenterol*. 2014 Apr;20(16): 4718–22.