

University of Groningen

Pulsed field (endocardial) ablation as part of convergent hybrid ablation for the treatment of long-standing persistent atrial fibrillation

Magni, Federico T; Mulder, Bart A; Rienstra, Michiel; Klinkenberg, Theo J; Mariani, Massimo A; Blaauw, Yuri

Published in:
Journal of interventional cardiac electrophysiology

DOI:
[10.1007/s10840-022-01183-3](https://doi.org/10.1007/s10840-022-01183-3)

IMPORTANT NOTE: You are advised to consult the publisher's version (publisher's PDF) if you wish to cite from it. Please check the document version below.

Document Version
Publisher's PDF, also known as Version of record

Publication date:
2022

[Link to publication in University of Groningen/UMCG research database](#)

Citation for published version (APA):

Magni, F. T., Mulder, B. A., Rienstra, M., Klinkenberg, T. J., Mariani, M. A., & Blaauw, Y. (2022). Pulsed field (endocardial) ablation as part of convergent hybrid ablation for the treatment of long-standing persistent atrial fibrillation. *Journal of interventional cardiac electrophysiology*, 64(2), 271-272. <https://doi.org/10.1007/s10840-022-01183-3>

Copyright

Other than for strictly personal use, it is not permitted to download or to forward/distribute the text or part of it without the consent of the author(s) and/or copyright holder(s), unless the work is under an open content license (like Creative Commons).

The publication may also be distributed here under the terms of Article 25fa of the Dutch Copyright Act, indicated by the "Taverne" license. More information can be found on the University of Groningen website: <https://www.rug.nl/library/open-access/self-archiving-pure/taverne-amendment>.

Take-down policy

If you believe that this document breaches copyright please contact us providing details, and we will remove access to the work immediately and investigate your claim.

Downloaded from the University of Groningen/UMCG research database (Pure): <http://www.rug.nl/research/portal>. For technical reasons the number of authors shown on this cover page is limited to 10 maximum.



Pulsed field (endocardial) ablation as part of convergent hybrid ablation for the treatment of long-standing persistent atrial fibrillation

Federico T. Magni^{1,2} · Bart A. Mulder¹ · Michiel Rienstra¹ · Theo J. Klinkenberg² · Massimo A. Mariani² · Yuri Blaauw¹

Received: 1 March 2022 / Accepted: 10 March 2022
© The Author(s) 2022

A 69-year-old male patient with a pacemaker, previous hypertension, myocardial infarction, and long-standing persistent atrial fibrillation (AF) was referred for staged convergent hybrid ablation AF ablation. During this procedure, epicardial surgical ablation of the left atrial (LA) posterior wall (PW) is performed followed by endocardial catheter ablation of the pulmonary veins (PV) and remaining PW gaps [1]. We present a case of staged convergent hybrid ablation where pulsed field ablation (PFA) was used for the endocardial procedure.

Nine weeks after the epicardial procedure, 3D-electro-anatomic mapping of the LA (ENSITE Precision) showed a large PW lesion (Fig. 1 *Panel A*). Additional PV isolation was performed with a 35-mm PFA catheter (FARA-PULSE, Fig. 1 *Panel B*) with four applications in the flower

and four in the basket shape for each PV. The posterior box was extended superiorly to the PW area inaccessible during surgical ablation due to pericardial reflections, with the PFA catheter in the flower position (positions are shown in *Panel B*). Remapping confirmed PV isolation and posterior box extension. No esophageal temperature probe was used. Total procedure time was 76 min.

We present the first case of convergent hybrid convergent AF ablation where PFA technology was used for endocardial ablation. PFA is a novel ablation modality with high acute efficacy, fast ablation times, and tissue selectivity, which is especially important when ablating the PW thus sparing the esophagus [2]. Here, PFA seems to offer a good alternative to radiofrequency technology.

✉ Federico T. Magni
f.t.magni@umcg.nl

¹ Department of Cardiology, University of Groningen, University Medical Center Groningen, Groningen, Netherlands

² Department of Cardio-Thoracic Surgery, University of Groningen, University Medical Center Groningen, Groningen, Netherlands

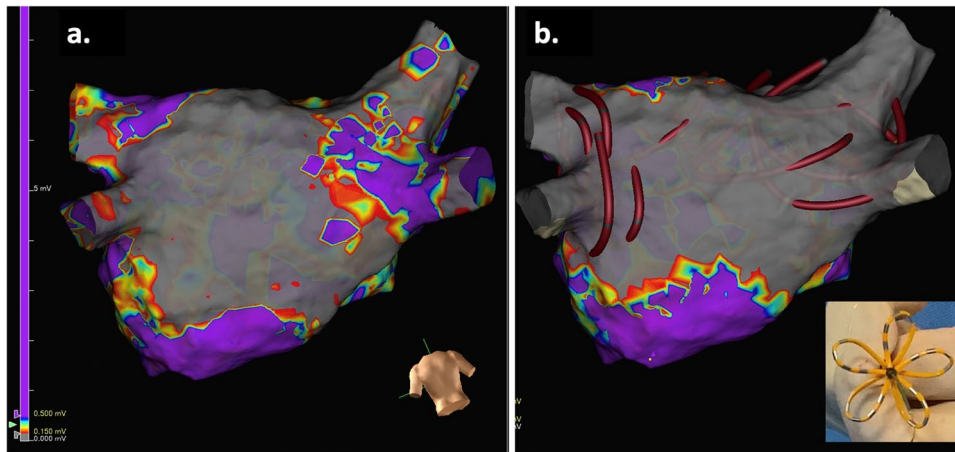


Fig. 1 **a** Three-dimensional electroanatomic voltage map of the LA (posterior-anterior view, 0.15–0.50 mV) before PFA endocardial ablation. Low-voltage areas (highlighted in gray) represent an extensive “posterior box” lesion made during epicardial surgical ablation. This is displaced towards the inferior aspect of the posterior wall between the two inferior pulmonary veins. **b** Three-dimensional electroanatomic voltage map of the LA (posterior-anterior view) after

PFA endocardial ablation. Low-voltage areas (highlighted in gray) highlight the additional pulmonary vein isolation performed and the extension of the existing posterior box to the superior aspect of the LA posterior wall. The catheter is represented in the 3D map as a circular catheter and the positions during PFA are shown. PFA applications to the LA posterior wall were delivered with the PFA catheter in the flower shape, as depicted in the right lower panel

Open Access This article is licensed under a Creative Commons Attribution 4.0 International License, which permits use, sharing, adaptation, distribution and reproduction in any medium or format, as long as you give appropriate credit to the original author(s) and the source, provide a link to the Creative Commons licence, and indicate if changes were made. The images or other third party material in this article are included in the article's Creative Commons licence, unless indicated otherwise in a credit line to the material. If material is not included in the article's Creative Commons licence and your intended use is not permitted by statutory regulation or exceeds the permitted use, you will need to obtain permission directly from the copyright holder. To view a copy of this licence, visit <http://creativecommons.org/licenses/by/4.0/>.

persistent and long-standing persistent atrial fibrillation: results of CONVERGE clinical trial. *Circ Arrhythmia Electrophysiol.* 2020;13(12): e009288. <https://doi.org/10.1161/CIRCEP.120.009288>.

- Reddy VY, Anic A, Koruth J, Petru J, Funasako M, Minami K, et al. Pulsed field ablation in patients with persistent atrial fibrillation. *J Am Coll Cardiol.* 2020;76(9):1068–80. <https://doi.org/10.1016/j.jacc.2020.07.007>.

Publisher's note Springer Nature remains neutral with regard to jurisdictional claims in published maps and institutional affiliations.

References

- DeLurgio DB, Crossen KJ, Gill J, Blauth C, Oza SR, Magnano AR, et al. Hybrid convergent procedure for the treatment of