

University of Groningen

Need and value of targeted immunosuppressive therapy in giant cell arteritis

Sandovici, Maria; van der Geest, Niels; van Sleen, Yannick; Brouwer, Elisabeth

Published in:
BMJ Open

DOI:
[10.1136/rmdopen-2021-001652](https://doi.org/10.1136/rmdopen-2021-001652)

IMPORTANT NOTE: You are advised to consult the publisher's version (publisher's PDF) if you wish to cite from it. Please check the document version below.

Document Version
Publisher's PDF, also known as Version of record

Publication date:
2022

[Link to publication in University of Groningen/UMCG research database](#)

Citation for published version (APA):

Sandovici, M., van der Geest, N., van Sleen, Y., & Brouwer, E. (2022). Need and value of targeted immunosuppressive therapy in giant cell arteritis. *BMJ Open*, 8(1), [e001652].
<https://doi.org/10.1136/rmdopen-2021-001652>

Copyright

Other than for strictly personal use, it is not permitted to download or to forward/distribute the text or part of it without the consent of the author(s) and/or copyright holder(s), unless the work is under an open content license (like Creative Commons).

The publication may also be distributed here under the terms of Article 25fa of the Dutch Copyright Act, indicated by the "Taverne" license. More information can be found on the University of Groningen website: <https://www.rug.nl/library/open-access/self-archiving-pure/taverne-amendment>.





Take-down policy

If you believe that this document breaches copyright please contact us providing details, and we will remove access to the work immediately and investigate your claim.

Downloaded from the University of Groningen/UMCG research database (Pure): <http://www.rug.nl/research/portal>. For technical reasons the number of authors shown on this cover page is limited to 10 maximum.

REVIEW

Need and value of targeted immunosuppressive therapy in giant cell arteritis

Maria Sandovici , Niels van der Geest , Yannick van Sleen , Elisabeth Brouwer 

To cite: Sandovici M, van der Geest N, van Sleen Y, *et al.* Need and value of targeted immunosuppressive therapy in giant cell arteritis. *RMD Open* 2022;**8**:e001652. doi:10.1136/rmdopen-2021-001652

Received 18 November 2021
Accepted 17 January 2022

ABSTRACT

Despite the heterogeneity of the giant cell arteritis (GCA) at the level of clinical manifestations and the cellular and molecular players involved in its pathogenesis, GCA is still treated with standardised regimens largely based on glucocorticoids (GC). Long-term use of high dosages of GC as required in GCA are associated with many clinically relevant side effects. In the recent years, the interleukin-6 receptor blocker tocilizumab has become available as the only registered targeted immunosuppressive agent in GCA. However, immunological heterogeneity may require different pathways to be targeted in order to achieve a clinical, immunological and vascular remission in GCA. The advances in the targeted blockade of various molecular pathways involved in other inflammatory and autoimmune diseases have catalyzed the research on targeted therapy in GCA. This article gives an overview of the studies with targeted immunosuppressive treatments in GCA, with a focus on their clinical value, including their effects at the level of vascular inflammation.

INTRODUCTION

Giant cell arteritis (GCA) is the most prevalent inflammatory disease of medium size and large arteries affecting almost exclusively people older than 50 years of age. GCA is regarded as a spectrum of diseases, from cranial (C)-GCA, to large vessels (LV)-GCA and combinations thereof, with or without features of polymyalgia rheumatica (PMR).¹ GCA can be a serious debilitating disease, with acute ischaemic complications such as sight loss and stroke due to vascular inflammation and stenosis, and dissection of aorta due to formation of an aneurysm.

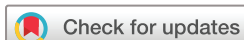Despite the huge impact of the disease on the quality of life of the patients with GCA, the therapeutic options available for GCA are yet very limited. Standardised treatment of GCA consists of high dose glucocorticoids (GC) to induce remission, followed by a long-term, gradual tapering regimen to maintain remission. Despite of chronic GC use with

Key messages

- ▶ The interleukin-6 receptor blocker tocilizumab is the only registered targeted immunosuppressive agent in giant cell arteritis (GCA), being effective in about the half of the treated patients.
- ▶ The targeted inhibition of various immunological pathways are currently being tested in GCA.
- ▶ Future studies with targeted immunosuppressive agents in GCA should include both evaluation of clinical and immunological parameters in addition to multiple vascular imaging modalities.

their well-known side effects² vascular inflammation is not always adequately controlled³ and up to 75% of GCA patients experience relapses.⁴ Powerful GC-sparing medication and a better control of the disease activity and secondary damage with disease modifying drugs remain thus important unmet needs in GCA.

Several attempts have been made to achieve a GC-sparing effect using conventional synthetic immunosuppressive agents. The pooled analysis of individual patient data⁵ of three randomised controlled trials (RCTs) (a total of 161 patients) comparing addition of a low to moderate dose of methotrexate (7.5–15 mg/week) vs placebo, revealed a modest decreased risk of relapses in the patients receiving methotrexate, higher rates of GC-free remission and lower cumulative GC doses. In this meta-analysis, the number of patients needed to treat with methotrexate to prevent a first relapse is 3.6. Therefore, methotrexate may be used as an adjunctive therapy in GCA patients at high risk of GC toxicity or relapsing patients.⁶ There is until now insufficient evidence for efficacy of any other conventional synthetic immunosuppressive agent.⁶ The advances in the pathophysiological knowledge regarding GCA and the plethora of targeted drugs becoming



© Author(s) (or their employer(s)) 2022. Re-use permitted under CC BY-NC. No commercial re-use. See rights and permissions. Published by BMJ.

Department of Rheumatology and Clinical Immunology, University Medical Centre Groningen, Groningen, Netherlands

Correspondence to

Dr Maria Sandovici;
m.sandovici01@umcg.nl

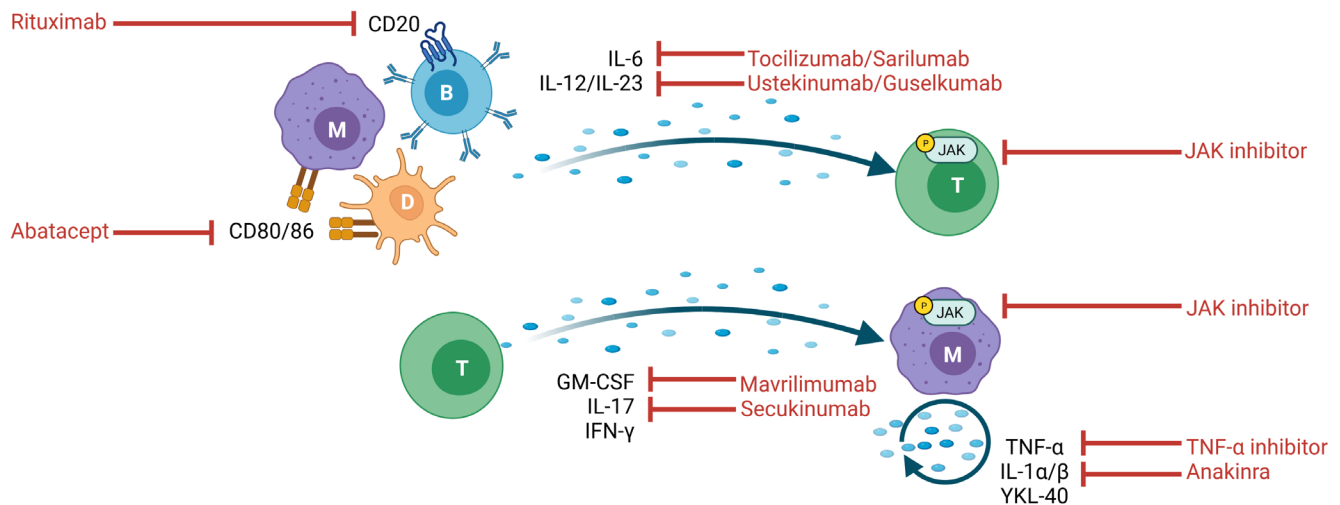


Figure 1 Schematic representation of the most important cellular players in the immunopathogenesis of giant cell arteritis (GCA) (D, dendritic cell, M, monocyte/macrophage, T, T cell, B, B cell), their cytokine/soluble products and the potential targets and tools of therapeutic intervention in GCA. Created with BioRender.com. CD, cluster of differentiation; IFN, interferon; IL, interleukin; JAK, Janus kinase; GM-CSF, granulocyte-macrophage colony-stimulating factor; TNF, tumour necrosis factor.

available for other autoimmune diseases, have catalysed the research on targeted therapy in GCA. This article gives an overview of the studies with targeted biological and synthetic immunosuppressive agents in GCA.

POTENTIAL CELLULAR AND MOLECULAR TARGETS OF IMMUNE INTERVENTION IN GCA

GCA is a granulomatous vasculitis that is postulated to start with the activation of the resident adventitial dendritic cells (DC).⁷ This results in a chemokine-mediated influx of T cells, monocytes and B cells in the vessel wall that perpetuate and amplify the local inflammatory cascade (figure 1). Through interaction with the resident vascular cells which trigger remodelling and neoangiogenesis, this uncontrolled immune process will eventually jeopardise the architecture of the vessel wall. DC stimulate T cells with their cognate peptides bound to MHC class II molecules, costimulatory molecules (ie, CD80/CD86) and cytokines. Among these cytokines, interleukin (IL)-12 promotes the CD4 +T helper 1 (Th1) cell response with production of interferon (IFN)- γ , whereas IL-1 β , IL-6 and IL-23 favour the expansion of CD4 +T helper 17 (Th17) cells which produce IL-17.^{8,9} The Janus kinase-signal transducer and activator of transcription (JAK-STAT) signalling plays an important role in multiple cytokine pathways, including the Th1 and Th17 response.¹⁰ Another key cellular player in GCA is the macrophage. Macrophages are activated by IFN- γ producing T cells and produce tumour necrosis factor (TNF)- α and IL-6.^{11,12} An important factor controlling the macrophage phenotype is granulocyte-macrophage colony-stimulating factor (GM-CSF). GM-CSF is actively produced in temporal artery (TA) biopsies of GCA patients.¹³ GM-CSF-skewed, CD206+MMP9+ macrophages

in the TA express high levels of YKL-40 which may stimulate tissue destruction and angiogenesis through IL-13-receptor α 2 signalling.¹⁴ Targeting GM-CSF or YKL-40 may thus inhibit macrophages that are currently insufficiently suppressed by GC. B cells are present in the adventitia and media of both TA and aorta GCA, where they can organise in tertiary lymphoid organs.^{15,16} B cells themselves can produce several pro-inflammatory cytokines such as IL-6, TNF- α and GM-CSF.¹⁷

Taken together, GCA is a heterogeneous disease, not only clinically but also at the level of pathogenic cellular and molecular pathways,¹⁸ possibly requiring different immunosuppressive agents in order to achieve a clinical, immunological and vascular remission.

TARGETED THERAPY IN GCA

Table 1 gives an overview of the prospective clinical trials with targeted immunosuppressive agents in GCA.

CYTOKINE-TARGETING

TNF- α inhibitors

In a phase 2 RCT including 44 new-onset GCA patients infliximab therapy did not increase the proportion of patients without relapse at week 22 compared with placebo.¹⁹ An RCT including 70 new-onset GCA patients treated with adalimumab or placebo also failed to achieve its primary end point of being in remission on less than 0.1 mg/kg of prednisone at week 26.²⁰ An RCT with etanercept in 17 new-onset and relapsing patients did show a GC-sparing effect,²¹ however, the primary outcome being GC-free remission at 12 months was not met.

IL-6 and IL-6 receptor inhibitors

Villiger *et al*²² reported the results of a single centre, phase 2, RCT with tocilizumab (an IL-6 receptor blocker) in

Table 1 Overview of the prospective studies with targeted immunosuppressive agents in giant cell arteritis (GCA)

Study author/sponsor	Target	Level of evidence	Targeted immunosuppressive agent	GC start dosage /taper	Classification criteria	Disease stage (total N)	Primary end point	Primary end point met (YES/NO)	Duration of follow-up
Villiger <i>et al</i> ²²	IL-6	RCT	Tocilizumab i.v. 8 mg/kg or placebo 1 x/4 wk until 52 wk	1 mg/kg/day+taperto 0.1 mg/kg/day by wk 12+taperto 0	ACR1990 and TAB + or MRA+	New-onset Relapsing (30)	Complete remission rate at a GC dose of 0.1 mg/kg/day at 12 wk	YES 85% vs 40% p=0.03 GC sparing	52 wk
Stone <i>et al</i> ²³	IL-6	RCT	Tocilizumab s.c. 162 mg four arms: 1 x/wk +26 wk GC 1 x/2wk +26 wk GC placebo +26 wk GC placebo +52 wk GC	20–60 mg/day + 26-or 52 wk taper	ACR1990, PMR and TAB + or PET+	New-onset Relapsing (251)	GC-free remission rate at 52 wk in each TCZ group vs placebo 26 wk GC	YES 56% and 53% vs 14% p<0.001 GC sparing	52 wk
Christ <i>et al</i> ²⁶	IL-6	Open-label	Tocilizumab i.v. 1 x 8 mg/kg followed by s.c. 162 mg 1 x/wk	500 mg methylprednisolone i.v. during 3 days	ACR1990, PMR and TAB + or PET+	New-onset (18)	Remission within 31 days	NO mean time to first remission: 11.1 wk	52 wk
Schmidt <i>et al</i> ³⁰	IL-6	RCT	Sirukumab three arms	20–60 mg/day+standard taper	High ESR/CRP and cranial or PMR clinic and TAB/imaging+	New-onset Relapsing (161)	Sustained remission rate at 52 wk	Unclear Only 17.4% reached 52 wk	52 wk early terminated
Conway <i>et al</i> ³⁸	IL-12/IL-23	Open-label	Ustekinumab s.c. 90 mg at wk 0, 4, then 1 x/12 wk	Median 20 mg/day+standard taper	ACR1990 or imaging+	Relapsing (25)	GC dose prior to ustekinumab vs GC dose at 52 wk	YES 20 vs 5 mg/day p<0.001	52 wk
Matza <i>et al</i> ³⁹	IL-12/IL-23	Open-label	Ustekinumab s.c. 90 mg at wk 0, 4, 12, 20, 28, 36, 44	20–60 mg/day + 24 wk taper	GCA or PMR-symptoms and TAB/imaging+	New-onset Relapsing (13)	GC-free remission rate at 52 wk	NO 23%	52 wk early terminated
Venhoff <i>et al</i> ³⁶	IL17(A)	RCT	Secukinumab s.c. 300 mg or placebo at wk 0, 1, 2, 3, 4, then 1 x/4 wk	26 wk taper	ACR1990 or imaging+	New-onset Relapsing (50)	Sustained remission rate at 28 wk	YES 70% vs 20%	52 wk
Langford <i>et al</i> ⁴²	T cell	RCT	Abatacept i.v. 10 mg/kg open-label, then at 12 wk randomised	28 wk taper	ACR1990	New-onset Relapsing (49)	Relapse-free survival rate at 12 mo	YES 48% vs 31% p=0.049	12 mo

Continued

Table 1 Continued

Study author/sponsor	Target	Level of evidence	Targeted immunosuppressive agent	GC start dosage /taper	Classification criteria	Disease stage (total N)	Primary end point	Primary end point met (YES/NO)	Duration of follow-up
Koster <i>et al</i> ⁴¹	JAK 1/2	Open-label	Baricitinib 4 mg/day	10–30 mg/day+standard taper	TAB + or imaging+	Relapsing (15)	Safety (frequency of AE and SAE)	YES	52 wk
Cid <i>et al</i> ⁴⁰	GM-CSF	RCT	Mavrilimumab s.c. 150 mg 1 x/2 wk or placebo	20–60 mg/day+26 wk taper	TAB + or imaging+	New-onset Relapsing (70)	The time to first adjudicated flare by week 26	YES NE vs 25.1 wk p=0.0263	26 wk
Hoffman <i>et al</i> ¹⁹	TNF- α	RCT	Infliximab i.v. 5 mg/kg or placebo at week 0, 2, 6 then 1 x/8 wk	40–60 mg/day+22 wk taper	ACR1990	New onset (44)	Relapse-free rate through 22 wk	NO 43% vs 50% p=0.65 No GC-sparing	22 wk early terminated
Seror <i>et al</i> ²⁰	TNF- α	RCT	Adalimumab s.c. 40 mg 1 x/2 wk or placebo during 10 wk	0.7 mg/kg/day+standard taper	ACR1990 partly TAB+	New onset (70)	Remission rate on less than 0.1 mg/kg GC at 26 wk	NO 59% vs 50% p=0.46 No GC-sparing	26 wk
Martinez <i>et al</i> ²¹	TNF- α	RCT	Etanercept s.c. 25 mg 2 x/wk or placebo	Median 15 mg/day+standard taper	TAB+	New onset Relapsing (17)	GC-free remission rate at 12 months	NO 50% vs 22% GC-sparing	12 mo

AE, adverse events; CRP, C reactive protein; ESR, erythrocyte sedimentation rate; GC, glucocorticoids; i.v., intravenously; mo, month; MRA, MR angiography; NE, not estimable; PET, positron emission tomography; PMR, polymyalgia rheumatica; RCT, randomised controlled trial; SAE, serious AEs; s.c., subcutaneous; TAB, temporal artery biopsy; TCZ, tocilizumab; TNF, tumour necrosis factor; wk, week.

GCA. Patients with new-onset (n=23) or relapsing (n=7) disease received either tocilizumab intravenously or placebo until week 52 in combination with a predefined GC regime. The primary outcome being the complete remission rate at a prednisolone dose of 0.1 mg/kg/day at week 12 was met (85% vs 40% in the tocilizumab and placebo group, respectively, $p=0.03$). The complete remission rate at week 52 also strongly favoured tocilizumab (85% vs 20%, $p=0.001$). The treating physicians were not blinded for C reactive protein (CRP)/erythrocyte sedimentation rate (ESR). There were no safety issues. This was the first RCT with tocilizumab in GCA pointing out the efficacy of this drug in combination with GC. In a follow-up study approximately half of the GCA patients (9/17) remained in lasting remission after discontinuation of tocilizumab. The rest of the GCA patients relapsed after a mean time of 6.4 (range 2–14) months during the total 44 months follow-up. In this small study none of the relapses was accompanied by new vascular complications.

This phase 2 study was followed by the Giant Cell Arteritis Actemra (GiACTA) trial in 2017²³: a multicentre, double-blind, placebo controlled, phase 3 trial with tocilizumab. In this study 251 patients with either new-onset (119) or relapsing GCA (132) were randomly assigned, in a 2:1:1:1 ratio, to one of the following arms: (1) subcutaneous (s.c.) tocilizumab (162 mg) 1x/week combined with 26-week GC taper; (2) tocilizumab s.c. 1x/2 week combined with 26 week GC taper; (3) placebo combined with a 26-week GC taper; (4) placebo combined with a 52-week GC taper. The primary outcome, being the rate of sustained GC-free remission at week 52 in arm 1 and 2 as compared with arm 3 was clearly achieved (56% and 53% in arm 1 and 2, respectively, vs only 14% in arm 3, $p<0.001$). The treating physicians were blinded for CRP/ESR. In a sensitivity analysis that excluded the requirement for a normalised CRP from the definition of sustained remission, the percentage of GC-free remission was 59% vs 20% in the first and third arm, respectively. The relapse rate was 23% and 26% in arm 1 and 2 as compared with 68% and 49% in arm 3 and 4, respectively. The number of GCA patients needed to treat with tocilizumab 1x/week during 52 weeks in order to prevent one relapse is 2.2. Most GCA relapses (72%) occurred while patients were still receiving GC, with more than one-fifth of relapses occurring in patients receiving >10 mg/day prednisolone.²⁴ In the 2-year follow-up of the GiACTA study,²⁵ 215 of the initial 251 patients were included. No new adverse event(AE) were reported over the 3-year follow-up period. Of the 59 patients in GC-free remission in arm 1 at the end of GiACTA, 25 (42%) maintained tocilizumab-free and GC-free clinical remission, as compared with 8 of the 36 (29%) in the follow-up of arm 2. After 3 years of total follow-up, the use of GC was 33% lower in the patients initially treated in arm 1 as compared with arm 2. In relapsing patients, tocilizumab-based regimens restored clinical remission after (median): 15 days for tocilizumab alone, 16 days for tocilizumab +GC and 54 days for GC alone. Whether a GC-free induction of

remission was possible with tocilizumab was not yet clear. To address this question, a recent investigator-initiated, single-arm, open-label trial included 18 new-onset GCA patients who received 500 mg methylprednisolone intravenously for three consecutive days, combined with a single infusion of tocilizumab (8 mg/kg), followed by tocilizumab s.c. 1x/week.²⁶ The primary endpoint of an early remission at 4 weeks was not reached. Anterior ischaemic optic neuropathy occurred in one patient with extensive atherosclerosis at day 15. This proof-of concept study does not support an induction of remission with tocilizumab monotherapy.

In GiACTA, tocilizumab improved clinical outcomes regardless of the clinical phenotype (C-GCA only, PMR only or both).²⁷ Baseline parameters predicting treatment failure in the tocilizumab/GC group included female sex, lower GC doses and worse patient reported outcome measures.²⁸ In a daily practice study, tocilizumab improved GCA clinical outcomes significantly and demonstrated effectiveness in the subgroups of patients with PMR symptoms and GCA-related visual manifestations at GCA diagnosis.²⁹

Trials with the anti-IL-6 monoclonal antibody sirukumab³⁰ and another anti-IL6 receptor monoclonal antibody sarilumab (NCT03600805) were prematurely terminated due to sponsor decision or slow inclusion rate caused by COVID-19 pandemic, respectively.

The clear positive results of the GiACTA study set the stage for the rapid approval of tocilizumab for the treatment of GCA by both US and European regulatory authorities in 2017. The use of tocilizumab in GCA is currently recommended by clinical guidelines especially in patients at high risk of GC toxicity or relapsing patients^{6,31} but more recently also in new-onset GCA.³² Less clear is what is the optimal duration of tocilizumab treatment in GCA. The available follow-up data^{25,33} show that approximately half of the patients in clinical remission after 1 year of treatment maintain long-term treatment-free remission. Based on these data we recommend discontinuation of tocilizumab treatment after 1 year, followed by close monitoring especially during the first 6 months. Alternatively, the dosage of tocilizumab may be gradually decreased. In relapsing patients, combined tocilizumab-GC-based regimens are expected to restore clinical remission within 2–3 weeks.

As tocilizumab is not effective in half of the treated patients and as there are also contra-indications for or relevant side effects of tocilizumab (especially serious infections, leucopenia but also hypercholesterolaemia),^{22,23,25} the search for alternative treatments in GCA is ongoing.

IL-1 inhibitors

Anakinra is a blocker of the interleukin-1-type 1 receptor (IL-1R1), whereby the biological activity of IL-1 α and IL-1 β is inhibited. Two case series including a total of nine patients with refractory GCA^{34,35} showed efficacy of anakinra 100 mg/day as reflected by clinical and biochemical improvement accompanied by either resolution

or decrease of vascular inflammation on 18F-fluorodeoxyglucose positron emission tomography (18FDG-PET) scan.^{34 35} The GCA and Anakinra Trial (GiAnT, NCT02902731) is currently recruiting patients. An RCT with the IL-1 β blocker gevokizumab initiated in 2014 was prematurely discontinued due to the slow inclusion rate.

IL-17 inhibitors

Recently, a multicentre, phase 2 RCT exploring the efficacy and safety of secukinumab compared with placebo in combination with an open label GC taper regimen was completed. Fifty patients were randomised (1:1) to either 300 mg secukinumab or placebo s.c. during 52 weeks combined with a 26-week GC taper regimen. The primary endpoint, being the proportion of patients in sustained remission until week 28 in secukinumab vs placebo was met (70.1% vs 20.3%, respectively). At 52 weeks, 59.3% vs 8.0% of the patients were still in sustained remission.³⁶ Secukinumab was well-tolerated. A phase 3 study with secukinumab (NCT04930094) was designed but not started recruiting yet.

IL-12/IL-23 inhibitors

In a proof-of concept, prospective, open-label study, ustekinumab showed a GC-sparing effect in 14 patients with refractory GCA.³⁷ In a prospective, open-label study, 25 patients with relapsing-refractory GCA received ustekinumab 90 mg every 12 weeks.³⁸ Ustekinumab significantly reduced the GC dose from a median of 20 mg (15–25) to 5 (2.5–5) mg daily at week 52 ($p < 0.001$). There were no relapses in the ustekinumab group. Approximately one-fourth of the patients was able to stop the GC completely. There were no unexpected AE. Two of five patients who stopped the treatment had subsequently a PMR relapse without apparent GCA relapse. In another prospective, open-label trial, inclusion of 20 patients with either new-onset or relapsing GCA treated with ustekinumab was initially planned. All patients received a 24-week GC taper and ustekinumab 90 mg till week 52.³⁹ Surprisingly, only three patients achieved the primary endpoint which was GC-free remission rate at week 52. The study was prematurely terminated after 7 of the initial 10 patients had relapsed. One serious AE (SAE) occurred. The discrepancy of the outcome of these two trials may be related to differences in the study design. Currently, the Ustekinumab for the Treatment of Relapse of Refractory Giant Cell Arteritis trial is recruiting patients (NCT03711448). The IL-23 receptor blocker guselkumab is currently also being investigated in a phase 2 trial (NCT04633447).

GM-CSF inhibition

The preliminary results of a phase 2 RCT with mavrilimumab (an anti-GM-CSF-R α monoclonal antibody) were recently presented.⁴⁰ Seventy active GCA patients received either 150 mg mavrilimumab ($n=42$) or placebo ($n=28$) s.c. every 2 weeks. Primary endpoint was the time to first adjudicated flare by week 26. Median time to flare by week 26 could not be estimated (NE) in

the mavrilimumab group due to too few events, NE vs 25.1 week in mavrilimumab and placebo group, respectively, $p=0.0263$. Sustained remission at week 26 occurred in 83.2% vs 49.9% (mavrilimumab vs placebo, $p=0.0038$). Results were consistent across disease type subgroups. No vision loss occurred. AE and SAE did not differ between the groups.

Targeting JAK-STAT signalling

In a recent phase two, open-label study, 15 patients with relapsing GCA were treated with 4 mg baricitinib daily for 52 weeks in addition to a standardised GC taper.⁴¹ The primary endpoint was the safety of treatment. At week 52, 14/15 (93%) patients had at least one AE, mostly infections. Only 1 of 14 (7%) patients relapsed during the study. The remaining 13 patients achieved stable GC-free remission at week 52. Another RCT with upadacitinib (NCT03725202) is ongoing.

Targeting T cell activation

Abatacept is a soluble CTLA4Ig fusion protein that binds to CD80 and CD86 on antigen-presenting cells, thereby inhibiting the activation of T cells. Forty-nine GCA patients were initially all treated with abatacept 10 mg/kg intravenously on days 1, 15 and 29 and week 8⁴² in combination with a 28-week GC taper. At week 12, patients in remission ($n=41$) were assigned to either abatacept monthly ($n=20$) or placebo ($n=21$). The primary endpoint, being the relapse-free survival rate at 12 months was met (48% abatacept vs 31% placebo; $p=0.049$). There were no safety issues. A longer duration of remission was seen in abatacept vs placebo group (median duration 9.9 vs 3.9 months; $p=0.023$). These promising results led to the design of the ABAGART trial (NCT04474847) which is ongoing.

In a prospective, open-label study, 33 biopsy-proven GCA patients were randomised to receive either tocilizumab (intravenously 8 mg/kg/month or s.c. 162 mg/week) or abatacept (s.c. 125 mg/week) in addition to GC.⁴³ All patients in the tocilizumab intravenously group experienced a response (57% complete response and 43% partial response) vs tocilizumab s.c. 83% and abatacept 62%. After 12 months of therapy, 100% of patients in the tocilizumab groups and 43% of abatacept group were receiving doses of prednisone lower than 7.5 mg/day.

Targeting B cells, rituximab (anti-CD20)

There is one case report describing efficacy of B-cell depletion therapy in a patient with relapsing GCA.⁴⁴ Another case report describes the use of rituximab in a neutropenic patient with GCA, however, no data on the effectiveness of rituximab is provided.⁴⁵ There is yet no clinical trial with rituximab in GCA.

In summary, from the targeted immunosuppressive agents employed in clinical studies in GCA, strong evidence for a beneficial clinical effect exists so far only for tocilizumab. Secukinumab, ustekinumab, anakinra,

Table 2 Prospective, follow-up imaging studies monitoring the therapeutic response of tocilizumab on vascular inflammation in giant cell arteritis (GCA)

Author	Disease subset (no of patients)	Duration of follow-up	Disease activity at follow-up	Biochemical activity	Ultrasound	MR angiography	18F-Fluorodeoxyglucose positron emission tomography
Adler <i>et al</i> ³³	New-onset Relapsing LV-GCA (n=9)	12 mo on TCZ + 28.1 (17–44) mo	Remission: n=9 (clinical and laboratory definition)	Low CRP and ESR under TCZ Normal biomarkers*	Not performed	Persisting wall enhancement of the aorta in all patients in treatment-free remission	Not performed
Prieto Peña <i>et al</i> ⁴⁷	Relapsing C-/LV-GCA (n=7) LV-GCA (n=23)	Mean 10.8±3.7 mo	Remission: n=25 (83%) (clinical and laboratory definition)	Low CRP and ESR under TCZ	Not performed	Not performed	<ul style="list-style-type: none"> ▲ Mean TVS decreased from 4.97±2.62 to 3.13±1.89 (p<0.001) ▲ Mean thoracic TBR decreased from 1.70±0.52 to 1.48±0.25 (p=0.005) ▲ Normalisation TVS in n=3 (10%) ▲ Normalisation TBR in n=9 (30%)
Quinn <i>et al</i> ⁴⁹	New-onset Relapsing (n=25)	Up to 24 mo	At 18–24 months: remission in n=22 of 25 (88%) (clinical definition)	Not specified	Not performed	Not performed	At 18–24 mo (n=12): Median PETVAS decreased from 24.0 (22.3–27.0) to 18.5 (15.3–23.8); p<0.01.
Schönau <i>et al</i> ⁴⁸	New-onset (n=19) treated with TCZ + GC	Mean 15.3±11.8 mo	Remission: n=13, 68.4% (clinical and laboratory definition)	Low CRP and ESR under TCZ	Not performed	Not performed	PETVAS decreased from 19.8 to 7.5 (p=0.0002)
Sebastian <i>et al</i> ⁴⁶	Relapsing C-GCA (n=10) LV-GCA (n=10) C-/LV-GCA (n=2)	43 (12–52) wk Only 4 patients (18%) completed the 12 mo TCZ	At 52 wk: n=3 of 4 in remission At <52 wk: n=15 in remission (clinical definition)	Low CRP and ESR under TCZ	Decreased TA HS (median 11 to 0; n=5) Stable AA HS (n=8)	Not performed	Median TVS decreased after starting TCZ (median 11.5 to 6.5; n=4).

Continued

Table 2 Continued

Author	Disease subset (no of patients)	Duration of follow-up	Disease activity at follow-up	Biochemical activity	Ultrasound	MR angiography	18F-Fluorodeoxyglucose positron emission tomography
Seitz <i>et al</i> ⁵⁰	New onset (n=18) C-GCA (n=16) LV-GCA (n=6) treated with intravenously 500 mg GC during 3 days	52 wk	<ul style="list-style-type: none"> ▲ Baseline: active ▲ Day 2–3: n=0 in remission ▲ 4 wk: n=3 in remission ▲ 24 wk: n=14 in remission ▲ 52 wk: unclear (clinical definition) 	Not specified	<ul style="list-style-type: none"> ▲ Baseline (IMT): TA: 2.48; AA/SA: 1.36 ▲ Day 2–3: TA: 2.16; AA/SA: 1.21 ▲ 4 wk: TA: 2.50; AA/SA: 1.42 ▲ 24 wk: TA: 1.79; AA/SA: 1.54 ▲ 52 wk: TA: 1.55; AA/SA: 1.48 	Not performed	Not performed

*Interleukin-6, matrix metalloproteinase-3, soluble tumour necrosis factor receptor 2, soluble CD163, soluble intercellular adhesion molecule-1, pentraxin-3.

AA, axillary artery; C-GCA, cranial GCA; CRP, C reactive protein; ESR, erythrocyte sedimentation rate; GC, glucocorticoids; HS, Halo Score; IMT, intima-media thickness; LV-GCA, large vessel GCA; mo, month; PETVAS, Positron Emission Tomography Vascular Activity Score; SA, subclavian artery; TA, temporal artery; TBR, Target to Background ratio; TCZ, tocilizumab; TVS, Total Vascular Score; wk, week.

mavrilimumab, abatacept, the JAK-STAT inhibitors and rituximab remain promising therapeutic tools but they still have to prove their value before finding their way to the daily clinical practice in GCA. The TNF- α blockers have failed that path.

EFFECTS OF TARGETED IMMUNOSUPPRESSIVE THERAPY ON VASCULAR INFLAMMATION

The effect of targeted immunosuppressive therapy on vascular inflammation has been investigated in several prospective studies (table 2).

Tocilizumab

Adler *et al*, performed MR angiography (MRA) in all 20 tocilizumab patients at baseline.³³ At 52 weeks it was repeated in those patients who showed mural enhancement at inclusion. There was a trend to a reduction of vasculitis areas over time (from 61% to 57%) in patients in stable clinical remission. All patients in lasting remission showed MRA enhancement at follow-up, raising questions about the MRA as follow-up tool (as serum biomarkers did not indicate subclinical activity) and/or the efficiency of tocilizumab on the vascular inflammation. In a real-life, single centre study⁴⁶ including GCA patients with refractory/relapsing disease treated with tocilizumab, the TA Halo Scores decreased during the follow-up, while the axillary artery Halo Score remained stable. The total vascular score on 18FDG-PET-CT also decreased. In another single centre, observational study⁴⁷ achievement of clinical remission in 83.3% (25 of 30) (patients with refractory LV-GCA starting treatment with tocilizumab, was accompanied by a reduction of 18F-FDG vascular uptake. However, less than one-third of the patients showed complete normalisation of vascular uptake. Imaging improvement was also found in new-onset LV-GCA patients (n=19) treated with tocilizumab.⁴⁸ PET Vascular Activity Score (PETVAS) decreased from 19.8 baseline to 7.47 at mean 15.3 months of follow-up. The changes in PETVAS were similar to those found in parallel methotrexate and GC groups. In another study,⁴⁹ 25 patients starting treatment with tocilizumab underwent an FDG-PET-CT scan at the baseline visit and at follow-up every 6 months. In addition to clinical improvement, PETVAS was also significantly reduced over a 2-year treatment period. Repeated FDG-PET scans after tocilizumab discontinuation showed worsening of PET activity in five out of six patients, with two patients subsequently experiencing clinical relapse. In a study exploring a ultrashort GC strategy combined with tocilizumab⁵⁰ ultrasound evaluation of the intima-media thickness showed a slow and steady decrease in TA but no clear long-term effect on the LV.

Ustekinumab

In line with the clinical data, imaging with CT angiography in 8 patients with LV-GCA also demonstrated improvement of the vasculitis in all patients, with full resolution in 4 patients.³⁸

In summary, follow-up information on vascular activity as reflected by imaging is still limited and hampered by the lack of uniform definitions of clinical and vascular disease activity and chronic vascular damage in GCA. Although the presented studies generally document improvement of the vascular activity after tocilizumab, prospective and head-to-head comparison of different imaging modalities are warranted.

CONCLUSION

GCs are still central in the treatment in GCA but the arsenal of targeted therapies might expand in the years to come. So far, tocilizumab has been approved showing efficacy in approximately half of the GCA patients. Since multiple immune pathways are involved in GCA, investigation of other targeted therapies and combination with conventional immunosuppressive agents is awaited. Future studies with targeted therapies should include both evaluation of clinical and immunological parameters of GCA activity as well as multiple vascular imaging modalities.

Twitter Yannick van Sleen @sleenyannick

Contributors MS: study concept and design, manuscript preparation, manuscript editing, final approval of the article. NvdG: study concept and design, manuscript preparation, manuscript editing, final approval of the article. YvS: study concept and design, manuscript preparation, figure preparation, manuscript editing, final approval of the article. EB: study concept and design, manuscript preparation, manuscript editing, final approval of the article.

Funding The authors have not declared a specific grant for this research from any funding agency in the public, commercial or not-for-profit sectors.

Competing interests NvdG and EB report personal fees from Roche, outside of the submitted work.

Patient consent for publication Not applicable.

Ethics approval This study does not involve human participants.

Provenance and peer review Commissioned; externally peer reviewed.

Open access This is an open access article distributed in accordance with the Creative Commons Attribution Non Commercial (CC BY-NC 4.0) license, which permits others to distribute, remix, adapt, build upon this work non-commercially, and license their derivative works on different terms, provided the original work is properly cited, appropriate credit is given, any changes made indicated, and the use is non-commercial. See: <http://creativecommons.org/licenses/by-nc/4.0/>.

ORCID iDs

Maria Sandovici <http://orcid.org/0000-0002-4809-0653>
 Niels van der Geest <http://orcid.org/0000-0003-2798-6765>
 Yannick van Sleen <http://orcid.org/0000-0002-7382-8322>
 Elisabeth Brouwer <http://orcid.org/0000-0002-4809-0653>

REFERENCES

- 1 Dejaco C, Brouwer E, Mason JC, *et al*. Giant cell arteritis and polymyalgia rheumatica: current challenges and opportunities. *Nat Rev Rheumatol* 2017;13:578–92.
- 2 Miloslavsky EM, Naden RP, Bijlsma JWJ, *et al*. Development of a glucocorticoid toxicity index (GTI) using multicriteria decision analysis. *Ann Rheum Dis* 2017;76:543–6.
- 3 Maleszewski JJ, Younge BR, Fritzen JT, *et al*. Clinical and pathological evolution of giant cell arteritis: a prospective study of follow-up temporal artery biopsies in 40 treated patients. *Mod Pathol* 2017;30:788–96.
- 4 Muratore F, Kermani TA, Crowson CS, *et al*. Large-Vessel giant cell arteritis: a cohort study. *Rheumatology* 2015;54:463–70.
- 5 Mahr AD, Jover JA, Spiera RF, *et al*. Adjunctive methotrexate for treatment of giant cell arteritis: an individual patient data meta-analysis. *Arthritis Rheum* 2007;56:2789–97.

- 6 Mackie SL, DeJaco C, Appenzeller S, *et al.* British Society for rheumatology guideline on diagnosis and treatment of giant cell arteritis. *Rheumatology* 2020;59:e1–23.
- 7 Ma-Krupa W, Jeon M-S, Spoerl S, *et al.* Activation of arterial wall dendritic cells and breakdown of self-tolerance in giant cell arteritis. *J Exp Med* 2004;199:173–83.
- 8 Watanabe R, Berry GJ, Liang DH, *et al.* Cellular signaling pathways in medium and large vessel vasculitis. *Front Immunol* 2020;11:587089.
- 9 Samson M, Corbera-Bellalta M, Audia S, *et al.* Recent advances in our understanding of giant cell arteritis pathogenesis. *Autoimmun Rev* 2017;16:833–44.
- 10 Zhang H, Watanabe R, Berry GJ, *et al.* Inhibition of JAK-STAT signaling suppresses pathogenic immune responses in medium and large vessel vasculitis. *Circulation* 2018;137:1934–48.
- 11 Hernández-Rodríguez J, Segarra M, Vilardeell C, *et al.* Tissue production of pro-inflammatory cytokines (IL-1 β , TNF α and IL-6) correlates with the intensity of the systemic inflammatory response and with corticosteroid requirements in giant-cell arteritis. *Rheumatology* 2004;43:294–301.
- 12 Jiemy WF, van Sleen Y, van der Geest KS, *et al.* Distinct macrophage phenotypes skewed by local granulocyte macrophage colony-stimulating factor (GM-CSF) and macrophage colony-stimulating factor (M-CSF) are associated with tissue destruction and intimal hyperplasia in giant cell arteritis. *Clin Transl Immunology* 2020;9:e1164.
- 13 Cid MC, Gandhi R, Corbera-Bellalta M. THU0008 GM-CSF pathway signature identified in temporal artery biopsies of patients with giant cell arteritis. *Ann Rheum Dis* 2019;78:271.
- 14 van Sleen Y, Jiemy WF, Pringle S, *et al.* A distinct macrophage subset mediating tissue destruction and neovascularization in giant cell arteritis: implication of the YKL-40/Interleukin-13 receptor α 2 axis. *Arthritis Rheumatol* 2021;73:2327–37.
- 15 Ciccio F, Rizzo A, Maugeri R, *et al.* Ectopic expression of CXCL13, BAFF, APRIL and LT- β is associated with artery tertiary lymphoid organs in giant cell arteritis. *Ann Rheum Dis* 2017;76:235–43.
- 16 Graver JC, Boots AMH, Haacke EA, *et al.* Massive B-cell infiltration and organization into artery tertiary lymphoid organs in the aorta of large vessel giant cell arteritis. *Front Immunol* 2019;10:83.
- 17 van der Geest KSM, Abdulahad WH, Chalan P, *et al.* Disturbed B cell homeostasis in newly diagnosed giant cell arteritis and polymyalgia rheumatica. *Arthritis Rheumatol* 2014;66:1927–38.
- 18 van der Geest KSM, Sandovici M, van Sleen Y, *et al.* Review: what is the current evidence for disease subsets in giant cell arteritis? *Arthritis Rheumatol* 2018;70:1366–76.
- 19 Hoffman GS, Cid MC, Rendt-Zagar KE, *et al.* Infliximab for maintenance of glucocorticosteroid-induced remission of giant cell arteritis: a randomized trial. *Ann Intern Med* 2007;146:621.
- 20 Seror R, Baron G, Hachulla E, *et al.* Adalimumab for steroid sparing in patients with giant-cell arteritis: results of a multicentre randomised controlled trial. *Ann Rheum Dis* 2014;73:2074–81.
- 21 Martínez-Taboada VM, Rodríguez-Valverde V, Carreño L, *et al.* A double-blind placebo controlled trial of etanercept in patients with giant cell arteritis and corticosteroid side effects. *Ann Rheum Dis* 2008;67:625–30.
- 22 Villiger PM, Adler S, Kuchen S, *et al.* Tocilizumab for induction and maintenance of remission in giant cell arteritis: a phase 2, randomised, double-blind, placebo-controlled trial. *Lancet* 2016;387:1921–7.
- 23 Stone JH, Tuckwell K, Dimonaco S. Trial of tocilizumab in giant-cell arteritis. *N Engl J Med* 2017. doi:10.1056/nejmoa1613849
- 24 Stone JH, Tuckwell K, Dimonaco S, *et al.* Glucocorticoid dosages and acute-phase reactant levels at giant cell arteritis flare in a randomized trial of tocilizumab. *Arthritis Rheumatol* 2019;71:1329–38.
- 25 Stone JH, Han J, Aringer M. Long-Term effect of tocilizumab in patients with giant cell arteritis: open-label extension phase of the giant cell arteritis Actemra (GIACTA) trial. *Lancet Rheumatol* 2021.
- 26 Christ L, Seitz L, Scholz G. Tocilizumab monotherapy after ultra-short glucocorticoid administration in giant cell arteritis: a single-arm, open-label, proof-of-concept study. *Lancet Rheumatol* 2021.
- 27 Spiera R, Unizony SH, Bao M, *et al.* Tocilizumab vs placebo for the treatment of giant cell arteritis with polymyalgia rheumatica symptoms, cranial symptoms or both in a randomized trial. *Semin Arthritis Rheum* 2021;51:469–76.
- 28 Unizony SH, Bao M, Han J, *et al.* Treatment failure in giant cell arteritis. *Ann Rheum Dis* 2021;80:1467–74.
- 29 Unizony S, McCulley TJ, Spiera R, *et al.* Clinical outcomes of patients with giant cell arteritis treated with tocilizumab in real-world clinical practice: decreased incidence of new visual manifestations. *Arthritis Res Ther* 2021;23:8.
- 30 Schmidt WA, Dasgupta B, Luqmani R, *et al.* A multicentre, randomised, double-blind, placebo-controlled, parallel-group study to evaluate the efficacy and safety of Sirukumab in the treatment of giant cell arteritis. *Rheumatol Ther* 2020;7:793–810.
- 31 Hellmich B, Agueda A, Monti S, *et al.* 2018 update of the EULAR recommendations for the management of large vessel vasculitis. *Ann Rheum Dis* 2020;79:19–30.
- 32 Maz M, Chung SA, Abril A, *et al.* 2021 American College of Rheumatology/Vasculitis Foundation guideline for the management of giant cell arteritis and Takayasu arteritis. *Arthritis Care Res* 2021;73:1071–87.
- 33 Adler S, Reichenbach S, Gloor A, *et al.* Risk of relapse after discontinuation of tocilizumab therapy in giant cell arteritis. *Rheumatology* 2019;58:1639–43.
- 34 Ly K-H, Stirnemann J, Liozon E, *et al.* Interleukin-1 blockade in refractory giant cell arteritis. *Joint Bone Spine* 2014;81:76–8.
- 35 Deshayes S, Ly K-H, Rieu V, *et al.* Steroid-Sparing effect of anakinra in giant-cell arteritis: a case series with clinical, biological and iconographic long-term assessments. *Rheumatology* 2021;61:400–6.
- 36 Venhoff N, Schmidt WA, Lamprecht P, *et al.* Efficacy and safety of secukinumab in patients with giant cell arteritis: study protocol for a randomized, parallel group, double-blind, placebo-controlled phase II trial. *Trials* 2021;22:543.
- 37 Conway R, O'Neill L, O'Flynn E, *et al.* Ustekinumab for the treatment of refractory giant cell arteritis. *Ann Rheum Dis* 2016;75:1578–9.
- 38 Conway R, O'Neill L, Gallagher P, *et al.* Ustekinumab for refractory giant cell arteritis: a prospective 52-week trial. *Semin Arthritis Rheum* 2018;48:523–8.
- 39 Matza MA, Fernandes AD, Stone JH, *et al.* Ustekinumab for the treatment of giant cell arteritis. *Arthritis Care Res* 2021;73:893–7.
- 40 Cid MC, Unizony S, Pupim L. OP0059 MAVRILIMUMAB (ANTI GM-CSF RECEPTOR A MONOCLONAL ANTIBODY) REDUCES RISK OF FLARE AND INCREASES SUSTAINED REMISSION IN A PHASE 2 TRIAL OF PATIENTS WITH GIANT CELL ARTERITIS. *Ann Rheum Dis* 2021.
- 41 Koster M, Crowson C, Gblon R. Baricitinib in Relapsing Giant Cell Arteritis: A Prospective Open-Label Single-Institution Study [abstract]. *Arthritis Rheumatol* 2021;73.
- 42 Langford CA, Cuthbertson D, Ytterberg SR, *et al.* A randomized, double-blind trial of abatacept (CTLA-4Ig) for the treatment of giant cell arteritis. *Arthritis Rheumatol* 2017;69:837–45.
- 43 Rossi D, Cecchi I, Sciascia S, *et al.* An agent-to-agent real life comparison study of tocilizumab versus abatacept in giant cell arteritis. *Clin Exp Rheumatol* 2021;39 Suppl 129:125–8.
- 44 Bhatia A, Eil PJ, Edwards JCW. Anti-Cd20 monoclonal antibody (rituximab) as an adjunct in the treatment of giant cell arteritis. *Ann Rheum Dis* 2005;64:1099–100.
- 45 Mayrbaeurl B, Hinterreiter M, Burgstaller S, *et al.* The first case of a patient with neutropenia and giant-cell arteritis treated with rituximab. *Clin Rheumatol* 2007;26:1597–8.
- 46 Sebastian A, Kayani A, Prieto-Pena D, *et al.* Efficacy and safety of tocilizumab in giant cell arteritis: a single centre NHS experience using imaging (ultrasound and PET-CT) as a diagnostic and monitoring tool. *RMD Open* 2020;6:e001417.
- 47 Prieto Peña D, Martínez-Rodríguez I, Atienza-Mateo B, *et al.* Evidence for uncoupling of clinical and 18-FDG activity of PET/CT scan improvement in tocilizumab-treated patients with large-vessel giant cell arteritis. *Clin Exp Rheumatol* 2021;39 Suppl 129:69–75.
- 48 Schönau V, Roth J, Tascilar K, *et al.* Resolution of vascular inflammation in patients with new-onset giant cell arteritis: data from the RIGA study. *Rheumatology* 2021;60:3851–61.
- 49 Quinn KA, Dashora H, Novakovich E, *et al.* Use of 18F-fluorodeoxyglucose positron emission tomography to monitor tocilizumab effect on vascular inflammation in giant cell arteritis. *Rheumatology* 2021;60:4384–9.
- 50 Seitz L, Christ L, Lötscher F, *et al.* Quantitative ultrasound to monitor the vascular response to tocilizumab in giant cell arteritis. *Rheumatology* 2021;60:5052–9.