

University of Groningen

Successful treatment of hairy cell leukemia variant with obinutuzumab

Al-Sarayfi, Diana; Meeuwes, Freek O.; Munnink, Thijs Oude; Plattel, Wouter; Rosati, Stefano; Matutes, Estella; Nijland, Marcel

Published in:
Annals of Hematology

DOI:
[10.1007/s00277-021-04559-z](https://doi.org/10.1007/s00277-021-04559-z)

IMPORTANT NOTE: You are advised to consult the publisher's version (publisher's PDF) if you wish to cite from it. Please check the document version below.

Document Version
Publisher's PDF, also known as Version of record

Publication date:
2022

[Link to publication in University of Groningen/UMCG research database](#)

Citation for published version (APA):

Al-Sarayfi, D., Meeuwes, F. O., Munnink, T. O., Plattel, W., Rosati, S., Matutes, E., & Nijland, M. (2022). Successful treatment of hairy cell leukemia variant with obinutuzumab. *Annals of Hematology*, 101, 703–704. <https://doi.org/10.1007/s00277-021-04559-z>

Copyright

Other than for strictly personal use, it is not permitted to download or to forward/distribute the text or part of it without the consent of the author(s) and/or copyright holder(s), unless the work is under an open content license (like Creative Commons).

The publication may also be distributed here under the terms of Article 25fa of the Dutch Copyright Act, indicated by the "Taverne" license. More information can be found on the University of Groningen website: <https://www.rug.nl/library/open-access/self-archiving-pure/taverne-amendment>.

Take-down policy

If you believe that this document breaches copyright please contact us providing details, and we will remove access to the work immediately and investigate your claim.

Downloaded from the University of Groningen/UMCG research database (Pure): <http://www.rug.nl/research/portal>. For technical reasons the number of authors shown on this cover page is limited to 10 maximum.



Successful treatment of hairy cell leukemia variant with obinutuzumab

Diana Al-Sarayfi¹ · Freek O. Meeuwes^{1,2} · Thijs Oude Munnink³ · Wouter Plattel¹ · Stefano Rosati⁴ · Estella Matutes⁵ · Marcel Nijland¹

Received: 8 April 2021 / Accepted: 17 May 2021
© The Author(s) 2021

Dear Editor,

A 70-year-old male presented with pancytopenia and massive splenomegaly. Bone marrow examination and flow cytometry showed an extensive infiltration by hairy cell leukemia variant (HCLv) with phenotypical expression of CD20, CD22, CD11c, and CD103 and lack of CD5 and CD25 (Fig. 1A–C) [1]. Cytogenetic analysis showed a complex karyotype with loss of 17p13.3p11.2. Mutational analysis by next-generation sequencing demonstrated a mutation in TP53 (c645T > A, variant allele frequency 0.44).

The patient was initially treated with cladribine (0.15 mg/kg/day for 5 days). Bone marrow evaluation 6 weeks after treatment showed refractory disease. The patient subsequently started rituximab at a dose of 375 mg/m², which had to be discontinued after the third infusion because of an anaphylactic reaction. Rituximab plasma levels could not be detected due to anti-rituximab antibodies. Because of persistent splenomegaly, the patient subsequently underwent a

splenectomy. Histological examination of the spleen showed displacement of the normal architecture by extensive diffuse infiltration of the red pulp by HCLv. Response evaluation 6 weeks after splenectomy showed persistent cytopenia due progressive HCLv bone marrow involvement. Given the absence of detectable rituximab in the plasma and the persistent CD20 expression on the tumor cells, the patient was considered naïve to CD20-targeted therapy. The fully human anti-CD20 antibody ofatumumab has been successfully used to treat rituximab-intolerant patients, but is no longer marketed in Europe [2]. Obinutuzumab is a humanized glyco-engineered type 2 anti-CD20 monoclonal antibody, targeted at a different epitope of CD20 than rituximab and ofatumumab [3]. Because of these pharmacological differences between rituximab and obinutuzumab, we did not expect obinutuzumab to cause a cross hypersensitivity reaction [4]. Although obinutuzumab has not been reported in HCLv, it has been successfully employed in multidrug-resistant HCL [5].

After written informed consent, the patient received 4 weekly cycles of obinutuzumab at dosage of 1000 mg. The first infusion was given over 2 days, at a dose of 100 mg and 900 mg, respectively [3]. Infusion of obinutuzumab was uneventful. Blood counts normalized within 4 weeks after the start of the treatment. A bone marrow examination showed a complete remission with minimal residual disease (MRD) detected by flow cytometry (3% monoclonal B cells). The patient received consolidation with 4 weekly cycles of obinutuzumab. Six months after treatment, the patient remains in complete remission without detectable MRD (<0.01% monoclonal B cells) (Fig. 1D–F).

In conclusion, this case report shows the feasibility of obinutuzumab in patients allergic to rituximab. Obinutuzumab is a potential treatment option for patients with HCLv.

✉ Marcel Nijland
m.nijland@umcg.nl

¹ Department of Hematology, University Medical Center Groningen, Hanzeplein 1, 9700 RB Groningen, The Netherlands

² Department of Hematology, Martini Hospital, Groningen, The Netherlands

³ Department of Clinical Pharmacy and Pharmacology, University Medical Center Groningen, Hanzeplein 1, 9700 RB Groningen, The Netherlands

⁴ Department of Pathology, University Medical Center Groningen, Hanzeplein 1, 9700 RB Groningen, The Netherlands

⁵ Department of Hematopathology, Hospital Clínic, Barcelona, Spain

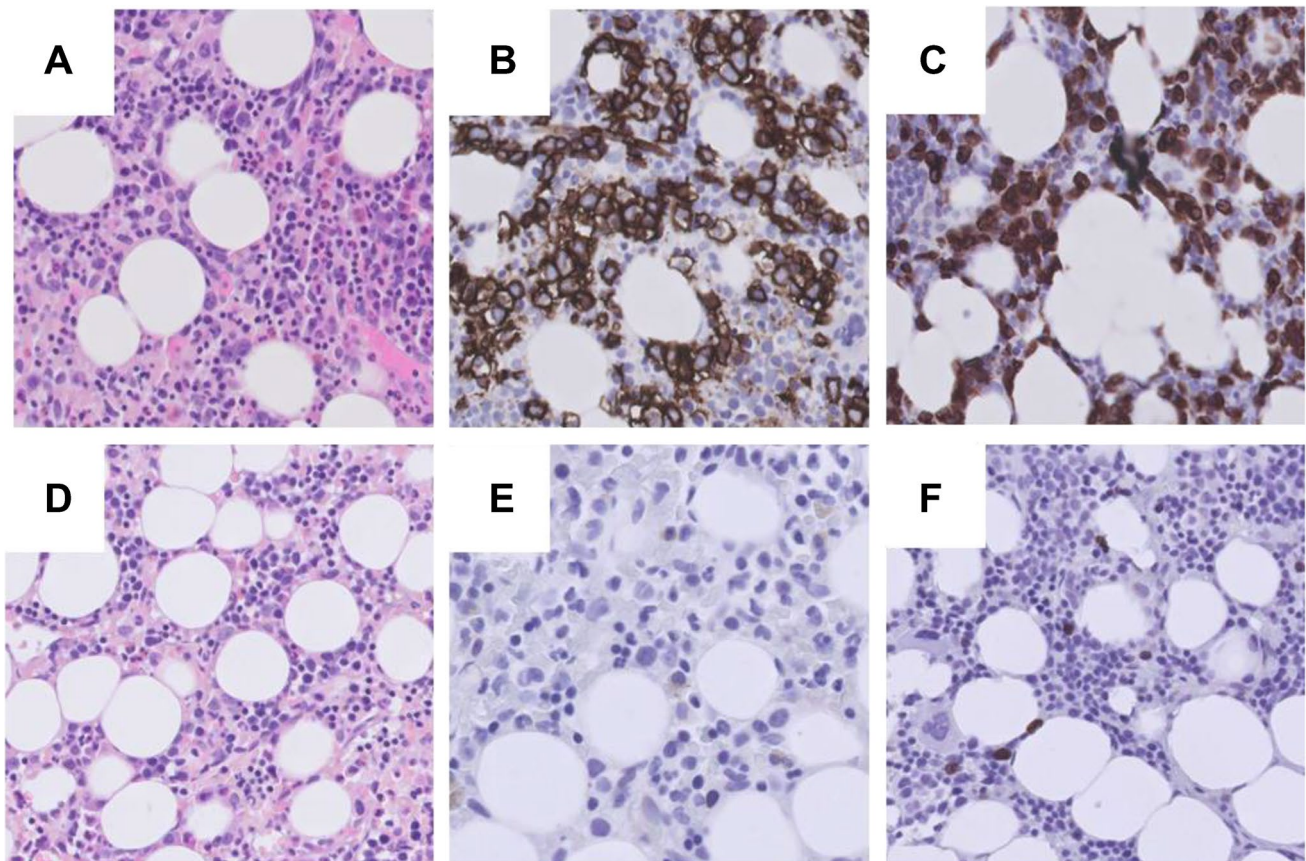


Fig. 1 Immunohistochemical staining of bone marrow biopsy of hairy cell leukemia variant ($\times 400$). **A** Bone marrow biopsy (H/E stain) at diagnosis showing a interstitial infiltrate of atypical lymphoid cells with enlarged, irregularly shaped nuclei. **B, C** Tumor

cells were CD20 and CD79a positive. **D** Bone marrow biopsy (H/E stain) after successful treatment with obinutuzumab showing normal hematopoiesis. **E, F** No CD20- or CD79a-positive B cells could be observed. This was confirmed by flow cytometry (detection $< 0.01\%$)

Declarations

Ethics approval This article does not contain any studies with human participants performed by any of the authors.

Consent to participate Informed consent was obtained from the patient for publication.

Conflict of interest The authors declare no competing interests.

Open Access This article is licensed under a Creative Commons Attribution 4.0 International License, which permits use, sharing, adaptation, distribution and reproduction in any medium or format, as long as you give appropriate credit to the original author(s) and the source, provide a link to the Creative Commons licence, and indicate if changes were made. The images or other third party material in this article are included in the article's Creative Commons licence, unless indicated otherwise in a credit line to the material. If material is not included in the article's Creative Commons licence and your intended use is not permitted by statutory regulation or exceeds the permitted use, you will need to obtain permission directly from the copyright holder. To view a copy of this licence, visit <http://creativecommons.org/licenses/by/4.0/>.

References

1. Swerdlow SH, Campo E, Harris NL, et al. WHO classification of tumours of haematopoietic and lymphoid tissues. Lyon 2017; 230–231
2. Chen LY, Shah R, Cwynarski K, Lambert J, McNamara C et al (2019) Ofatumumab is a feasible alternative anti-CD20 therapy in patients intolerant of rituximab. *Br J Haematol* 184(3):462–465
3. Goede V, Fischer K, Busch R, Engelke A, Eichhorts B et al (2014) Obinutuzumab plus chlorambucil in patients with CLL and coexisting condition. *NEJM* 370:1101–1110
4. Ghione P, Joffe E, De Paola N, Mainardi T, Noor SJ et al (2020) Alternative anti-CD20 antibody versus desensitization for lymphoma patients with drug hypersensitivity reactions requiring discontinuation of rituximab, obinutuzumab, or ofatumumab. *J Clin Oncol* 38(15_suppl):8062–8062
5. Bohn JP, Willenbacher E, Steurer M (2016) Obinutuzumab in multidrug-resistant hairy cell leukemia. *Ann Hematol* 95:s351–352

Publisher's note Springer Nature remains neutral with regard to jurisdictional claims in published maps and institutional affiliations.