

University of Groningen

Detection by fluorescence of pituitary neuroendocrine tumour (PitNET) tissue during endoscopic transsphenoidal surgery using bevacizumab-800CW (DEPARTURE trial)

Vergeer, Rob A; Postma, Mark R; Schmidt, Iris; Korsten-Meijer, Astrid GW; Feijen, Robert A; Kruijff, Schelto; Nagengast, Wouter B; van Dijk, J Marc C; den Dunnen, Wilfred F A; van Beek, André P

Published in:
BMJ Open

DOI:
[10.1136/bmjopen-2021-049109](https://doi.org/10.1136/bmjopen-2021-049109)

IMPORTANT NOTE: You are advised to consult the publisher's version (publisher's PDF) if you wish to cite from it. Please check the document version below.

Document Version
Publisher's PDF, also known as Version of record

Publication date:
2021

[Link to publication in University of Groningen/UMCG research database](#)

Citation for published version (APA):

Vergeer, R. A., Postma, M. R., Schmidt, I., Korsten-Meijer, A. GW., Feijen, R. A., Kruijff, S., Nagengast, W. B., van Dijk, J. M. C., den Dunnen, W. F. A., van Beek, A. P., Kuijlen, J. M. A., & van den Berg, G. (2021). Detection by fluorescence of pituitary neuroendocrine tumour (PitNET) tissue during endoscopic transsphenoidal surgery using bevacizumab-800CW (DEPARTURE trial): study protocol for a non-randomised, non-blinded, single centre, feasibility and dose-finding trial. *BMJ Open*, 11(10), Article 049109. <https://doi.org/10.1136/bmjopen-2021-049109>

Copyright



Other than for strictly personal use, it is not permitted to download or to forward/distribute the text or part of it without the consent of the author(s) and/or copyright holder(s), unless the work is under an open content license (like Creative Commons).

The publication may also be distributed here under the terms of Article 25fa of the Dutch Copyright Act, indicated by the "Taverne" license. More information can be found on the University of Groningen website: <https://www.rug.nl/library/open-access/self-archiving-pure/taverne-amendment>.

Take-down policy

If you believe that this document breaches copyright please contact us providing details, and we will remove access to the work immediately and investigate your claim.

BMJ Open Detection by fluorescence of pituitary neuroendocrine tumour (PitNET) tissue during endoscopic transsphenoidal surgery using bevacizumab-800CW (DEPARTURE trial): study protocol for a non-randomised, non-blinded, single centre, feasibility and dose-finding trial

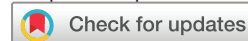Rob A Vergeer ¹, Mark R Postma,² Iris Schmidt,³ Astrid GW Korsten-Meijer,⁴ Robert A Feijen,⁴ Schelto Kruijff,⁵ Wouter B Nagengast,³ J Marc C van Dijk ⁶, Wilfred F A den Dunnen,⁷ André P van Beek,² Jos M A Kuijlen,¹ Gerrit van den Berg²

To cite: Vergeer RA, Postma MR, Schmidt I, *et al.* Detection by fluorescence of pituitary neuroendocrine tumour (PitNET) tissue during endoscopic transsphenoidal surgery using bevacizumab-800CW (DEPARTURE trial): study protocol for a non-randomised, non-blinded, single centre, feasibility and dose-finding trial. *BMJ Open* 2021;**11**:e049109. doi:10.1136/bmjopen-2021-049109

► Prepublication history for this paper is available online. To view these files, please visit the journal online (<http://dx.doi.org/10.1136/bmjopen-2021-049109>).

RAV, MRP, JMAK and GvdB contributed equally.

Received 18 January 2021
Accepted 20 September 2021



© Author(s) (or their employer(s)) 2021. Re-use permitted under CC BY-NC. No commercial re-use. See rights and permissions. Published by BMJ.

For numbered affiliations see end of article.

Correspondence to

Dr Rob A Vergeer;
ra.vergeer@umcg.nl

ABSTRACT

Introduction Achieving gross total resection and endocrine remission in pituitary neuroendocrine tumours (PitNET) can be challenging, especially in PitNETs with cavernous sinus (CS) invasion, defined as a Knosp grade of 3 or 4. A potential target to identify PitNET tissue is vascular endothelial growth factor A (VEGF-A), which expression is known to be significantly higher in PitNETs with CS invasion.

Methods and analysis The aim of this non-randomised, non-blinded, single centre, feasibility and dose-finding phase 1 trial is to determine the feasibility of intraoperative fluorescence imaging detection of PitNET tissue during endoscopic transsphenoidal surgery using the VEGF-A targeting optical agent bevacizumab-800CW (4, 5, 10 or 25 mg). Nine to fifteen patients with a PitNET with a Knosp grade of 3 or 4 will be included. Secondary objectives are: (1) To identify the optimal tracer dose for imaging of PitNET tissue during transsphenoidal surgery for further development in a phase 2 fluorescence molecular endoscopy trial. (2) To quantify fluorescence intensity in vivo and ex vivo with multidiameter single-fibre reflectance, single-fibre fluorescence (MDSFR/SFF) spectroscopy. (3) To correlate and validate both the in vivo and ex vivo measured fluorescence signals with histopathological analysis and immunohistochemical staining. (4) To assess the (sub)cellular location of bevacizumab-800CW by ex vivo fluorescence microscopy. Intraoperative, three imaging moments are defined to detect the fluorescent signal. The tumour-to-background ratios are defined by intraoperative fluorescence in vivo measurements including MDSFR/SFF spectroscopy data and by ex vivo back-table fluorescence imaging. After inclusion of three patients in each dose group, an interim analysis will be performed to define the optimal dose.

Strengths and limitations of this study

- The DEPARTURE trial is the first study on detection of pituitary neuroendocrine tumour (PitNET) tissue during endoscopic transsphenoidal surgery using the fluorescent tracer molecule bevacizumab-800CW.
- An intraoperative near infrared camera system will be used that has shown successful tumour detection using bevacizumab-800CW in tumours with high vascular endothelial growth factor A (VEGF-A) expression in multiple clinical trials.
- Multidiameter single-fibre reflectance, single-fibre fluorescence spectroscopy will be used to allow quantification of fluorescent intensities both in vivo and ex vivo.
- This pilot study is a phase 1 exploratory trial, which means that data recorded within this study cannot be directly used for the current endoscopic transsphenoidal treatment of patients with PitNET.
- A heterogeneous group of PitNETs with possible different VEGF-A expression is included in this study.

Ethics and dissemination Approval was obtained from the Medical Ethics Review Board of the University Medical Centre Groningen. Results will be disseminated through national and international journals. The participants and relevant patient support groups will be informed about the results.

Trial registration number NCT04212793

INTRODUCTION

Pituitary neuroendocrine tumours (PitNETs) are usually benign tumours arising from adenohypophyseal cells. They are a

heterogeneous group of tumours in their origin, growth patterns and biological behaviours. PitNETs account for 15% of all intracranial neoplasms and are the third most frequent tumour type after meningiomas and gliomas. They generally present either due to hypersecretion of pituitary hormones and/or due to local space occupying effects (optico-chiasmatic compression/cavernous sinus invasion) and/or hyposecretion of some or all of the pituitary hormones. PitNETs can be divided histopathologically into six main categories (somatotroph, lactotroph, thyrotroph, corticotroph, gonadotroph and plurihormonal tumours)¹ and are associated with considerably mortality² and morbidity.³ Transsphenoidal surgery (TSS) is the primary treatment of choice in all PitNETs except for lactotroph tumours, which are primarily treated with dopamine agonists. The purpose of surgery is to remove the tumour mass and thereby decompress vital structures or create endocrine remission (ER) in case of hypersecreting tumours. However, gross total resection (GTR) and ER are not always achieved, necessitating repeated surgery, additional radiotherapy and/or medical treatment. Cavernous sinus (CS) invasion, defined as a Knosp grade of 3 or 4,⁴ is the main reason for not achieving GTR and ER. In a recent study describing a modified version of this classification, tumours invading the inferior CS compartments (grade 3B) had an inferior clinical/radiological outcome versus those invading the superior CS compartments (grade 3A). The rate of intraoperative observed invasion in grade 3A PitNETs was 26.5% with a GTR/ER rate of 85%/67%, whereas for grade 3B PitNETs, the invasion rate was 70.6% with a GTR/ER rate of 64%/0%. In cases in which the intracavernous internal carotid artery was encased on preoperative MRI (grade 4), GTR and ER were never achieved.⁵ A French study recently corroborated the value of the modified Knosp classification to predict GTR and ER in PitNETs.⁶ Thus, it would be highly valuable if surgical resection can be improved in these cases, thereby limiting mortality and morbidity, but also substantially reducing lifetime treatment costs.⁷

Motivation for intraoperative molecular imaging of PitNET tissue during TSS

Although PitNET tissue has a texture different from normal pituitary tissue and is relatively easy to differentiate from the normal pituitary gland, it remains difficult to remove all tumour tissue while protecting essential structures around the sella turcica, such as the optic nerve and internal carotid artery. As a result, expert pituitary surgeons achieve remission rates of 80%–90% in patients with microadenomas (<1 cm) and 40%–70% in patients with macroadenomas (≥1 cm).³ By endoscopic sight alone, neurosurgeons cannot reliably determine locoregional removal of all tumour tissue in the inferior CS compartment. An additive instrument to differentiate between residual tumour and normal tissue during surgery could improve GTR rates and prevent recurrences. Current available evidence does not describe a

clear benefit from intraoperative fluorescence imaging using 5-Aminolevulinic acid (5-ALA), Indocyanine green (ICG), OTL-38 (On Target Laboratories, West Lafayette, Indiana) or fluorescein in PitNET surgery in terms of extent of resection or ER.⁸

METHODS AND ANALYSIS

Near-infrared fluorescence imaging for endoscopy

Near-infrared (NIR) fluorescence imaging combines optical imaging with a NIR (wavelength: 650–900 nm) targeted fluorescence tracer binding to a specific molecule. By choosing a fluorescence tracer binding to a tumour specific molecule, it is possible to visualise the presence of tumour tissue *in vivo*.

NIR optical imaging in the area of the sella has several advantages over current methods for visualising tumour characteristics: it does not use ionising radiation, it is affordable and it can be used as part of endoscopic procedures—allowing parallel biopsy acquisition of relevant tumour areas for optimal *ex vivo* analyses. The NIR window allows for both improved tissue penetration by reduced absorption of haemoglobin and reduced autofluorescence resulting in lower background signal and higher signal-to-background ratio. These advantages make NIR fluorescence imaging appropriate for *in vivo* imaging.

Multidiameter single-fibre reflectance, single-fibre fluorescence spectroscopy

To allow quantification of fluorescent intensities *in vivo*, multidiameter single fibre reflectance (MDSFR) and single-fibre fluorescence (SFF) spectroscopy has been developed by the Erasmus Medical Centre Rotterdam. MDSFR spectroscopy determines the tissue absorption coefficient and reduced scattering coefficient of the tissue, while SFF spectroscopy measures the tissue fluorescence. Afterwards, the fluorescence is corrected for the optical properties resulting in the intrinsic fluorescence which is a quantitative value.^{9–11} MDSFR-SFF spectroscopy has been successfully used previously *in vivo* and *ex vivo* in multiple ongoing clinical studies by our group (NCT02113202, NCT01972373, NCT02583568 and NCT03205501).

Clinical molecular imaging of VEGF-A

A potential target to be used to identify PitNET tissue is vascular endothelial growth factor A (VEGF-A). VEGF-A is a potent, endothelial-cell specific activator of angiogenesis and its expression is known to be significantly higher in PitNETs with CS invasion.¹²

Bevacizumab binds and neutralises all isoforms of human VEGF-A. VEGF-A is endothelial cell-specific and is one of the key regulators of angiogenesis in general, including the promotion of tumour progression and metastasis.¹³ In PitNETs, it is known to correlate with disease progression and haemorrhage.^{14 15} Overexpression of VEGF has been observed in lactotroph PitNETs,

Table 1 Overview of ongoing and completed clinical trials using bevacizumab-800CW

Indication	Subjects planned	Dose (mg)	Surgery or endoscopy	Status	Subjects enrolled*	Reference
Breast cancer (study I)	20	4.5	Surgery	Completed	20	NCT01508572
Peritoneal carcinomatosis	10	4.5	Surgery	Completed	7	NL45588
Colorectal cancer (study I)	30	4.5	Surgery/endoscopy	Completed	30	NCT01972373
Malignant oesophageal lesions	14	4.5	Endoscopy	Completed	14	NCT02129933
Familial adenomatous polyps	15	4.5, 10, 25	Endoscopy	Completed	15	NCT02113202
Breast cancer (study II)	26	4.5, 10, 25	Surgery	Completed	26	NCT02583568
Pancreatic cancer	26	4.5, 10, 25, 50	Surgery	Completed	11	NCT02743975
Endometriosis	10	4.5	Surgery	Completed	4	NCT02975219
Sinonasal inverted papilloma	8	10, 25	Surgery	Enrolling	4	NCT03925285
Oesophageal cancer	41	4.5, 10, 25	Endoscopy	Enrolling	10	NCT03558724
Sarcoma	23	10, 25, 50	Surgery	Completed	15	NCT03913806
Carotid atherosclerotic stenosis	10	4.5	Surgery	Enrolling	6	NCT03757507
Oesophageal cancer (study II)	60	0.1 mg/cm ²	Endoscopy	Enrolling	18	NCT03877601
Perihilar cholangiocarcinoma	15	4.5, 10, 25, 50	Surgery/endoscopy	Enrolling	7	NCT03620292

*Subjects enrolled by 18 February 2020.

†Dose given is 0.1 mg tracer per cm Barrett lesion. Tracer is diluted to a concentration of 0.1 mg/mL.

especially in men, and in pituitary carcinomas.^{16–19} Bevacizumab can be labelled (ratio 1:2) with the NIR organic fluorophore IRDye800CW, developed by LI-COR Biosciences (Lincoln, Nebraska, USA) and can be used for NIR imaging. Labelling of bevacizumab to IRDye800CW is performed at the Department of Clinical Pharmacy and Pharmacology of the University Medical Centre Groningen under Good Manufacturing Practice (GMP) conditions. Therefore, it is expected that the tracer bevacizumab-800CW accumulates in the pituitary micro-environment. The aim of this study is to visualise the fluorescence in the NIR spectrum using the fluorescence endoscopy system during pituitary surgery. In addition, this technique may be able to differentiate the poorly vascularised microcorticotroph tumour from the well vascularised normal surrounding pituitary.

Dose selection for bevacizumab-800CW

It is important that the tracer only binds selectively to the target tissue with a sufficient amount of fluorophore to detect a signal while any therapeutic effect of the bevacizumab moiety should be prevented.

Based on results of previous studies (table 1), doses of 4.5, 10 and 25 mg can be used safely without observed increase in bleeding risk. Tumour-to-background ratios (TBR) are calculated by fluorescence endoscopy in vivo measurements including MDSFR/SFF spectroscopy data. If background tissue, either normal pituitary or tissue of the medial wall of the cavernous sinus is available, TBR of the ex vivo tissue can be calculated. After inclusion of

the first three patients in each dose group (nine patients in total), an interim analysis is performed. After this analysis, three scenarios are possible. If one dose group allows for differentiation between tumour area and surrounding normal tissue, only this dose is expanded. If two dose groups differentiate, these are expanded to a total of six patients. If none of the doses show a sufficient contrast between tumour and normal tissue, the study is terminated after the interim analysis. In case of the first scenario, expansion of two cohorts, a final analysis is performed to define the optimal dose, which will represent a balance between the lowest dose and a clinically usable TBR, sufficient to discriminate between tumorous and non-tumorous tissue. The dose protocol for this study is shown in table 2.

Objectives

Primary objective is to determine the feasibility of bevacizumab-800CW mediated fluorescence for PitNET by comparing intraoperative both in vivo and ex vivo fluorescence measurements including MDSFR/SFF spectroscopy data with ex vivo histological examination in tumours with a Knosp grade of 3 or 4.

Secondary objectives are:

- ▶ To identify the optimal tracer dose for imaging of PitNET tissue during TSS for further development in a phase 2 fluorescence molecular endoscopy trial.
- ▶ To quantify fluorescence intensity in vivo and ex vivo with MDSFR/SFF spectroscopy.

**Table 2** Overview of possible scenarios for this study

Dosage bevacizumab-800CW	4.5 mg	10 mg	25 mg	Total subjects
Primary cohort	3	3	3	9
Interim analysis				
Extension: minimal two dose scenario	3	3		15
Extension: maximal two dose scenario		3	3	
Extension: lowest single dose scenario	3			12
Extension: medium single dose scenario		3		12
Extension: highest single dose scenario			3	12
No extension				9

- ▶ To correlate and validate both in vivo and ex vivo measured fluorescence signals with histopathological analysis and immunohistochemical staining.
- ▶ To assess the (sub)cellular location of bevacizumab-800CW by ex vivo fluorescence microscopy.

Study population

Inclusion criteria

- ▶ Age ≥ 18 years.
- ▶ Patients with an established diagnosis of PitNET with a Knosp grade of 3 or 4 who are scheduled to undergo TSS.
- ▶ WHO performance status 0–2.
- ▶ Signed written informed consent.

Exclusion criteria

- ▶ Medical or psychiatric conditions that compromise the patient's ability to give informed consent.
- ▶ Pregnant or lactating women. Documentation of a negative pregnancy test must be available for woman of childbearing potential. We define women of childbearing potential as premenopausal women with intact reproductive organs and women less than 2 years after menopause.
- ▶ History of infusion reactions to bevacizumab or other monoclonal antibody therapies.
- ▶ Inadequately controlled hypertension with or without current antihypertensive medications.
- ▶ Within 6 months prior to inclusion: myocardial infarction, transient ischemic attack, cerebrovascular accident, pulmonary embolism, uncontrolled chronic hepatic failure or unstable angina pectoris.

Sample size calculation

This is a feasibility study to investigate if accumulation of the fluorescent tracer bevacizumab-800CW can be detected with an intraoperative NIR camera system, whether this can be used to identify PitNET tissue during TSS and to define the optimal dose of bevacizumab-800CW. With the dose protocol as described in [table 2](#) we

expect to be able to determine whether this approach is feasible to continue to a phase 2 study.

Investigational treatment

Investigational product

Bevacizumab (Avastin) is a recombinant, humanised, IgG1 monoclonal antibody with specific affinity for human VEGF. IRDye800CW is a NIR organic fluorophore, developed and produced by LI-COR Biosciences and produced under GMP conditions. For more information regarding IRDye800CW to the toxicity studies of Marshall *et al.*²⁰ and Ter Weele *et al.*²¹ Conjugation of the fluorescent dye to bevacizumab, purification and formulation is performed at the department of Clinical Pharmacy and Pharmacology of the University Medical Centre Groningen. Bevacizumab-800CW is sterile filled into injection vials as a ready-to-use solution. The product is compounded by drawing the required volume of tracer into a syringe of sufficient size. No dilution of the product is performed.

Dosages, dosage modifications and method of administration

The initial dose level of 4.5 mg flat dose is based on 'FDA Guidance for Industry, Investigators, and Reviewers - Exploratory IND Studies'. This document specifies that a micro dose for proteins, in view of the higher molecular weight of protein molecules compared with conventional drugs, is defined as no more than 30 nanomoles of dust. Bevacizumab-800CW has a molecular weight of 150 000 g/mol, which brings an amount of 30 nanomoles to a dosage of 4.5 mg. This level has been chosen as the starting dose because it is the highest dose level at which a pharmacological effect of the tracer is almost certainly completely absent. Although the higher dose levels from the studies do not fall under microdosing, in terms of safety, the effect and side effects are expected to be very limited, since bevacizumab is therapeutically dosed in schedules up to 10 mg/kg body weight every 2 weeks. The higher doses are thus also far below the therapeutic doses of the antibody. From an imaging point of view, the doses of 10 and 25 mg are based on previous experiences with bevacizumab-800CW, in which other oncological indications showed that 10–25 mg gave a sufficiently strong signal that could be distinguished from background noise. Since these doses cannot be translated directly into other indications, this study has chosen to search for a workable dose for imaging in the same range.

Study procedures

Study flow chart ([figure 1](#)).

Recruitment

Inclusion of participants started on the 1 October 2020. Identification of potential participants occurs during the multidisciplinary pituitary tumour meeting. Enrolment takes place at the outpatient clinic of the neurosurgery or endocrinology department. Suitability is evaluated based on the inclusion and exclusion criteria. When a patient is identified as a potential participant,

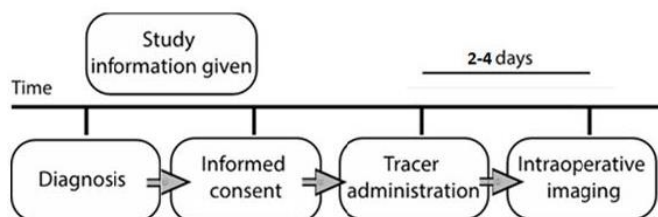


Figure 1 Study flowchart.

the patient information folder in adjusted linguistics is provided during the standard preoperative visit to the neurosurgeon.

Tracer administration

A single dose of bevacizumab-800CW (4.5 mg, 10 mg or 25 mg) is administered intravenously 2–4 days prior to surgery to the patient at the ward of the neurosurgery department. The infusion line is flushed with a saline solution afterwards. During tracer administration, a crash car with necessary equipment is available in case of an adverse reaction. Directly before and after tracer administration, blood pressure, pulse and temperature are measured. The patient is observed for 60 min following tracer injection. After the observation period of 1 hour the intravenous line is removed and the patient is discharged.

Surgical procedure

The surgery is performed according to standard of care. The procedure starts with preparing the endonasal route towards the sella, by the Ear, Nose and Throat (ENT) surgeon. When the sellar region is in sight, the anterior wall of the sella is removed and the dura exposed.

Imaging moments

1. After opening of the dura and when the tumour is in sight, in vivo NIR fluorescence imaging is performed using the fluorescence endoscopic system. Additionally, MDSFR/SFF spectroscopy data are obtained by placing the probe in the tumour tissue of interest.
2. After removal of tumour tissue, a second moment of in vivo NIR fluorescence imaging is performed and MDSFR/SFF spectroscopy data are obtained in the sella, including the normal pituitary as background tissue when available.
3. Finally, in vivo NIR fluorescence imaging is performed and MDSFR/SFF spectroscopy data are obtained of the medial wall of the cavernous sinus. If technically possible, both cavernous sinuses are imaged.

Within this feasibility and dose finding study, the surgeons do not deviate from the standard surgical procedure based on the findings of the fluorescence endoscopic system, including the number of biopsies taken. At the end of the imaging procedure, the surgery continues as usual. After the surgical procedure, patients are monitored at the recovery care unit as usual, after which they are transported to the neurosurgical ward. The surgical procedure for removal of a PitNET can be classified as a

low risk procedure. Mortality rate is below 1%. Median total hospital stay is ~5 days.

Specimen related study procedures

Fresh surgical specimen procedures

The excised surgical specimen is imaged ex vivo with the Odyssey CLx flatbed scanner (LI-COR Biosciences) for detection of fluorescence. The fresh surgical specimen is transported to the pathology department for standard histopathological analysis including immunohistochemistry. In consultation with the pathologist additional tissue is stored for further analyses.

Procedures after collection of all surgical specimens

Additional 4 µm slices are cut from formalin-fixed paraffin-embedded blocks. These slices are scanned for fluorescence on the Odyssey scanner and directly after stained with H&E staining, providing a direct correlation between the fluorescence signal and histology.

Outcome measurements

Primary outcome measures

1. Discrimination of tumorous and non-tumorous tissue based on in vivo and ex vivo fluorescence measurements from bevacizumab-800CW gained during fluorescence endoscopic transsphenoidal surgery of PitNETs. To determine the sensitivity of the marker bevacizumab-800CW in discriminating between tumorous and non-tumorous tissue during endoscopic transsphenoidal surgery of PitNETs defined as the tumour to background ratio and intrinsic fluorescence.
2. Number of participants with adverse events (AEs), serious AEs (SAEs) and suspected unexpected serious adverse reactions. Data collection as a measure of safety and tolerability regarding administration of bevacizumab-800CW.

Secondary outcome measures

1. The correlation of in vivo and ex vivo fluorescent signals to histopathological analysis results. Correlate the H/E images to the fluorescent images made with multiple ex vivo imaging modalities.
2. Quantification of the fluorescent signal by MDSFR/SFF spectroscopy. MDSFR/SFF spectroscopy can measure the fluorescence signal quantitatively, both in vivo and ex vivo.
3. Assessment of the (sub)cellular distribution of bevacizumab-800CW by ex vivo fluorescence microscopy. Imaging of the distribution of bevacizumab-800CW with a fluorescence microscope.

Withdrawal of individual subjects

The investigator can decide to withdraw a subject from the study for urgent medical reasons. Withdrawal should always be considered in case of a SAE.

Data management

Clinical record forms are recorded in a web-based data capture system, Research Electronic Data Capture

(REDCap), which is hosted by the Trial Coordination Centre of the University Medical Centre Groningen. All imaging data are stored on a secured server of the University Medical Centre Groningen.

Statistical analysis

Descriptive statistics

Descriptive statistics include measures of distribution: (geometrical) means with SD; medians with range; frequencies. Continuous variables are inspected for normal distribution by histograms, and if non-normally distributed, attempts are made to transform the data to obtain a normal distribution.

Patient and tumour characteristics

- ▶ Patient: age, sex, body mass index, clinical presentation (non-functioning PitNET, acromegaly, Cushing's disease, prolactinoma), signs and symptoms.
- ▶ Tumour: maximum diameter (mm) and Knosp classification grade, histological diagnosis, Ki67-index, VEGF staining.

Intraoperative imaging

- ▶ Semi-quantification of signal intensity (tumour/margins/background).
- ▶ Samples and biopsies taken during surgical procedure (number per individual, fluorescence yes/no, %).
- ▶ Imaging procedure time.
- ▶ Qualitative visibility of a fluorescent signal in tumour and surrounding tissue (yes/no, %) on recorded location during TSS.

Ex vivo imaging of surgical specimen

- ▶ (Semi-)quantification of fluorescent signal with available fluorescence imaging systems (mean, SD per subject for tumour and surrounding tissue for all subjects together (intra-variability and inter-variability)).
- ▶ (Semi-)quantification of fluorescent signal intensity in fresh samples (mean, SD per subject for tumour and surrounding tissue and for all tumour samples together (intra-variability and inter-variability)).
- ▶ Ex vivo VEGF levels.

Patient and public involvement

No patients were involved in the design of the study. The participants and relevant patient support groups will be informed about the results of the study.

Ethics and dissemination

Regulation statements

The study is conducted according to the principles of the Declaration of Helsinki (Fortaleza 2013 amendment) and in accordance with the medical Research Involving Human Subjects Act (WMO) and other guidelines, regulations and Acts. The protocol has been written and the study is conducted according to the International Council for Harmonisation of Technical Requirements for Pharmaceuticals for Human Use (ICH) Harmonised Tripartite Guideline for Good Clinical Practice.

Consent

An information folder in adjusted linguistics is offered to all participants containing information about the study aims, procedures and risks of potential negative effects. In a conversation with the attending physician, questions regarding the study are answered. After the visit to the neurosurgeon, the patient decides whether he/she wants to participate, for which 7 days may be used. During this period, it is possible to consult with the study coordinator or principal investigator about the study by telephone. After 7 days, the attending physician calls the patient to ask if there are any remaining questions or uncertainties and whether he/she wishes to participate. If the patient wishes to participate, the informed consent form must be signed. The appointment for tracer administration and further study-related procedures are planned after the informed consent form has been signed by both patient and investigator.

Confidentiality

The data of the participant are recorded and analysed without any personal identifiers, by using coded information. The source documents and identification lists are archived in a secured facility. Permission for accessing data are documented per investigator.

Dissemination

Results of this study will be disseminated through national and international papers. The participants and relevant patient support groups will be informed about the results of the study.

Author affiliations

¹Department of Neurosurgery, University Medical Centre Groningen, Groningen, The Netherlands

²Department of Endocrinology, University Medical Centre Groningen, Groningen, The Netherlands

³Department of Gastroenterology and Hepatology, University Medical Centre Groningen, Groningen, The Netherlands

⁴Department of Otorhinolaryngology—Head and Neck Surgery, University Medical Centre Groningen, Groningen, The Netherlands

⁵Department of Surgical Oncology, University Medical Center Groningen, Groningen, The Netherlands

⁶Department of Neurosurgery, University of Groningen, Groningen, The Netherlands

⁷Department of Pathology, University Medical Centre Groningen, Groningen, The Netherlands

Contributors MRP, RAV, JMAK, APvB and GvdB initiated the study. MRP, IS, RAV, JMAK, APvB and GvdB designed the DEPARTURE trial. RAV, IS, MRP and JMAK constructed the first draft of the protocol. RAV and MRP further edited the protocol to conform SPIRIT guidelines. AGWK-M, RAF, SK, WBN, JMCvD, WFAdD, APvB and GvdB critically reviewed the protocol and the study procedures. All authors have given final approval for the manuscript.

Funding The authors have not declared a specific grant for this research from any funding agency in the public, commercial or not-for-profit sectors.

Competing interests None declared.

Patient and public involvement Patients and/or the public were not involved in the design, or conduct, or reporting, or dissemination plans of this research.

Patient consent for publication Not applicable.

Provenance and peer review Not commissioned; externally peer reviewed.

Open access This is an open access article distributed in accordance with the Creative Commons Attribution Non Commercial (CC BY-NC 4.0) license, which permits others to distribute, remix, adapt, build upon this work non-commercially,

and license their derivative works on different terms, provided the original work is properly cited, appropriate credit is given, any changes made indicated, and the use is non-commercial. See: <http://creativecommons.org/licenses/by-nc/4.0/>.

ORCID iDs

Rob A Vergeer <http://orcid.org/0000-0002-6700-196X>

J Marc C van Dijk <http://orcid.org/0000-0002-0814-5680>

REFERENCES

- Aflorei ED, Korbonits M. Epidemiology and etiopathogenesis of pituitary adenomas. *J Neurooncol* 2014;117:379–94.
- Sherlock M, Ayuk J, Tomlinson JW, *et al*. Mortality in patients with pituitary disease. *Endocr Rev* 2010;31:301–42.
- Molitch ME. Diagnosis and treatment of pituitary adenomas: a review. *JAMA* 2017;317:516–24.
- Knosp E, Steiner E, Kitz K, *et al*. Pituitary adenomas with invasion of the cavernous sinus space: a magnetic resonance imaging classification compared with surgical findings. *Neurosurgery* 1993;33:610–7.
- Micko ASG, Wöhrer A, Wolfsberger S, *et al*. Invasion of the cavernous sinus space in pituitary adenomas: endoscopic verification and its correlation with an MRI-based classification. *J Neurosurg* 2015;122:803–11.
- Buchy M, Lapras V, Rabilloud M, *et al*. Predicting early post-operative remission in pituitary adenomas: evaluation of the modified knosp classification. *Pituitary* 2019;22:467–75.
- Biermasz NR, Roelfsema F, Pereira AM, *et al*. Cost-effectiveness of lanreotide Autogel in treatment algorithms of acromegaly. *Expert Rev Pharmacoecon Outcomes Res* 2009;9:223–34.
- Chang SW, Donoho DA, Zada G. Use of optical fluorescence agents during surgery for pituitary adenomas: current state of the field. *J Neurooncol* 2019;141:585–93.
- van Leeuwen-van Zaane F, Gamm UA, van Driel PBAA, *et al*. In vivo quantification of the scattering properties of tissue using multi-diameter single fiber reflectance spectroscopy. *Biomed Opt Express* 2013;4:696–13.
- Hoy CL, Gamm UA, Sterenberg HJCM, *et al*. Method for rapid multi-diameter single-fiber reflectance and fluorescence spectroscopy through a fiber bundle. *J Biomed Opt* 2013;18:107005.
- Middelburg TA, Hoy CL, Neumann HAM, *et al*. Correction for tissue optical properties enables quantitative skin fluorescence measurements using multi-diameter single fiber reflectance spectroscopy. *J Dermatol Sci* 2015;79:64–73.
- Iuchi T, Saeki N, Osato K, *et al*. Proliferation, vascular endothelial growth factor expression and cavernous sinus invasion in growth hormone secreting pituitary adenomas. *Acta Neurochir* 2000;142:1345–51.
- Kim KJ, Li B, Winer J, *et al*. Inhibition of vascular endothelial growth factor-induced angiogenesis suppresses tumour growth in vivo. *Nature* 1993;362:841–4.
- Niveiro M, Aranda FI, Peiró G, *et al*. Immunohistochemical analysis of tumor angiogenic factors in human pituitary adenomas. *Hum Pathol* 2005;36:1090–5.
- Cristina C, Perez-Millan MI, Luque G, *et al*. VEGF and CD31 association in pituitary adenomas. *Endocr Pathol* 2010;21:154–60.
- Trouillas J, Delgrange E, Wierinckx A, *et al*. Clinical, pathological, and molecular factors of aggressiveness in lactotroph tumours. *Neuroendocrinology* 2019;109:70–6.
- Wang Y, Li J, Tohti M, *et al*. The expression profile of dopamine D2 receptor, MGMT and VEGF in different histological subtypes of pituitary adenomas: a study of 197 cases and indications for the medical therapy. *J Exp Clin Cancer Res* 2014;33:56.
- Wierinckx A, Delgrange E, Bertolino P, *et al*. Sex-related differences in lactotroph tumor aggressiveness are associated with a specific gene-expression signature and genome instability. *Front Endocrinol* 2018;9:706.
- Lloyd RV, Scheithauer BW, Kuroki T, *et al*. Vascular endothelial growth factor (VEGF) expression in human pituitary adenomas and carcinomas. *Endocr Pathol* 1999;10:229–35.
- Marshall MV, Draney D, Sevick-Muraca EM, *et al*. Single-dose intravenous toxicity study of IRDye 800CW in Sprague-Dawley rats. *Mol Imaging Biol* 2010;12:583–94.
- Ter Weele EJ, Terwisscha van Scheltinga AGT, Linssen MD, *et al*. Development, preclinical safety, formulation, and stability of clinical grade bevacizumab-800CW, a new near infrared fluorescent imaging agent for first in human use. *Eur J Pharm Biopharm* 2016;104:226–34.