

University of Groningen

## Does SCA45 Cause Very Late-Onset Pure Cerebellar Ataxia?

Tonholo Silva, Thiago Y; Rosa, Augusto B R; Quaio, Caio R; Verbeek, Dineke; Pedroso, José Luiz; Barsottini, Orlando

*Published in:*  
Neurology. Genetics

*DOI:*  
[10.1212/NXG.0000000000000581](https://doi.org/10.1212/NXG.0000000000000581)

**IMPORTANT NOTE:** You are advised to consult the publisher's version (publisher's PDF) if you wish to cite from it. Please check the document version below.

*Document Version*  
Publisher's PDF, also known as Version of record

*Publication date:*  
2021

[Link to publication in University of Groningen/UMCG research database](#)

*Citation for published version (APA):*

Tonholo Silva, T. Y., Rosa, A. B. R., Quaio, C. R., Verbeek, D., Pedroso, J. L., & Barsottini, O. (2021). Does SCA45 Cause Very Late-Onset Pure Cerebellar Ataxia? *Neurology. Genetics*, 7(3), 1-5. [e581]. <https://doi.org/10.1212/NXG.0000000000000581>

### Copyright

Other than for strictly personal use, it is not permitted to download or to forward/distribute the text or part of it without the consent of the author(s) and/or copyright holder(s), unless the work is under an open content license (like Creative Commons).

The publication may also be distributed here under the terms of Article 25fa of the Dutch Copyright Act, indicated by the "Taverne" license. More information can be found on the University of Groningen website: <https://www.rug.nl/library/open-access/self-archiving-pure/taverne-amendment>.

### Take-down policy

If you believe that this document breaches copyright please contact us providing details, and we will remove access to the work immediately and investigate your claim.

*Downloaded from the University of Groningen/UMCG research database (Pure): <http://www.rug.nl/research/portal>. For technical reasons the number of authors shown on this cover page is limited to 10 maximum.*

# Does SCA45 Cause Very Late-Onset Pure Cerebellar Ataxia?

Thiago Y. Tonholo Silva, MD, Augusto B.R. Rosa, MD, Caio R. Quaio, MD, Dineke Verbeek, PhD, José Luiz Pedroso, MD, PhD, and Orlando Barsottini, MD, PhD

**Correspondence**

Dr. Pedroso  
jlpedroso.neuro@gmail.com

*Neurol Genet* 2021;7:e581. doi:10.1212/NXG.0000000000000581

Spinocerebellar ataxias (SCAs) are a large group of genetically and phenotypically heterogeneous autosomal dominant, neurodegenerative disorders manifesting with progressive cerebellar ataxia usually with adult-onset.<sup>1</sup> Currently, 48 subtypes of SCAs are described; of which, for 40 SCAs, the genes have been identified. The most frequent types are related to coding repeat expansions including SCA1, SCA2, SCA3, SCA6, and SCA7. However, for unusual SCA types, whole exome sequencing (WES) is necessary to identify the genetic cause. Late-onset cerebellar ataxia can be caused by several genetic mutations, but a large percentage of patients remain undiagnosed after WES.

In this article, we describe 2 siblings who presented with very late-onset cerebellar ataxia, mild cerebellar atrophy, and whose genetic investigation disclosed a novel heterozygous c.10906T>G, p.Tyr3636Asp *FAT2* (SCA45) missense variant. In addition, given that the variant is novel, affects a conserved amino acid, and segregates with disease in combination with the previous report on missense variants in *FAT2*, we may classify this variant of unknown significance as likely pathogenic.

## Case Reports

### Patient 1

An 86-year-old man presented with a progressive ataxia that started at 70 years of age. At 81 years, he developed dysarthria and dysphagia and started using a wheelchair at the age of 84 years. Family history was remarkable for cerebellar ataxia (figure A). Neurologic examination showed normal ocular movements and deep tendon reflexes, slurred speech, head titubation, and global cerebellar ataxia (video 1, [links.lww.com/NXG/A403](https://links.lww.com/NXG/A403)). Cognition was normal. Brain MRI (MRI) showed mild cerebellar atrophy (figure, B and C). Given the dominance inheritance pattern of the disease within the family, the SCA1, 2, 3, 6, 7, and 10 genes were tested for repeat expansions but was negative. WES was performed using a routine procedure including exome capture with Agilent Clinical Research Exome v1, followed by sequencing using the Illumina NextSeq platform. WES identified a novel heterozygous missense variant c.10906T>G, p.Tyr3636Asp in the SCA45 gene, *FAT2* (ENST00000261800.5).

### Patient 2

The sister of patient 1, 79 years old, presented with a 6-year history of progressive cerebellar ataxia. She also suffered of mild dysarthria, slurred speech, and dysphagia. Neurologic examination showed global ataxia (video 1). Cognition and ocular movements were normal, as well as deep tendon reflexes. Brain MRI showed mild cerebellar atrophy (figure, D and E). WES identified the same c.10906T>G, p.Tyr3636Asp variant in *FAT2*.

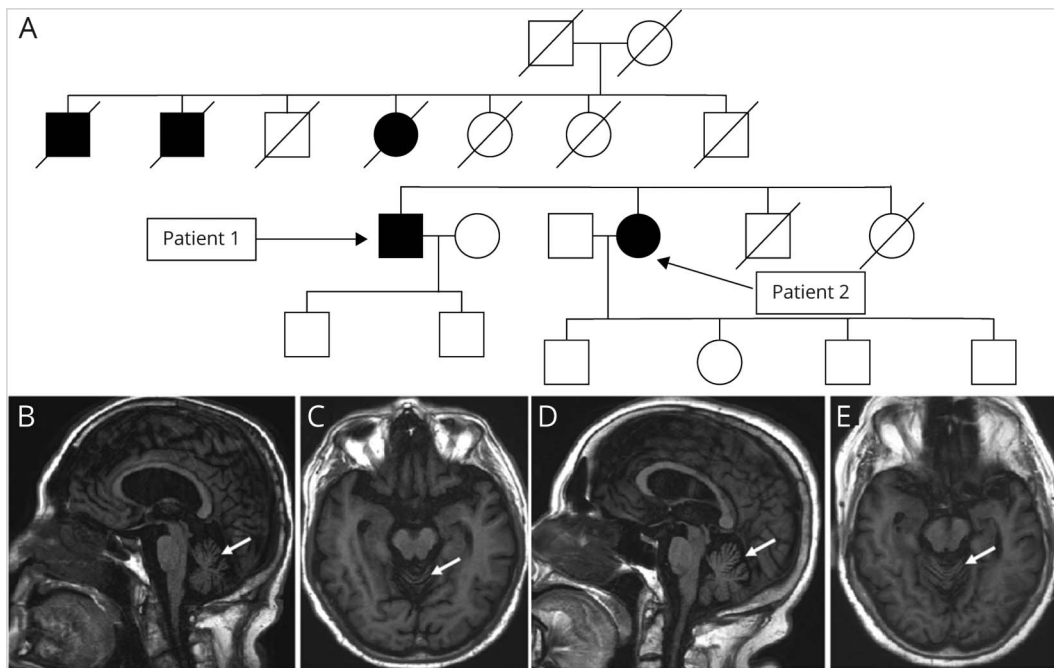
**MORE ONLINE****▶ Video**

From the Universidade Federal de São Paulo (T.Y.T.S., A.B.R.R., J.L.P., O.B.); Fleury Medicina Diagnóstica (C.R.Q.), São Paulo, Brazil; and University of Groningen (D.S.V.), Groningen, the Netherlands.

Funding information and disclosures are provided at the end of the article. Full disclosure form information provided by the authors is available with the full text of this article at [Neurology.org/NG](https://Neurology.org/NG).

This is an open access article distributed under the terms of the Creative Commons Attribution-NonCommercial-NoDerivatives License 4.0 (CC BY-NC-ND), which permits downloading and sharing the work provided it is properly cited. The work cannot be changed in any way or used commercially without permission from the journal.

**Figure 1** Heredogram and Brain Imaging of Patients with SCA45



(A) Heredogram discloses many family members affected, suggesting an autosomal dominant inheritance. Sagittal (B) and axial (C) T1-weighted brain MRI of patient 1 with SCA45 shows mild cerebellar atrophy (arrows). Sagittal (D) and axial (E) T1-weighted brain MRI of patient 2 with SCA45 also discloses mild cerebellar atrophy (arrows).

## Discussion

SCA45 (MIM #617769) related to the *FAT2* gene variants is an unusual conventional SCA type.<sup>2</sup> SCA45 was reported in 2017 in a WES-based study that reported 2 different missense variants c.10758G>C, p.Lys3586Asn and c.10946G>A, p.Arg3649Glu affecting highly conserved amino acids in the last cadherin repeat and linker region between the cadherin repeat and the laminin A-G of *FAT2*. The first variant was identified in a patient who presented with pure cerebellar ataxia, downbeat nystagmus, dysarthria, a positive family history, and disease onset after the age of 40 years. The second case also had slowly progressive ataxia and a disease onset after the age of 50 years, but no family history.<sup>2</sup> Moreover, a recent study including patients with CANVAS phenotype and negative for the *RFC1* repeat-expansion disclosed one subject with the heterozygous c.4370T>C, p.Val1457Ala variant affecting the 13<sup>th</sup> cadherin domain of *FAT2*.<sup>3</sup>

The p.Tyr3636Asp variant described in our report is novel and absent in control databases (gnomAD, ABraOM) and literature. Although this may seem a variant of unknown significance, there are some relevant points to be considered: (1) the variant is located close to the previously reported p.Lys3586Asn variant in a well-established functional domain, (2) cosegregates with disease, and (3) the phenotype is highly similar to cases described in previous studies of SCA45—we considered this variant likely pathogenic and the cause of the ataxia.

*FAT2*, previously named *MEGF1*, belongs to the family of human *FAT* genes.<sup>4</sup> *AT2* is a large transmembrane adhesion molecule specifically expressed in the cerebellar granule cells, playing an important role in postnatal cerebellum development.<sup>5</sup> *FAT* genes are the human homologous of *Drosophila fat*.<sup>6</sup> Recently, the depletion of *fat* in *Drosophila* was reported to cause neurodegeneration of the fly eye, very likely to deficits in autophagy.<sup>7</sup> The question remains whether *FAT2* in humans is also implicated in autophagy and thereby mediates neuronal homeostasis in the cerebellum needs to be established.

So far, only one family with a few affected members and one sporadic case carrying likely pathogenic *FAT2* variants have been described. All cases presented with a slowly progressive late-onset ataxia.<sup>2,3</sup> Therefore, additional cases with likely pathogenic variants presenting with late-onset ataxia and future functional studies on how variants in *FAT2* cause late-onset ataxia will further add to link between *FAT2* and SCA45. In conclusion, SCA45 seems characterized by a very late-onset cerebellar ataxia and cases presenting with such features without repeat expansions in the most common SCAs should be screened for variants in *FAT2* using WES.

## Acknowledgment

The authors would like to thank FAPESP (Fundação de Amparo à Pesquisa do Estado de São Paulo) for having funded this study.

## Study Funding

This article was funded by FAPESP (Fundação de Amparo à Pesquisa do Estado de São Paulo), grant number 2019/15298-1.

## Disclosure

T.Y. Tonholo Silva, A.B.R. Rosa, D. Verbeek and O. Barsottini report no disclosures. J.L. Pedroso received a grant from FAPESP (Fundação de Amparo à Pesquisa do Estado de São Paulo). This article was funded by FAPESP. Full disclosure form information provided by the authors is available with the full text of this article at [Neurology.org/NG](https://www.neurology.org/NG).

## Publication History

Received by *Neurology: Genetics* November 19, 2020. Accepted in final form February 3, 2021.

## Appendix Authors

Name	Location	Contribution
<b>Thiago Y. Tonholo Silva, MD</b>	Universidade Federal de São Paulo, Brazil	Conception, organization, and execution and writing of the first draft
<b>Augusto B.R. Rosa, MD</b>	Universidade Federal de São Paulo, Brazil	Conception, organization, and execution and writing of the first draft

## Appendix (continued)

Name	Location	Contribution
<b>Caio R. Quaió, MD</b>	Fleury Medicina Diagnóstica, São Paulo, Brazil	Conception, organization, and execution and writing of the first draft
<b>Dineke S. Verbeek, PhD</b>	University of Groningen Groningen, the Netherlands	Conception, organization, and execution and writing of the first draft
<b>José Luiz Pedroso, MD, PhD</b>	Universidade Federal de São Paulo, Brazil	Conception, organization, and execution; review; and critique
<b>Orlando Barsottini, MD, PhD</b>	Universidade Federal de São Paulo, Brazil	Conception, organization, and execution; review; and critique

## References

1. Klockgether T, Mariotti C, Paulson HL. Spinocerebellar ataxia. *Nat Rev Dis Primers* 2019;5:24.
2. Nibbeling EAR, Duarri A, Verschuuren-Bemelmans CC, et al. Exome sequencing and network analysis identifies shared mechanisms underlying spinocerebellar ataxia. *Brain* 2017;140:2860–2878.
3. Raféhi H, Szmulewicz DJ, Bennett MF, et al. Bioinformatics-based identification of expanded repeats: a non-reference intronic pentamer expansion in RFC1 causes CANVAS. *Am J Hum Genet* 2019;105:151–165.
4. Nakayama M, Nakajima D, Nagase T, Nomura N, Seki N, Ohara O. Identification of high-molecular-weight proteins with multiple EGF-like motifs by motif-trap screening. *Genomics* 1998;51:27–34.
5. Katoh M. Function and cancer genomics of FAT family genes (review). *Int J Oncol* 2012;41:1913–1918.
6. Nakayama M, Nakajima D, Yoshimura R, Endo Y, Ohara O. MEGF1/fat2 proteins containing extraordinarily large extracellular domains are localized to thin parallel fibers of cerebellar granule cells. *Mol Cell Neurosci* 2002;20:563–578.
7. Baron O, Grieshaber D, Dias C, Fanto M. Fat cadherins in mouse models of degenerative ataxias. *Sci Rep* 2019;9:16155.

# Neurology<sup>®</sup> Genetics

## **Does SCA45 Cause Very Late-Onset Pure Cerebellar Ataxia?**

Thiago Y. Tonholo Silva, Augusto B.R. Rosa, Caio R. Quaino, et al.

*Neurol Genet* 2021;7;

DOI 10.1212/NXG.0000000000000581

**This information is current as of March 26, 2021**

*Neurol Genet* is an official journal of the American Academy of Neurology. Published since April 2015, it is an open-access, online-only, continuous publication journal. Copyright © 2021 The Author(s). Published by Wolters Kluwer Health, Inc. on behalf of the American Academy of Neurology. All rights reserved. Online ISSN: 2376-7839.



<b>Updated Information &amp; Services</b>	including high resolution figures, can be found at: <a href="http://ng.neurology.org/content/7/3/e581.full.html">http://ng.neurology.org/content/7/3/e581.full.html</a>
<b>References</b>	This article cites 7 articles, 0 of which you can access for free at: <a href="http://ng.neurology.org/content/7/3/e581.full.html##ref-list-1">http://ng.neurology.org/content/7/3/e581.full.html##ref-list-1</a>
<b>Subspecialty Collections</b>	This article, along with others on similar topics, appears in the following collection(s): <b>All Genetics</b> <a href="http://ng.neurology.org/cgi/collection/all_genetics">http://ng.neurology.org/cgi/collection/all_genetics</a> <b>All Movement Disorders</b> <a href="http://ng.neurology.org/cgi/collection/all_movement_disorders">http://ng.neurology.org/cgi/collection/all_movement_disorders</a> <b>Cerebellum</b> <a href="http://ng.neurology.org/cgi/collection/cerebellum">http://ng.neurology.org/cgi/collection/cerebellum</a> <b>Gait disorders/ataxia</b> <a href="http://ng.neurology.org/cgi/collection/gait_disorders_ataxia">http://ng.neurology.org/cgi/collection/gait_disorders_ataxia</a> <b>Spinocerebellar ataxia</b> <a href="http://ng.neurology.org/cgi/collection/spinocerebellar_ataxia">http://ng.neurology.org/cgi/collection/spinocerebellar_ataxia</a>
<b>Permissions &amp; Licensing</b>	Information about reproducing this article in parts (figures, tables) or in its entirety can be found online at: <a href="http://ng.neurology.org/misc/about.xhtml#permissions">http://ng.neurology.org/misc/about.xhtml#permissions</a>
<b>Reprints</b>	Information about ordering reprints can be found online: <a href="http://ng.neurology.org/misc/addir.xhtml#reprintsus">http://ng.neurology.org/misc/addir.xhtml#reprintsus</a>

*Neurol Genet* is an official journal of the American Academy of Neurology. Published since April 2015, it is an open-access, online-only, continuous publication journal. Copyright © 2021 The Author(s). Published by Wolters Kluwer Health, Inc. on behalf of the American Academy of Neurology. All rights reserved. Online ISSN: 2376-7839.

