

University of Groningen

Extranodal Natural Killer/T-cell Lymphoma, Nasal Type

van Doesum, Jaap A; Niezink, Anne G H; Huls, Gerwin A; Beijert, Max; Diepstra, Arjan; van Meerten, Tom

Published in:
HemaSphere

DOI:
[10.1097/HS9.0000000000000523](https://doi.org/10.1097/HS9.0000000000000523)

IMPORTANT NOTE: You are advised to consult the publisher's version (publisher's PDF) if you wish to cite from it. Please check the document version below.

Document Version
Publisher's PDF, also known as Version of record

Publication date:
2021

[Link to publication in University of Groningen/UMCG research database](#)

Citation for published version (APA):

van Doesum, J. A., Niezink, A. G. H., Huls, G. A., Beijert, M., Diepstra, A., & van Meerten, T. (2021). Extranodal Natural Killer/T-cell Lymphoma, Nasal Type: Diagnosis and Treatment. *HemaSphere*, 5(2), Article 523. <https://doi.org/10.1097/HS9.0000000000000523>

Copyright

Other than for strictly personal use, it is not permitted to download or to forward/distribute the text or part of it without the consent of the author(s) and/or copyright holder(s), unless the work is under an open content license (like Creative Commons).

The publication may also be distributed here under the terms of Article 25fa of the Dutch Copyright Act, indicated by the "Taverne" license. More information can be found on the University of Groningen website: <https://www.rug.nl/library/open-access/self-archiving-pure/taverne-amendment>.

Take-down policy

If you believe that this document breaches copyright please contact us providing details, and we will remove access to the work immediately and investigate your claim.

Downloaded from the University of Groningen/UMCG research database (Pure): <http://www.rug.nl/research/portal>. For technical reasons the number of authors shown on this cover page is limited to 10 maximum.

Extranodal Natural Killer/T-cell Lymphoma, Nasal Type: Diagnosis and Treatment

Jaap A. van Doesum¹, Anne G. H. Niezink², Gerwin A. Huls¹, Max Beijert², Arjan Diepstra³, Tom van Meerten¹

Correspondence: J. A. van Doesum (j.a.van.doesum@umcg.nl).

Abstract

The aggressive lymphoma, extranodal natural killer/T-cell lymphoma-nasal type, is strongly associated with Epstein-Barr virus (EBV) and is most common in Asia and in South and Central America. By contrast, incidence is low in the United States and Europe, where extranodal natural killer/T-cell lymphoma represents only 0.2%–0.4% of all newly diagnosed non-Hodgkin lymphomas. At diagnosis, it is important to test for EBV DNA in plasma by polymerase chain reaction and to carry out positron emission tomography/computer tomography and magnetic resonance imaging of the nasopharynx. In stage I/II disease, radiotherapy is the most important treatment modality, but in high-risk stage I/II disease (stage II, age > 60 y, elevated lactate dehydrogenase, Eastern Cooperative Oncology Group performance score ≥ 2 , primary tumor invasion), it should be combined with chemotherapy. The most optimal responses are reached with nonmultidrug resistance-based therapy (eg, asparaginase- or platinum-based therapy). Therapeutic approaches consist of either platinum-based concurrent chemoradiotherapy or sequential chemoradiotherapy. The minimum dose of radiotherapy should be 50–56 Gy. Treatment of stage III/IV disease consists of 3 cycles of chemotherapy followed by autologous hematopoietic cell transplantation. Allogeneic hematopoietic cell transplantation should only be considered in case of relapsed disease or after difficulty reaching complete remission. During treatment and follow-up, plasma EBV levels should be monitored as a marker of tumor load.

Introduction

Extranodal natural killer/T-cell lymphoma (ENKTL) is an aggressive lymphoma that is closely associated with Epstein-Barr virus (EBV). Incidence in the United States and Europe is low, with only 0.2%–0.4% of newly diagnosed non-Hodgkin lymphomas of the ENKTL type.^{1,2} ENKTL is more common in Asia and in Central and South America, where ENKTL represents 5%–15% of all newly diagnosed lymphomas.³ Around 85% of ENKTLs originate from natural killer (NK) cells and 15% from T-cells.⁴ The most common site of occurrence is the nasopharynx, but other common locations include the sinuses, tonsils, Waldeyer ring, and oropharynx. About 70%–90% of patients have stage I or II lymphoma at presentation,⁵ and the majority present with nasal obstruction, epistaxis, or tumor growth through anatomic structures such as the palatum or orbita. Common additional symptoms include fever, weight loss, and malaise. In stage III/IV disease, the most frequent sites of occurrence include the skin, salivary glands, lymph nodes, testis, and the gastrointestinal tract, accompanied by

gastrointestinal bleeding as a common presenting symptom. In up to 11% of cases, the presenting symptom is hemophagocytic syndrome.^{6,7}

Diagnosis

Diagnosis of ENKTL by tissue biopsy is not always straightforward. In nasal mucosa, in particular, where extensive ulceration is often present, it can be difficult to differentiate between lymphoma and other conditions such as granulomatous polyangiitis, infection, or cocaine-induced destruction. ENKTL shows a diffuse and invasive growth pattern, often accompanied by an angiocentric and angiodestructive pattern that can result in necrosis and significant inflammation (Figure 1). Among individual cases, the cytological spectrum of tumor cells is broad, ranging from small and barely atypical to large and anaplastic. Nuclear contour can be irregular, the cytoplasm is often pale, and mitotic figures are frequently numerous.⁸ Epstein-Barr virus-encoded small RNAs in situ hybridization is always positive, and in most cases, the NK cell marker CD56 and cytotoxic markers granzyme B and TIA-1 are expressed and detectable by immunohistochemistry. Of the traditional T-cell markers, CD2 is positive and CD3 shows only cytoplasmic positivity, whereas CD4, CD8, CD5, and CD7 are usually negative.⁸ T-cell receptor clonality analysis by polymerase chain reaction (PCR) usually shows no rearrangement products, consistent with the NK cell origin of ENKTL in 85% of cases. In daily practice, Epstein-Barr virus-encoded small RNA and CD56 staining are very helpful in distinguishing ENKTL from other inflammatory and ulcerating processes. In view of the newly available therapeutic options, it is worth mentioning that 95% of ENKTLs are positive for CD38, about 30% for CD30 and up to 70% for programmed death-ligand 1 (PD-L1) (CD274), with positivity even reaching almost 100% in nodal cases.^{9,10}

¹Department of Hematology, University Medical Center Groningen, University of Groningen, The Netherlands

²Department of Radiation Oncology, University Medical Center Groningen, University of Groningen, The Netherlands

³Department of Pathology and Medical Biology, University Medical Center Groningen, University of Groningen, The Netherlands.

Copyright © 2021 the Author(s). Published by Wolters Kluwer Health, Inc. on behalf of the European Hematology Association. This is an open-access article distributed under the terms of the Creative Commons Attribution-Non Commercial License 4.0 (CCBY-NC), where it is permissible to download, share, remix, transform, and buildup the work provided it is properly cited. The work cannot be used commercially without permission from the journal.

HemaSphere (2021) 5:2(e523). <http://dx.doi.org/10.1097/H59.0000000000000523>.

Received: 17 July 2020 / Accepted: 23 November 2020

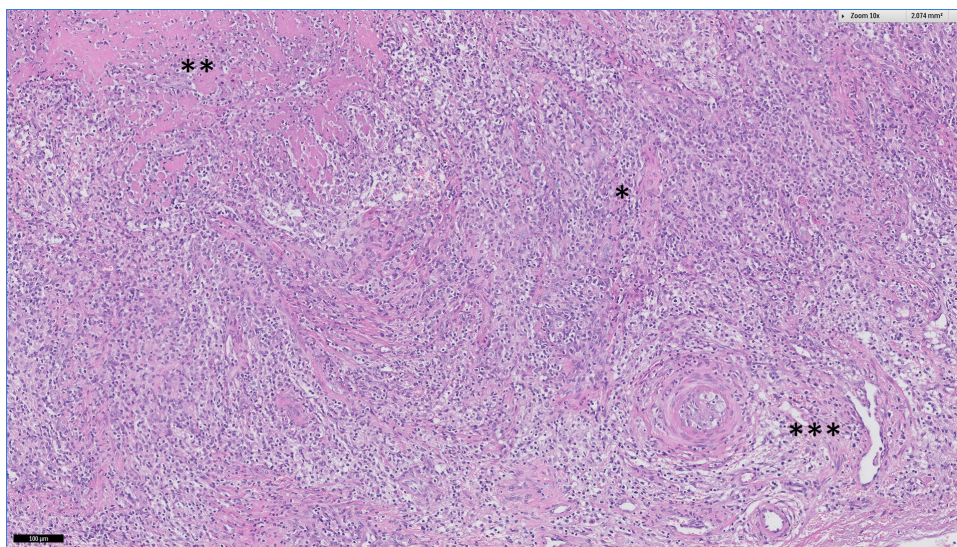


Figure 1. Histology of an NK/T-cell lymphoma showing *extensive lymphocytic infiltration, **necrosis, and ***angiocentric growth. NK = natural killer.

ENKTL is also fluorodeoxyglucose (FDG)-avid in almost 100% of cases, although maximum standardized uptake values are lower compared to diffuse large B-cell lymphoma.^{11,12} Therefore, positron emission tomography (PET)/computer tomography (CT) should be performed at diagnosis in order to stage the disease. A magnetic resonance imaging of the nasopharynx is especially recommended in cases with nasal localization in order to determine the radiation fields in stage I/II disease. Random biopsies of the nasopharynx are also recommended if nasal localization is not found on imaging of stage I/II disease, due to the possible need for radiation therapy if there is nasopharynx involvement.³

Plasma EBV load is a reliable marker for tumor load at diagnosis and can be used at follow-up for early detection of recurrent disease.¹³⁻¹⁵ PCR analysis of EBV plasma DNA is therefore advised at diagnosis as a baseline measurement.

ENKTL is often accompanied by hemophagocytosis (HLH). If there is a clinical suggestion of HLH, further diagnostics for HLH should be performed. Finally, staging of the disease includes a bone marrow biopsy.

Prognostic models

Using the Ann Arbor staging system, most ENKTL patients are categorized as early stage, which does not correlate with the poor survival. Recently the Asia lymphoma study group published a new and improved correlating staging system.¹⁶ With stage I defined as limited nasal disease without tumor invasion in the surrounding structures, stage II nonnasal localization or nasal localization with tumor invasion, stage III nasal disease with regional lymph node involvement, and stage IV disease with nonregional lymph node involvement or lymph node involvement on both sides of the diaphragm. As mentioned by the authors, the suggested staging system needs to be validated, preferably in a prospective study.

In the past, the International Prognostic Index and NK/T-cell lymphoma prognostic index were used for risk stratification. Following the introduction of nonanthracycline containing treatment regimens, these scoring systems were no longer adequate, and in 2016 the prognostic index of natural killer lymphoma (PINK) was introduced (Table 1).¹⁷ This new scoring system attributes 1 point for every risk factor, and a modification of the PINK score is the prognostic index of natural killer lymphoma-EBV score that includes all factors from the PINK score together with EBV plasma load.¹⁷ Since 2017, the PINK

score has been included in the National Comprehensive Cancer Network (NCCN) guideline for peripheral T-cell lymphoma.¹⁸

Treatment

Due to differences in treatment modalities for stage I/II and stage III/IV disease, adequate staging at diagnosis is crucial. Although almost all data are obtained from phase I/II studies or retrospective studies, it has been established that the most important treatment modality in stage I/II disease is radiotherapy, which often is combined with chemotherapy. Stage III/IV disease treatment consists of chemotherapy and hemopoietic stem cell transplantation (Figure 2).

Owing to the complexity of diagnostics and treatment, it is important that a patient is treated by a multidisciplinary team in a center with expertise in NK/T-cell lymphoma treatment.¹⁹

Treatment of a stage I/II disease

In stage I/II disease, the choice of therapy depends on the risk of disease. A large retrospective study by Yang et al,⁵ which included 1273 patients with stage I/II disease, showed that combined

Table 1
Prognostic Score Algorithm for NK/T-Cell Lymphoma.

PINK	PINK-E
Age > 60 y	Age > 60 yr
Stage III/IV disease	Stage III/IV disease
Nonnasal primary localization	Nonnasal primary localization
Distant lymph node involvement*	Distant lymph node involvement*
	Detectable plasma EBV DNA
Low: 0	Low: 0-1
Intermediate: 1	Intermediate: 2
High: 2-4	High: 3-5
3-y OS	3-y OS
Low: 81%	Low: 81%
Intermediate: 62%	Intermediate: 55%
High: 25%	High: 28%

Every item scores 1 point.
EBV = Epstein-Barr virus; ENKTL = extranodal natural killer/T-cell lymphoma; NK = natural killer; OS = overall survival; PINK = prognostic index of natural killer lymphoma; PINK-E = prognostic index of natural killer lymphoma-EBV.
*Axillary, infraclavicular, mediastinal in case of primary nasal ENKTL.

chemotherapy/radiotherapy in standard-risk disease has no additional value compared to radiotherapy alone, with a 5-year overall survival (OS) of 87% for the group with radiotherapy alone versus 88% for the group with combined chemoradiotherapy. By contrast, in high-risk disease, the 5-year OS for combined chemoradiotherapy was 72%, which compares favorably with the 60% 5-year OS for radiotherapy alone. Yang et al⁵ defined disease as high risk when 1 or more of the following factors were present:

1. Ann Arbor stage II
2. Age > 60 years
3. Elevated lactate dehydrogenase
4. Eastern Cooperative Oncology Group performance score ≥ 2
5. Primary tumor invasion into surrounding anatomic structures

These outcome data and risk stratifications were confirmed in a retrospective study by Liu et al²⁰ that also included patients treated with nonmultidrug resistance (MDR)-based treatment. These authors found no difference between treatment with radiotherapy or chemoradiotherapy in the low risk (none of above factors present) and intermediate risk (1 factor present) categories, although there was a clear trend in favor of treatment with radiotherapy combined with a non-MDR-based chemotherapy regime. However, patients in whom ≥ 2 factors were present derived clear survival benefit when treated with radiotherapy combined with a non-MDR-based chemotherapy regime.²⁰

In a retrospective study including 642 patients with stage I-II disease, Vargo et al²¹ showed that patients treated with chemotherapy alone had an inferior OS (32% 5-y OS in the chemotherapy alone group compared to 53% in the radiotherapy alone group and 58% in the combined chemoradiotherapy group). These investigators also found that OS was significantly lower with radiation doses of less than 50 Gy (5-y OS < 50 Gy 38% versus ≥ 50 Gy 53%). Another retrospective study has also shown that the risk of a locoregional relapse increases with doses < 50-52 Gy.²²

Most existing clinical data are based on the use of outdated 3D conformal radiation therapy, but radiotherapy techniques have improved over the last decades. Newer techniques such as intensity-modulated radiotherapy (IMRT) improve target coverage²³ and make it possible to reduce doses to organs at risk (OARs).²⁴ Compared to IMRT, volumetric-modulated arc therapy reduces treatment time but delivers higher mean doses to OARs.²⁴ Further reduction of dose to OARs, especially the integral dose to the body that is relevant to the induction of secondary cancers, can be achieved using proton therapy.²⁵

The International Lymphoma Radiation Oncology Group (ILROG) guideline states that the clinical target volume includes the entire involved cavity and adjacent structures. This is because ENKTL is locally destructive and may have infiltrated in adjacent tissues without macroscopic changes. Magnetic resonance imaging and PET differentiation between tumor and inflammatory tissue/retained mucus is also frequently challenging.²⁶ The guideline recommends that the delivered radiotherapy dose should be at least 50 Gy preferably using an IMRT technique, with eventually 5-10 Gy boost in case of residual disease.¹⁸

Choice of chemotherapy

In the past chemotherapeutic treatments consisted of cyclophosphamide, doxorubicin, vincristine, and prednisolone (CHOP)-like regimens and achieved 5-year OS rates of less than 50%. In the mid-1990s, it was demonstrated that ENKTL expresses the *MDR1/ABCB1* gene and its product P-glycoprotein. This indicated that anthracycline-containing regimens should be avoided and non-MDR-dependent therapies should be the first choice of therapy, examples of which are asparaginase- or platinum-based therapies.^{3,19}

Asparagine is a nonessential amino acid that can be synthesized from aspartic acid in healthy cells (Figure 3) and cellular synthesis of asparagine is accomplished by the enzymatic action of asparaginase. Asparaginase is an enzyme that breaks down asparagine, reducing cellular levels of the amino acid. Insufficient levels of cellular asparagine lead to reduced DNA, RNA, and protein synthesis, inhibition of cell growth, and ultimately to the activation of apoptotic cell death.²⁷ As glutamine can be used as an amino group donor in asparagine synthesis, it has been suggested that both asparaginase and glutamine should be depleted for optimal therapeutic effect.²⁸ Importantly, NK cells lack the asparaginase activity found in most normal cells, and asparaginase has been shown to induce apoptosis in NK/T-cell lymphoma cell lines *in vitro*.²⁹ It was subsequently shown that asparaginase is effective in patients relapsing after CHOP-based therapy.^{30,31}

The 2 main treatment strategies used for high-risk profile stage I/II disease, either concurrent chemoradiotherapy (CCRT) or a sandwich approach, showed no differences in outcome in a large retrospective study.³²

A commonly used CCRT schedule combines radiotherapy (50 Gy) and 3 cycles of dexamethasone, etoposide, ifosfamide, and carboplatin (DeVIC). A phase 2 study showed a complete

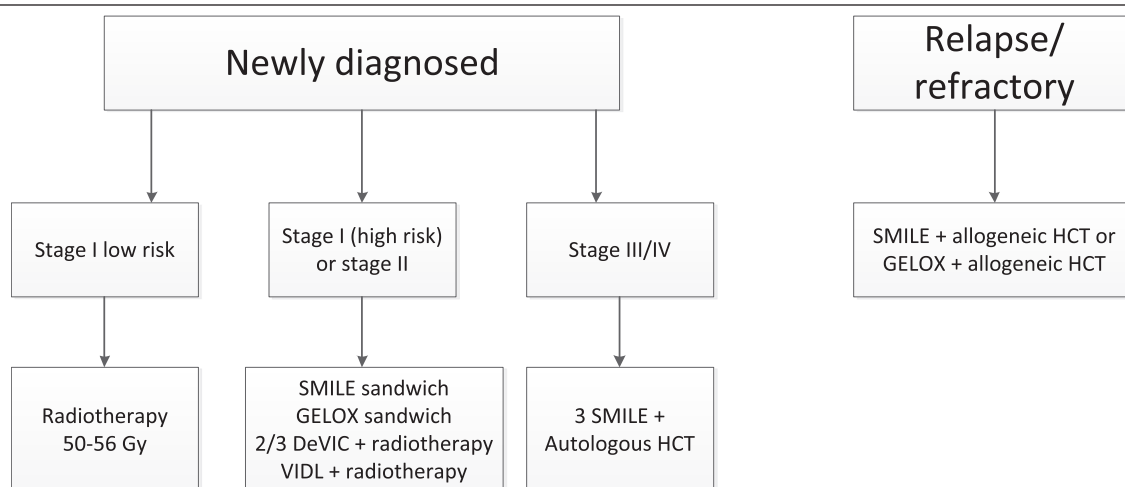
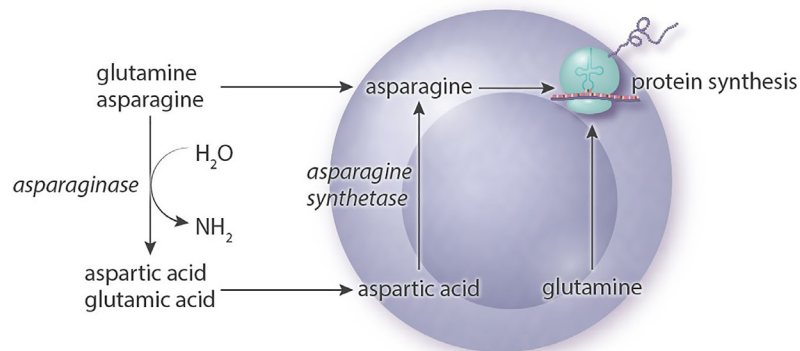
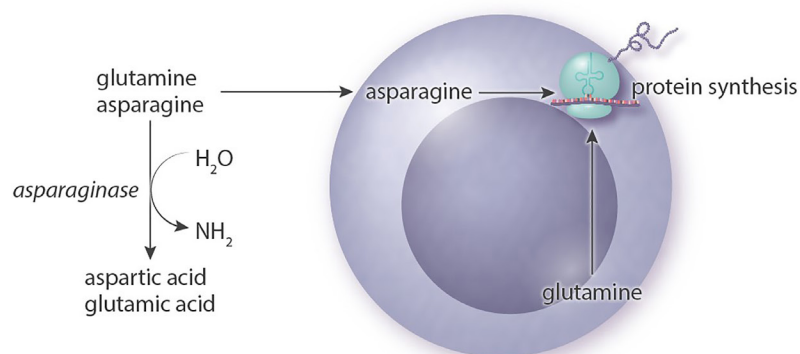


Figure 2. Proposed treatment algorithm. DeVIC = dexamethasone, etoposide, ifosfamide, and carboplatin; GELOX = gemcitabine, oxaliplatin, and L-asparaginase; HCT = hematopoietic cell transplantation; SMILE = dexamethasone, methotrexate, ifosfamide, L-asparaginase, and etoposide; VIDL = etoposide, ifosfamide, dexamethasone, and L-asparaginase.

Normal cells



NK/T cells without asparaginase



NK/T cells with asparaginase

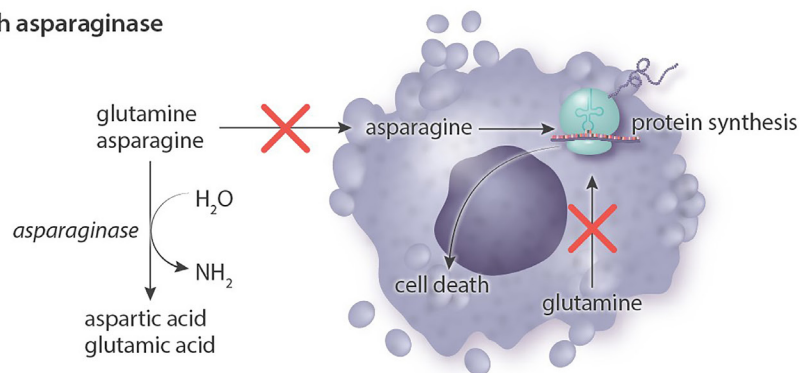


Figure 3. Mechanism of action of asparaginase. The lack of asparagine synthetase in NK/T-cells means that they are dependent on exogenous asparagine and glutamine. By degrading asparagine and glutamine to aspartic acid and glutamic acid, asparaginase inhibits essential intracellular protein synthesis and triggers cell death. NK = natural killer.

remission (CR) rate of 77%, a 5-year OS of 70%, and progression-free survival (PFS) of 63%.³³ These outcomes were later confirmed in a large retrospective study in Japan.³⁴

A schedule used in Korea combined 40-44 Gy radiotherapy with cisplatin once a week, followed by 2 cycles of VIDL (etoposide, ifosfamide, dexamethasone, and L-asparaginase). Eighty-seven percent of the patients reached CR and the 5-year OS and PFS were 73% and 60%, respectively.³⁵ Two other CCRT treatment protocols used in Korea are VIPD (etoposide, ifosfamide, cisplatin, and dexamethasone) and MIDDLE (methotrexate, ifosfamide, dexamethasone, L-asparaginase, and etoposide). In the VIPD study, 80% of patients reached CR and the 3-year PFS and OS were 85% and 86%, respectively.³⁶ The study using the MIDDLE regimen reported that 82% of patients reached CR

at 3-year follow-up, with an OS and PFS were 82% and 74%, respectively.³⁷

The most commonly used asparaginase-containing sequential regimen is sandwich therapy with 2 cycles of SMILE (dexamethasone, methotrexate, ifosfamide, L-asparaginase, and etoposide) followed by 50 Gy radiotherapy and again 2 cycles of SMILE. Eighty-two percent of patients reached CR and long-term response was 90%.³⁸ A small series of non-Asian patients whereby L-asparaginase was replaced with pegylated (PEG)-asparaginase (modified SMILE) showed a 2-year OS of 100% and a PFS of 83%.³⁹ The most common side effects were neutropenia and severe infections. Five patients died in the first study due to severe infection, after adding granulocyte-colony stimulating factor (G-CSF) support, no more deaths were seen due to

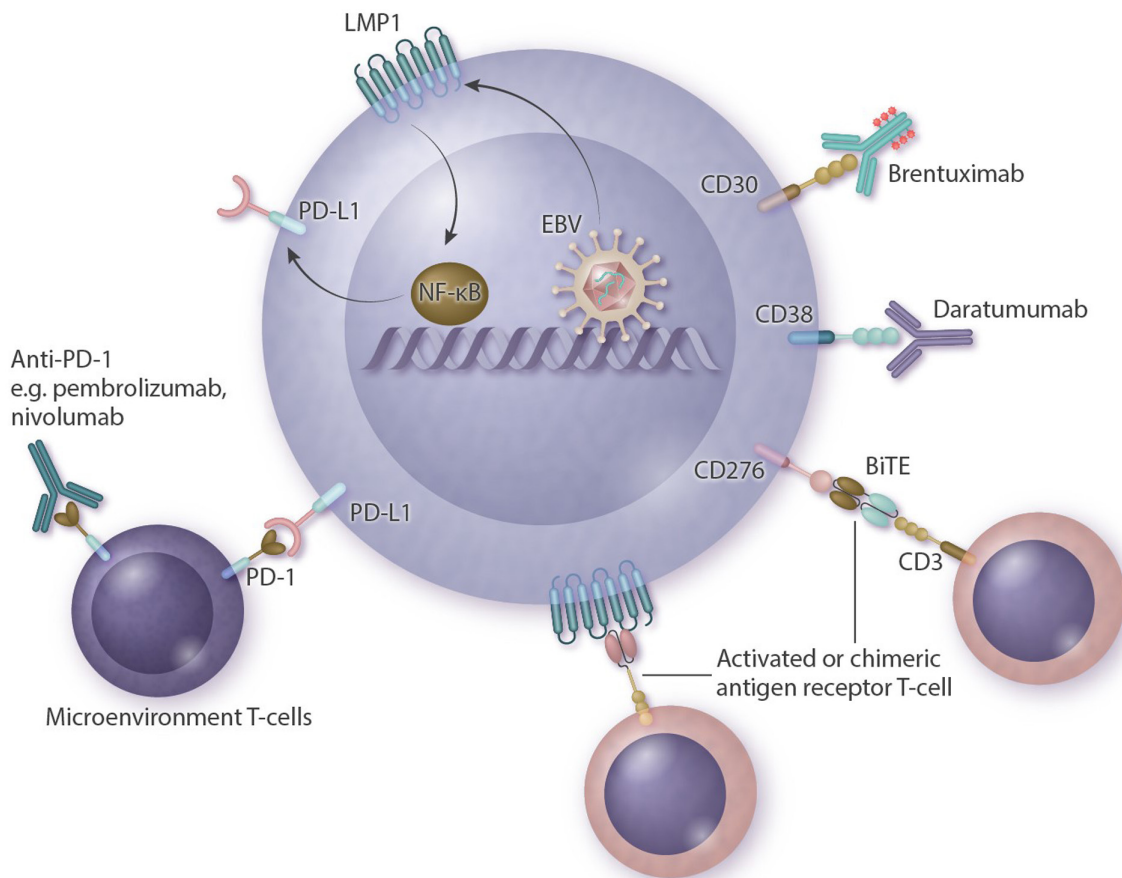


Figure 4. Summary of possible new therapeutic strategies with mechanisms of action. Antibody drugs target proteins on the cellular membrane and include brentuximab-vedotin (directed against CD30) and daratumumab (directed against CD38). Anti-PD-1 antibodies (pembrolizumab, nivolumab) target microenvironmental T-cells that become inactivated when bound to PD-L1 expressed on a lymphoma. LMP1 is a transmembrane protein produced by EBV that activates the NF- κ B pathway and leads to proliferation and lymphomagenesis. This, in turn, upregulates PD-L1. Other possible targets are CAR-T or BiTE directed against LMP1 or CD276 (B7-H3). BiTE = bisppecific antigen engager; CAR-T = chimeric antigen receptor T-cells; EBV = Epstein-Barr virus; LMP1 = latent membrane protein 1; NF- κ B = nuclear factor kappa B; PD-1 = programmed cell death protein 1; PD-L1 = programmed death-ligand 1.

infection.³¹ SMILE should only be prescribed to fit patients and when accompanied by G-CSF support.

Gemcitabine-based therapies have been combined with asparaginase in some studies. A study by Wang et al⁴⁰ combined GELOX (gemcitabine, oxaliplatin, and L-asparaginase) treatment with 56 Gy radiotherapy and reported a CR rate of 74% and a 2-year OS and PFS of 86%. This study also found less hematological toxicity than studies in which courses of SMILE were used (see also Table 2).

Treatment of stage III/IV disease

In a phase II study in stage IV disease, the response after 2 cycles of SMILE was 80%, whereby 40% reached a CR,³¹ the OS after 1 year was 55% and the PFS 53%. L-asparaginase could be replaced with PEG-asparaginase 1500-2500 IE/m² on day 8³⁹ and the cycle shortened to 21 days with PEG-asparaginase. If an allergic reaction to L-asparaginase or PEG-asparaginase occurs, an alternative is Erwinia asparaginase 25 000 IE/m² 3 times a week (6 doses in total) as a replacement for 1 dose of PEG-asparaginase or 7 doses of L-asparaginase.⁴¹

In a retrospective study of 25 patients with stage III/IV or relapsed disease, treatment with P-GEMOX (PEG-asparaginase, gemcitabine, oxaliplatin) was promising, with responses of 80%, including 51% with CR. However, as 2-year PFS was only 39% responses seem to be short-lived.⁴² Another combination in use is GDP (gemcitabine, dexamethasone, and cisplatin) (see

also Table 3).⁴³ To our knowledge, only 1 study has directly compared a gemcitabine/platinum-based regimen to a SMILE regimen.⁴⁴ In this study, DDGP (PEG-asparaginase, gemcitabine, cisplatin, and dexamethasone) was randomized against SMILE. After 3 years, PFS was 57% for the DDGP group and 42% for the SMILE group, which was accompanied by a 5-year OS of 74% for the DDGP group and 52% for the SMILE group.⁴⁵ Although the outcome of the DDGP-treated arm appears promising, there are several caveats associated with this study. First, reported outcomes for the DDGP group are much better than for other previously reported gemcitabine-based regimens, even though differences in medication are minimal. Second, a considerable number of patients in the SMILE group did not complete treatment, with only 42% completing 6 cycles and 19% not even completing 1 cycle. Third, more patients died due to toxicity in the SMILE group than expected, probably due to lack of G-CSF support in the SMILE group. And finally, this study compared L-asparaginase with PEG-asparaginase. We know from studies of acute lymphoblastic leukemia that the latter causes fewer allergic reactions and is probably more effective due to less antibody-mediated neutralization. Thus, due to the early dropout in the SMILE group, intention-to-treat analysis was probably not the best approach when comparing the 2 groups, and a per-protocol analysis of the patients that completed at least 1 cycle would have been a better comparison in terms of effectiveness. In conclusion, DDGP is probably less toxic than SMILE, but SMILE is probably more effective than reported

Table 2**Treatment of Stage I/II Disease.**

Treatment	Stage	No. Patients (n)	Response (%)	PFS (%)	OS (%)	Grade 3/4 Toxicity (%)	References
Radiotherapy 50-56 Gy	I low risk	298	NA	5-y 79	5-y 89	NA	Yang et al ¹⁵
2/3 DeVIC + 50 Gy radiotherapy	I/II	33	CR 77	5-y 63	5-y 70	Neutropenia 93 Infection/febrile neutropenia 15 TRM 0	Yamaguchi et al ³³
2/3 DeVIC + 50 Gy radiotherapy	I/II	150	NA	5-y 61	5-y 72	Neutropenia NA Infection/febrile neutropenia 22 TRM 0	Yamaguchi et al ³⁴
Cisplatin + 45 Gy radiotherapy + 2 VIDL	I/II	30	CR 87	5-y 60	5-y 73	Neutropenia 80 Infection/febrile neutropenia 17 TRM 0	Kim et al ³⁵
Cisplatin + 45 Gy radiotherapy + 2 MIDLE	I/II	28	CR 82	3-y 74	3-y 82	Neutropenia 91 Infection/febrile neutropenia 44 TRM 4	Yoon et al ³⁷
Cisplatin + 45 Gy radiotherapy + 3 VIDP	I/II	30	CR 80	3-y 80	3-y 86	Neutropenia 47 Infection/febrile neutropenia 15 TRM 7	Kim et al ³⁶
SMILE + > 40 Gy radiotherapy	I/II	17	CR 69	NA	NA	Neutropenia 67 Infection/febrile neutropenia 31 TRM 6	Kwong et al ³⁸
mSMILE + 45 Gy radiotherapy	I/II	11	NA	2-y 83	2-y 100	NA	Qi et al ³⁹
GELOX + 56 Gy radiotherapy	I/II	27	CR 74	2-y 86	2-y 86	Neutropenia 33 Infection NA TRM 0	Wang et al ⁴⁰

CR = complete remission; DeVIC = dexamethasone, etoposide, ifosfamide, and carboplatin; GELOX = gemcitabine, oxaliplatin, and L-asparaginase; MIDLE = methotrexate, ifosfamide, dexamethasone, L-asparaginase, and etoposide; mSMILE = dexamethasone, methotrexate, ifosfamide, PEG-asparaginase; NA = not available; OS = overall survival; PFS = progression-free survival; SMILE = dexamethasone, methotrexate, ifosfamide, L-asparaginase, and etoposide; TRM = treatment-related mortality; VIDL = etoposide, ifosfamide, dexamethasone, and L-asparaginase; VIDP = etoposide, ifosfamide, dexamethasone, L-asparaginase.

here and the side effects are acceptable when good support is provided. Nonetheless, gemcitabine/platinum-based therapies may possibly represent more effective treatments in less fit patients.

Radiotherapy has no standard role in the treatment of stage III/IV disease, but some small series have reported positive trends when radiotherapy was used following chemotherapy in cases with a bulky mass.⁴⁶ Patients with residual disease have reportedly converted to CR (6/8 patients converted from partial remission [PR] to CR) and the 2-year OS for the group undergoing radiotherapy was 81.5% compared to 40.2% with

no radiotherapy.⁴⁶ It should be noted that 67% of the patients in this 2015 study were treated with a nonasparaginase-based therapy. Nevertheless, further studies to establish the role of radiotherapy in stage III/IV disease are warranted.

Refractory or relapsed disease

Patients previously treated with SMILE or refractory to SMILE can be treated with gemcitabine and platinum-based regimens. Examples include P-GEMOX, possibly followed by

Table 3**Treatment of Stage III/IV/Relapsed Disease.**

Treatment	Stage	No. Patients (n)	Response (%)	PFS (%)	OS (%)	Grade 3/4 Toxicity (%)	References
SMILE	III/IV, refractory, relapsed	38	ORR 79 CR 45	1-y 53	1-y 55	Neutropenia 100 Infection/febrile neutropenia 61 TRM 0	Yamaguchi et al ³¹
SMILE	III/IV, refractory, relapsed	47	ORR III/IV 81 ORR R/R 75	4-y R/R 68,2 St III/IV NA	5-y R/R 52,3 St III/IV NA	Neutropenia 67 Infection/febrile neutropenia 31 TRM 6	Kwong et al ³⁸
DDGP	III/IV, refractory, relapsed	80	ORR 90	3-y 57	5-y 74	Neutropenia 71 Infection/febrile neutropenia NA TRM 0	Li et al ⁴⁴
P-GEMOX	III/IV, refractory, relapsed	35	ORR 94 CR 26	2-y 39	2-y 65	Neutropenia 40 Infection/febrile neutropenia NA TRM 0	Wang et al ⁴²
GDP	III/IV, refractory, relapsed	41	ORR 83 CR 42	1-y 55	1-y 73	Neutropenia 34 Infection/febrile neutropenia NA TRM 0	Wang et al ⁴³

CR = complete remission; DDGP = PEG-asparaginase, gemcitabine, cisplatin, and dexamethasone; GDP = gemcitabine, dexamethasone, and cisplatin; NA = not available; ORR = overall response rate; OS = overall survival; PEG = pegylated; PFS = progression-free survival; P-GEMOX = PEG-asparaginase, gemcitabine, and oxaliplatin; SMILE = dexamethasone, methotrexate, ifosfamide, L-asparaginase, and etoposide; TRM = treatment-related mortality.

consolidation with allogeneic hematopoietic cell transplantation (HCT). Rechallenge with an asparaginase-based therapy is possible if 6 months have passed since last treatment with SMILE, as a retrospective study by Lim et al⁴⁷ showed a 50% response rate, whereas patients retreated within 6 months were nonresponders.

Autologous hematopoietic cell transplantation

In the prospective studies by Yamaguchi et al,³¹ Kwong et al,³⁸ and Wang et al,⁴² a proportion of patients received either autologous HCT (Wang et al⁴² 20%, Yamaguchi et al³¹ 11%, and Kwong et al³⁸ 16%) or allogeneic HCT (Yamaguchi et al³¹ 45% and Kwong et al³⁸ 9%) as a form of consolidation therapy. A prospective Korean study using a SMILE regimen and autologous HCT described transplants in 11 of 27 patients; the 2-year OS was 63% and the 2-year PFS was 55%.⁴⁸ Of the 3 patients who reached CR but were not consolidated with an autologous HCT, 2 died due to relapse. The study by Kwong et al³⁸ mentioned that of those who did not receive a consolidation, 41% stayed in CR. Two recent retrospective studies from the European Society for Blood and Marrow Transplantation and American Society for Blood and Marrow Transplantation showed that consolidation with an autologous HCT has no place in the first line in the case of stage I/II disease associated with good survival (>70%) following sandwich chemoradiotherapy.^{49,50} In stage III/IV disease, an autologous HCT may have added value and is recommended in both the European Society for Medical Oncology and NCCN guidelines.^{18,51}

The number of cycles before transplantation is not established. In the Kwong et al³⁸ and Yamaguchi et al³¹ studies, 2-3 cycles were administered before transplantation. In the study by Kim et al,⁴⁸ 3 cycles were administered before transplantation.

Allogeneic hematopoietic cell transplantation

In patients who underwent an earlier autologous HCT and relapsed or in patients who did not achieve CR after first line of therapy, an allogeneic HCT could be considered. There is limited (retrospective) data available on the role of allogeneic HCT. The largest series is found in a retrospective study based on data available at the Center for International Blood and Marrow Transplant Research (CIBMTR), gathered between 2000 and 2014.⁵² This study included 82 patients, with 30% receiving an allogeneic HCT in the first line and 60% after >1 line of therapy (10% unknown). Fifty-nine percent received reduced intensity conditioning and 38% myeloablative conditioning. The 3-year PFS and OS were 28% for the reduced intensity conditioning group and 34% for the myeloablative conditioning group, respectively. No further relapses were seen after 24 months, and there was no significant difference in PFS and OS between upfront allogeneic HCT versus transplantation at relapse. It should be noted that just 38% of the patients received asparaginase-based therapy before allogeneic HCT.⁵² A retrospective Asian study of allogeneic HCT in 18 patients with mostly stage III/IV or relapsed disease showed a 5-year OS of 51%, and no further relapses at 20 months.⁵³

New therapeutic strategies

A new and promising therapy therapeutic option are the immune checkpoint inhibitors. ENKTL cells show upregulation of PD-L1, and 1 mechanism of action is via EBV triggering of latent membrane protein 1 (LMP1), which then upregulates PD-L1 expression through activation of the mitogen-activated protein kinases pathway/nuclear factor kappa B pathway (Figure 4).¹⁰ This suggests that programmed cell death protein 1/PD-L1 inhibitors are a rational choice. In 5 small retrospective series, responses of up to 100% and CR rates of up to 71% were found, despite extensive earlier treatment with L-asparaginase

and platinum-based therapy.⁵⁴⁻⁵⁷ The 2 largest series, reported by Kwong et al⁵⁴ and Couronné et al,⁵⁷ included 7 and 13 patients, respectively. In the Kwong et al⁵⁴ study, 5 patients reached CR (2 after previous allogeneic HCT) and 2 achieved PR. In the Couronné et al⁵⁷ series, only 3 of 13 patients reached CR and 2 PR. Another study, in this case from China (Orient-4), used an anti-programmed cell death protein 1 antibody, sintilimab, and reported CR or PR in 68% of the patients.⁵⁸ Several studies of sintilimab are ongoing in China (NCT04004572, NCT04127227, NCT03936452), and phase II studies are currently being conducted in the United States using pembrolizumab in patients with NK/T-cell lymphoma, including both stage I/II and III/IV disease (NCT03728972, NCT03586024).

Other potential targets include CD38 and CD30. Two case reports have described successful treatment with daratumumab (an antibody directed against CD38),^{59,60} although a phase II study with daratumumab monotherapy showed barely any response. Of the 32 patients included in the latter study, the responses included 0 reaching CR, 8 PR, 5 stable disease, 14 progressive disease, and 5 patients were not evaluable.⁶¹ Median response duration was 55 days. In addition, 2 case reports have described treatment with brentuximab-vedotin (antibody-drug conjugate directed against CD30), 1 as a monotherapy and 1 in combination with bendamustine, but both with reportedly good responses.^{62,63}

Studies are currently underway using chimeric antigen receptor T-cells directed against LMP1.⁶⁴ In an earlier study with autologous cytotoxic T-lymphocytes directed against LMP1, 3 out of 11 patients achieved long-term remission.⁶⁵ Promising results were also seen in vitro and in mice with chimeric antigen receptor T-cells and bispecific T-cell engager directed against B7-H3 (CD276).⁶⁶

As Xiong et al⁶⁷ demonstrated in their recent publication, mutations in ENKTL are very heterogeneous with different subtypes and with different responses to therapy. More personalized treatment approached will probably be developed in the future. A possible target might be the Janus kinases/signal transducer and activator of transcription protein pathway, especially as Janus kinases 3/signal transducer and activator of transcription protein 3 and STAT5B seem to be upregulated in ENKTL.⁶⁸⁻⁷⁰

Follow-up

After intensive treatment, strict follow-up is important and the focus should lie on toxicity following chemotherapy and radiotherapy, together with early identification of recurrent disease. Standard follow-up should include plasma EBV-PCR, as any sign of an increase in EBV means that relapse is inevitable, even when a patient has been in remission for years.³ Serial measurement of EBV load is therefore strongly recommended. Toxicity following chemotherapy is highly dependent on the chemotherapy schedule used. One very specific radiotherapy-related toxicity is the development of obstruction of the nasopharynx and nasal secretion, which might be due to fibrosis and inflammation but could also be a sign of recurrent disease. To further differentiate between fibrosis and recurrence or residual disease, an FDG PET-CT should be performed. Within the first months after treatment, a positive FDG PET-CT is not uncommon due to posttreatment inflammation. In case of FDG-PET positive lesions, a biopsy should be taken. In case of nasal obstruction, a nasal lavage or cleavage of fibrosis is often needed.

Disclosures

The authors declare no competing interest.

References

1. van Doesum JA, Nijland M, Brink M, Huls GA, van Meerten T. A West-European cohort of patients with NK/T-cell lymphoma, a population-based analysis. *HemaSphere*. 2020;4(S1):EP1238.

2. Karkera AC, Marshall Parson B, Borgert A, Go RS. NK/T cell lymphoma in the U.S.: a population-based study using the national cancer database from 1998–2012. *J Clin Oncol*. 2016;34(15_suppl):e19038.
3. Tse E, Kwong YL. How I treat NK/T-cell lymphomas. *Blood*. 2013;121:4997–5005.
4. de Mel S, Soon GS, Mok Y, et al. The genomics and molecular biology of natural killer/T-cell lymphoma: opportunities for translation. *Int J Mol Sci*. 2018;19:1931.
5. Yang Y, Zhu Y, Cao JZ, et al. Risk-adapted therapy for early-stage extranodal nasal-type NK/T-cell lymphoma: analysis from a multicenter study. *Blood*. 2015;126:1424–1432; quiz 1517.
6. Cheung MM, Chan JK, Lau WH, et al. Primary non-Hodgkin's lymphoma of the nose and nasopharynx: clinical features, tumor immunophenotype, and treatment outcome in 113 patients. *J Clin Oncol*. 1998;16:70–77.
7. Jia J, Song Y, Lin N, et al. Clinical features and survival of extranodal natural killer/T cell lymphoma with and without hemophagocytic syndrome. *Ann Hematol*. 2016;95:2023–2031.
8. Swerdlow SH, Campo E, Pileri SA, et al. The 2016 revision of the World Health Organization classification of lymphoid neoplasms. *Blood*. 2016;127:2375–2390.
9. Wang L, Wang H, Li PF, et al. CD38 expression predicts poor prognosis and might be a potential therapy target in extranodal NK/T cell lymphoma, nasal type. *Ann Hematol*. 2015;94:1381–1388.
10. Hu B, Oki Y. Novel immunotherapy options for extranodal NK/T-cell lymphoma. *Front Oncol*. 2018;8:139.
11. Khong PL, Pang CB, Liang R, et al. Fluorine-18 fluorodeoxyglucose positron emission tomography in mature T-cell and natural killer cell malignancies. *Ann Hematol*. 2008;87:613–621.
12. Chan WK, Au WY, Wong CY, et al. Metabolic activity measured by F-18 FDG PET in natural killer-cell lymphoma compared to aggressive B- and T-cell lymphomas. *Clin Nucl Med*. 2010;35:571–575.
13. Kwong YL, Anderson BO, Advani R, et al; Asian Oncology Summit. Management of T-cell and natural-killer-cell neoplasms in Asia: consensus statement from the Asian Oncology Summit 2009. *Lancet Oncol*. 2009;10:1093–1101.
14. Au WY, Pang A, Choy C, et al. Quantification of circulating Epstein-Barr virus (EBV) DNA in the diagnosis and monitoring of natural killer cell and EBV-positive lymphomas in immunocompetent patients. *Blood*. 2004;104:243–249.
15. Suzuki R, Yamaguchi M, Izutsu K, et al; NK-cell Tumor Study Group. Prospective measurement of Epstein-Barr virus-DNA in plasma and peripheral blood mononuclear cells of extranodal NK/T-cell lymphoma, nasal type. *Blood*. 2011;118:6018–6022.
16. Hong H, Li Y, Lim ST, et al. A proposal for a new staging system for extranodal natural killer T-cell lymphoma: a multicenter study from China and Asia Lymphoma Study Group. *Leukemia*. 2020;34:2243–2248.
17. Kim SJ, Yoon DH, Jaccard A, et al. A prognostic index for natural killer cell lymphoma after non-anthracycline-based treatment: a multicentre, retrospective analysis. *Lancet Oncol*. 2016;17:389–400.
18. Horwitz SM, Ansell SM, Ai WZ, et al. NCCN guidelines insights: T-cell lymphomas, version 2.2018. *J Natl Compr Canc Netw*. 2018;16:123–135.
19. Yamaguchi M, Suzuki R, Oguchi M. Advances in the treatment of extranodal NK/T-cell lymphoma, nasal type. *Blood*. 2018;131:2528–2540.
20. Liu X, Wu T, Zhu SY, et al. Risk-dependent conditional survival and failure hazard after radiotherapy for early-stage extranodal natural killer/T-cell lymphoma. *JAMA Netw Open*. 2019;2:e190194.
21. Vargo JA, Patel A, Glaser SM, et al. The impact of the omission or inadequate dosing of radiotherapy in extranodal natural killer T-cell lymphoma, nasal type, in the United States. *Cancer*. 2017;123:3176–3185.
22. Yang Y, Cao JZ, Lan SM, et al. Association of improved locoregional control with prolonged survival in early-stage extranodal nasal-type natural killer/T-cell lymphoma. *JAMA Oncol*. 2017;3:83–91.
23. Tomita N, Kodaira T, Tachibana H, et al. A comparison of radiation treatment plans using IMRT with helical tomotherapy and 3D conformal radiotherapy for nasal natural killer/T-cell lymphoma. *Br J Radiol*. 2009;82:756–763.
24. Liu X, Huang E, Wang Y, et al. Dosimetric comparison of helical tomotherapy, VMAT, fixed-field IMRT and 3D-conformal radiotherapy for stage I-II nasal natural killer T-cell lymphoma. *Radiat Oncol*. 2017;12:76.
25. Tseng YD, Cutter DJ, Plastaras JP, et al. Evidence-based review on the use of proton therapy in lymphoma from the Particle Therapy Cooperative Group (PTCOG) lymphoma subcommittee. *Int J Radiat Oncol Biol Phys*. 2017;99:825–842.
26. Yahalom J, Illidge T, Specht L, et al; International Lymphoma Radiation Oncology Group. Modern radiation therapy for extranodal lymphomas: field and dose guidelines from the International Lymphoma Radiation Oncology Group. *Int J Radiat Oncol Biol Phys*. 2015;92:11–31.
27. Müller HJ, Boos J. Use of L-asparaginase in childhood ALL. *Crit Rev Oncol Hematol*. 1998;28:97–113.
28. Panosyan EH, Grigoryan RS, Avramis IA, et al. Deamination of glutamine is a prerequisite for optimal asparagine deamination by asparaginases in vivo (CCG-1961). *Anticancer Res*. 2004;24:1121–1125.
29. Ando M, Sugimoto K, Kitoh T, et al. Selective apoptosis of natural killer-cell tumours by L-asparaginase. *Br J Haematol*. 2005;130:860–868.
30. Jaccard A, Petit B, Girault S, et al. L-asparaginase-based treatment of 15 western patients with extranodal NK/T-cell lymphoma and leukemia and a review of the literature. *Ann Oncol*. 2009;20:110–116.
31. Yamaguchi M, Kwong YL, Kim WS, et al. Phase II study of SMILE chemotherapy for newly diagnosed stage IV, relapsed, or refractory extranodal natural killer (NK)/T-cell lymphoma, nasal type: the NK-Cell Tumor Study Group study. *J Clin Oncol*. 2011;29:4410–4416.
32. Kwong YL, Kim SJ, Tse E, et al. Sequential chemotherapy/radiotherapy was comparable with concurrent chemoradiotherapy for stage I/II NK/T-cell lymphoma. *Ann Oncol*. 2018;29:256–263.
33. Yamaguchi M, Tobinai K, Oguchi M, et al. Phase I/II study of concurrent chemoradiotherapy for localized nasal natural killer/T-cell lymphoma: Japan Clinical Oncology Group Study JCOG0211. *J Clin Oncol*. 2009;27:5594–5600.
34. Yamaguchi M, Suzuki R, Oguchi M, et al. Treatments and outcomes of patients with extranodal natural killer/T-cell lymphoma diagnosed between 2000 and 2013: a cooperative study in Japan. *J Clin Oncol*. 2017;35:32–39.
35. Kim SJ, Yang DH, Kim JS, et al. Concurrent chemoradiotherapy followed by L-asparaginase-containing chemotherapy, VIDL, for localized nasal extranodal NK/T cell lymphoma: CISL08-01 phase II study. *Ann Hematol*. 2014;93:1895–1901.
36. Kim SJ, Kim K, Kim BS, et al. Phase II trial of concurrent radiation and weekly cisplatin followed by VIPD chemotherapy in newly diagnosed, stage IE to IIE, nasal, extranodal NK/T-cell lymphoma: consortium for improving survival of lymphoma study. *J Clin Oncol*. 2009;27:6027–6032.
37. Yoon DH, Kim SJ, Jeong SH, et al. Phase II trial of concurrent chemoradiotherapy with L-asparaginase and MIDDLE chemotherapy for newly diagnosed stage I/II extranodal NK/T-cell lymphoma, nasal type (CISL-1008). *Oncotarget*. 2016;7:85584–85591.
38. Kwong YL, Kim WS, Lim ST, et al. SMILE for natural killer/T-cell lymphoma: analysis of safety and efficacy from the Asia Lymphoma Study Group. *Blood*. 2012;120:2973–2980.
39. Qi S, Yahalom J, Hsu M, et al. Encouraging experience in the treatment of nasal type extra-nodal NK/T-cell lymphoma in a non-Asian population. *Leuk Lymphoma*. 2016;57:2575–2583.
40. Wang L, Wang ZH, Chen XQ, et al. First-line combination of gemcitabine, oxaliplatin, and L-asparaginase (GELOX) followed by involved-field radiation therapy for patients with stage IE/II extranodal natural killer/T-cell lymphoma. *Cancer*. 2013;119:348–355.
41. Salzer WL, Asselin B, Supko JG, et al. Erwinia asparaginase achieves therapeutic activity after pegaspargase allergy: a report from the Children's Oncology Group. *Blood*. 2013;122:507–514.
42. Wang JH, Wang L, Liu CC, et al. Efficacy of combined gemcitabine, oxaliplatin and pegaspargase (P-gemox regimen) in patients with newly diagnosed advanced-stage or relapsed/refractory extranodal NK/T-cell lymphoma. *Oncotarget*. 2016;7:29092–29101.
43. Wang JJ, Dong M, He XH, et al. GDP (gemcitabine, dexamethasone, and cisplatin) is highly effective and well-tolerated for newly diagnosed stage IV and relapsed/refractory extranodal natural killer/T-cell lymphoma, nasal type. *Medicine (Baltimore)*. 2016;95:e2787.
44. Li X, Cui Y, Sun Z, et al. DDGP versus SMILE in newly diagnosed advanced natural killer/T-cell lymphoma: a randomized controlled, multicenter, open-label study in China. *Clin Cancer Res*. 2016;22:5223–5228.
45. Wang X, Zhang L, Liu X, et al. Efficacy and survival in newly diagnosed advanced extranodal natural killer/T-cell lymphoma: a randomized, controlled, multicenter and open-labeled study with Ddgp regimen versus SMILE regimen. *Blood*. 2019;134(suppl_1):463–463.
46. Bi XW, Jiang WQ, Zhang WW, et al. Treatment outcome of patients with advanced stage natural killer/T-cell lymphoma: elucidating the effects of asparaginase and postchemotherapeutic radiotherapy. *Ann Hematol*. 2015;94:1175–1184.

47. Lim SH, Hong JY, Lim ST, et al. Beyond first-line non-anthracycline-based chemotherapy for extranodal NK/T-cell lymphoma: clinical outcome and current perspectives on salvage therapy for patients after first relapse and progression of disease. *Ann Oncol*. 2017;28:2199–2205.
48. Kim SJ, Park S, Kang ES, et al. Induction treatment with SMILE and consolidation with autologous stem cell transplantation for newly diagnosed stage IV extranodal natural killer/T-cell lymphoma patients. *Ann Hematol*. 2015;94:71–78.
49. Fox CP, Boumendil A, Schmitz N, et al. High-dose therapy and autologous stem cell transplantation for extra-nodal NK/T lymphoma in patients from the Western hemisphere: a study from the European Society for Blood and Marrow Transplantation. *Leuk Lymphoma*. 2015;56:3295–3300.
50. Yhim HY, Kim JS, Mun YC, et al; Consortium for Improving Survival of Lymphoma Study. Clinical outcomes and prognostic factors of up-front autologous stem cell transplantation in patients with extranodal natural killer/T cell lymphoma. *Biol Blood Marrow Transplant*. 2015;21:1597–1604.
51. d'Amore F, Gaulard P, Trumper L, et al; ESMO Guidelines Committee. Peripheral T-cell lymphomas: ESMO Clinical Practice Guidelines for diagnosis, treatment and follow-up. *Ann Oncol*. 2015;26(suppl 5):v108–115.
52. Kanate AS, DiGilio A, Ahn KW, et al. Allogeneic haematopoietic cell transplantation for extranodal natural killer/T-cell lymphoma, nasal type: a CIBMTR analysis. *Br J Haematol*. 2018;182:916–920.
53. Tse E, Chan TS, Koh LP, et al. Allogeneic haematopoietic SCT for natural killer/T-cell lymphoma: a multicentre analysis from the Asia Lymphoma Study Group. *Bone Marrow Transplant*. 2014;49:902–906.
54. Kwong YL, Chan TSY, Tan D, et al. PD1 blockade with pembrolizumab is highly effective in relapsed or refractory NK/T-cell lymphoma failing l-asparaginase. *Blood*. 2017;129:2437–2442.
55. Li X, Cheng Y, Zhang M, et al. Activity of pembrolizumab in relapsed/refractory NK/T-cell lymphoma. *J Hematol Oncol*. 2018;11:15.
56. Chan TSY, Li J, Loong F, et al. PD1 blockade with low-dose nivolumab in NK/T cell lymphoma failing L-asparaginase: efficacy and safety. *Ann Hematol*. 2018;97:193–196.
57. Couronné L, Chaubard S, Bruneau J, et al. PD-1 blockade in a French series of 13 relapsed/refractory NK/T-cell lymphoma patients. *Hematol Oncol*. 2019;37:272–273.
58. Tao R, Fan L, Song Y, et al. Sintilimab for relapsed/refractory (R/R) extranodal NK/T cell lymphoma (ENKTL): a multicenter, single-arm, phase 2 trial (ORIENT-4). *J Clin Oncol*. 2019;37:389–390.
59. Hari P, Raj RV, Olteanu H. Targeting CD38 in refractory extranodal natural killer cell-T-cell lymphoma. *N Engl J Med*. 2016;375:1501–1502.
60. Aeppli S, Driessen C, Graf L, et al. Systemic treatment of a patient with relapsed and refractory extranodal NK/T-cell lymphoma (ENKL) and meningeosis leukemica with daratumumab. *Hematol Oncol*. 2018;36:713–714.
61. Huang H-q, Kim W-S, Yao M, et al. Daratumumab monotherapy for patients with relapsed or refractory (R/R) natural killer/T-cell lymphoma (NKTCL), nasal type: updated results from an open-label, single-arm, multicenter phase 2 study. *Blood*. 2019;134(suppl_1):1568.
62. Kim HK, Moon SM, Moon JH, et al. Complete remission in CD30-positive refractory extranodal NK/T-cell lymphoma with brentuximab vedotin. *Blood Res*. 2015;50:254–256.
63. Poon LM, Kwong YL. Complete remission of refractory disseminated NK/T cell lymphoma with brentuximab vedotin and bendamustine. *Ann Hematol*. 2016;95:847–849.
64. Prockop S, Reshef R, Tsai DE, et al. Long-term outcomes of subjects with Epstein-Barr virus-driven post-transplant lymphoproliferative disorder (EBV+PTLD) following solid organ (SOT) or allogeneic hematopoietic cell transplants (HCT) treated with tablecleucel on an expanded access program. *Blood*. 2019;134(suppl_1):4071.
65. Bollard CM, Gottschalk S, Torrano V, et al. Sustained complete responses in patients with lymphoma receiving autologous cytotoxic T lymphocytes targeting Epstein-Barr virus latent membrane proteins. *J Clin Oncol*. 2014;32:798–808.
66. Zheng M, Yu L, Hu J, et al. Efficacy of B7-H3-redirection BiTE and CAR-T immunotherapies against extranodal nasal natural killer/T cell lymphoma. *Transl Oncol*. 2020;13:100770.
67. Xiong J, Cui BW, Wang N, et al. Genomic and transcriptomic characterization of natural killer T cell lymphoma. *Cancer Cell*. 2020;37:403–419.e6.
68. Koo GC, Tan SY, Tang T, et al. Janus kinase 3-activating mutations identified in natural killer/T-cell lymphoma. *Cancer Discov*. 2012;2:591–597.
69. Küçük C, Jiang B, Hu X, et al. Activating mutations of STAT5B and STAT3 in lymphomas derived from $\gamma\delta$ -T or NK cells. *Nat Commun*. 2015;6:6025.
70. Lee S, Park HY, Kang SY, et al. Genetic alterations of JAK/STAT cascade and histone modification in extranodal NK/T-cell lymphoma nasal type. *Oncotarget*. 2015;6:17764–17776.