

## University of Groningen

### Long-term morbidity and follow-up after choledochal malformation surgery; A plea for a quality of life study

de Kleine, R. H.; ten Hove, A.; Hulscher, J. B. F.

*Published in:*  
Seminars in Pediatric Surgery

*DOI:*  
[10.1016/j.sempedsurg.2020.150942](https://doi.org/10.1016/j.sempedsurg.2020.150942)

**IMPORTANT NOTE: You are advised to consult the publisher's version (publisher's PDF) if you wish to cite from it. Please check the document version below.**

*Document Version*  
Publisher's PDF, also known as Version of record

*Publication date:*  
2020

[Link to publication in University of Groningen/UMCG research database](#)

*Citation for published version (APA):*

de Kleine, R. H., ten Hove, A., & Hulscher, J. B. F. (2020). Long-term morbidity and follow-up after choledochal malformation surgery; A plea for a quality of life study. *Seminars in Pediatric Surgery*, 29(4), Article 150942. <https://doi.org/10.1016/j.sempedsurg.2020.150942>

#### Copyright

Other than for strictly personal use, it is not permitted to download or to forward/distribute the text or part of it without the consent of the author(s) and/or copyright holder(s), unless the work is under an open content license (like Creative Commons).

The publication may also be distributed here under the terms of Article 25fa of the Dutch Copyright Act, indicated by the "Taverne" license. More information can be found on the University of Groningen website: <https://www.rug.nl/library/open-access/self-archiving-pure/taverne-amendment>.

#### Take-down policy

If you believe that this document breaches copyright please contact us providing details, and we will remove access to the work immediately and investigate your claim.

*Downloaded from the University of Groningen/UMCG research database (Pure): <http://www.rug.nl/research/portal>. For technical reasons the number of authors shown on this cover page is limited to 10 maximum.*



# Long-term morbidity and follow-up after choledochal malformation surgery; A plea for a quality of life study <sup>☆</sup>

R.H. de Kleine <sup>a,\*</sup>, A. ten Hove <sup>a,b</sup>, J.B.F. Hulscher <sup>b</sup>

<sup>a</sup> Department of Surgery, Division of Hepato-Pancreatico-Biliary Surgery and Liver Transplantation, University Medical Center Groningen, the Netherlands

<sup>b</sup> Department of Surgery, Division of Pediatric Surgery, University Medical Center Groningen, the Netherlands

## ARTICLE INFO

### Keywords:

Choledochal malformation  
Cholangitis  
Cholangiocarcinoma  
Quality of life  
Follow-up  
Review

## ABSTRACT

Much about the aetiology, pathophysiology, natural course and optimal treatment of choledochal malformation remains under debate. Surgeons continuously strive to optimize their roles in the management of choledochal malformation. Nowadays the standard treatment is complete cyst excision followed by Roux-en-Y hepaticojejunostomy, be it via a laparotomy, laparoscopy or robot-assisted procedure. Whatever surgical endeavor is undertaken, it will be a major operation, with significant morbidity. It is important to realize that especially in asymptomatic cases, this is considered prophylactic surgery, aimed at preventing symptoms but even more important the development of malignancy later in life. A clear overview of long-term outcomes is therefore necessary. This paper aims to review the long-term outcomes after surgery for choledochal malformation. We will focus on biliary complications such as cholangitis, the development of malignancy and quality of life. We will try and identify factors related to a worse outcome. Finally, we make a plea for a large scale study into quality and course of life after resection of a choledochal malformation, to help patients, parents and their treating physicians to come to a well-balanced decision regarding the treatment of a choledochal malformation.

© 2020 The Authors. Published by Elsevier Inc.

This is an open access article under the CC BY license. (<http://creativecommons.org/licenses/by/4.0/>)

## Introduction

Choledochal malformations (CM) are rare congenital diseases of the biliary tree. While the incidence in the Western part of the world hardly exceeds 1:40.000<sup>1</sup>, the incidence in the Far East can reach 1:5000.<sup>2</sup> Females are most often affected. Nowadays, some 25% of cases are detected antenatally.<sup>3</sup> They can be classified according to Todani as seen in Fig. 1, with types I and IV being most prevalent.<sup>4</sup> Type V, or Caroli's disease, is considered a separate entity and will therefore not be discussed in the present paper.

Most patients present with symptoms within the first decade of life. The classical clinical triad consists of jaundice, fever and a palpable mass in the right upper quadrant.<sup>5</sup> However, this occurs in less than one-fifth of cases.<sup>6</sup> Younger children tend to present with jaundice and acholic stools (beware biliary atresia), while older infants can present with jaundice and a palpable mass.<sup>7</sup> In older children (over 6 years of age) recurrent abdominal pain and fever often are the presenting symptoms.<sup>5</sup> The most feared long-term

complication is the development of an epithelial malignancy of the affected bile duct or gallbladder. This cholangiocarcinoma is the presenting diagnosis in ~3% adult cases in whom the CM has been asymptomatic until that point, while malignancy is present in a total of eleven percent of patients in whom a CM is resected later in life.<sup>8</sup> Remarkably, this rate of malignancy is similar between Eastern and Western countries.

Symptomatic CM requires rapid surgical intervention as soon as the infant's clinical condition permits. However, the majority of infants in whom CM is detected antenatally will be asymptomatic at birth, and many will remain asymptomatic.<sup>9</sup> Surgery for asymptomatic CM can therefore be considered as prophylactic surgery, in an attempt to prevent the development of symptoms as well as the development of malignancy. Aims of the operation are to excise all affected biliary tissue, to clean the remaining intrahepatic bile ducts of debris and to restore biliary-enteric continuity via a Roux Y hepaticojejunostomy (HJ), or even hepaticoduodenostomy (HD, see below). This reconstruction removes the stasis of bile and the reflux of pancreatic enzymes, which is considered essential in the prevention of carcinoma development. This procedure can be performed via a laparotomy, but laparoscopic and robot-assisted procedures are gaining popularity, especially in high-volume expert centers.

<sup>☆</sup> On behalf of the Center of Expertise for Choledochal Malformation, University Medical Center Groningen, Hanzeplein 1, 9700RB Groningen, The Netherlands.

\* Corresponding author.

E-mail address: [r.de.kleine@umcg.nl](mailto:r.de.kleine@umcg.nl) (R.H. de Kleine).

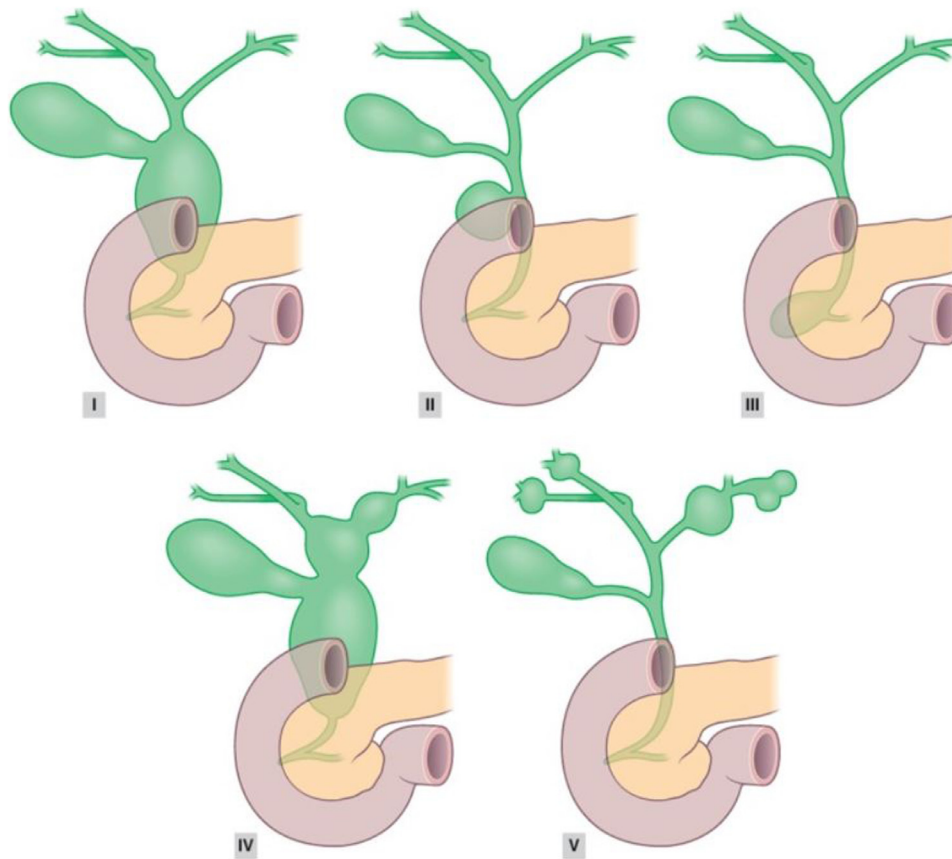


Fig. 1. Todani classification of choledochal malformations.<sup>4,8</sup>

While a safe procedure in experienced hands, with mortality rates approaching zero, the operation still carries significant morbidity, both on the short- and the long-term. Risks and benefits of such a major procedure have therefore to be weighted carefully. This paper aims to review the long-term morbidity after surgery for choledochal malformation. We will focus on long-term hepatobiliary morbidity and the development of malignancy, and secondly on long-term quality of life. We will make a plea for a large scale study into quality and course of life after resection of a choledochal malformation, to help patients, parents and their treating physicians to come to a well-balanced decision regarding the treatment of choledochal malformation.

### Cholangitis/pancreatitis

While cholangitis is less common after resection for CM than after biliary atresia, probably due to the greater bile flow in the former, it still forms an important complication. Recently, a large series from the Nordic countries demonstrated cholangitis/pancreatitis to occur in >20% of patients with a follow-up time over 5 years, again underscoring the need for careful follow-up of these patients.<sup>10</sup> The occurrence of cholangitis/pancreatitis was independent of short-term complications, but strongly associated with elevated ALT and bilirubin levels during follow-up. Age at surgery was not related to the occurrence of symptoms.

A survey from the Netherlands demonstrated a cholangitis incidence of 13% after a median follow-up of 13 years, with 65% of cases occurring within 2 years after surgery.<sup>1</sup> Conform the Nordic series, the occurrence of a short-term complication was not associated with long-term complications. However, unlike the Nordic series, younger age at surgery was related to the occurrence of long-term complications (OR 9.3, range 2.7–33). The laparoscopic

approach was also related to the occurrence of long term complications (OR 4.4, range 1.2–16.2).<sup>1</sup> We will come to this issue later.

When cholangitis is demonstrated, anastomotic stricture of the HJ should be looked for. Non-invasive imaging should be ultrasound in experienced hand followed by Magnetic Resonance Cholangio-Pancreaticography (MRCP) to ascertain the extent of the stenosis, cast formation, complete or partial occlusion of the intrahepatic bile ducts. The therapeutic regimen consists of balloon endoscopy (with limited work-space) to clean and inspect the HJ, percutaneous transhepatic cholangiography with drain placement and step-wise dilatation and finally surgical reintervention. When dilatation of the anastomosis is impossible, a new wide anastomosis should be created surgically to prevent recurrent cholangitis and subsequent liver fibrosis.

Pancreatitis before resection of the CM is most often due to the development of bile or protein plugs in the common channel. ERCP with removal of the plugs and sphincterotomy should be undertaken when a surgical approach is not warranted at time of presentation. Postoperative pancreatitis is extremely rare and evaluation should focus on malignancy, injury of the pancreatic main duct or incomplete excision of the cyst, leading to a protein plug re-formation in the distal remnant.<sup>11</sup>

### Stone formation and intrahepatic dilatation

Hepaticolithiasis after resection for CM is mainly related to dilatation of the intrahepatic bile ducts. These dilations can be pre-existent, with or without stenosis (Type IV Todani), but also develop after surgery due to anastomotic strictures. Koshinaga et al. suggested that intrahepatic cylindrical-type biliary dilatations might disappear after total cyst excision, while cystic biliary dilata-

tions tend to persist postoperatively and are frequently accompanied by ductal stenosis, which remains in the same portion of the biliary ducts.<sup>12</sup> Alternating dilatation and stenosis can therefore be observed as common morphological feature of cholangiograms in patients who develop postoperative cholangitis and stone formation.

The London group performed a study in children with type IV CM, measuring both choledochal pressure and biliary amylase content.<sup>13</sup> In their series the median intraoperative choledochal pressure was 17 (8–27) mm Hg (normal, <5 mm Hg), and intraoperative bile amylase was 3647 (range, 500–58,000) IU/L (normal, <100 IU/L). The preoperative diameter of the intrahepatic ducts correlated with choledochal pressure but not with biliary amylase. Most strikingly, at 1 year post surgery, the median intrahepatic duct (IHD) diameter had decreased to normal values in all cases. This remained stable for up to a 10-year follow-up. This suggests that IHD dilatation in type IV might be more related to sustained increased intrabiliary pressure rather than a pre-existing dilatation. Effective surgery invariably reduces IHD toward normal values. Similar findings were reported in a Finnish series, in which all intrahepatic dilatations in Type IV malformations had disappeared after six months.<sup>14</sup>

The above also emphasizes the need for a thorough debridement of the intra-hepatic bile ducts, and a meticulous wide hilar anastomosis. Care should also be taken to connect – when technically possible – also possible aberrant bile ducts into the Roux Y limb to avoid stasis.

## Cirrhosis

The reported incidence of liver fibrosis and/or cirrhosis associated with CM ranges from virtually non-existing to over 50%. Especially in the youngest infants, biliary obstruction can lead to cholestatic jaundice with subsequent liver failure and the distinction between CM and biliary atresia should be made with great caution. This formation of cirrhosis has been described in children with CM before the age of 6 months. Several authors have described the presence of fibrosis and even cirrhosis in pre-operative biopsies. For instance, Fumino described 15 cases in which preoperative liver biopsies were available.<sup>15</sup> In 8 patients fibrosis was present, in 3 of those advanced fibrosis or cirrhosis.<sup>15</sup> These pathological changes seemed to be related to the development of symptoms, early age/antenatal detection, Type IV malformations and the presence of a pancreatico-biliary maljunction.<sup>15–17</sup>

In our center liver biopsy is rarely performed, and certainly not routinely during follow-up. However, we are not aware of any case of progressive fibrosis when adequate bile flow has been established and in the absence of recurrent cholangitis. In the Nordic series, after a median follow-up of eight years, elevated ALT occurred in 5% of cases, with elevated bilirubin present in 7%.<sup>10</sup> In their series, biopsies were also not performed. This suggests that the presence of liver fibrosis or even cirrhosis might be clinically of little importance unless present prior to surgery. However, there is little solid data to confirm this statement.

There are case-reports describing histopathologic improvement in biliary cirrhosis after surgery for CM (in the presence of jaundice).<sup>18</sup> However, while several histological changes (e.g. inflammation and bile duct proliferation) can demonstrate resolution postoperatively, advanced fibrosis (F3, F4) generally does not resolve.<sup>16</sup> In the absence of obstruction, in the presence of F4 liver fibrosis, including liver failure, liver transplantation should be considered as a valid salvage procedure.

Given the discrepancies mentioned above, further studies are needed to investigate the correlation between liver fibrosis and clinical outcomes, as this might ultimately influence the timing of

surgery in asymptomatic neonates, especially those with type IV cysts.

## Type of surgery

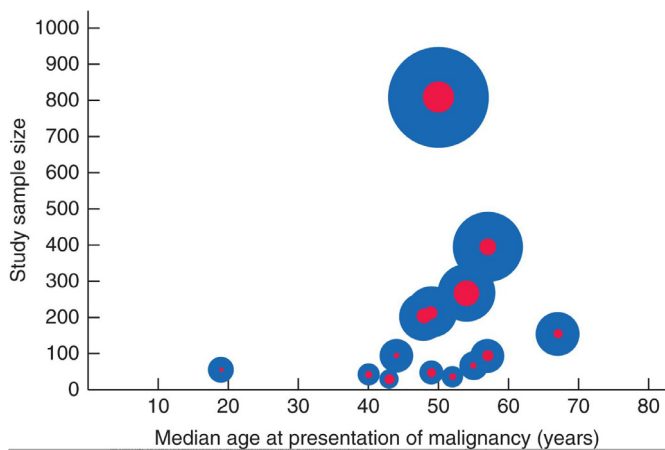
While resection for CM was usually performed via a laparotomy, recently laparoscopic and robot-assisted procedures have gained popularity. Especially in high volume (eastern) centers laparoscopic resection has become the standard of care, and can even be performed via a single port.<sup>19–21</sup> However, this is a technically demanding procedure, with a learning curve of over 30 procedures.<sup>22</sup> For most western centers, even in more centralized countries like the Netherlands, this would imply a learning curve spanning over five years. While short-term benefits seem to be present (shorter hospital stay, less complications, perhaps even shorter operating time in experienced hands), long-term results have yet to be awaited.<sup>22,23</sup>

In a study from The Netherlands, laparoscopic resection of CM was clearly related to a worse long-term outcome.<sup>1</sup> It has to be mentioned that these procedures were all performed by acclaimed laparoscopists, however with little experience to surgery for CM given the rarity of the disease. The odds ratio for a long-term complication after laparoscopic resection was 4.2 (1.2–15.5). Complications occurred in 5/12 (42%) after laparoscopic resection, versus in 11/78 (14%) after open resection ( $p < 0.01$ ). These complications consisted mainly of stenosis of the HJ (17%). Laparoscopy was also associated with an increased percentage of patients in whom a radiological or surgical reintervention was warranted (25% vs 6%,  $p = 0.07$ ). Due to the rarity of the disease, these disappointing results after laparoscopy have been attributed to the relatively long learning curve. In the Netherlands, this has led to the replacement of laparoscopic resection by a robotic assisted approach, in search of improvement of outcome.

Recently robotic assisted procedures have been developed which are used also in the West. Robotic surgery, with the magnification of the surgical view, the improved ergonomic surgical posture and the articulating instruments with movement scaling could be able to improve the long-term results of surgery by overcoming several of the technical issues associated with laparoscopic resection. In 2014 Alizai described an 81% success rate of robot-assisted resection.<sup>24</sup> Operation times are significantly longer in the beginning, but tend to decrease after some 10 cases.<sup>25</sup> Time to full enteral feeding is comparable, as is hospital stay. Importantly, a study in adults demonstrated significantly less bile leaks in the robotic group, confirming the perception that besides having ergonomic advantages for the surgeon, the robot, with its magnification of the surgical view and articulating instruments, is especially beneficial for the meticulous completion of the hepaticojejunostomy.<sup>26</sup> Whether this indeed will lead to a decrease in long-term complications such as anastomotic stenosis remains to be seen.

A minority of surgeons prefer HD over HJ. Apart from the technical ease of a single anastomosis, the operation has been considered have several other advantages such as being more physiologic and allows postoperative endoscopic access to the anastomosis if a stricture or stone occurs. In experienced hands short-term outcomes are good, with a low complication rate.<sup>27,28</sup> Operative time might also be shorter than with a hepaticojejunostomy. However, most surgeons prefer Roux-en-Y hepaticojejunostomy because the high incidence of bilious gastritis secondary to duodenogastric reflux after hepaticoduodenostomy. Via the hepaticoduodenostomy duodenal contents, including pancreatic enzymes might also reflux into the intrahepatic bile ducts. This might lead to persistent injury of the cholangiocytes, causing bile duct carcinoma. In a recent meta-analysis, Narayanan confirmed this higher incidence of reflux/gastritis after HD, which was absent after HJ. (27) In the





**Fig. 2.** Median age of patients with choledochal malformation at presentation of malignancy in each study. The size of each blue circle indicates the study sample size, and that of each red circle the incidence of malignancy, relative to that in the other studies.<sup>8</sup>

opinion of the authors, HD should therefore be reserved for patient with insufficient lesser intestines for a save entero-enterostomy, at least until long term results become available.

### Development of malignancy

Development of malignancy is probably the most feared long-term complication of CM. Probably following a hyperplasia – dysplasia – neoplasia sequence, the toxic mixture of refluxing pancreatic and bile secretions in combination with increased pressure in a congenital malformed duct can lead to persistent inflammation and subsequent (pre-)malignant transformation.<sup>29,30</sup> Exactly how this process is driven is as yet unknown but resection of the CM does have a protective yield by separating pancreatic and bile flow, making surgery the cornerstone in treatment. It is important to realize that the youngest patient known with a CM associated malignancy was a 3-year-old boy, who presented with an invasive cholangiocarcinoma in a type 1 CM proving enhanced carcinogenic pathways.<sup>31</sup> In contrast, in a national Dutch cohort including 91 children up to the age of 18 years, no malignancy was found.<sup>1</sup>

Recently we performed a review regarding the development of malignancy in CM, including the literature from the past 20 years.<sup>8</sup> We could include eighteen observational studies, totaling 2904 patients. The majority of patients (90%) had Types I or IV, 2% had Types II or III, and 7% had Type V. Overall, 10.7% of patients developed a malignancy. These could be subdivided into malignant prevalence in the CM itself (7.3%) and malignant transformation after resection (3.4%). Patients with Types I and IV formed > 90% of cases of both malignant prevalence as well as transformation. Patients who underwent cystic drainage had an increased risk of developing biliary malignancy in comparison to those who underwent complete cyst excision, with an odds ratio of 3.9 (95% confidence interval, 2.4–6.5), making this intervention obsolete. Median age at time of detection of malignancy was 49 years, which is 20 years below the age at which cholangiocarcinoma usually occurs. This is again indicative of enhanced carcinogenesis. There was one 12-year-old child with a malignancy. The number of patients per age decade is shown in Fig. 2.

Overall, CM patients have an eleven percent risk of developing malignancy. After surgery, this risk is reduced to 0.3%.<sup>8</sup> The risk of malignancy following cystic drainage surgery is up to four times higher in comparison to complete cyst excision. This makes a case for redo surgery aiming to resect the malformation in pa-

tients who previously underwent a drainage procedure only. The matter of follow-up, especially for patients with CM Types I or IV with increased risk of malignant transformation remains unclear. Rate of detection of CCA in patients with a CM on preoperative MR-imaging remains low at best with the majority of CCA or gall-bladder carcinoma found “by chance” in the resection specimen, already after surgery. Prognosis of patients with CCA detected on preoperative imaging is dismal with very low chance of long-term survival. The inability to detect CCA on imaging and the subsequent lack of therapeutic gain makes follow up of postoperative patient in light of other malignancies of less value.

At this moment there is no measurable factor clearly associated with the development of malignancy. A recent paper from the London group investigated biliary CA19-9 levels and found them to be grossly raised.<sup>30</sup> In the same paper the authors described increased epithelial proliferation in 19% of cases. However, there was no clinical correlation whatsoever. On this basis we continue to suggest long-term surveillance and follow-up for all patients until better markers of malignant predisposition become available.

To summarize, while there is a predilection for malignancy in patients with CM, the reason for malignant degeneration and the true incidence remain unclear. Also, it remains to be seen how effective imaging modalities are for the early detection of biliary tract malignancy. In the absence of clear benefit of follow-up for oncological reasons, follow-up should be aimed at the early detection of bile duct stenosis to prevent progression to advanced fibrosis.

### Quality of life

Over the last decades, the emphasis of care for children with many congenital anomalies has shifted from survival to a more holistic care model, including long-term functional outcomes and quality of life (QoL). For several paediatric surgical diseases, e.g. anorectal malformations, oesophageal atresia and biliary atresia, long-term outcome regarding quality of life emerge in literature. However, data regarding long-term quality of life after resection for a CM are scant at best.

One of the few groups addressing this issue is the Kagoshima paediatric surgery group. In a cohort of 35 young adults (median age 29, range 18–42, 12 males and 23 females) Baba et al. described health related quality of life using the Japanese version of the internationally validated SF-36v2.<sup>32</sup> This validated questionnaire measures eight health domains, which can be used to calculate three summary scores: physical, mental and role-social. Post-operative complications occurred in 12 patients (34%), mainly consisting of adhesive ileus (17%). Overall, HRQOL component summary scores were within the normal range in the majority of patients, especially in those without post-operative complications. However, general health was perceived lower in patients after complications. The mental component score was also significantly lower in patients who had experienced complications. Of note was the finding that the physical component score showed a significant negative correlation with age in patients without a complication, while the mental and role-social component scores remained the same during ageing.

While a small series with a relatively low response-rate, this study again demonstrates the need for paediatric surgeons to continuously be aware of long-term outcomes regarding quality of life, especially after ‘prophylactic’ surgery. While we all tend to focus on novel surgical strategies, including laparoscopic and robotic-assisted resection for CM, we should always keep in mind the need for assessing long-term outcomes. For CM this clearly is a knowledge gap that needs to be assessed. The authors would also urge the field to develop a formal patients reported outcome measure (PROM) for CM, further including the patient perspective with spe-

cial interest in the outcome of patients with HJ stenosis or recurrent stone formation.

### What do we do and what would we like to do

Our surgical protocol includes – besides resection of the extrahepatic bile duct with Roux-en-Y HJ – a thorough cleaning of the common channel as well as the proximal bile ducts, preferably using the intra-operative cholangioscope. We have recently started a robotic approach for asymptomatic children who can safely be delayed until approximately two years of age. We have chosen this time-point with regards to the working space in the abdominal cavity.<sup>24</sup> Possible robotic procedures can also be performed in smaller children, but it remains unclear whether this is necessary in asymptomatic cases. Of course, obtaining a good preoperative visualization of the PBM anatomy, to prevent a too long remnant of the distal CBD as well as injury to the pancreatic duct, is very important.

Follow-up consists of outpatient visits, with blood tests, including CA19.9 and liver ultrasound every six months. After two years we perform this once yearly. Given the chance of stenosis of the HJ and the risk for malignancy, currently we perform life-long follow up at a 2 year interval. When intrahepatic dilatation persists, or other complications occur, follow-up is kept at one-year intervals. Any deterioration, clinical or laboratory wise leads to imaging with ultrasound, often followed by MRCP.

Given the rarity of the disease and the clear knowledge gap regarding long-term outcomes, we should start studies investigating long-term outcomes within the framework of international networks, such as the European Reference Networks for Rare Diseases. Only via such cooperation, including international registries and when possible biobanking, we will be able to outline the clinical course of disease more in detail, and obtain patient reported outcome measures to guide both patients and physicians in the treatment of this disease. Prospective database registration with preoperative and postoperative consecutive quality of life questionnaires should provide more insight into the best therapeutic regimen.

### Conclusion

Due to the rarity of the disease, there are few large series, even less comparative studies. In the West there will always be small numbers. Regarding surgery, the prevention of early complications is important, whether surgery is performed open, laparoscopically or robotically. One should aim for resection of all affected tissue, clearance of debris, and reconstruction with Roux-en-Y HJ with wide hilar anastomosis. In doing so, the bigger picture should be kept in mind. And the bigger picture is that surgery for CM is often prophylactic surgery in asymptomatic children, who have a life before them to potentially develop long-term complications. We should combine our efforts to further gain insight into the long-term sequelae, identifying factors related to a worse outcome and thereby identifying areas for improvement. We should do so in international cooperation, with the patient not only as patient but also as partner.

### References

- van den Eijnden MHA, de Kleine RHJ, de Blaauw I, et al. Choledochal malformation in children: lessons learned from a Dutch national study. *World J Surg.* 2017;41(10):2631–2637. doi:10.1007/s00268-017-4064-x.
- Dhupar R, Gulack B, Geller DA, Marsh JW, Gamblin TC. The changing presentation of choledochal cyst disease : an incidental diagnosis. *HPB Surg.* 2009;2009:1–5.
- Dewburry K, Aluwihare A, Birch J, Freeman N. Prenatal ultrasound demonstration of a choledochal cyst. *Br Inst Radiol.* 1980;53:906–907.
- Todani T, Watanabe Y, Narusue M, Tabuchi K, Okajima K. Congenital bile duct cysts: classification, operative procedures, and review of thirty-seven cases including cancer arising from choledochal cyst. *Am J Surg.* 1977;134(2):263–269.
- Stringer MD, Dhawan A, Davenport M, Mowat AP, Howard ER. Choledochal cysts: lessons from a 20 year experience. *Arch Dis Child.* 1995;73:528–531.
- Singham J, Yoshida EM, Scudamore CH. Choledochal cysts Part 2 of 3: diagnosis. *Can J Surg.* 2009;52(6):506–511.
- Sinham J, Yoshida EM, Scudamore CH. Choledochal cysts Part 3 of 3: management. *Can J Surg.* 2010;53(1):51–56.
- ten Hove A, de Meijer VE, Hulscher JBF, de Kleine RHJ. Meta-analysis of risk of developing malignancy in congenital choledochal malformation. *Br J Surg.* 2018;105(5):482–490. doi:10.1002/bjs.10798.
- van den Eijnden MHA, de Kleine RH, de Blaauw I, et al. The timing of surgery of antenatally diagnosed choledochal malformations: a descriptive analysis of a 26-year nationwide cohort. *J Pediatr Surg.* 2017;52(7):1156–1160. Available from: <http://dx.doi.org/10.1016/j.jpedsurg.2017.03.003>.
- Hukkinen M, Björnland K, Gatzinsky V, et al. Management strategies and treatment results of pediatric choledochal malformations in the Nordic countries. *HPB (Oxford).* 2020;22(1):161–168. doi:10.1016/j.hpb.2019.07.001.
- Chiba K, Kamisawa T, Egawa N. Relapsing acute pancreatitis caused by protein plugs in a remnant choledochal cyst. *J Hepatobiliary Pancreat Sci.* 2010;17(5):729–730.
- Koshinaga T, Inoue M, Ohashi K, et al. Persistent biliary dilatation and stenosis in postoperative congenital choledochal cyst. *J Hepatobiliary Pancreat Sci.* 2011;18(1):47–52.
- Hill R, Parsons C, Farrant P, Sellars M, Davenport M. Intrahepatic duct dilatation in type 4 choledochal malformation: pressure-related, postoperative resolution. *J Pediatr Surg.* 2011;46(2):299–303.
- Hukkinen M, Koivusalo A, Lindahl H, Rintala R, Pakarinen MP. Increasing occurrence of choledochal malformations in children: a single-center 37-year experience from Finland. *Scand J Gastroenterol.* 2014;49(10):1255–1260.
- Fumino S, Higuchi K, Aoi S, Furukawa T, Kimura O, Tajiri T. Clinical analysis of liver fibrosis in choledochal cyst. *Pediatr Surg Int.* 2013;29(11):1097–1102.
- Sugandhi N, Agarwala S, Bhatnagar V, Singh MK, Sharma R. Liver histology in choledochal cyst-pathological changes and response to surgery: the overlooked aspect? *Pediatr Surg Int.* 2014;30(2):205–211.
- Okada T, Honda S, Miyagi H, Kubota KC, Cho K, Taketomi A. Liver fibrosis in prenatally diagnosed choledochal cysts. *J Pediatr Gastroenterol Nutr.* 2013;57(2).
- Ishimaru T, Kitano Y, Uchida H, et al. Histopathologic improvement in biliary cirrhosis after definitive surgery for choledochal cyst. *J Pediatr Surg.* 2010;45(5).
- Liem NT, Pham HD, Dung LA. Early and intermediate outcomes of laparoscopic surgery for choledochal cysts with 400 patients. *J Laparoendosc Adv Surg Tech.* 2012;22(6):599–603.
- Diao M, Li L, Zhang J, Cheng W. A shorter loop in Roux-Y hepatojejunostomy reconstruction for choledochal cysts is equally effective : preliminary results of a prospective randomized study. *J Pediatr Surg.* 2010;45(4):845–847. Available from: <http://dx.doi.org/10.1016/j.jpedsurg.2009.12.022>.
- Tang Y, Li F, He G. Comparison of single-incision and conventional laparoscopic cyst excision and Roux-en-Y hepatojejunostomy for children with choledochal cysts. *Indian J Surg.* 2016;78(4):259–264.
- Wen Z, Liang H, Liang J, Liang Q, Xia H. Evaluation of the learning curve of laparoscopic choledochal cyst excision and Roux-en-Y hepatojejunostomy in children: CUSUM analysis of a single surgeon's experience. *Surg Endosc.* 2017;31(2):778–787.
- Zhen C, Xia Z, Long L, et al. Laparoscopic excision versus open excision for the treatment of choledochal cysts: a systematic review and meta-analysis. *Int Surg.* 2015;100(1):115–122.
- Alizai NK, Dawrant MJ, Najmaldin AS. Robot-assisted resection of choledochal cysts and hepatojejunostomy in children. *Pediatr Surg Int.* 2014;30(3):291–294. doi:10.1007/s00383-013-3459-5.
- Chang EY, Hong YJ, Chang HK, Oh JT, Han SJ. Lessons and tips from the experience of pediatric robotic choledochal cyst resection. *J Laparoendosc Adv Surg Tech.* 2012;22(6):609–614.
- Han JH, Lee JH, Hwang DW, et al. Robot resection of a choledochal cyst with Roux-en-y hepatojejunostomy in adults : initial experiences with 22 cases and a comparison with laparoscopic approaches. *Ann hepatobiliary Pancreat Surg.* 2018;22:359–366.
- Narayanan SK, Chen Y, Narasimhan KL, Cohen RC. Hepaticoduodenostomy versus hepatojejunostomy after resection of choledochal cyst: a systematic review and meta-analysis. *J Pediatr Surg.* 2013;48(11):2336–2342.
- Yeung F, Fung ACH, Chung PHY, Wong KKY. Short-term and long-term outcomes after Roux-en-Y hepatojejunostomy versus hepaticoduodenostomy following laparoscopic excision of choledochal cyst in children. *Surg Endosc.* 2020;34:2172–2177. doi:10.1007/s00464-019-07004-5.
- Komi N, Tamura T, Tsuge S, Miyoshi Y, Udaka H, Takehara H. Relation of patient age to premalignant alterations in choledochal cyst epithelium: histochemical and immunohistochemical studies. *J Pediatr Surg.* 1986;21(5):430–433.
- La Pergola E, Zen Y, Davenport M. Congenital choledochal malformation: search for a marker of epithelial instability. *J Pediatr Surg.* 2016;51(9):1445–1449.
- Saikusa N, Naito S, Iinuma Y, Ohtani T, Yokoyama N, Nitta K. Invasive cholangiocarcinoma identified in congenital biliary dilatation in a 3-year-old boy. *J Pediatr Surg.* 2009;44(11):2202–2205.
- Baba T, Mukai M, Masuya R, et al. The long-term health-related quality of life in patients operated for choledochal cyst. *Pediatr Surg Int.* 2019;35(5):539–546.