

University of Groningen

## Revertant cell therapy for epidermolysis bullosa

Gostynski, Antoni

**IMPORTANT NOTE: You are advised to consult the publisher's version (publisher's PDF) if you wish to cite from it. Please check the document version below.**

*Document Version*

Publisher's PDF, also known as Version of record

*Publication date:*  
2014

[Link to publication in University of Groningen/UMCG research database](#)

*Citation for published version (APA):*

Gostynski, A. (2014). *Revertant cell therapy for epidermolysis bullosa*. [Thesis fully internal (DIV), University of Groningen]. [S.n.].

**Copyright**

Other than for strictly personal use, it is not permitted to download or to forward/distribute the text or part of it without the consent of the author(s) and/or copyright holder(s), unless the work is under an open content license (like Creative Commons).

The publication may also be distributed here under the terms of Article 25fa of the Dutch Copyright Act, indicated by the "Taverne" license. More information can be found on the University of Groningen website: <https://www.rug.nl/library/open-access/self-archiving-pure/taverne-amendment>.

**Take-down policy**

If you believe that this document breaches copyright please contact us providing details, and we will remove access to the work immediately and investigate your claim.

*Downloaded from the University of Groningen/UMCG research database (Pure): <http://www.rug.nl/research/portal>. For technical reasons the number of authors shown on this cover page is limited to 10 maximum.*



## **ADHESIVE STRIPPING TO REMOVE EPIDERMIS IN JUNCTIONAL EPIDERMOLYSIS BULLOSA FOR REVERTANT CELL THERAPY**

A. Gostynski<sup>1</sup>, F.C.L. Deviaene<sup>1,2</sup>, A.M.G. Pasmooij<sup>1</sup>, H.H. Pas<sup>1</sup>, M.F. Jonkman<sup>1</sup>

1 Center for Blistering Diseases, Department of Dermatology, University of Groningen, University Medical Center Groningen, Groningen, The Netherlands

2 Department of Dermatology, Free University, Brussels, Belgium.

**2**

47

Published in British Journal of Dermatology 2009 Aug;161(2):444-7

## SUMMARY

*Background.* Replacing mutant skin in epidermolysis bullosa (EB) by epithelial sheets of transduced autologous keratinocytes is the essential surgical step of ex vivo gene therapy. The same applies for *revertant cell therapy* in which epithelial sheets of revertant autologous keratinocytes are used. Revertant cells can be found in patches of normal skin in patients with junctional epidermolysis bullosa (JEB) due to revertant mosaicism caused by *in vivo* reversions.

*Objectives.* To develop a technique of adhesive tape stripping as a method for epidermis removal to prepare the acceptor site for revertant cell therapy in a patient with revertant mosaic JEB.

*Methods.* We performed revertant cell therapy on a patient with mosaic type XVII collagen-deficient non-Herlitz JEB. Skin biopsies were taken from revertant skin on the wrist. Graft production took place on a 3T3-J2 feeder layer resulting in two 6x7 cm grafts. An innovative method that uses the pathological plane of least resistance of JEB skin was developed to prepare the acceptor site. A polyacrylate adhesive plaster was placed on the skin and then pulled off with the epidermis.

*Results.* The epidermis was easily removed with the plaster. The skin separated at the level of the lamina lucida, leaving a bloodless wound bed of naked lamina densa. Transplantation was successful; the acceptor site healed without scarring. However, blistering could be provoked. The functional repair was not achieved due to the low percentage of revertant cells in the graft.

*Conclusions.* We conclude that adhesive stripping is a simple, effective and almost painless procedure for removing epidermis for ex vivo cell therapy in EB.

Epidermolysis bullosa (EB) is a group of hereditary genetic blistering diseases of skin and mucosae. Junctional EB (JEB) is caused by mutations in the genes for type XVII collagen, laminin-332 or integrin  $\alpha 6\beta 4$  which are crucial for keratinocyte adhesion to the basement membrane. Some patients with JEB notice normal, nonfragile skin patches. This phenomenon is called revertant mosaicism.<sup>1</sup> It is caused by naturally occurring somatic *in vivo* reversions that restore protein function and provide restoration of the keratinocyte adhesive function. Skin that contains sufficient revertant keratinocytes displays a wild-type phenotype.<sup>1</sup>

Most studies of cell therapy for EB focus on restoring function by adding correct genes or repairing defective genes of mutant stem cells, and growing these into transplantable epidermal sheets.<sup>2</sup> In revertant cell therapy there is no need for corrective gene manipulation. Epidermal sheets for transplantation are produced from autologous revertant keratinocytes that are present in the healthy skin patches. An effective transplant technique is important for revertant cell therapy to avoid scarring and patients' discomfort.

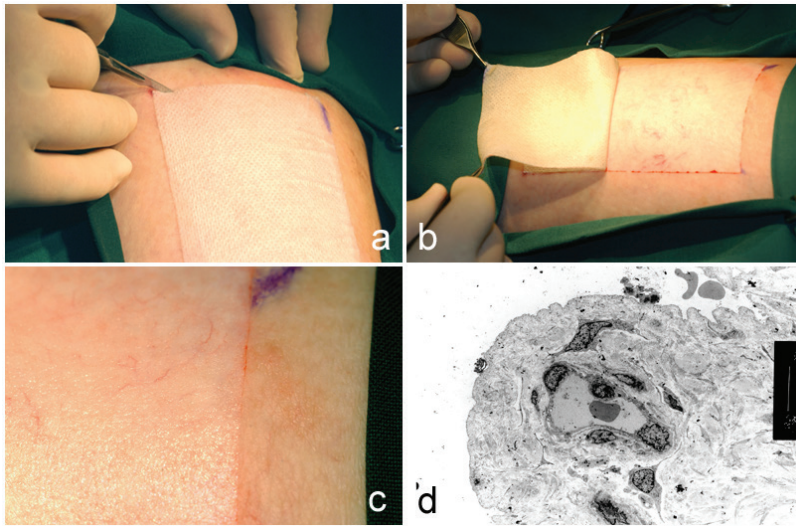
Here we report on the innovative technique of adhesive tape stripping as a method for epidermis removal to prepare the acceptor site for revertant cell therapy in a patient with revertant mosaic JEB.<sup>1,3</sup>

### Patient and methods

The patient had JEB of the generalized non-Herlitz type due to compound heterozygosity of *COL17A1*: c.1706delA and c.3781C>T,p.R1226X mutations in the gene for type XVII collagen. About 4% of her total body surface was revertant due to at least two different *in vivo* reversions: a gene conversion that corrected the 1706delA germline mutation (arm, forearm, hand) and a second-site mutation 3782G>C (ankle) that prevented the premature ending of translation by the R1226X germline mutation.

The left wrist was selected for the donor site, and the upper right leg was chosen for the acceptor site. Keratinocytes were harvested from a 6-mm punch biopsy by enzymatic digestion and cultured on a feeder layer of irradiated mouse fibroblasts (3T3-J2 cells). The cells grew slowly and it took five weeks to grow two epidermal sheets of 6x7 cm each. The sheets were clipped to synthetic gauze to scaffold the vulnerable epithelium.

To prepare the acceptor site we used a method based on the pathology of adhesion between the epidermis and dermis in patients affected by JEB. In the skin of patients with type XVII collagen deficiency the loss of adhesion is present at the level of the lamina lucida of the epidermal basement membrane. This enables "en bloc" removal of interfollicular epidermis with just an adhesive plaster. The plaster is placed on the skin and then, when removed, takes off the epidermis leaving naked lamina densa.



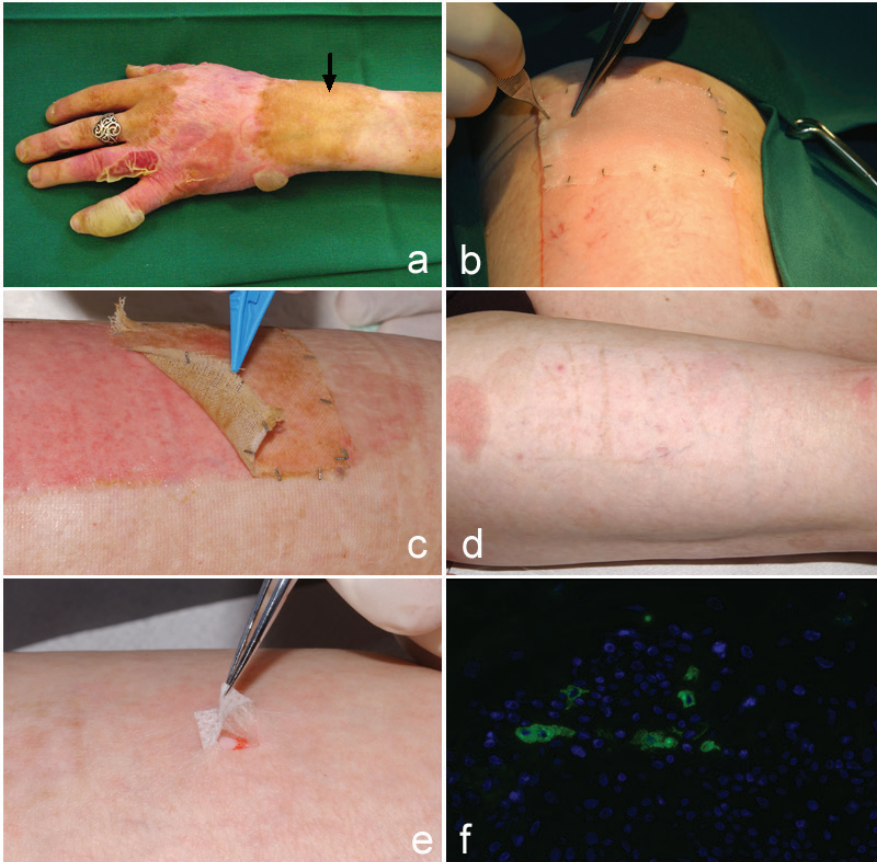**Figure 1.** Preparation of the acceptor site on the upper leg. (a) Incisions are made around the adhesive plaster; (b) clear-cut peeling off of epidermis by adhesive plaster; (c) the bloodless wound bed is composed of naked lamina densa; (d) electron microscopy reveals complete removal of epidermis with the lamina densa on top of the wound surface.

## Transplantation

The patient was hospitalized one day prior to transplantation. On the evening before the procedure, a 12x7 cm area was outlined on the right upper leg, degreased with ether, and a polyacrylate adhesive plaster (Fixomull stretch; BSN Medical Hamburg, Germany) was placed on the skin. The transplantation procedure took place under sterile conditions in the operating theatre. Paracetamol (500 mg) was given preoperatively. No local or systemic anaesthesia was used. During the transplantation ultrasuperficial incisions (<0,1 mm) were made around the edge of the plaster with a scalpel to direct the line of perforation of the epidermis. The plaster together with the attached epidermis was easily peeled off. A clean, nonbleeding erosion developed induced by a split at the level of the lamina lucida as demonstrated by electron microscopy of a skin biopsy, disclosing the naked lamina densa as the wound surface (Figure 1 a-d). The acceptor site was kept moist with warm saline gauzes and immediately before placing the graft it was carefully padded with dry gauze. The grafts were placed on the wound bed with the basal layer facing the wound.

As the first contact layer, polyurethane foam coated with silicon (Mepilex transfer, Mölnlycke Health Care, Breda, the Netherlands) was used, covered with nonadherent absorbent compresses (Melolin, Smith & Nephew). That was then fixed by a wrap of nonadhesive elastic gauze bandage (Elastomull Haft, Beiersdorf) and tubular stretch bandage (Tubifast Garment, Medeco). The patient was immobilized for three days and given nadroparin for thrombosis prophylaxis.

[Figure 2 a-d]



**Figure 2.** (a) A revertant skin patch before harvesting with a punch biopsy (arrow, future donor site). (b) Epithelial grafts are placed on the acceptor site. Note the metal clips at the edge that secured the graft to the gauze carrier. (c) Removal of the gauze carrier at day 7. (d) The acceptor site had healed without scarring at 4 months. (e) Positive adhesive tape test of the acceptor site reveals weak epidermolysis bullosa skin. (f) The graft stained for type XVII collagen with 3% positive keratinocytes.

## Results

The whole procedure was well tolerated by the patient. During the next five days dressings were left intact and no leakage of wound exudates was observed. Five days after transplantation all dressings, except the gauze scaffold were removed. The graft looked well attached to the acceptor site; the wound was dry. Seven days after the procedure all dressings, including the gauze, were removed. The wound was erythematous but dry and had re-epithelialized. No blisters were observed. Four months later the acceptor site had healed without scarring and with minimal

linear pigmentation. The adhesive pull test however provoked a skin loosening [Figure 2e]. Retrospective staining with monoclonal 1A8C (a kind gift from Dr K. Owaribe, Nagoya, Japan) for type XVII collagen of p2 cells side cultured on the cover slips showed that more than 30% of the cells were revertant. However the graft as the final product unexpectedly contained a low percentage of revertant cells (<3%) (Figure 2f). This explains why no functional repair was obtained, although the transplantation procedure was a surgical success.

## Discussion

In our experiment we showed that the removal of epidermis with an adhesive plaster in patients with JEB is feasible. Our method was well tolerated, simple to perform and, very importantly, causes little pain and therefore was not traumatic for the patient. After transplantation we have observed a fast and physiological healing process without any signs of graft rejection or scarring. That is why we suggest that the adhesive stripping could also be used for *ex-vivo* skin stem cell gene therapy in JEB which also requires replacement of large areas of epidermis.

2

52

The correction of the phenotype was unsuccessful because the graft consisted of less than 3 % revertant cells. There is no clear explanation why the graft appeared to be negative. The biopsy was taken from a patch of healthy skin, where at least 30 % of the cells were revertant. We have as yet no answer to this problem and any kind of discussion would be highly speculative. There is a possibility that during the wound healing process resident mutant epidermal stem cells colonize the grafted bed from the edge of the wound or from skin appendages. Theoretically it could be a danger for the revertant graft. However we have no reason to believe that these mutant cells would outcompete the grafted revertant cells. In previously described cases of transplantation of epidermal grafts,<sup>2,4</sup> graft survival was demonstrated. The method of acceptor site preparation by diathermy which left dermal papillae intact, was not deep enough to remove hair follicles, but was sufficient for long term graft survival in the first *ex-vivo* gene therapy performed in the skin.<sup>2</sup> We believe that the revertant cell therapy would be an elegant way to study the survival of autologous keratinocytes after epithelial sheet grafting.

## Conclusion

We conclude that adhesive tape stripping is a simple, effective and almost painless method for acceptor site preparation in revertant cell therapy. The method might also work for grafting of genetically modified epithelial sheets in EB. The next hurdle in revertant cell therapy in EB is to improve graft production such that adequate percentages of revertant stem cells are present, to secure functional repair of the skin.

## REFERENCES

- 1 Jonkman MF, Scheffer H, Stulp R et al. Revertant mosaicism in epidermolysis bullosa caused by mitotic gene conversion. *Cell* 1997; 88: 543-51.
- 2 Mavilio F, Pellegrini G, Ferrari S et al. Correction of junctional epidermolysis bullosa by transplantation of genetically modified epidermal stem cells. *Nature medicine* 2006; 12: 1397-402.
- 3 Pasmooij AM, Pas HH, Deviaene FC et al. Multiple correcting COL17A1 mutations in patients with revertant mosaicism of epidermolysis bullosa. *American journal of human genetics* 2005; 77: 727-40.
- 4 Kopp J, Horch RE, Stachel KD et al. Hematopoietic stem cell transplantation and subsequent 80% skin exchange by grafts from the same donor in a patient with Herlitz disease. *Transplantation* 2005; 79: 255-6.



