

## University of Groningen

### Young eyes for elderly people

Gaalen, Kim Warda van

**IMPORTANT NOTE: You are advised to consult the publisher's version (publisher's PDF) if you wish to cite from it. Please check the document version below.**

*Document Version*

Publisher's PDF, also known as Version of record

*Publication date:*  
2009

[Link to publication in University of Groningen/UMCG research database](#)

*Citation for published version (APA):*

Gaalen, K. W. V. (2009). *Young eyes for elderly people: a clinical comparison of spherical and aspheric intraocular lenses*. s.n.

**Copyright**

Other than for strictly personal use, it is not permitted to download or to forward/distribute the text or part of it without the consent of the author(s) and/or copyright holder(s), unless the work is under an open content license (like Creative Commons).

The publication may also be distributed here under the terms of Article 25fa of the Dutch Copyright Act, indicated by the "Taverne" license. More information can be found on the University of Groningen website: <https://www.rug.nl/library/open-access/self-archiving-pure/taverne-amendment>.

**Take-down policy**

If you believe that this document breaches copyright please contact us providing details, and we will remove access to the work immediately and investigate your claim.

*Downloaded from the University of Groningen/UMCG research database (Pure): <http://www.rug.nl/research/portal>. For technical reasons the number of authors shown on this cover page is limited to 10 maximum.*

---

# **Straylight measurements in pseudophakic eyes with natural and dilated pupils**

## **A one-year follow-up**

Kim W. van Gaalen<sup>1</sup>, MSc, Steven A. Koopmans<sup>2</sup>, MD, PhD, Johanna M.  
M. Hooymans,<sup>2</sup> MD, PhD, Nomdo M. Jansonius<sup>1,2</sup>, MD, PhD, and  
Aart C. Kooijman<sup>1</sup>, PhD

<sup>1</sup> Laboratory of Experimental Ophthalmology, University Medical Center Groningen,  
University of Groningen, Groningen, The Netherlands

<sup>2</sup> Department of Ophthalmology, University Medical Center Groningen, University of  
Groningen, Groningen, The Netherlands

## Abstract

### *Purpose*

To compare the amounts of straylight in natural and dilated pupils in pseudophakic eyes, six weeks and one year after cataract extraction.

### *Setting*

Laboratory of Experimental Ophthalmology, University Medical Center Groningen, University of Groningen, Groningen, The Netherlands.

### *Methods*

Patients with bilateral age-related cataract who had undergone cataract surgery and had received either an aspheric Tecnis ZA9003 intraocular lens (IOL) or a spherical Sensar AR40e IOL participated. Straylight measurements were performed six weeks after surgery (with natural pupils) and one year after surgery (with natural and dilated pupils) on a randomly chosen eye, using the C-Quant straylight meter. Retroillumination photographs of dilated pupils were taken to document posterior capsule opacification.

### *Results*

Twenty-two patients were included in the analysis. A significant decrease in straylight was observed between measurements performed six weeks (mean log(s) = 1.44) and 1 year (1.30;  $P = .012$ ) after surgery when measured with a natural pupil. The straylight parameter was greater after dilation (mean log(s) = 1.48) than it was with a natural pupil (1.29;  $P = .012$ ) after one year. This difference appeared to be greater when more of the anterior capsule was visible in the pupillary area surface ( $P = .031$ ).

### *Conclusions*

Straylight decreases significantly in the first year after cataract surgery. Furthermore, straylight increases with increasing pupil size, associated with a capsulorhexis size smaller than the pupil size. It would seem reasonable to create a capsulorhexis as large as possible in order to prevent straylight under especially low-luminance conditions, when the pupil is large.

## **Introduction**

Due to imperfections of the eye optics, part of the light that enters the eye is scattered in the eye media rather than focused on the retina. This phenomenon is called straylight and decreases contrast of the retinal image.<sup>1,2</sup> Subjectively, straylight results in difficulties in the perception of low contrast objects, and in glare and halo-like phenomena, especially in the presence of bright light sources such as car headlights, streetlights and low sun.

Ocular straylight, induced by the cornea, the sclera, the lens, the vitreous and the retina, is present in all eyes, but increases with age mainly due to changes in the structure of the crystalline lens.<sup>3-7</sup> Hence, as to be expected, glare is a well-known visual symptom of cataract.<sup>2</sup> De Waard et al. measured straylight in patients with age-related cataract and found an increase in straylight for cortical, nuclear and subcapsular cataract.<sup>8</sup> By replacing the opacified crystalline lens with an artificial, optically clear intraocular lens (IOL), straylight decreases significantly,<sup>9</sup> and the optical performance of the eye is improved. Van den Berg et al. measured straylight in healthy eyes of different ages, as well as in eyes with cataract and in pseudophakic eyes.<sup>9</sup> A significant decrease in straylight was found after cataract extraction, and the majority of the pseudophakic eyes showed straylight values comparable to healthy non-cataractous eyes.<sup>9</sup>

Although the main source of ocular straylight is removed by replacing a cataractous lens with an IOL, a large number of pseudophakic patients still report glare and halo-like phenomena. In general, most of these complaints are referred to by pseudophakic patients with multifocal IOLs. However, these complaints are also referred to by pseudophakic patients with monofocal IOLs. Clinical experience would suggest that the number of these complaints does decrease over time. It remains unclear, however, whether this decrease is due to habituation or due to an actual reduction in straylight over time. In this study, we have therefore compared straylight measured six weeks and one year after cataract surgery with monofocal IOLs. Since glare and halo-like phenomena are often perceived during night vision, we also measured the effect that pupil size has on straylight in pseudophakic eyes.

## **Methods**

### *Subjects*

Measurements were obtained from 24 patients with bilateral age-related cataract. The study was approved by the UMCG Medical Ethical Committee. Informed consent was obtained from all patients in accordance to the tenets of the Declaration of Helsinki. Exclusion


criteria included any concurrent disease that might influence the optical or neural performance of the eye, like uveitis, retinal and optic nerve pathology such as macular degeneration, diabetic retinopathy or glaucoma, corneal or vitreous opacities and irregularities, amblyopia and complications during cataract surgery. To further document the absence of ocular pathology, corneal topography was performed (Orbscan II version 3.12, Bausch & Lomb, Inc., Rochester, New York, USA). Furthermore, patients who received Nd:YAG laser capsulotomy to treat posterior capsule opacification (PCO) were excluded, as were patients with a refractive error of more than +/- 2 D spherical equivalent after cataract extraction and/or with an astigmatism of more than 2.5 D in either eye.

Patients received the aspheric Tecnis ZA9003 IOL (AMO, Santa Ana, CA, USA) in one eye and the spherical Sensar AR40e IOL (AMO, Santa Ana, CA, USA) in the fellow eye as part of an earlier study wherein these two IOLs were compared within subject. For that study, a pseudo-randomization scheme was used in order to have equal numbers of dominant/non-dominant, left/right and first/last operated eyes with both IOL types. IOL power was chosen aiming for an emmetropic postoperative refraction. All surgery was performed by the same experienced surgeon (SK), at the University Medical Center Groningen, The Netherlands, using phakoemulsification through a 3.0 mm clear corneal incision at the 12:00 o'clock position and IOL implantation with an Emerald injector (AMO, Santa Ana, CA, USA). Implantation in the second eye was scheduled at least one month after the first eye, in accordance with the guidelines of the Dutch Ophthalmological Society.

The pupil was dilated with two drops of tropicamide 0.5% and two drops of phenylephrine 2.5% (Chauvin Pharmaceuticals Ltd, Kingston-upon-Thames, Surrey, UK). Retroillumination photographs were taken 30 minutes after dilation and straylight measurements (see below) were performed both before dilation and thirty minutes after dilation.

#### *Retroillumination photographs*

To quantify the amount and location of the PCO, digital retroillumination photographs of the entire IOL surface were taken one year after cataract surgery using a digital camera (Nikon D70, Sendia, Japan) attached to a slitlamp (Carl Zeiss Meditec, Oberkochen, Germany) by an experienced photographer. An experienced ophthalmologist (SK), who was unaware of the straylight test results, pointed out whether the eye of the patient had PCO formation within a central zone of 3.0 mm diameter. Those patients with PCO within this zone were excluded from the analyses. Pupil size and capsulorhexis size were also determined from these photographs using IMAGEnet2000, version 2.53 (Topcon Europe B.V., Capelle aan den IJssel, The Netherlands; Figure 1).



**Figure 1.** *Illustration of a retroillumination photograph. The area within the capsulorhexis was calculated from its mean diameter, determined by averaging the lengths of the eight green lines; the pupil area was calculated using the length of the blue line as diameter. Note: the average dilated pupil diameter in our study was 5.5 mm that is, obviously, smaller than the pupil diameter in this example.*

### *Straylight measurements*

Straylight was assessed with the C-Quant (Oculus, Wetzlar, Germany), six weeks (natural pupil) and one year (both natural and dilated pupil) after cataract extraction. The measurement was based on compensation comparison and has been described by Franssen et al. in detail.<sup>10</sup>

### *Statistical analysis*

The main outcome variable for the straylight measurements was the logarithmic straylight parameter,  $\log(s)$ . To obtain reliable straylight values,  $\log(s)$  had to be less than 2.5 with a standard deviation of less than 0.12.<sup>9,11,12</sup> No significant differences in straylight between eyes with the spherical Sensar AR40e IOL (mean  $\log(s)$  1.33, standard deviation 0.22,  $n = 18$  [straylight measurements were unreliable in 4 patients]) and the aspheric Tecnis ZA9003 IOL (mean  $\log(s)$  1.31, standard deviation 0.22,  $n = 18$ ,  $P = .644$ ) could be found. For that reason, the analyses were performed without stratification to IOL type. The analyses were performed on one eye per subject, again based on a pseudo-randomization scheme: right and left eyes were selected alternately based on the order in which the cataract surgeries were performed. The t-test for paired samples was used to calculate differences in straylight between spherical and aspheric IOLs, between six weeks and one year after cataract extraction, and between dilated and undilated pupils. The relationships between straylight

measured in natural and dilated pupils, between measurements performed six weeks and 1 year after cataract surgery, and between straylight measured in dilated pupils and the ratio between the exposed capsule area and pupil area were evaluated with linear regression analysis (aiming at a linear relationship). To confirm a normal distribution of the residuals, a non-parametric Kolmogorov-Smirnov  $Z$  test was performed. A  $P$ -value  $\leq 0.05$  was considered statistically significant.

## Results

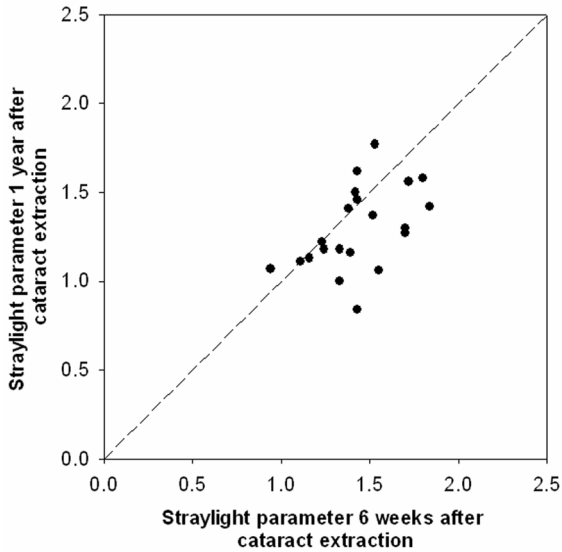
Originally, 24 patients, 13 females and 11 males, were included in this study. The mean follow-up period was 1.4 years, with a standard deviation of 0.3 years. The mean age of these patients was 71.2 years, with a standard deviation of 11.4 years; ages ranged from 47 to 88 years of age. One patient was excluded from the study because Nd:YAG laser capsulotomy was performed on the selected eye; another patient was excluded because of the presence of PCO in the center of the lens capsule. This left 22 patients (11 with a Tecnis IOL and 11 with a Sensar IOL).

### *Straylight at different points in time, measured with a natural pupil*

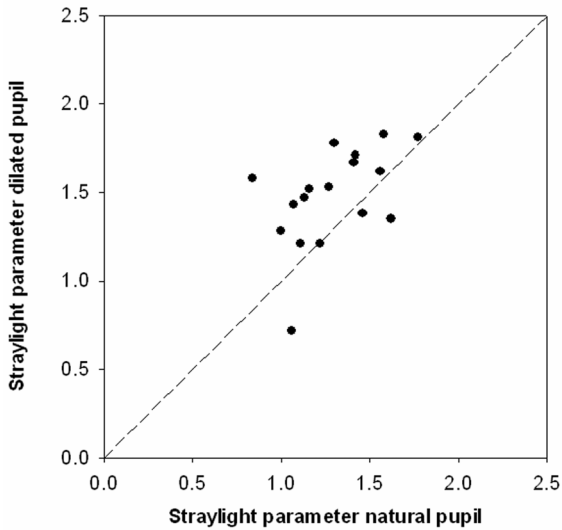
Straylight decreased significantly after cataract extraction (preoperative mean log(s) 1.78, standard deviation 0.27,  $n = 16$ ; postoperative 1.41, standard deviation 0.24,  $n = 16$  [straylight measurements pre- or postoperatively were unreliable in 6 patients];  $P < .001$ ). Figure 2 shows a scatterplot with straylight values six weeks and one year after the operation. The straylight parameter measured six weeks after cataract surgery (mean log(s) 1.44, standard deviation 0.23) was significantly higher than the value measured after one year (1.30, standard deviation 0.23,  $n = 21$  [straylight measurements 6 weeks or 1 year postoperatively were unreliable in 1 patient],  $P = .012$ ). A statistically significant relationship was found between measurements performed six weeks and one year postoperatively ( $R^2 = 0.25$ ,  $P = .021$ ).

### *Straylight in natural versus dilated pupils*

Figure 3 presents a scatterplot with straylight values with natural and dilated pupils. The straylight parameter increased significantly with dilation (mean log(s) with natural pupils 1.29, standard deviation 0.25; with dilated pupils 1.48, standard deviation 0.28,  $n = 17$  [straylight measurements with or without dilation were unreliable in 5 patients],  $P = .012$ ). In addition, there was a significant relationship found between the amount of straylight measured in dilated and natural pupils ( $R^2 = 0.24$ ,  $P = .044$ ).



**Figure 2.** Straylight measured one year after cataract extraction as function of straylight measured six weeks after cataract extraction. Measurements performed in a natural pupil.

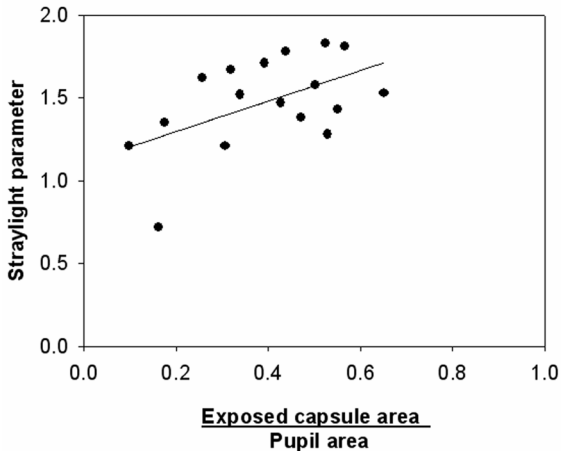


**Figure 3.** Straylight measured in dilated pupils as function of straylight measured in natural pupils. Measurements performed one year postoperatively.

Figure 4 shows the relationship between straylight measured in dilated pupils and the ratio between the exposed capsule area and the pupil area. As can be seen in this figure, straylight appeared to be higher when a larger part of the pupillary area was obstructed by the anterior capsule (slope = 0.92;  $R^2 = 0.28$ ;  $P = .031$ ). When adjusted for the pupil area



using a multivariate model, the ratio between the exposed capsule area and the pupil area remained significantly associated with straylight (slope = 1.45;  $R^2 = 0.36$ ;  $P = .018$ ) whereas the pupil area itself was not significantly associated with straylight ( $P = .195$ ). Hence, the increase in straylight in dilated pupils seems to be caused by the presence of the anterior capsule in the pupillary area and not by an increase in the pupil area itself (see Discussion).



**Figure 4.** Straylight as a function of the ratio between the exposed capsule area (the area within the pupil minus the area within the capsulorhexis) and the pupil area. Measurements were performed in dilated pupils, one year after cataract surgery.

## Discussion

This study investigated the relationship between straylight measured six weeks and one year after IOL implantation. Over time, straylight was found to decline. To construe the glare and halo-like phenomena sometimes reported by pseudophakic patients during night vision, the relationship between pupil size and straylight in pseudophakic patients was studied. An increase in straylight was found when pupils were dilated.

Phacoemulsification leads to endothelial cell loss<sup>13-15</sup> and early sub-clinical postoperative corneal swelling.<sup>16-18</sup> The location that has the most swelling may well depend on the location of the incision.<sup>16</sup> Bolz et al.<sup>16</sup> measured corneal thickness in patients after small-incision cataract surgery and found an increase in thickness at all locations on the cornea, but this increase was more profound peripherally than centrally. Three months after cataract surgery, corneal thickness had decreased to preoperative values in all regions of the cornea.<sup>16</sup> Elliot et al. measured the straylight in eyes with a contact lens-induced increase in thickness of the cornea<sup>19</sup> and found a decrease in straylight with decreasing corneal thickness. The presence of residual sub-clinical corneal swelling soon after cataract

surgery could explain the higher straylight values found in our study at six weeks after implantation compared to one year after implantation in our study when measured in a natural pupil. In our study, however, we could not find a significant difference in central corneal thickness between the measurements performed six weeks (552  $\mu\text{m}$ , standard deviation 45  $\mu\text{m}$ ) and one year (553  $\mu\text{m}$ , standard deviation 46  $\mu\text{m}$ ;  $P = .70$ ,  $n = 19$ ) after cataract surgery. These measurements were performed in the center of the cornea; some residual swelling more close to the incision site might explain the higher straylight values six weeks after the operation.

Glare problems are generally experienced more strongly at night when the pupil is large. It might seem obvious to simply conclude that an increase in glare perception is due to an increase in straylight. However, because large pupils allow more light to reach the retina, the effect of glare is counteracted: not only is the proportion of scattered light greater, but also the proportion of non-scattered light, resulting in relatively the same amount of straylight for both small and large pupils.<sup>20</sup> Franssen and co-authors investigated the relationship between pupil size and straylight in healthy phakic eyes.<sup>20</sup> No statistically significant difference in straylight was found for pupil sizes between 2.0 mm and 8.0 mm. In the present study, however, we found an increase in straylight with increasing pupil size. A possible explanation for this apparent discrepancy is that with a large pupil in a pseudophakic eye, parts of the peripheral anterior capsule may become visible in the pupillary area, interfering with the light rays, and thus increasing straylight. The result of our multivariate analysis supports the hypothesis that the increase in straylight between natural and dilated pupils is caused by the presence of anterior capsule in the pupillary area and not by an increase in pupil size itself. With a capsulorhexis diameter of 4 mm and a pupil diameter of 5 mm, the average straylight parameter is 0.52 greater than in the case of an undisturbed optical path. This increase in straylight is larger than the average decrease in straylight after cataract surgery (the difference between the average pre- and postoperative [6 weeks] straylight parameter was 0.34), suggesting that the advantage of cataract surgery on straylight is largely diminished when the capsulorhexis becomes visible in the pupillary area. The mean dilated pupil diameter in our study was 5.5 mm (hence, Figure 1 does not represent a typical case). The mean natural pupil diameter under mesopic conditions has been reported to be 5.1 mm, with a standard deviation of 0.7 mm.<sup>21</sup> Hence, with a typical capsulorhexis diameter of 4 mm, which may further shrink due to phimosis, some anterior capsule visible in the pupillary area will not be a rare finding under mesopic conditions with natural pupils.

Some of the increase in straylight with increasing pupil diameter might also be caused by PCO formation at the edges of the IOL. PCO is common after cataract surgery and can be considered part of the normal wound-healing process.<sup>22,23</sup> In PCO, residual lens epithelial cells cause opacification of the capsular bag.<sup>24,25</sup> These opacifications may reside

not only on the posterior capsule, but also on the anterior capsule, and may increase with time. Because the residual lens epithelial cells can disturb the light distribution on the retina, straylight may increase<sup>26,27</sup> while visual acuity<sup>26,27</sup> and contrast sensitivity<sup>26-28</sup> may decrease. Contradictory results have been reported concerning the preferred size of the capsulorhexis from the point of view of PCO formation. Hollick et al. demonstrated that a large capsulorhexis resulted in more severe PCO,<sup>29</sup> whereas Apple et al. and Tetz et al.<sup>24,25</sup> postulated that a capsulorhexis larger than the IOL would allow fusion of the anterior capsule to the posterior capsule, preventing the epithelial cells from migrating centrally. The follow-up period (1.4 years) of our study was too short to study the relationship between capsulorhexis size and PCO formation. Whether or not a large capsulorhexis is favorable or unfavorable from the point of view of PCO formation should, therefore, be the subject of future research.

In conclusion, we found an increase in straylight in dilated pupils related to the presence of anterior capsule in the pupillary area. This increase in straylight could explain complaints reported by patients concerning night vision.

## **Acknowledgements**

The authors would like to thank José Eisses and Henk Luurtsema for their contribution in taking the retroillumination photographs.

## References

1. Van den Berg TJ. Importance of pathological intraocular light scatter for visual disability. *Doc Ophthalmol* 1986; 61:327-333
2. Elliott DB, Bullimore MA. Assessing the reliability, discriminative ability, and validity of disability glare tests. *Invest Ophthalmol Vis Sci* 1993; 34:108-119
3. Van den Berg TJ. Analysis of intraocular straylight, especially in relation to age. *Optom Vis Sci* 1995; 72:52-59
4. Van den Berg TJ, IJspeert JK, de Waard PW. Dependence of intraocular straylight on pigmentation and light transmission through the ocular wall. *Vision Res* 1991; 31:1361-1367
5. Vos JJ. Disability glare-a state of the art report. *Commission International de l'Éclairage Journal* 3/2 1984; 39-53
6. IJspeert JK, de Waard PW, van den Berg TJ, de Jong PT. The intraocular straylight function in 129 healthy volunteers; dependence on angle, age and pigmentation. *Vision Res* 1990; 30:699-707
7. De Wit GC, Franssen L, Coppens JE, van den Berg TJ. Simulating the straylight effects of cataracts. *J Cataract Refract Surg* 2006; 32:294-300
8. De Waard PW, IJspeert JK, van den Berg TJ, de Jong PT. Intraocular light scattering in age-related cataracts. *Invest Ophthalmol Vis Sci* 1992; 33:618-625
9. Van den Berg TJ, Van Rijn LJ, Michael R, et al. Straylight effects with aging and lens extraction. *Am J Ophthalmol* 2007; 144:358-363
10. Franssen L, Coppens JE, van den Berg TJ. Compensation comparison method for assessment of retinal straylight. *Invest Ophthalmol Vis Sci* 2006; 47:768-776
11. Coppens JE, Franssen L, van den Berg TJ. Reliability of the compensation comparison method for measuring retinal stray light studied using Monte-Carlo simulations. *J Biomed Opt* 2006; 11:054010
12. Coppens JE, Franssen L, Van Rijn LJ, van den Berg TJ. Reliability of the compensation comparison straylight measurement method. *J Biomed Opt* 2006; 11:34027
13. Zetterstrom C, Laurell CG. Comparison of endothelial cell loss and phacoemulsification energy during endocapsular phacoemulsification surgery. *J Cataract Refract Surg* 1995; 21:55-58
14. Walkow T, Anders N, Klebe S. Endothelial cell loss after phacoemulsification: relation to preoperative and intraoperative parameters. *J Cataract Refract Surg* 2000; 26:727-732
15. Dick B, Kohnen T, Jacobi KW. [Endothelial cell loss after phacoemulsification and 3.5 vs. 5 mm corneal tunnel incision]. *Ophthalmologie*. 1995;92:476-483.
16. Bolz M, Sacu S, Drexler W, Findl O. Local corneal thickness changes after small-incision cataract surgery. *J Cataract Refract Surg* 2006; 32:1667-1671
17. Salvi SM, Soong TK, Kumar BV, Hawksworth NR. Central corneal thickness changes after phacoemulsification cataract surgery. *J Cataract Refract Surg* 2007; 33:1426-1428

18. Lundberg B, Jonsson M, Behndig A. Postoperative corneal swelling correlates strongly to corneal endothelial cell loss after phacoemulsification cataract surgery. *Am J Ophthalmol* 2005; 139:1035-1041
19. Elliott DB, Fonn D, Flanagan J, Doughty M. Relative sensitivity of clinical tests to hydrophilic lens-induced corneal thickness changes. *Optom Vis Sci* 1993; 70:1044-1048
20. Franssen L, Taberero J, Coppens JE, van den Berg TJ. Pupil size and retinal straylight in the normal eye. *Invest Ophthalmol Vis Sci* 2007; 48:2375-2382
21. Denoyer A, Le Lez ML, Majzoub S, Pisella PJ. Quality of vision after cataract surgery after Tecnis Z9000 intraocular lens implantation: effect of contrast sensitivity and wavefront aberration improvements on the quality of daily vision. *J Cataract Refract Surg* 2007; 33:210-216
22. Schaumberg DA, Dana MR, Christen WG, Glynn RJ. A systematic overview of the incidence of posterior capsule opacification. *Ophthalmology* 1998; 105:1213-1221
23. Apple DJ, Peng Q, Visessook N, et al. Eradication of posterior capsule opacification: documentation of a marked decrease in Nd:YAG laser posterior capsulotomy rates noted in an analysis of 5416 pseudophakic human eyes obtained postmortem. *Ophthalmology* 2001; 108:505-518
24. Apple DJ, Solomon KD, Tetz MR, et al. Posterior capsule opacification. *Surv Ophthalmol* 1992; 37:73-116
25. Tetz MR, O'Morchoe DJ, Gwin TD, et al. Posterior capsular opacification and intraocular lens decentration. Part II: Experimental findings on a prototype circular intraocular lens design. *J Cataract Refract Surg* 1988; 14:614-623
26. Jose RM, Bender LE, Boyce JF, Heatley C. Correlation between the measurement of posterior capsule opacification severity and visual function testing. *J Cataract Refract Surg* 2005; 31:534-542
27. Meacock WR, Spalton DJ, Boyce J, Marshall J. The effect of posterior capsule opacification on visual function. *Invest Ophthalmol Vis Sci* 2003; 44:4665-4669
28. Buehl W, Sacu S, Findl O. Association between intensity of posterior capsule opacification and contrast sensitivity. *Am J Ophthalmol* 2005; 140:927-930
29. Hollick EJ, Spalton DJ, Meacock WR. The effect of capsulorhexis size on posterior capsular opacification: one-year results of a randomized prospective trial. *Am J Ophthalmol* 1999; 128:271-279