

University of Groningen

Discogenic low back pain

Coppes, Maarten Hubert

IMPORTANT NOTE: You are advised to consult the publisher's version (publisher's PDF) if you wish to cite from it. Please check the document version below.

Document Version

Publisher's PDF, also known as Version of record

Publication date:

2000

[Link to publication in University of Groningen/UMCG research database](#)

Citation for published version (APA):

Coppes, M. H. (2000). *Discogenic low back pain: lumbar spondylodesis revisited*. s.n.

Copyright

Other than for strictly personal use, it is not permitted to download or to forward/distribute the text or part of it without the consent of the author(s) and/or copyright holder(s), unless the work is under an open content license (like Creative Commons).

The publication may also be distributed here under the terms of Article 25fa of the Dutch Copyright Act, indicated by the "Taverne" license. More information can be found on the University of Groningen website: <https://www.rug.nl/library/open-access/self-archiving-pure/taverne-amendment>.

Take-down policy

If you believe that this document breaches copyright please contact us providing details, and we will remove access to the work immediately and investigate your claim.

Downloaded from the University of Groningen/UMCG research database (Pure): <http://www.rug.nl/research/portal>. For technical reasons the number of authors shown on this cover page is limited to 10 maximum.

INTERBODY FUSION FOR CHRONIC LOW BACK PAIN

Throughout the medical history fusion operations have been performed in order to immobilize painful joints. Pain of musculoskeletal origin arises from complex neural networks when damaging stimulants such as chemical irritants, heat, and mechanical stresses stimulate peripheral nociceptors. With respect to pain arising from the degenerated lumbar spine, motion, particularly if abnormal in character or degree, often is a potent stimulus to peripheral nociception. Temporary prevention of excessive movements by rest or immobilizing external casts may result in pain relief. When instability or spinal deformities are the cause of pathologic motion, a more permanent correction, and therefore elimination of nociception stimulation, can be achieved by spinal fusion. So, the aim of fusing one or more spinal segments is to stabilize the spine, correct the deformity, and to eliminate painful movement, thereby restoring skeletal alignment, relieving pain, and preventing recurrence. Based on these principles arthrodesis has been applied to the management of painful spinal segments.

4.1 HISTORICAL REVIEW OF SPINAL FUSION

Hibbs³⁶ and Albee⁵ were the first to report clinical results of spinal fusion in 1911. Independently they reported on a novel surgical technique for the treatment of Pott's disease (spondylitis tuberculosa). Hibbs had noticed that the patella became secondarily integrated in the ankylosis after surgical arthrodesis of the knee. He also observed the spontaneous ankylosis of the infected spine and reasoned that surgical acceleration of this process might result in more rapid and reliable consolidation. In order to induce spinal fusion, Hibbs bridged the interlaminar spaces using the spinous processes, a technique that became known as posterior interlaminar fusion. Albee, on the other hand, inserted a tibial graft into the spinous processes in order to provide an internal splint and hasten stabilization of the spine. Although posterior hardware fixation devices (wires and steel bars) had already been described by Hadra²⁹ and Lange⁴⁴, no type of internal fixation was used in these early reports. In 1924, Hibbs reported a fusion method in patients with scoliosis³⁷ which was quite different from the one published in 1911. In this technique, nowadays referred to as the classic Hibbs method of spinal fusion, a posterolateral approach was used allowing a larger area for bone grafting and fusion than the aforementioned posterior interlaminar fusion. All methods of spinal fusion in which fragments of bone are elevated from the laminae and spinous processes and are turned up and down in a transposed manner, are virtually modifications of this technique.⁵² In 1929, the first studies on the outcome of lumbosacral fusions performed for degenerative conditions of the spine were reported by Hibbs and Swift.³⁸ Later, in 1943, Howorth⁴⁰ published results of spinal fusion for ruptured lumbar intervertebral discs. It is interesting to note that the development of spinal fusion techniques predates the understanding and surgical treatment of lumbar disc herniation. By 1933, when Mixter and Barr⁵¹ presented

their treatise on disc herniation to the New England Surgical Society, there was a 20-year experience with spinal fusion.

Surgical techniques have markedly changed over the years in an attempt to provide better correction of the deformities, enhance stabilization, and increase the rate of bony consolidation. The evolved fusion techniques can generally be divided into posterior, posterolateral, and anterior approaches. Posterior spinal fusion, such as described by Hibbs and Albee in 1911, is by definition posterior to the pedicles. Unfortunately, this initial technique proved to be biomechanically insufficient and did not allow the use of extensive posterior decompressive procedures. Other techniques were therefore developed by Hibbs himself as well as by others. In 1939, Campbell¹² described posterolateral fusion of the lumbosacral spine in association with sacroiliac fusion. Subsequently, many others^{4,8,9,14,48,66} have described various posterolateral fusions techniques (transverse process fusions), but the principle of solid lateral intertransverse fusion remained the same.⁷⁰ In comparison with the initial posterior fusion, these procedures yielded superior fusion results and enabled the combination with decompressive procedures and posterior instrumentation.³⁰

Cloward was not satisfied with the posterior type of spinal fusion after removal of the herniated disc fragment. The bridging with a graft of the spinous processes and laminae, which are non-weight-bearing surfaces, of one single vertebral segment did not seem physiologically appropriate. He therefore developed a technique which on the one hand restored the height of the intervertebral space and on the other hand immobilized the adjacent vertebral bodies.¹⁶ In this posterior lumbar interbody fusion (PLIF) technique, the bodies (main weight-bearing part of the vertebra) become fused by a strong intervertebral graft wedged into the interspace at the site of the ruptured disc. He started his procedure in 1943, and over the years he has reported on more than 1,300 cases treated by PLIF.⁶ His fusion and long-term clinical success rates of both over 90% turned out to be hard to equal by others, who published results varying from 40% up to 95%⁶⁰. Cloward himself reviewed the topic in 1985¹⁵, stating strongly once again that with the PLIF technique good fusion and clinical results can be obtained.

Before the posterior technique was introduced, the spine had already been approached anteriorly by Muller in 1906 for treatment of tuberculosis of the spine.³⁹ However, the first report on anterior lumbar spinal fusion was not until 1932 by Capener²⁸, followed by Burns¹⁰ in 1933 who used a tibial graft to transfix L5 to S1 in a 14 year old boy with spondylolisthesis. Modification and variations were then described,^{18,23,35,49,59} and in 1948, Lane and Moore⁴³ were the first to use anterior interbody fusion specifically for discopathies. The fusion as well as clinical results of anterior lumbar spinal fusion (ALIF) varied from less than 20% up to more than 95%,^{19,25,26,34,61} comparable to the PLIF results.

As part of the evolution of surgical techniques, internal fixation devices have been developed in order to accomplish greater correction of deformation, enhance stabilization, increase rate and degree of bone consolidation, and reduce the rate of pseudoarthrosis.²⁷ The introduction of posterior hooks and rods by Harrington in 1962³³ initiated modern posterior internal fixation of the spine. Improvement of the Harrington distraction and compression rod system resulted, among others, in the Luque method of sublaminar wire fixation and the Wisconsin system of fixation with spinous process wires.⁵⁸ Next to these methods other devices like pedicle screw systems^{41,47,67,69} have been developed in such a way that, nowadays, the spine surgeon has a wide variety of spinal devices in his armamentarium. The question remains how and when to use these different forms of hardware.

4.2 RATES OF SPINAL FUSION

Individual beliefs and style of practice are very important in deciding whether or not to perform spinal fusion, especially in patients with degenerative spinal disorders. Inconsistency regarding the appropriate indication for spinal fusion in this major group of potential spinal fusion candidates may therefore create geographic differences in reported fusion rates (table 4.1).^{13,42} These differences in fusion rates are small compared to the differences in the overall back surgery rates in which herniated disc operations are included (table 4.2).

Table 4.1 Rate of lumbar spinal fusion operations for degenerative spine conditions in different countries (number per 100.000 inhabitants).*

	1992	1994	1996	1998
France	15.0	16.6	18.3	20.2
Germany	12.6	13.9	15.3	16.9
Austria	12.9	14.3	15.8	17.4
Spain	4.2	4.6	5.1	5.6
Italy	2.5	2.7	3.1	3.4
Belgium	10.0	11.0	12.2	13.4
The Netherlands	8.8	9.7	10.6	11.7
Denmark	7.0	7.8	8.6	9.4
Norway	8.5	9.4	10.3	11.4
Sweden	8.4	9.3	10.2	11.3
Finland	7.3	8.0	8.9	9.8
Great Britain	9.0	9.9	10.9	12.0
Ireland	9.5	10.5	11.6	12.8
Greece	1.7	1.9	2.0	2.3
Turkey	0.3	0.3	0.4	0.4
South Africa	8.8	9.6	10.7	11.7
Israel	3.0	3.3	3.7	4.1
Portugal	4.1	4.5	4.9	5.5
USA ⁴²	30.9	-	-	-
Switzerland	4.8	5.3	5.8	6.4
Total	7.7	8.5	9.4	10.3

* Data obtained from Sofamor-Danek

Table 4.2 International comparison of overall back surgery rates.

Country	BSR* per 100.000 inhabitants	No.spine surgeons/million population
USA	158	76
Great Britain	30	18
The Netherlands	115	30
Sweden	52	87

* BSR = back surgery rate

The number of spinal column operations performed, in particular that of lumbar spinal fusion, increased significantly during the eighties. For example, between 1979 and 1990 the rate of lumbar spinal fusions doubled in the US.²¹ The magnitude of this increase could not be attributed to differences in age distribution, increase in population size, sociodemographic differences or prevalence of back problems, it rather reflected changes and new concepts of the medical practice (like new fusion techniques and instrumentation).⁶⁵ The rates of lumbar spinal fusion appeared to stabilise in the early nineties^{21,55,65}, a trend which has also been noted in The Netherlands.⁶³ This stabilization was probably due to more strict selection criteria, especially in the treatment of patients with chronic low back pain. The total numbers of lumbar spinal fusion procedures for degenerative spinal disorders in different countries over the last years are presented in table 4.1.

4.3 BIOMECHANICAL CONSIDERATIONS OF LUMBAR SPINAL FUSION

The spine is to be considered as a mechanical structure. The vertebrae articulate with each other in a controlled manner through a complex system of levers (vertebrae), pivots (discs and facets), passive restraints (ligaments), and activators (muscles). A comprehensive knowledge of spinal biomechanics is of major importance for the understanding of clinical signs and symptoms and management of spine problems.

From a biomechanical point of view fusing one or more spinal motion segments is not physiologic. The normal spine allows specific motion at each level, while arthrodesis prohibits movement. Focus of lumbar spinal fusion in patients with chronic low back pain is on relieving pain and disability and not directly on the mechanical characteristics. Nevertheless, it can be stated that successful clinical results are in some way related to reduced mechanical stresses in particular painful spinal structures.¹

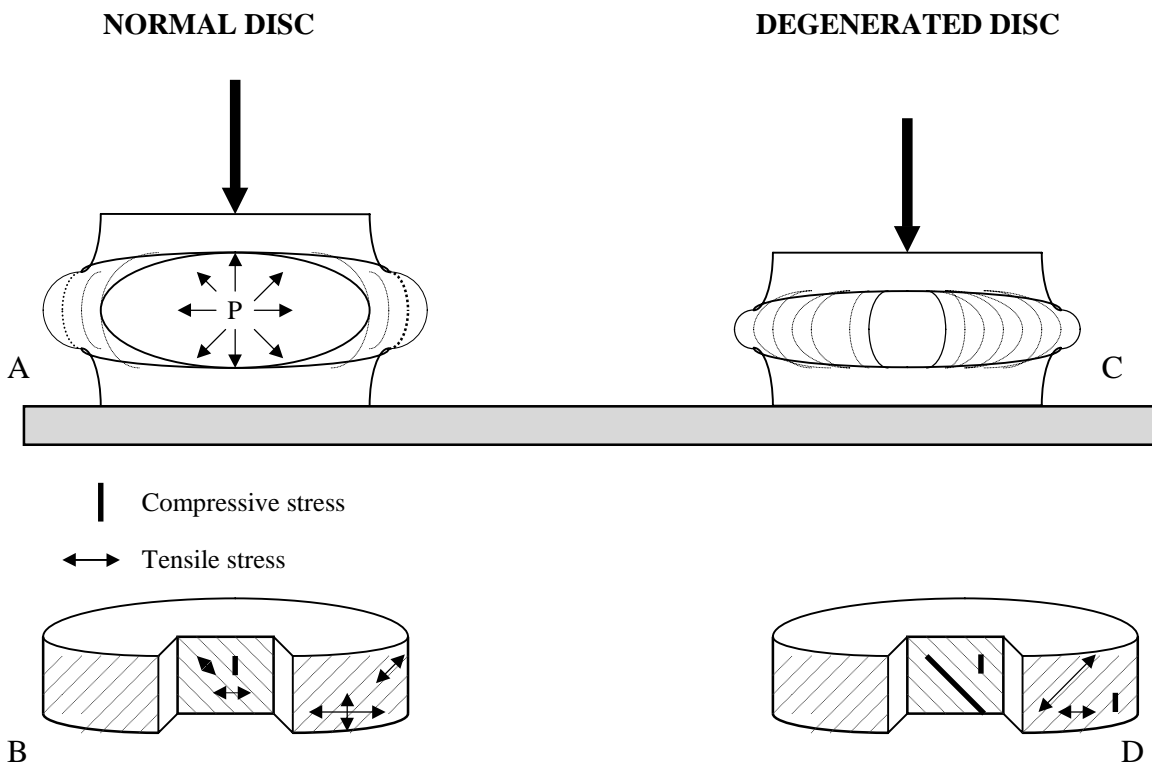
4.3.1 Biomechanics of the intervertebral disc

The intervertebral disc is perfectly designed to alleviate mechanical forces and transmit them in all possible directions. Because of its liquid and elastic nature, the disc can be compressed, redistribute primary vertical forces in the horizontal plane, and subsequently recover from the pressure. When compressive forces are applied to the liquid nucleus pulposus, fluid pressure builds up and pushes the surrounding structures away from the center (tensile stresses). This load-transferring mechanism can only function optimally when the disc water content is high and sufficient fluid pressure can be built up. This is usually the case in early life up to the age of 30. In a healthy intervertebral disc the nucleus is capable of absorbing and retaining large quantities of fluid. Because of its elastic nature, it is the anulus that gives the disc its compressibility and remodelling properties, and prevents bending and twisting of the disc.

The intervertebral disc receives the effects of most forces transmitted from one vertebral body to another. Since the major loading of the intervertebral disc is in the form of vertical compression, it may seem paradoxical that the anulus is optimally constructed to resist tension stresses, but the nucleus transforms the vertical thrust into a radial pressure that is restricted by the tensile properties of the lamellae of the anulus. This results in various stresses in different directions: tensile stresses along the anular fibers,

tensile stresses in a horizontal (tangential) direction, and stresses in an axial direction. Although the basic plan of alternating bands of fibers is one of the obvious sources of the tensile strength of the anulus, this arrangement is not uniform with respect to the directions of the fibers or the degrees of resistance encountered throughout the anulus.⁵⁶ The fibers generally become longer, and the angle of their spiral course becomes more horizontal near the outer parts of the anulus. The anulus of the nondegenerated disc has the greatest resistance in the horizontal sections of the peripheral lamellae, whereas the more vertical medial sections are more distensible (figure 4.1).

Fig. 4.1 Nondegenerated and degenerated discs under compression (based on White and Panjabi⁶⁸).



A. Pressure within the nucleus produced by compression pushes the anulus and the two end-plates outward. The disc bulges out in the horizontal plane and the end-plates deflect in axial direction.

B. The anulus is subjected to varying amounts of stresses in different directions. On the outer layers there is a large tangential (peripheral) stress, and a relatively small tensile stress in axial direction. In the inner layers, the stresses are smaller but of the same type, except for the axial stress which is now compressive.

C. In the degenerated disc the compressive load is transferred from one end-plate to the other by way of the anulus only, thus loading the end-plates at the periphery.

D. The stresses in the degenerated disc are different from the healthy one (B). In the outer layers of the disc, tangential (peripheral) stress is much smaller, while the anulus fibers are subjected to nearly twice as much stress. Further, the axial stress is compressive. In the inner layers the fiber stress remains very high, but now is compressive.

The way the disc deals with mechanical stresses has changed when the disc is degenerated. For example, the load-transferring capacity of the degenerated disc is reduced because of the decreased water content; when compressed, the nucleus is not capable of building up enough fluid pressure, resulting in load transfer from one endplate to the other by the annulus only. The outer annular layers are then submitted to less horizontal tensile stresses, but the tensile stresses along the annular fibers are much higher. Peaks of compressive stress are present in the middle of the annulus, particularly posterior to the nucleus.^{2,3} The fiber stress in the inner annular layer remains high but is compressive as well. In severely degenerated discs, structural damage to the vertebral endplates and the annulus often is present. The stress distributions become multiple and irregular in the annulus. It is believed that, in these damaged discs, a cascade of changes causes nerve structures to penetrate deeper into the intervertebral disc and the disc may become painful (see Chapter 3).²² These observations have been confirmed in patients undergoing spinal fusion and are consistent with findings of provocative discography.^{53,62}

4.3.2 Lumbar spinal fusion and biomechanics

Prevention of intervertebral motion by bony union between adjacent vertebral bodies (spinal fusion) is assumed to result in pain reduction. The most logical site to fixate the spinal motion segment, in order to prevent intervertebral movement, is at some distance from its physiologic rotation centers. The rotation center for flexion and extension is close to the nucleus pulposus⁵⁷, and for axial rotation the rotation center is in the posterior annulus fibrosis.¹⁷ Theoretically, spinal movement becomes maximally restricted by fixation at some distance from these regions of the disc. Both pedicle screw fixators and anterior plating systems meet this requirement. However, it is unlikely that rigid spinal fixation systems without adding interbody fusion will be capable to maintain the immobilisation of the fused segment for a long period of time. At some moment the fixation systems will permit slight motion and only small compressive deformities are necessary to induce high intradiscal compressive stresses.

Although spinal interbody fusion fixates the spinal motion segment at its fulcrum it has the advantage of additional spinal stability by influencing the intervertebral ligaments which are strong and lie relatively far away from the rotation centers. Normally these ligaments are not effective in inhibiting small spinal movements because they are slack for a certain range of motion, especially when the disc is degenerated.^{1,50} However, during spinal interbody fusion these ligaments become tight resulting in enhanced stability.

Thus, a biomechanical basis for spinal fusion in patients with chronic low back pain due to benign spinal degeneration is apparently present. By preventing intervertebral motion and unloading specific areas in the disc, the pain and disability should be relieved. Although interbody fusion stabilizes the motion segment close to the pivot point of flexion/extension movements, it has the advantage of additional stabilization by tightening the intervertebral ligaments.

4.4 SURGICAL TECHNIQUES

Lumbar interbody fusion operations can be divided in posterior lumbar interbody fusion (PLIF) and anterior lumbar interbody fusion (ALIF), based on the approach. The posterior approach through a longitudinal midline incision provides direct access of all levels of the lumbar spine. The anterolateral retroperitoneal flank approach can usually provide visualisation of the vertebrae L2 to S1.

4.4.1 Posterior lumbar interbody fusion

Cloward^{15,16} is credited for fully elaboration of the PLIF-technique. Numerous techniques have evolved that modify Cloward's basic construct, including dowel fusion and cage fusion. We will describe the technique advocated by Cloward.

The patient is placed on the operating table either bending on his knees with his torso resting on a pillow (Salaam position) or prone (Jack knife position). After preliminary soft tissue dissection exposing the posterior elements, the supra- and interspinous ligaments and the flaval ligament are removed. The inferior border of the superior lamina is removed. The medial part of the inferior articular process is cut off which exposes the medial border of the underlying superior articular process. Reduction of this part completes the partial medial facetectomy. The procedure is carried out bilaterally.

After discectomy an osteotome is used to take down the caudal and cranial anulus parts and the end-plates. The lower and upper surfaces are made parallel to each other. Curettes are used quite extensively in cleaning out the intervertebral disc space. The vertebral bodies are distracted using a lamina or interbody spreader. The width and depth of the intervertebral disc space is measured during moderate distraction. Usually grafts with a length of 2.5 to 3.0 cm and a height of 1.0 to 1.8 cm will do to fill up the obtained disc space. Two full thickness (tricortical) grafts are removed separately from the posterior iliac crest using an osteotome and a power saw. The grafts are cut slightly larger (± 1 mm) than the height of the distracted interspace to achieve firm impaction. After removing the interbody spreader a spacer of the appropriate size is placed on one side of the intervertebral disc space to maintain the distraction. On the opposite side an appropriate size tricortical bone graft is then placed in the intervertebral disc space with slight tapping. While placing the graft, special attention is given to protect the nerve roots passing cranially and medially to the graft. The spacer is then removed and a second bone graft inserted. Occasionally a third graft is inserted after pushing-up a graft medially using a wedging technique with two specially designed chisels: by spreading and turning the chisels, the graft is directed medially allowing space for an additional graft.

The lumbar dorsal fascia is closed over a suction drainage, and the wound is closed in layers. Finally, the iliac crest wound is closed also using suction drainage.

4.4.2 Anterior lumbar interbody fusion

The patient is placed in the supine position on the operating table. The table is handled in such a way that hyperextension of the lumbar spine is provided. A small pillow is placed under the left buttock to elevate the iliac crest. An oblique, left-sided paramedian incision is made, commencing approximately 3 cm lateral of the midline between the umbilicus and symphysis pubis and extending upwards and laterally. The incision is made through the skin and superficial fascia, and the anterior rectus sheath is divided in the line of the skin incision. The rectus muscle is retracted medially. A posterior rectus sheath incision is

made and the retroperitoneal space is entered. Extension of the incision into the aponeurosis of the internal oblique muscles and the transverse muscle can be made to reach the L3-4 and higher levels. The peritoneum is carefully separated by blunt dissection. The psoas muscle, the left ureter and the iliac artery and vein are visualized on the left side.

Several patterns of bifurcation of the common iliac arteries and veins exist. The bifurcation may be opposite to the midline of the fifth lumbar vertebra or at the level of the last intervertebral disc space or even as high as the middle of the fourth lumbar vertebral body. The decision to retract the left artery and vein to the right, in order to expose L4-L5, depends on the height of the bifurcation. Usually, isolation of the L5-S1 interspace is possible just below the bifurcation. Exposure of the L3-L4 interspace can often be achieved without division of any significant vessels; a lumbar vessel lying on the side of the body of L4 may need to be divided.

After exposing the lumbosacral interspace by retracting the left iliac artery and vein to the left side and of the right iliac artery and vein to the right side with blunt retractors, Steinmans spikes are driven bilaterally into the body of the fifth lumbar vertebra. One spike is driven into the rostral part of the first sacral vertebra on the right side. In this way, exposure is maintained during the interbody fusion procedure. The arterial pulse is palpated distally to the spikes in order to assure that excessive tensions on the vessels is prevented.

In exposing the third and fourth lumbar interspace, the left iliac artery and vein and the aorta and vena cava are kept to the right behind two Steinmans spikes. During exposure of these interspaces the change of obliterating the left iliac artery by applying excessive tension on the retractor is greater than at the former level.

The anterior longitudinal ligaments along with the anterior part of the anulus fibrosus is cut and the disc is removed. The space is cleaned out thoroughly, up to the posterior longitudinal ligament. Cartilage surfaces are removed from the vertebral bodies with an osteotome until bleeding bone is encountered and the lower and upper surfaces run parallel to each other. Then the dimensions of the interspace can be measured while enlarging the interspace with a vertebral body distractor.

The iliac crest is prepared by subperiosteal dissection to harvest full thickness bone grafts, i.e. including inner and outer cortex of the ilium. The tricortical grafts are taken slightly larger than the measured height of the interspace so that firm impaction can be effected. Usually graft dimensions vary between 1.0 to 1.8 cm in height and 2.5 to 3.0 cm in length. When the width, which is the third dimension, of the grafts are small, three or incidentally four grafts are inserted. In these cases the previous described wedging technique is used by introducing two specially designed chisels between the lateral part of the intervertebral space and the inserted graft. The spine is then straightened by reversing the hyperextended position of the table.

A suction drain is put in the retroperitoneal cavity. Both fascia layers of the rectus muscle are closed. Subcutaneous tissues are closed and monoflyic nylon sutures are placed through the skin. At the donor side the wound is closed in layers using suction drainage.

4.4.3 Minimal Invasive Anterior Lumbar Interbody Fusion (mini-ALIF)

A microsurgical modification of the surgical anterior approach has recently been advocated by Mayer.⁴⁷ A standardized, microsurgical retroperitoneal approach to levels L2-

L3, L3-L4 and L4-L5 and a microsurgical transperitoneal approach to L5-S1 are described. The operation is performed with a surgical microscope or with a headlamp and loupes.

Retroperitoneal approach

The patient is placed in a right lateral position on the surgical table. Depending on the level that must be operated on, the table is tilted backwards in the axial plane for 20° (L4-L5), 30°(L3-L4) or 40°(L2-L3). A few centimeters ventral and proximal of the spina iliaca anterior superior, a 4 cm skin incision is made in an oblique direction parallel to the fibers of the external oblique abdominal muscle. The retroperitoneal space is reached by a blunt, muscle splitting approach. The anterolateral attachments of the psoas muscle are dissected from the lateral circumference of the disc space. The lateral border of the anterior longitudinal ligament is exposed in the center of the wound. On rare occasions the segmental vessels of the inferior vertebral body need to be ligated.

In general, no retraction of the left iliac vein or artery is needed. In the anterolateral cortex of the adjacent vertebral bodies, two screws are placed. These screws serve as an anchor for the vertebral bodies. Then the graft bed is prepared using this anterolateral approach. A tricortical graft or a cage is placed into the intervertebral space.

Transperitoneal approach

The patient is placed in a supine Trendelenburg position (trunk tilted 20-30°) with the lumbar spine hyperextended and both legs abducted (the surgeon is standing between the legs). A 4 cm skin incision is made in the midline of the abdomen centered over L5-S1 (usually 5-10 cm cranial from the symphysis). The visceral peritoneum is reached and dissected in the midline. The mesenterium with the ileum and sigmoid colon are pushed into the upper left abdominal cavity. A special spreader is inserted that exposes the promontorium. Five millimeters medial to the right common iliac artery, an incision of the peritoneum parietale is made. The retroperitoneal fat is retracted to the left and the anterior circumference of L5-S1 is exposed. After dissection of the middle sacral artery and vein, the disc is incised and the disc space is cleared. A graft or cage can be placed after completing the preparation of the graft bed.

4.4.4 Spinal instrumentation

A further evolution of the PLIF- and ALIF-techniques was facilitated by the development of a wide array of spinal instrumentation devices.^{31,32} The interest for the combined technique of interbody fusion with instrumentation resulted from dissatisfaction with the fusion rates obtained by interbody fusion alone. Indeed, the combined application of these techniques resulted in a increased bony fusion rate.^{45,46,74} An additional but also important advantage of internal fixation is the avoidance of need for external bracing post-operatively which also allows the patient to early join a rehabilitation program. The major disadvantages include the risk of nerve root lesioning, increase in operation time, increase of infection rate, and restricted to the anterior fixation device, vascular injuries.⁶⁹

The greatest enthusiasm during the past two decades has been for pedicle screw fixation. The underlying principle is that the pedicle and adjacent vertebral body represent the most secure point of fixation. A great deal of research attention has been given to the optimization of the screw design and the linkage systems (plates and rods).^{1,58,64} For the anterior approach plate- or rod systems are mostly used as supplemental lumbar fixation

devices. Each system has its theoretical and practical advantages and disadvantages. Provided advanced surgical skills, rods and screws can be safely applied to the lumbar spine.

Due to the wide variety of systems available we will not discuss the various application techniques of the individual devices.

4.4.5 Post-operative care

The use of a plaster spica from the trunk to one knee is usually prescribed in those patients without internal fixation devices. The plaster corset is worn for a period of three months. During this period, anticoagulation therapy is given prophylactically. Internal fixation devices obviate the need for plaster spica or anticoagulation therapy.

4.4.6 Technique related complications

The PLIF- and ALIF-technique are both complex surgical procedures, but in experienced hands they can be carried out with good clinical results and few complications. The main concern in doing a PLIF-operation is to protect the spinal nerve roots and also the cauda equina from being damaged while inserting the interbody grafts. The major problem associated with ALIF concerns the high complication rate involved with mobilizing the great vessels and handling the presacral plexus. In addition impotence in the male may occur, though this complication may be prevented by careful dissection. There is a high risk of postoperative deep venous thrombosis, which may lead to permanent swelling of the legs and occasionally results in fatal pulmonary embolus (table 4.3).

Table 4.3 Complications of lumbar interbody fusion.^{19,30,41,42,47,60}

	Complications	Reported rates
peroperative	dural tears	0% - 15%
	excessive blood loss	sporadic case reports
	intra-abdominal vessel injury	0% - 2.5%
	nerve root injury	0.5% - 10.0%
	nerve injury secondary to donor site	0% - 4.5%
	position related peripheral nerve injury	0% - 1.0%
	visceral injury (bowel, kidney, ureter)	sporadic case reports
	donor site pain	8% - 45%
postoperative	graft extropulsion	0.7%
	incisional hernias	0.7%
	infection - superficial	0% - 3.2%
	- deep	0.5% - 3%
	- discitis	0.5% - 2.7%
	- meningitis	0.1%
	post-sympathectomy syndrome	0.5%
	pseudoarthrosis	5.0% - 60.0%
	pulmonary embolus	0.1% - 1.2%
	retrograde ejaculation	1.0%
	thrombosis - deep venous	1.2% - 3.0%
- arterial	0.3%	

urinary tract infection	2.4% - 10%
urinary retention	0.5% - 38%

4.5 BONE GRAFTING

In order to obtain definite spinal stability by spinal interbody fusion, solid bony union is mandatory. The transplanted bone graft initially provides structural support, but this is temporary. Solid bony union requires bone growth (osteogenesis), the formation of bone forming cells (osteinduction) and a favorable infrastructure on which new bone can be deposited (osteoconduction).²⁴ Of course, revascularization and ingrowth of capillaries and osteoprogenitor cells into the bone graft must be present for long-term survival of the bone graft. Therefore, the graft must be carefully selected, harvested, prepared and incorporated. The ideal graft possesses osteogenic, osteoinductive as well as osteoconductive properties. Of all the types of grafts, autogenous bone is considered the most successful in acquiring bony union after spinal interbody fusion. However, autogenous bone has the disadvantage that it must be harvested from the patients themselves resulting in additional morbidity. In this respect other graft types such as allografts, xenografts or ceramics all carry an advantage but they regrettably appear to be inferior in obtaining solid bony union.⁷

BMP

Osteoinductive bone graft substitutes are being researched as supplementary or alternative means to achieve fusion. The goal of such work is to potentially eliminate the morbidity associated with autograft donor sites and to decrease the incidence of pseudarthrosis. The use of human bone morphogenetic proteins (BMP's) and recombinant human bone morphogenetic proteins (rh BMP's) as osteoinductive bone graft substitutes or expanders have recently gained considerable research interest. Animal studies of osteoinductive growth factors in spinal fusion have revealed high fusion rates.²⁰ No similar conclusive study on humans has been published until now.

Tissue engineering

The recent identification of embryonic stem cells offers a new approach to repair damaged tissues. Until now researches are a long way from being able to produce fully differentiated cells out of embryonic stem cells that can be used to create or repair specific organs. A more immediate goal would be to isolate so-called progenitor cells from tissues. Such progenitor cells have taken some of the steps towards becoming specialized. Because not yet fully differentiated the progenitor cells remain flexible enough to replenish several different cell types. Caplan et al.¹¹ for instance have isolated progenitor cells from human bone marrow that can be prompted in the laboratory into either osteoblasts that form bone or chondrocytes that compose cartilage. In the next decade major problems such as contamination of the cultures with connective tissue (fibroblasts) and the relatively small amount of growing cells that actually can be cultivated remain to be solved.

4.6 CONCLUSIONS

Although spinal fusion operations have been performed since the beginning of this century, no consensus exists on the indications to perform lumbar spinal fusion in degenerative chronic low back pain cases. Since general guidelines are lacking, differences in belief of individual spine surgeons result in great geographic variations in spinal fusion rates. Generally, a lot of surgeons hesitate to perform interbody fusion in this group of patients because of the complexity of the operation and high failure rates in multilevel arthrodesis. Partially responsible for disappointing results are poor patient selection, improper diagnosis, and inability to identify the pain moderator. However, new techniques that minimize the operation (mini-ALIF) and enhance the fusion rates (spinal instrumentation) have been developed and fairly good till excellent results have been reported in highly selected patients with single level fusions. Arthrodesis may therefore result in pain relief in some patients.

Facts to keep in mind when considering lumbar spinal fusion are:

1. Successful outcomes of lumbar spinal fusion depend on medical as well as on complex psychosocial and workplace factors. In each individual with chronic low back pain these factors must be assessed and a selection must be made based on strict in- and exclusive criteria.
2. Permanent spinal stability can be achieved by interbody fusion with or without the use of internal fixation devices but not by fixation devices alone.
3. A technically successful and solid fusion does not necessarily result in a satisfactory clinical outcome, and conversely postoperative pseudarthrosis is not synonymous with clinical failure.

Future studies may provide better insight in the various causes of chronic low back pain and provide objective tests for this condition. Only then scientific based selection of patients for lumbar spinal fusion will become possible.

REFERENCES

1. Adams MA. Biomechanics of spinal implants. Ch 1 In: Szpalski M, Gunzburg R, Spengler DM, Nachemson A, eds Instrumented Fusion of the Degenerative Lumbar Spine. State of the Art, Questions, and Controversies. Philadelphia: Lippincott-Raven Publishers, 1996.
2. Adams MA, McNally DM, Chinn H, Dolan P. Posture and the compressive strength of the lumbar spine. International Society of Biomechanics Award Paper. Clin Biomech 1994;9:5-14.
3. Adams MA, McNally DS, Dolan P. Stress distributions inside intervertebral discs: the effect of age and degeneration. J Bone Joint Surg Br 1996;78(6):965-972.
4. Adkins EWO. Spondylolisthesis. J Bone Joint Surg 1955;37B:48-62.
5. Albee FH. Transplantation of a portion of the tibia into the spine for Pott's disease. JAMA 1911;57:885-886.
6. Basso M. Plaidoyer pour la spondylodese intersomatique par abord posterieur sans reduction dans les spondylolisthesis de moins de 75% et la spondylolyses. Thesis, L'Universite Claud-Bernard, Lyon, France, 1983.
7. Boden SD, Schimandle JH. Biologic enhancement of spinal fusion. Spine 1995;20S:113S-123S.
8. Bosworth DM. Techniques of spinal fusion. Pseudoarthrosis and method of repair. Instr Course Lect 1948;5:295-313.
9. Bosworth DM, Levine J. Tuberculosis of the spine. An analysis of cases treated surgically. J Bone Joint Surg 1949;31A:267-274.
10. Burns BH. An operation for spondylolisthesis. Lancet 1933;1:1233.
11. Caplan AI, Reuben D, Haynesworth SE. Cell-based tissue engineering therapies: The influence of whole body physiology. Adv Drug Deliv Rev 1998;33(1-2):3-14.
12. Campbell WC. An operation for extra-articular fusion of sacroiliac joint. Surg Gynecol Obstet 1939;45:218-219.
13. Cherkin DC, Deyo RA, Loeser JD, Busch T, Waddel G. An international comparison of back surgery rates. Spine 1994;19(11):1201-1206.
14. Cleveland M, Bosworth DM, Thompson FR. Pseudoarthrosis in the lumbosacral spine. J Bone Joint Surg 1948;30A:302-312.
15. Cloward RB. The treatment of ruptured lumbar intervertebral discs by vertebral body fusion. Clin Orthop 1985;193:5-15.
16. Cloward RB. The treatment of ruptured lumbar intervertebral discs by vertebral body fusion. J Neurosurg 1953;10:154-168.
17. Cossette JW, Farfan HF, Robertson GH, Well RV. The instantaneous centre of rotation of the third lumbar intervertebral joint. J Biomech 1971;4:149-153.
18. Creyssel J, Bonnet J. Spondylolisthesis. Vissage par voie transperitoneale. Lyon Chir 1950;45:372.
19. Crock HV. Anterior lumbar interbody fusion. Indications for its use and notes on surgical technique. Clin Orthop 1981;165:157.
20. Cunningham BW, Kanayama M, Parker LM, Weis JC, et al. Osteogenic protein versus autologous interbody arthrodesis in the sheep thoracic spine. A comparative

- endoscopic study using the Bagby and Kuslich interbody fusion device. *Spine* 1999;24(6):509-518.
21. Davies H. Increasing rates of cervical and lumbar spine surgery in the United States, 1979-1990. *Spine* 1994;19:1117-1124.
 22. Freemont AJ, Peacock TE, Goupille P, Hoyland JA, O'Brien J, Jayson MIV. Nerve ingrowth into diseased intervertebral disc in chronic back pain. *Lancet* 1997;350:178-181.
 23. Friberg S. Studies on spondylolisthesis. *Acta Chir Scan (Suppl)* 1939;55:1-140.
 24. Friedlaender GE. Current concepts review bone graft. *J Bone Joint Surg* 1987;69A:786-790.
 25. Gelderman PW. Het lage rugsyndroom. Ph.D. thesis, University of Utrecht, Waander, Zwolle, 1981.
 26. Ghosez JP, Cambier P, Goguin JP. Role of anterior intersomatic arthrodesis in treatment of lumbalgia. *Acta Orthop Belg* 1981;47:643-656.
 27. Goel VK, Gilbertson LG. Basic science of spinal instrumentation. *Clin Orthop* 1997;335:10-31.
 28. Capener N. Spondylolisthesis. *Br J Surg* 1932;19:374-386.
 29. Hadra B. Wiring of the vertebrae as a means of immobilization in fracture and Pott's disease. *Am Orthop Assn Trans* 1891;4:282-286.
 30. Haid RW. Posterior surgical approaches and fusion. In: *Lumbar Spine Stabilization Course Syllabus*. American Association of Neurologic Surgeons, 1991.
 31. Haid RW, Kopitnik TA. Thoracic fractures: Classification and relevance of instrumentation. *Clin Neurosurg* 1992;38:213-233.
 32. Hanley EN Jr. The indications for lumbar spinal fusion with and without instrumentation. *Spine* 1995;20:143S-153S.
 33. Harington PR. Treatment of scoliosis. Correction and internal fixation by spine instrumentation. *J Bone Joint Surg* 1962;44A:491.
 34. Harmon PH. Anterior excision and vertebral body fusion operation for intervertebral disc syndromes of the lower lumbar spine. Three to five year results in 244 cases. *Clin Orthop* 1963;26:107-127.
 35. Henschen C. Operation der spondylolisthesis durch transabdominelle lumbosacralschraubung und zusätzlich transplantede spanversteifung. *Acta Helv Med* 1942;9:25-28.
 36. Hibbs RA. An operation for progressive spinal deformities. *NY Med J* 1911;93:1013-1016.
 37. Hibbs RA. A report of fifty-nine cases of scoliosis treated by fusion operation. *J Bone Joint Surg* 1924;6:3.
 38. Hibbs RA, Swift WD. Developmental abnormalities at the lumbosacral juncture causing pain and disability: report of 147 patients treated by the spinal fusion operation. *Surg Gynecol Obstet* 1929;48:604.
 39. Hodgson AR, Edin FRCS, Stock FE. Anterior spinal fusion. A preliminary communication on the radical treatment of Pott's disease and Pott's paraplegia. *Clin Orthop* 1994;300:16-23.
 40. Howorth MB. Evolution of spinal fusion. *Ann Surg* 1943;117:278-289.
 41. Hsu K, Zucherman JF, White AH, Wynne G. Internal fixation with pedicle screws. In: White AH, Rothman RH, Ray CD, eds. *Lumbar Spine Surgery Techniques and Complications*. St. Louis: Mosby, 1987:322.
 42. Katz JN. Lumbar spinal fusion. Surgical rates, costs, and complications. *Spine* 1995;20:78S-83S.

- 43.Lane JD, Moore ES. Transperitoneal approach to the intervertebral disc in the lumbar area. *Ann Surg* 1948;127:537-551.
- 44.Lange F. Support for the spondylitic spine by means of buried steel bars attached to the vertebrae. *Am J Orthop Surg* 1910;8:344.
- 45.MacAfee PC, Farey ID, Sutterlin CE, et al. Volvo Award in Basic Science: Device-related osteoporosis with spinal instrumentation. *Spine* 1989;14:919-926.
- 46.Mardjetko SM, Connolly PJ, Shott S. Degenerative lumbar spondylolisthesis. A meta-analysis of literature 1970-1993. *Spine* 1994;20S:2256S-2265S.
- 47.Mayer MH. A new technique for minimally invasive anterior lumbar interbody fusion. *Spine* 1997;22:691-699.
- 48.McElroy KD. Technique for bilateral lateral lumbosacral fusion. *J Bone Joint Surg* 1964;46A:461.
- 49.Mercer W. Spondylolisthesis. With a description of a new method of operative treatment and notes on ten cases. *Edinburgh Med J* 1936;43:545-572.
- 50.Mimura M, Panjabi MM, Oxland TR, et al. Disc degeneration affects the multidirectional flexibility of the lumbar spine. *Spine* 1994;19:1371-1380.
- 51.Mixter WJ, Barr JS. Rupture of the intervertebral disc with involvement of the spinal canal. *N Eng Surg* 1934;211:210.
- 52.Moe JH. A critical analysis of methods of fusion for scoliosis: An evaluation in two hundred and sixty-six patients. *Clin Orthop* 1977;126:4-16.
- 53.Moneta GB, Videman T, Kaivanto K, et al. Reported pain during lumbar discography as a function of annular ruptures and disc degeneration. *Spine* 1994;19:1968-1974.
- 54.Nachemson AL. Newest knowledge of low back pain. *Clin Orthop* 1992;279:8-20.
- 55.Nilasena DS, Vaughn RJ, Mori M, Lyon JL. Surgical trends in the treatment of diseases of the lumbar spine in Utah's Medicare population, 1984 to 1990. *Med Care* 1995;33:585-597.
- 56.Parke WW. Applied anatomy of the spine. In: Rothman RH, Simeone FA, eds. *The Spine 3rd Edition*. Philadelphia: Saunders Company, 1992:35-88.
- 57.Pearcy MJ, Bogduk N. Instantaneous axes of rotation of the lumbar intervertebral joints. *Spine* 1988;13:1033-1041.
- 58.Phillips WA, Hensinger RN. Wisconsin and other instrumentation for posterior spinal fusion. *Clin Orthop* 1988;229:44-51.
- 59.Ramser R. Transabdominelle operation der nicht traumatischen spondylolisthesis mit einem spez. *Acta Helv Med* 1943;10:365.
- 60.Roye DP Jr, Farcy JP. Lumbosacral Fusion. In: Camins M, O'Leary P, eds. *The Lumbar Spine*. New York: Raven Press, 1987;309-340.
- 61.Sacks S. Anterior interbody fusion of the lumbar spine. Indications and results in 200 cases. *Clin Orthop* 1966;44:163-170.
- 62.Shackelford IM, McNally DS, Mulholland RC, Goodship AE. The relationship between lumbar disc internal biomechanics and pain as provoked by discography. Presented to the International Society for the Study of the Lumbar Spine, Helsinki, Finland, 1995.
- 63.SIG Health Care Information 1995. Trends in neurosurgery 1984-1993:19.
- 64.Steffee AD, Biscup RS, Sitkowski DJ. Segmental spine plates with pedicle screw fixation: A new internal fixation device for disorders of lumbar and thoracolumbar spine. *Clin Orthop* 1986;203:45-49.
- 65.Taylor VM, Deyo RA, Cherkin DC, Kreuter W. Low back pain hospitalization. Recent United States trends and regional variations. *Spine* 1994;19:1207-1213.

66. Watkins MB. Posterolateral fusion of the lumbar and lumbosacral spine. *J Bone Joint Surg* 1953;35A:1014-1018.
67. West JL, Ogilvie JW. Results of variable screw plate pedicle screw fixation. *Spine* 1991;16:576.
68. White AA, Panjabi MM. *Clinical biomechanics of the spine*. 2nd ed Philadelphia, JB Lippincott Co., 1990.
69. Whitecloud TS, Butler JC, Cohen JL, Candelora PD. Complications with the variable spinal plating system. *Spine* 1989;14:472.
70. Wiltse LL, Bateman JG, Duesy R. Experiences with transverse process fusions in the lumbar spine. *J Bone Joint Surg* 1962;44A:1013.

