

# CHAPTER 10.1

## MONITORING OF IMPENDING MYOCARDIAL DAMAGE AFTER PLEURO-PNEUMONECTOMY AND INTRAOPERATIVE PHOTODYNAMIC THERAPY FOR MALIGNANT PLEURAL MESOTHELIOMA USING BIOCHEMICAL MARKERS

J.M. Klaase<sup>1</sup>, J.C.J.M. Swaanenburg<sup>2</sup>, H. Schouwink<sup>3</sup>, M.N. Sosef<sup>1</sup>, J.M.G. Bonfrer<sup>4</sup>, F.A.N. Zoetmulder<sup>1</sup>, E.J.Th. Rutgers<sup>1</sup>, P. Baas<sup>3</sup>

Departments of <sup>1</sup>Surgery,

<sup>3</sup>Medical Oncology,

<sup>4</sup>Clinical Chemical Laboratory, The Netherlands Cancer Institute (Antoni van Leeuwenhoek Huis), Amsterdam,

<sup>2</sup>Pathology and Laboratory Medicine, University Hospital Groningen, Groningen.

*Photochemistry and Photobiology 2000; 71: 351-354.*

## Summary

In five patients who were treated for malignant pleural mesothelioma (MPM) with pleuropneumonec-tomy and intraoperative photodynamic therapy (PDT), impending myocardial damage was moni-tored using ECG, the classical biochemical markers (Creatine Kinase (CK)-total activity, CKMB-mass, and myoglobin), and the new cardiac markers troponin I and troponin T. No severe myocar-dial damage could be encountered after pleuropneumonec-tomy and PDT. From this study in patients with MPM treated with pleuropneumonec-tomy and PDT it can be concluded that measurement of troponin I or T for the detection of myocardial damage is more suitable than measurement of the classical markers, because the classical markers are all elevated by the concomitant skeletal muscle damage.

## Introduction

Malignant pleural mesothelioma (MPM) is in most patients in an advanced stage at the time of diagnosis. It is considered to be incurable because at that time the tumor diffusely spreads into the pleural space (1). Therefore, microscopically radical resection can seldom be performed. In patients who are eligible for operation, adjuvant regimens consisting of chemotherapy or radiotherapy have been tested, without consistent survival benefit. Recently, intraoperative photodynamic therapy (PDT) was shown to be applied safely as an adjuvant therapy in a feasibility study from our institute (1).

One of the side effects of the PDT is damage to the normal intrathoracic structures like esophagus and heart. For the determination of (minor) myocardial damage, conventionally, the CKMB-isoenzym is used as the gold standard (2). However, CKMB is not heart-specific. Recently, cardiac troponin I (cTnI) and cardiac troponin T (cTnT) have been introduced as fully heart specific markers (2).

The troponins consist of a group of three subunits in the troponin-myosin complex on the thin filament of muscle myofibrils. They are involved in the regulation of muscle contraction and relaxation. Troponin T is the tropomyosin-binding subunit, which binds troponin I and troponin C to the tropomyosin. Troponin I is the actomyosin ATPase-inhibiting subunit and regulates the relaxation, whereas troponin C, the calcium-binding subunit, causes contraction. Only troponin I and troponin T have cardiospecific isoforms. Troponin T was introduced first; however, most studies indicate that cTnI is as specific as or even more cardiospecific than troponin T. In the sera of healthy volunteers both cTnI and cTnT are hardly detectable. Therefore, its appearance in blood is considered to be a clear signal of cardiac myocyte damage (2,3).

For reasons of the already mentioned heart-specificity, the new cardiac markers are thought to be more suitable than the classical biochemical markers (CK-total activity, CKMB and myoglobin) for the detection of myocardial tissue damage. This is especially true in patients with concomitant chest wall muscle damage (2), which can be expected in patients treated with pleuropneumonec-tomy and PDT.

The aim of this study was to investigate impending myocardial damage in patients with MPM treated with pleuropneumonec-tomy and intra-operative PDT, using the classical biochemical markers and compare them with the new markers cTnI and cTnT.

## Patients and methods

In the period october till december 1998, five consecutive patients with MPM, who were eligible for

surgery, were treated with pleuropneumonectomy followed by intra-operative PDT. Patient and treatment characteristics are given in table 1. Our treatment protocol for intraoperative PDT was published in detail before (1).

Blood samples were collected for the analysis of CK, CKMB-mass, myoglobin, cTnI and cTnT at the start of the operation, after finishing the pleuropneumonectomy, at the end of the PDT, and, subsequently, 2, 4, 8, 12, 20, 44 hours postoperatively. At the same time intervals also an electrocardiogram (ECG) was made. In case of suspicion of pericardial effusion, a cardiac ultrasound was performed. ECG and cardiac ultrasound were reviewed by a cardiologist.

Surgery

The operation consisted in all patients of a right pleuropneumonectomy. To reduce toxicity to the normal tissues, the theatre lights were out of focus and the normal skin was completely covered with sheets. The surgical goal was to achieve a macroscopically radical resection. In areas unsuitable for radical resection, a tumor reduction to less than 5 mm thickness was performed. The diaphragm and pericardium were spared as much as possible.

Photodynamic Therapy

The photodynamic treatment was performed with light of 652 nm from a high power diode laser, and meta-tetrahydroxy phenylchlorin as the photosensitizer, which was injected intravenously 96 hours before. The light delivery to the thoracic cavity was monitored by in situ isotropic light detectors (6 watt Applied Optronics, USA). The light detectors were placed on strategic places in the thoracic cavity to enable an optimal light distribution from a pseudospherical light bulb which was placed in the center of the cavity. One probe was fixed on or near the pericardium. Using these calibrated isotropic light detectors both direct light and reflected light could be measured. The total hemithoracic surface was illuminated with 10 J/cm<sup>2</sup>. On average the fluence rate varied from 5-25 mW/cm<sup>2</sup>.

At the end of this PDT procedure, one drain was left in the thoracic cavity. Postoperatively all patients received oral anticoagulants and digoxin as standard procedure.

Biochemical Markers

CK-total activity (upper reference limit 70 U/L) was measured with a Vitros 750C analyser (Ortho Clinical Diagnostics, Beerse, Belgium).

Myoglobin (upper reference limit 70 ng/ml) measurements were performed using a BNII-nephelometer (Dade-Behring, Leusden, The Netherlands).

For cTnI measurements (upper reference limit 2.0 ng/ml) an AxSYM Analyser (Abbott Diagnostics Division, Hoofddorp, The Netherlands) was used.

CKMB-mass (url 5.0 ng/ml) and cTnT measurements (ureference limit 0.1 ng/ml) were performed on an Elecsys 2010 analyser (Roche, Almere, The Netherlands) using 'second generation' cTnT antibodies (4).

**Table 1.** Patient and treatment characteristics and postoperative cardiac events

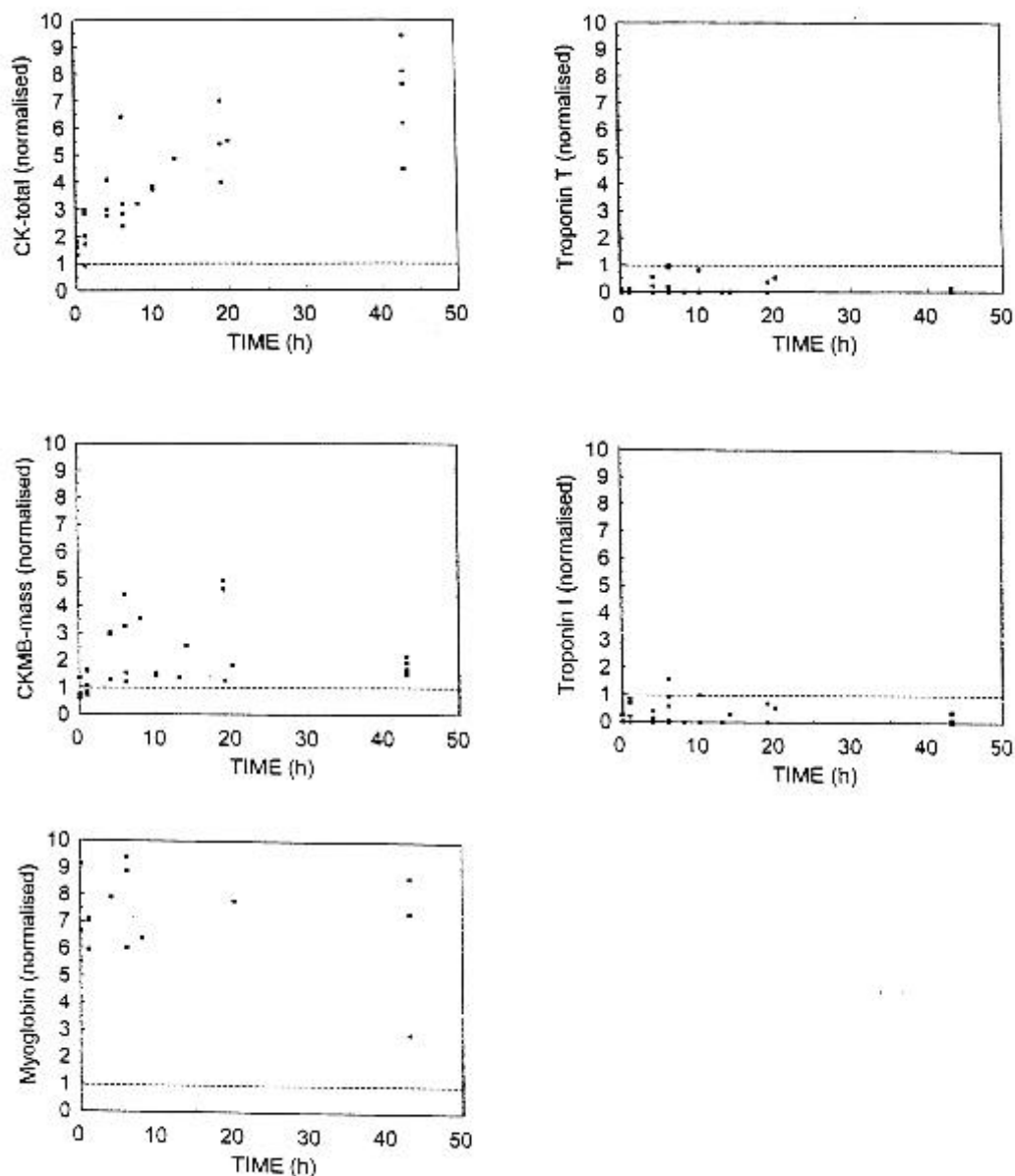
no	ge	age	site	diagnosis	treatment	car- diac even
----	----	-----	------	-----------	-----------	----------------------

ts

1	m	64	R	epitheloid mesothelioma	pleuropneumonectomy PDT 10 j/m <sup>2</sup>	minor pericardial effusion
2	f	54	R	mixed type mesothelioma	pleuropneumonectomy PDT 10 j/m <sup>2</sup>	minor pericardial effusion right bundle branch block
3	m	52	R	epitheloid mesothelioma	pleuropneumonectomy PDT 10 j/m <sup>2</sup>	atrial fibrillation
4	m	52	R	mesenchimal mesotheliomal	pleuropneumonectomy PDT 10 j/m <sup>2</sup>	minor pericardial effusion
5	m	60	R	mesothelioma unspecified	pleuropneumonectomy PDT 10 j/m <sup>2</sup>	minor pericardial effusion

## Results

The median duration of the operation was 5 (range 4-6) hours, including one hour PDT time (20 minutes of illumination and 20-40 minutes of preparation time). During the operation no complications occurred. The mean blood loss was 1 (range 1-2) liter. No serious cardiac side effects occurred in the early postoperative period (day 1-2) (table 1). In 4 of the 5 patients a small amount of pericardial effusion was detected on the second postoperative day, but this did not result in therapeutic interventions. In 1 patient an atrial fibrillation was detected on the second post-operative day despite digoxine treatment. Conversion to a normal sinus rhythm was achieved by treatment with cordarone. In one patient a right bundle branch block was detected on the ECG one day after the operation.



*Figure 1.* The release patterns of the normalised CK-total, CKMB-mass, myoglobin, cardiac troponin I and cardiac troponin T in 5 malignant mesothelioma patients undergoing pleuro-pneumectomy and subsequent intraoperative photodynamic therapy.

The test results of the biochemical markers are normalised by dividing the test result by the corresponding upper reference limit of that particular marker in order to be able to compare the results of the various markers. The normalised results of the biochemical parameters after pleuropneumectomy and intra-operative PDT are shown in figure 1. From this figure it can be concluded, that the examined classical parameters CK-total, CKMB-mass and myoglobin are all elevated after operation, whereas only one troponin I measurement (patient 5) and no troponin T measurements exceed the upper limit of reference range (illustrated by the solid line at level 1).

## Discussion

The use of PDT after pleuropneumectomy has been shown to be feasible in MPM patients (1). Although there is a potential danger of damage by PDT to the normal intrathoracic structures (like esophagus and heart) on theoretical grounds, so far, no serious cardiac side effects have been reported in the direct postoperative period. Only one study (5) is reported in the literature, which evaluates serial cardiac enzymes and ECG's after PDT for Barrett's esophagus in 12 patients. This study was carried out because atrial fibrillation after esophageal PDT had been reported in an earlier study. No significant or permanent abnormality was noted in the examined cardiac enzymes (CK-total, CKMB, LDH) or in the ECG's. Only one patient had transient atrial fibrillation during a follow-up endoscopy. However, in contrast to the present study the new markers cardiac troponin I and cardiac troponin T were not examined.

Because of their excellent cardiac specificity, troponin I and troponin T appear ideally suitable to discriminate between myocardial and skeletal muscle damage. This concerns for example non-cardiac surgery patients, like the patients in the present study, trauma patients or patients with chronic muscular disease, or after intense physical exercise (2,6,7).

The sensitivity of both troponins is at least equal to the known classical myocardial markers. The serum concentration of cTnI or cTnT seems to be the best biochemical marker for the detection of minor myocardial damage (8). Recently, for reasons of an insufficient sensitivity in the first hours following acute coronary syndromes, it was recommended to use another, more early myocardial marker, like myoglobin, in the cardiac panel for routine laboratory testing (9,10).

In the present study the examined classical markers CK-total activity, CK-MB mass and myoglobin were all elevated from the end of the PDT session on, whereas only one troponin I measurement was above the reference limit and no troponin T measurements were elevated. With the knowledge of the -at least- equal sensitivity of the classical markers and the troponins, it should be assumed that the classical markers were above their reference limits because of non-cardiac muscle damage. This can be explained by the trauma as a consequence of the operation and the intra-operative PDT. The finding, that only one troponin I concentration was minimally elevated and that no troponin T concentrations were elevated after operation and PDT, is in concordance with the fact that no serious cardiac side-effects were encountered in these patients. In only one patient there was a short period of atrium fibrillation, which may have been provoked by the right pneumonectomy itself instead of the PDT.

In conclusion, no serious myocardial damage could be detected as a consequence of pleuropneumectomy and intra-operative PDT in patients with MPM. The performance of the new cardiac markers troponin I and troponin T seems to be more reliable for the detection of (minor) myocardial damage than the classical parameters CK-total activity, CKMB-mass and myoglobin,

because the classical markers were all elevated as a consequence of the concomitant skeletal muscle damage.

## References

1. Baas, P., L. Murrer, F.A.N. Zoetmulder, F.A. Stewart FA, H.B. Ris, N. van Zandwijk, J.L. Peterse and E.J.Th. Rutgers (1997) Photodynamic therapy as adjuvant therapy in surgically treated pleural malignancies. *Br J Cancer* 76: 819-826.
2. Chapelle, J.P. (1999) Cardiac troponin I and troponin T: recent players in the field of myocardial markers. *Clin Chem Lab Med* 37(1): 11-20.
3. Del Rey, J.M., A.H. Madrid, J.M. Valino, J. Rubi, J. Mercader, C. Moro and E. Ripoll (1998) Cardiac troponin I and minor cardiac damage: biochemical markers in a clinical model of myocardial lesions. *Clin Chem* 44: 2270-2276.
4. Muller-Bardorff, M., K. Hallermeyer, A. Schroder, C. Ebert, A. Borgya, W. Gerhardt, A. Remppis, J. Zehelin and H.A. Katus (1997) Improved Troponin T ELISA specific for cardiac Troponin T isoform: assay development and analytical and clinical validation. *Clin Chem* 43: 458-66.
5. Overholt, B.F., M. Panjehpour and M. Ayres (1997) Photodynamic therapy for Barrett's esophagus: cardiac effects. *Lasers Surg Med* 21:317-20.
6. Falahati, A., S.W. Sharkey, D. Christensen, M. McCoy, E.A. Miller, M.A. Murakami and F.S. Apple (1999) Implementation of serum cardiac troponin I as marker for detection of acute myocardial infarction. *Am Heart J* 137: 332-7.
7. Swaanenburg, J.C.J.M., J.M. Klaase, M.J.L. DeJongste, K.W. Zimmerman and H.J. Ten Duis (1998) Troponin I, Troponin T, CKMB-activity and CKMB-mass as markers for the detection of myocardial contusion in patients who experienced blunt trauma. *Clin Chim Acta* 272: 171-81.
8. Apple, F.S., A. Falahati, P.R. Paulsen, E.A. Miller and S.W. Sharkey (1997) Improved detection of minor ischaemic myocardial injury with measurement of serum cardiac troponin I. *Clin Chem* 43: 2047-51.
9. Zaninotto, M., S. Altinier, M. Lachin, L. Celegon and M. Plebani (1999) Strategies for the early diagnosis of acute myocardial infarction using biochemical markers. *Am J Clin Path* 111: 399-405.
10. Wu, A.H.B., F.S. Apple, W. Brian Gibler, R.L. Jesse, M.M. Warshaw and R. Valdes Jr. (1999) National Academy of Clinical Biochemistry Standards of Laboratory Practice: Recommendations for the use of cardiac markers in coronary artery diseases. *Clin Chem* 45: 1104-21.

