

University of Groningen

Combined osimertinib, dabrafenib and trametinib treatment for advanced non-small-cell lung cancer patients with an osimertinib-induced BRAF V600E mutation

Meng, Pei; Koopman, Bart; Kok, Klaas; Elst, ter, Arja; Schuurin, Ed; van Kempen, L.; Timens, Wim; Hiltermann, Jeroen; Groen, Harry J. M. ; van den Berg, A.

Published in:
Lung Cancer

DOI:
[10.1016/j.lungcan.2020.05.036](https://doi.org/10.1016/j.lungcan.2020.05.036)

IMPORTANT NOTE: You are advised to consult the publisher's version (publisher's PDF) if you wish to cite from it. Please check the document version below.

Document Version
Publisher's PDF, also known as Version of record

Publication date:
2020

[Link to publication in University of Groningen/UMCG research database](#)

Citation for published version (APA):

Meng, P., Koopman, B., Kok, K., Elst, ter, A., Schuurin, E., van Kempen, L., Timens, W., Hiltermann, J., Groen, H. J. M., van den Berg, A., & van der Wekken, A. J. (2020). Combined osimertinib, dabrafenib and trametinib treatment for advanced non-small-cell lung cancer patients with an osimertinib-induced BRAF V600E mutation. *Lung Cancer*, 146, 358-361. <https://doi.org/10.1016/j.lungcan.2020.05.036>

Copyright

Other than for strictly personal use, it is not permitted to download or to forward/distribute the text or part of it without the consent of the author(s) and/or copyright holder(s), unless the work is under an open content license (like Creative Commons).

The publication may also be distributed here under the terms of Article 25fa of the Dutch Copyright Act, indicated by the "Taverne" license. More information can be found on the University of Groningen website: <https://www.rug.nl/library/open-access/self-archiving-pure/taverne-amendment>.

Take-down policy

If you believe that this document breaches copyright please contact us providing details, and we will remove access to the work immediately and investigate your claim.

Downloaded from the University of Groningen/UMCG research database (Pure): <http://www.rug.nl/research/portal>. For technical reasons the number of authors shown on this cover page is limited to 10 maximum.



Combined osimertinib, dabrafenib and trametinib treatment for advanced non-small-cell lung cancer patients with an osimertinib-induced *BRAF* V600E mutation

Pei Meng^a, Bart Koopman^a, Klaas Kok^c, Arja ter Elst^a, Ed Schuurin^a, Léon C. van Kempen^a, Wim Timens^a, T. Jeroen N. Hiltermann^b, Harry J.M. Groen^b, Anke van den Berg^a, Antonie J. van der Wekken^{b,*}

^a Department of Pathology and Medical Biology, University of Groningen, University Medical Center Groningen, the Netherlands

^b Department of Pulmonary Diseases, University of Groningen, University Medical Center Groningen, the Netherlands

^c Department of Genetics, University of Groningen, University Medical Center Groningen, the Netherlands

ARTICLE INFO

Keywords:

NSCLC
BRAF V600E
EGFR
 Dabrafenib
 Trametinib
 Osimertinib

ABSTRACT

Introduction: Previous studies have reported an acquired *BRAF* V600E mutation as a potential resistance mechanism to osimertinib treatment in advanced NSCLC patients with an activating mutation in *EGFR*. However, the therapeutic effect of combining dabrafenib and trametinib with osimertinib remains unclear. Here we report treatment efficacy in two cases with acquired *BRAF* V600E mutations.

Methods: Two patients with an *EGFR* exon 19 deletion and a T790 M mutation, both treated with osimertinib, acquired a *BRAF* V600E mutation at disease progression. Following the recommendation of the molecular tumor board, a concurrent combination of dabrafenib and trametinib plus osimertinib was administered.

Results: Because of toxicity, one patient ultimately received a reduced dose of dabrafenib and trametinib combined with a normal dose of osimertinib. Clinical response in this patient lasted for 13.4 months. Re-biopsy upon tumor progression revealed loss of *BRAF* V600E and emergence of *EGFR* C797S. The other patient, treated with full doses of the combined therapy, had progression with metastases in lung and brain one month after starting therapy.

Conclusion: *BRAF* V600E may be a resistance mechanism induced by osimertinib in *EGFR*-mutated advanced NSCLC. Combined treatment using dabrafenib/trametinib concurrently with osimertinib needs to be explored for osimertinib-induced *BRAF* V600E mutation.

1. Introduction

Osimertinib was approved by the Food and Drug Administration in 2018 for the treatment of epidermal growth factor receptor (*EGFR*)-mutant non-small-cell lung cancer (NSCLC) patients. At first, osimertinib was used only for patients with acquired T790 M mutations after 1st and/or 2nd generation *EGFR* tyrosine kinase inhibitor (TKI) treatment, but it more recently began to be used in first line treatment of *EGFR*-mutant patients [1]. Despite good initial responses, patients developed resistance to second-line osimertinib treatment, with a median time to progression of 10.1 months [2]. Several mechanisms to explain this resistance have been identified, including an acquired v-raf murine sarcoma viral oncogene homolog B1 (*BRAF*) V600E mutation

[2]. Treatment options for patients with acquired *BRAF* V600E have not been established and are still in an early phase of development.

Here we report treatment outcomes of dual inhibition of *EGFR* and *BRAF* for two NSCLC patients who developed resistance to osimertinib in second-line treatment, both with a *BRAF* V600E mutation as a potential acquired mechanism of resistance to osimertinib. We also provide an overview of the treatment outcomes for all reported cases with acquired *BRAF* V600E mutations.

2. Material and methods

Retrospective analysis of NSCLC patients with actionable *EGFR* mutations treated with osimertinib between January 1, 2015 and

* Corresponding author at: Afdeling longziekten en Tuberculose AA11, Universitair Medisch Centrum Groningen, Hanzeplein 1, 9713 GZ, Groningen, the Netherlands.

E-mail address: a.j.van.der.wekken@umcg.nl (A.J. van der Wekken).

<https://doi.org/10.1016/j.lungcan.2020.05.036>

Received 30 March 2020; Received in revised form 18 May 2020; Accepted 23 May 2020

0169-5002/ © 2020 The Author(s). Published by Elsevier B.V. This is an open access article under the CC BY license (<http://creativecommons.org/licenses/by/4.0/>).

March 1, 2020 revealed a *BRAF* V600E mutation in 2 of 80 NSCLC patients. Re-analysis of the pre- and post-osimertinib samples was performed for *BRAF* V600E using the highly sensitive droplet digital polymerase chain reaction (ddPCR) assay (dHsaMDV2010027 [Bio-Rad, Hercules, CA]) following standard procedures, as described previously [3]. The two patients were anonymized for the investigators. The study protocol complies with the Research Code of the University Medical Center Groningen (<https://www.rug.nl/umcg/research/documents/research-code-info-umcg-nl.pdf>) and national ethical and professional guidelines (“Code of conduct; Dutch federation of biomedical scientific societies”, <http://www.federa.org>).

3. Cases

Patient 1 was a 56-year-old never smoking Caucasian female diagnosed with a stage IV adenocarcinoma of the lung. An *EGFR* exon 19 deletion (E19del) (p.L747_A750delinsP) was identified by next generation sequencing (NGS) using an amplicon-based Ion Torrent platform on plasma DNA. The patient received afatinib as first-line treatment. After 11 months, she had progressive disease with an *EGFR* T790 M in addition to the previously observed *EGFR* E19del. Therefore, osimertinib was started as a second-line treatment. After about 8.5 months, the patient presented with progressive disease in lung and brain. Re-biopsy of the lung lesion and NGS showed loss of the *EGFR* T790 M and gain of a *BRAF* V600E in addition to the *EGFR* E19del. To establish whether the *BRAF* V600E was pre-existing or acquired, we performed ddPCR on the earlier biopsy taken from axillar lymph node. No *BRAF* V600E mutant droplets were detected in the pre-osimertinib sample, while there were 6,740 wild-type *BRAF* droplets, equaling a limit of detection of 0.04 %. As both biopsies originated from the same site, this indicates that the mutation developed during osimertinib treatment. After clinical discussion, the patient started treatment with dabrafenib and trametinib plus osimertinib concurrently. The patient responded clinically within 2 weeks, although brain metastases progressed at magnetic resonance imaging (MRI) after 6 weeks. Treatment had to be stopped because of a pneumonitis (Fig. 1A). The clinical condition of the patient was then not good enough to start new treatment, and she died 5 months later.

Patient 2 was a 66-year-old never smoking Caucasian male diagnosed with a stage IV adenocarcinoma of the lung. Diagnostic tests revealed an *EGFR* E19del (p.E746_A750del) in the baseline tumor biopsy. The patient received gefitinib treatment for a total period of 11.2 months. At disease progression, an *EGFR* T790 M mutation was detected in addition to the previously detected *EGFR* E19del, and osimertinib was administered. A partial tumor response was observed that was sustained for 20 months. Analysis of a biopsy taken at progression indicated presence of a *BRAF* V600E in addition to the previously observed *EGFR* E19del and T790 M. Re-analysis by ddPCR of the pre- and post-osimertinib biopsies, both taken from the subcarinal lymph node, confirmed *BRAF* V600E in the post-osimertinib sample and no detectable *BRAF*-V600E mutation in the pre-osimertinib sample. The limit of detection was 0.06 %, with a total 5,212 *BRAF* wild-type droplets in the pre-osimertinib sample. Based on the observed mutations, the patient was treated with a combination of dabrafenib and trametinib plus osimertinib. The patient showed a partial tumor response for all tumor sites, but required dose reduction because of repeated grade 2 pyrexia, a common toxicity criteria (V 4.0), grade 2 nausea and grade 2 vomiting. The treatment was reduced to 50 mg BID (twice per day) dabrafenib, 0.5 mg QD (once per day) trametinib and 80 mg QD osimertinib. Tumor mass showed a remarkable reduction after 3 months according to the positron emission tomography–computed tomography (PET-CT) image (Fig. 1B). After 13.4 months, the patient had progressive disease with disappearance of the *BRAF* V600E and an acquired *EGFR* C797S that coexisted with the previously observed *EGFR* E19del at similar variant allele frequencies (VAF) (77 % and 83 %, respectively), while the T790 M mutation was observed only at a very

low frequency (VAF of 2%). The absence of the *BRAF* V600E mutation was confirmed using ddPCR, with 36,119 wild-type droplets and no mutant droplets, reaching a limit of detection of 0.008 %. Based on these results, and after evaluation by our molecular tumor board, gefitinib treatment was proposed and started. Three weeks after start of this treatment, the clinical condition of the patient worsened rapidly as a result of pneumonitis without tumor progression, and the patient died a few days later.

4. Discussion

BRAF V600E is a known oncogenic driver occurring in approximately 2 % of all NSCLC [4]. Clinical studies have shown good anti-tumor effects of the *BRAF* inhibitor dabrafenib in combination with the MEK inhibitor trametinib in initial *BRAF* V600E-mutated NSCLC patients [5]. However, the effectiveness of dabrafenib and trametinib plus osimertinib as a treatment strategy for NSCLC patients where *BRAF* V600E is a possible resistance mechanism to EGFR TKI treatment is largely unknown. In our two cases, the *BRAF* V600E mutation is most likely an acquired osimertinib-resistance mutation, as we could not detect the *BRAF* V600E in pre-treatment biopsies using ddPCR. One of the two patients included in our study had brain metastases, and the main clinical deterioration under treatment came from progression of brain metastases. This patient did not respond to the treatment, possibly due to limited drug penetration across the blood-brain barrier [6] or to a novel resistance mechanism in the brain metastasis. The other patient responded to the treatment for 14 months until loss of the *BRAF* V600E mutation and induction of a new resistant mutation (*EGFR* C797). In both patients, a pneumonitis developed on TKI after exposure to the combined treatment. We do not know whether this is caused by the treatment.

So far, treatment outcome has been reported for five cases (Table 1). One patient demonstrated a reduction of tumor size after 2 weeks of dabrafenib/trametinib and a slight increase 4 weeks thereafter [7]. A second patient presented with clinical progression after 4 weeks of dabrafenib and trametinib treatment. After switching treatment to a combination of both osimertinib and dabrafenib, an impressive metabolic response was observed by ¹⁸F-2-fluoro-2-deoxy-D-glucose (FDG) PET/CT (−33 %) within 2 weeks [7]. The third patient was treated with dabrafenib and trametinib alternated with osimertinib because of hepatic progression in which a *BRAF* V600E was detected [8]. This patient responded to treatment for 6 months. The last two cases (one with an *EGFR* E19del and one with a L858R) were treated with a combination of dabrafenib, trametinib and osimertinib concurrently, after acquiring a *BRAF* V600E mutation upon treatment with osimertinib, which had been administered based on an acquired T790 M [9,10]. Both patients demonstrated tumor shrinkage during reported treatment times of 2 and 7 months, respectively. Treatment was ongoing at the time of the case reports, so the PFS time was not yet known. Despite the limited number of patients treated thus far, promising results have been obtained with the combined treatment.

In conclusion, our data indicate that the TKI-induced *BRAF* V600E mutation is an acquired resistance mechanism to osimertinib. Of the five patients receiving combined dabrafenib, trametinib and osimertinib, the four patients without brain metastasis showed a clinical response, while the fifth patient with brain metastasis did not respond. Combined treatment with dabrafenib/trametinib and osimertinib thus seems to be effective, especially in patients without brain metastasis. To define the most optimal treatment strategy for patients with *EGFR*-activating mutations who develop *BRAF* V600E mutations after initial response, further studies with similar treatment regimens and data on PFS and OS are required.

Declaration of Competing Interest

There are no conflicts of interest to this study.

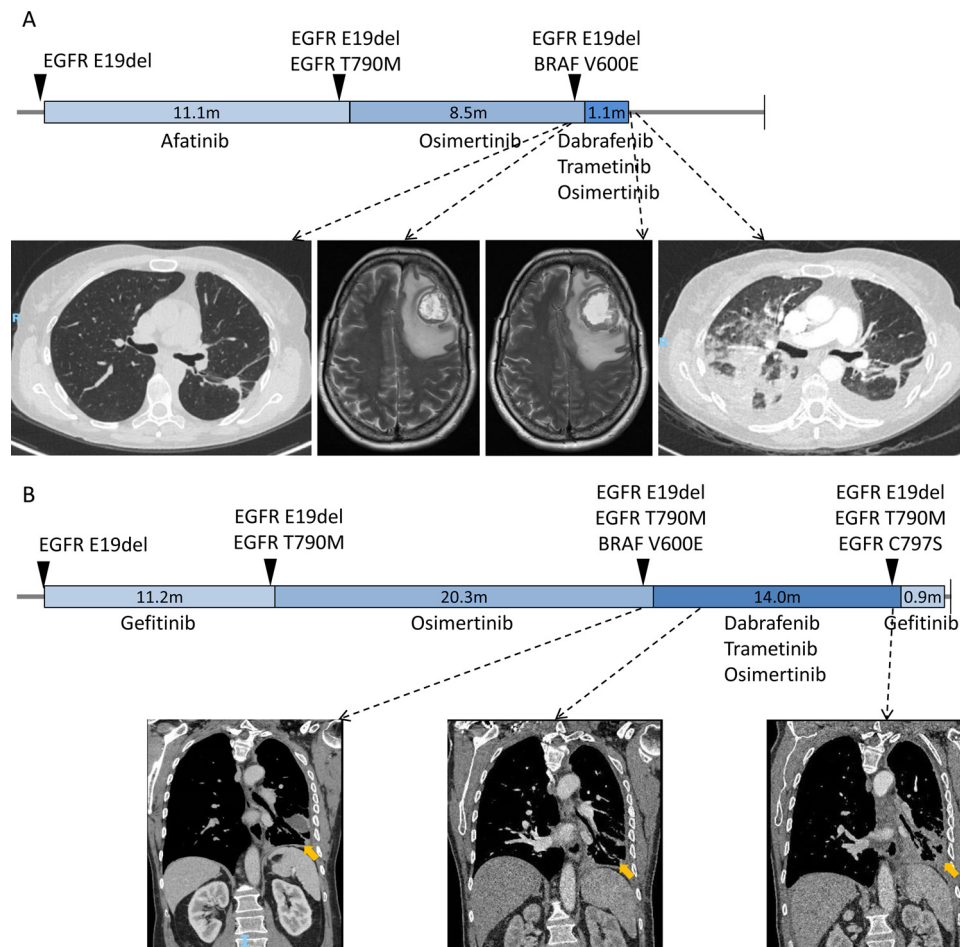


Fig. 1. Overview of treatment history and observed mutations before and during treatment of two *EGFR* E19del patients. A) Overview of patient 1. B) Overview of patient 2. Blue bar indicates the treatment periods of the different TKI regimens. The CT and MRI images are ordered according to the time point relative to the treatment. (For interpretation of the references to colour in this figure legend, the reader is referred to the web version of this article).

Table 1

Overview of patients with an osimertinib-induced *BRAF* V600E mutation and their treatment details from literature and this study.

No.	Ref	Baseline <i>EGFR</i> mutation	Line of the treatment	Mutation profile at resistance to osimertinib	Treatment	PFS (months)
1	12	E19del	NA	<i>EGFR</i> E19del / T790 M, <i>BRAF</i> V600E	D + T	1+
2	12	E19del	NA	<i>EGFR</i> E19del / loss of T790 M, <i>BRAF</i> V600E,	O + D	0.5+*
3	9	E19del	2	<i>EGFR</i> E19del / T790 M, <i>BRAF</i> V600E,	D + T + O*	6
4	10	E19del	2	<i>EGFR</i> E19del / T790 M, <i>BRAF</i> V600E	D + T + O	7+
5	11	L858R	2	<i>EGFR</i> L858R / T790 M <i>BRAF</i> V600E	D + T + O	2+
6	This study, patient 1	E19del	2	<i>EGFR</i> E19del / loss of T790 M, <i>BRAF</i> V600E	D + T + O	1
7	This study, Patient 2	E19del	2	<i>EGFR</i> L858R/ T790 M, <i>BRAF</i> V600E	D + T + O	14

D, T and O: dabrafenib, trametinib and osimertinib; * +: Treatment ongoing.

* D/T and O treatments were alternated every month.

Transparency document

The [Transparency document](#) associated with this article can be found in the online version.

Acknowledgements

We thank the molecular diagnostics team of the University Medical Center Groningen. We thank Kate Mc Intyre for English language editing. Pei Meng was supported by a grant of the Graduate School of Medical Sciences, University of Groningen. Bart Koopman was supported by ZonMw (The Netherlands Organization for Health Research) within the Personalized Medicine Program, grant number 846001001.

References

- [1] J.C. Soria, Y. Ohe, J. Vansteenkiste, T. Reungwetwattana, B. Chewaskulyong, K.H. Lee, A. Dechaphunkul, F. Imamura, N. Nogami, T. Kurata, I. Okamoto, C. Zhou, B.C. Cho, Y. Cheng, E.K. Cho, P.J. Voon, D. Planchard, W.C. Su, J.E. Gray, S.M. Lee, R. Hodge, M. Marotti, Y. Rukazenkov, S.S. Ramalingam, Osimertinib in untreated *EGFR*-mutated advanced non-small-cell lung cancer, *N. Engl. J. Med.* 378 (2) (2018) 113–125.
- [2] A. Leonetti, S. Sharma, R. Minari, P. Perego, E. Giovannetti, M. Tiseo, Resistance mechanisms to osimertinib in *EGFR*-mutated non-small cell lung cancer, *Br. J. Cancer* 121 (9) (2019) 725–737.
- [3] C. Bisschop, A. Ter Elst, L.J. Bosman, I. Platteel, M. Jalving, A. van den Berg, A. Diepstra, B. van Hemel, G.F.H. Diercks, G.A.P. Hospers, E. Schuurings, Rapid *BRAF* mutation tests in patients with advanced melanoma: comparison of immunohistochemistry, Droplet Digital PCR, and the Idylla Mutation Platform, *Melanoma Res.* 28 (2) (2018) 96–104.

- [4] C.S. Baik, N.J. Myall, H.A. Wakelee, Targeting BRAF-mutant non-small cell lung cancer: from molecular profiling to rationally designed therapy, *Oncologist* 22 (7) (2017) 786–796.
- [5] D. Planchard, E.F. Smit, H.J.M. Groen, J. Mazieres, B. Besse, A. Helland, V. Giannone, A.M. D'Amelio Jr., P. Zhang, B. Mookerjee, B.E. Johnson, Dabrafenib plus trametinib in patients with previously untreated BRAF(V600E)-mutant metastatic non-small-cell lung cancer: an open-label, phase 2 trial, *Lancet Oncol.* 18 (10) (2017) 1307–1316.
- [6] G. Gampa, S. Vaidhyanathan, B.W. Resman, K.E. Parrish, S.N. Markovic, J.N. Sarkaria, W.F. Elmquist, Challenges in the delivery of therapies to melanoma brain metastases, *Curr. Pharmacol. Rep.* 2 (6) (2016) 309–325.
- [7] D.S.Y. Abdulla, M. Scheffler, C. Kobe, T. Persigehl, M. Schmidt, J. Fassunke, S. Merkelbach-Bruse, S.Y.F. Michels, L. Nogova, S. Koleczko, R.N. Fischer, R. Riedel, A. Drzezga, R. Büttner, J. Wolf, Overcoming acquired osimertinib-resistance in EGFR-mutant advanced non-small lung cancer mediated by activating BRAF V600E mutation, *J. Clin. Oncol.* 37 (15_suppl) (2019) e20682-e20682.
- [8] J. Solassol, J.A. Vendrell, R. Senal, P. Audran, F. Leenhardt, X. Quantin, Challenging BRAF/EGFR co-inhibition in NSCLC using sequential liquid biopsies, *Lung Cancer* 133 (2019) 45–47.
- [9] Y. Huang, J. Gan, K. Guo, Y. Deng, W. Fang, Acquired BRAF V600E mutation mediated resistance to osimertinib and responded to Osimertinib, Dabrafenib, and trametinib combination therapy, *J. Thorac. Oncol.* 14 (10) (2019) e236–e237.
- [10] F. Zhou, W. Zhao, X. Chen, J. Zhang, C. Zhou, Response to the combination of dabrafenib, trametinib and osimertinib in a patient with EGFR-mutant NSCLC harboring an acquired BRAF(V600E) mutation, *Lung cancer (Amsterdam, Netherlands)* 139 (2020) 219–220.