

University of Groningen

Bilateral round ligament varicosities mimicking inguinal hernia during pregnancy

Ijpma, F.F.A.; Boddeus, K. M.; de Haan, H. H.; Van Geldere, D.

Published in:
Hernia

DOI:
[10.1007/s10029-008-0395-8](https://doi.org/10.1007/s10029-008-0395-8)

IMPORTANT NOTE: You are advised to consult the publisher's version (publisher's PDF) if you wish to cite from it. Please check the document version below.

Document Version
Publisher's PDF, also known as Version of record

Publication date:
2009

[Link to publication in University of Groningen/UMCG research database](#)

Citation for published version (APA):

Ijpma, F. F. A., Boddeus, K. M., de Haan, H. H., & Van Geldere, D. (2009). Bilateral round ligament varicosities mimicking inguinal hernia during pregnancy. *Hernia*, 13(1), 85-88.
<https://doi.org/10.1007/s10029-008-0395-8>

Copyright

Other than for strictly personal use, it is not permitted to download or to forward/distribute the text or part of it without the consent of the author(s) and/or copyright holder(s), unless the work is under an open content license (like Creative Commons).

The publication may also be distributed here under the terms of Article 25fa of the Dutch Copyright Act, indicated by the "Taverne" license. More information can be found on the University of Groningen website: <https://www.rug.nl/library/open-access/self-archiving-pure/taverne-amendment>.

Take-down policy

If you believe that this document breaches copyright please contact us providing details, and we will remove access to the work immediately and investigate your claim.

Downloaded from the University of Groningen/UMCG research database (Pure): <http://www.rug.nl/research/portal>. For technical reasons the number of authors shown on this cover page is limited to 10 maximum.

Bilateral round ligament varicosities mimicking inguinal hernia during pregnancy

F. F. A. Ijpma · K. M. Boddeus · H. H. de Haan ·
D. van Geldere

Received: 5 February 2008 / Accepted: 13 May 2008 / Published online: 2 July 2008
© Springer-Verlag 2008

Abstract Round ligament varicosities during pregnancy have not been reported extensively. The swelling mimics an inguinal hernia and should be considered in the differential diagnosis of a groin swelling during pregnancy. We report a case of a pregnant woman with bilateral round ligament varicosities. At 22 weeks of pregnancy she was operated on based on the clinical suspicion of a painful inguinal hernia on the right side. Surgical exploration revealed varicosities of the round ligament, and resection was performed. Four weeks later the same diagnosis was made by duplex sonography of a painful swelling in the left groin. Increased pain necessitated surgical exploration and resection of the varicosities on the left side. The postoperative course on both sides was uneventful and without pain during the rest of her pregnancy, during labor or post partum.

Keywords Round ligament varicosities · Round ligament · Varicosities · Inguinal hernia · Pregnancy

Introduction

Round ligament varicosities (RLV) have not been reported extensively [1–11]. They may appear as a reducible inguinal mass during pregnancy and might easily be mistaken for an inguinal hernia. Clinical distinction between the two is difficult. We report a case of bilateral RLV during preg-

nancy. This case highlights the importance of including RLV in the differential diagnosis of a groin swelling occurring during pregnancy.

Case report

A 29-year-old healthy woman presented with a painful swelling in the right groin during her third pregnancy. Her first pregnancy had been uneventful. Starting in the 14th week of her second pregnancy she experienced some tenderness and a mild swelling in the right groin. She consulted a general practitioner, who advised a wait-and-see policy under the provisional diagnosis “inguinal hernia”. Vaginal delivery of her second child was uncomplicated and after delivery both tenderness and swelling in the right groin resolved spontaneously. Starting in the 8th week of her third pregnancy, she noticed the same swelling in the right groin, which became gradually more painful. Therefore, she visited our surgical outpatient clinic in the 19th week of pregnancy.

At physical examination she had a soft, painful swelling in the superficial inguinal ring of the right groin with a diameter of 5 cm. This mass was completely reducible by soft digital pressure. Cough impulse led to enlargement of the groin swelling. General examination was unremarkable, with a normal uterine size for the duration of pregnancy and no signs of bowel obstruction. No vulvar or lower leg varicosities were observed. Under the provisional clinical diagnosis “symptomatic inguinal hernia,” surgical exploration of the right groin was performed in week 22 of pregnancy. Under spinal anesthesia, an oblique inguinal incision was made, dividing the external aponeurosis. To our surprise a mass of blue varicose veins arising from the round ligament was exposed (Fig. 1). The round ligament, including its varicose

F. F. A. Ijpma (✉) · K. M. Boddeus · D. van Geldere
Department of Surgery, Isala Clinics,
P.O. Box 10400, 8000 GK Zwolle, The Netherlands
e-mail: f.f.a.ijpma@isala.nl

H. H. de Haan
Department of Gynaecology, Isala Clinics,
P.O. Box 10400, 8000 GK Zwolle, The Netherlands

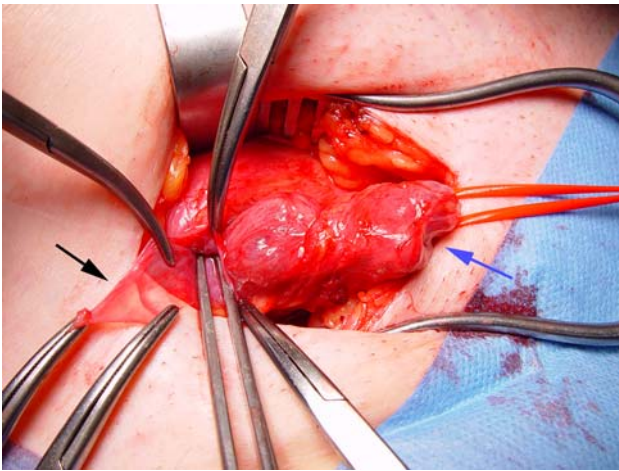
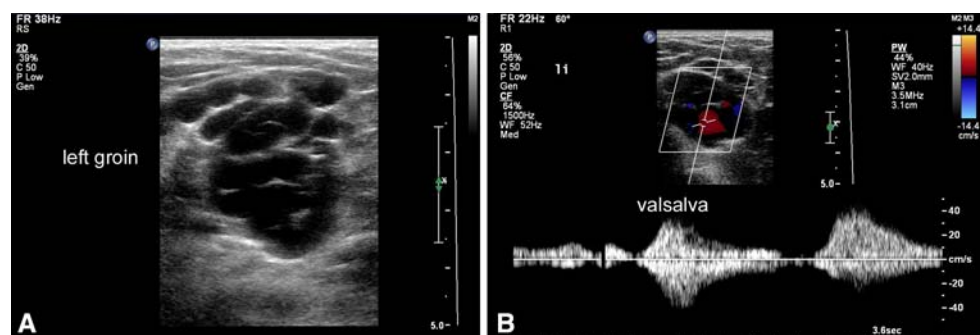


Fig. 1 Oblique incision in the right groin, exposing varicose veins in the inguinal canal arising from the round ligament (*blue arrow*). The *black arrow* indicates a small empty indirect hernia sac, with the tip of a forceps passing in the internal inguinal ring

veins, was ligated and excised. A very small indirect hernia sac was found to be empty; this peritoneal protrusion was ligated and excised as well. Histology revealed RLV without any rupture or thrombosis. Two weeks after surgery she visited the outpatient clinic and reported complete recovery of the painful sensation and swelling in the right groin.

However, a similar painful swelling in the left groin had emerged. Physical examination was comparable to the previous swelling on the right side. Duplex sonography revealed multiple dilated varicose veins within and around the round ligament, extending from the internal inguinal ring through the inguinal canal to the external inguinal ring (Fig. 2). The varicose veins were compressible and enlarged with increased intra-abdominal pressure. Duplex imaging detected minimal venous flow at rest with flow augmentation and enlargement of the veins during Valsalva maneuver. Neither signs of thrombosis or venous rupture, nor the presence of an inguinal hernia were observed. An identical operation on the left side was undertaken for pain relief in week 26 of pregnancy, again with ligation and excision of the round ligament and its varicose veins. No hernia sac was present (Fig. 3).

Fig. 2 Duplex sonography of the left groin demonstrating multiple dilated veins in the inguinal canal (**a**), and dilatation and marked flow augmentation in the veins during Valsalva maneuver (**b**)



At follow-up after 4 weeks the patient reported a fast and complete recovery, without relapse of the swelling in the left groin. At 40 weeks of pregnancy, she went into spontaneous labor and experienced an uncomplicated vaginal delivery of a healthy boy. She reported no complaints or recurrence of an inguinal swelling at physical examination at 6 weeks post partum.

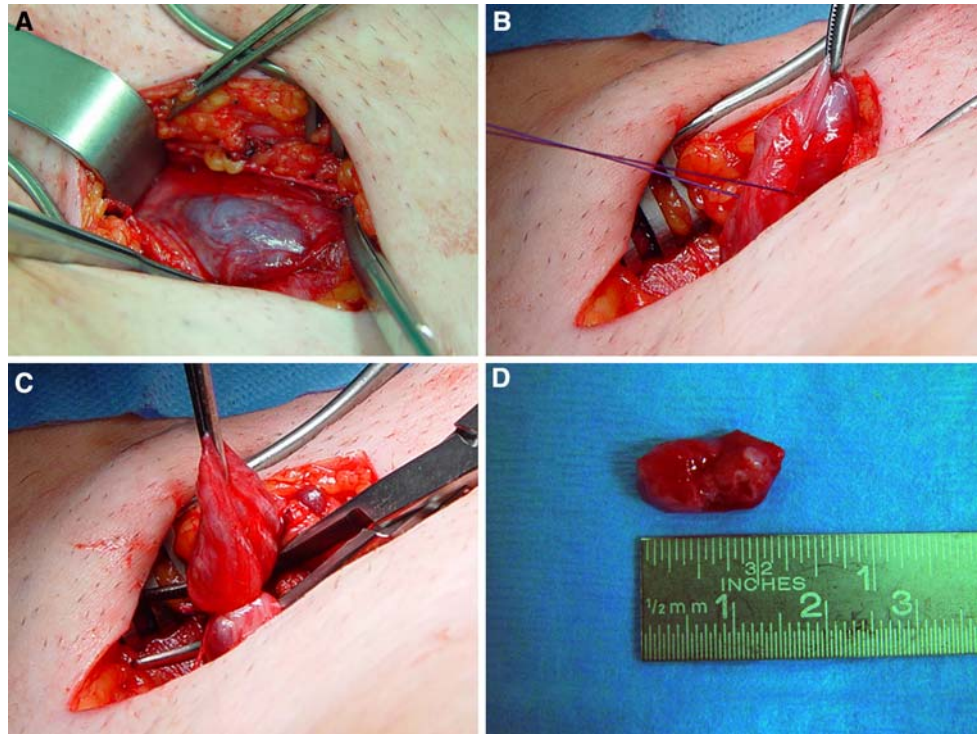
Discussion

We report a unique presentation of bilateral RLV during pregnancy, for which our patient needed to be operated on twice during pregnancy, with a successful relief of complaints. RLV during pregnancy can easily be mistaken for an inguinal hernia [1, 3, 6, 8, 9]. The incidence of RLV in pregnancy is unknown. It has been reported in some case reports and is probably an underdiagnosed phenomenon [1–11].

The most common diagnosis of a groin swelling is an inguinal hernia. However, inguinal hernias during pregnancy are relatively rare, with a reported incidence of 1 in 1,000–3,000 pregnant women [12]. A hernia of the inguinal region appearing for the first time during pregnancy is uncommon because most of the intra-abdominal structures that could potentially fill the hernia sac will be pushed aside by a growing uterus [1]. Even pre-existing hernias could temporarily disappear during pregnancy because the enlarged uterus pushes the intestines away from the inguinal canal and blocks the internal inguinal ring [1]. Varicosities of the round ligament can easily be mistaken for an inguinal hernia because they share the same clinical appearance [1–10]. Other considerations in the differential diagnosis for an inguinal mass include femoral hernia, persistent embryonic remnants of the process vaginalis with cyst formation (cyst of Nuck), lymphadenopathy, vascular aneurysm, soft tissue malignancies, abscess formation, extragenital endometriosis, and subcutaneous lipoma.

Varicosities of the lower legs are observed in 50% of the female general population [13, 14]. Pregnancy is considered a risk factor for the presence of varicosities [13]. In approximately 20–30% of pregnant women with varicose

Fig. 3 Oblique incision in the left groin exposing varicosities of the round ligament (**a**), followed by surgical exploration (**b**), and ligation of the round ligament with its varicose veins (**c**). The excised specimen is shown in **d**



veins of the lower extremities, coexistent varicose veins of the vulva and medial part of the upper thigh exist because of pelvic venous insufficiency [15]. Whilst other pelvic varicosities are usually not discovered, those of the round ligament can be diagnosed because of the superficial anatomic location of the ligament in the inguinal canal [3]. In most women, disappearance of the varicose veins will occur after delivery [2, 4, 5]. Although in the present case symptoms of RLV disappeared after the second pregnancy, progression of symptoms occurred in the third pregnancy, to the point of necessitating surgery.

The round ligament of the uterus, also known as the ligamentum teres uteri, originates at both uterine horns. It leaves the pelvis via the deep inguinal ring, passes through the inguinal canal, and continues to the labium majum. The venous plexus of the round ligament is associated with the uterine pelvic veins. However, communication with the great saphenous vein has also been described [6]. Several mechanisms contribute to varicose vein formation of the round ligament during pregnancy, including progesterone-mediated venous smooth muscle relaxation, a raised cardiac output causing increased venous return from the limbs leading to engorgement of venous tributaries, and most important, pelvic venous obstruction by the gravid uterus [2].

At physical examination, inguinal hernia and varicosities of the round ligament are difficult to distinguish. The presentation usually includes swelling and tenderness in the groin region, which can be provoked by increased intra-

abdominal pressure in case of coughing or weight lifting. In both conditions, the swelling is reducible in uncomplicated cases or irreducible in complicated cases [4]. Similar to inguinal hernias, RLV can transmit cough impulses because increased abdominal pressure will lead to vein distension [2, 4]. A clue that might suggest RLV is the coexistence of vulvar or lower limb varicosities [2, 4]. Our case, however, demonstrates that the absence of varicose veins elsewhere does not exclude varicosity of the round ligament.

Duplex sonography may lead to the right diagnosis [2, 5, 16]. The characteristic ultrasound appearance includes a prominent venous plexus with accompanying dilated draining veins and the typical “bag of worms” appearance of smaller veins [4, 16]. Duplex imaging can confirm venous flow and augmentation of this flow with Valsalva maneuver [7].

In case of an asymptomatic reducible groin mass based on RLV, a wait-and-see policy is justified [1]. Moreover, after delivery, spontaneous resolution is expected in most cases [2, 4, 5]. A symptomatic reducible groin mass may produce a variety of symptoms ranging from a mild tenderness to a more painful sensation in the groin. In these circumstances duplex sonography is mandatory, because getting the right diagnosis contributes to the therapeutic management. Duplex sonography can help in differentiating RLV from other causes of groin swelling in pregnancy, and unnecessary surgical exploration may therefore be avoided.

RLV might be treated with a truss, although to our best knowledge this has not been described anywhere. Depending on the severity of symptoms and the additional diagnostic

information from duplex sonography the optimal management of either a wait-and-see policy (with or without a truss) or surgical treatment should be determined. In our case a painful reducible groin mass based on RLV was initially misdiagnosed as an inguinal hernia and led to subsequent surgical exploration of the right groin. However, surgical treatment resulted in pain relief and complete satisfaction of our patient. In the left groin, “RLV without rupture or thrombosis” was preoperatively diagnosed by duplex sonography. Nevertheless, we proceeded to surgical treatment to reduce pain and discomfort for the remainder of pregnancy, eventually with a good result.

Even though these varicosities may be a self-limiting disease, surgical exploration and excision of the varicose veins is sometimes mandatory. A painful irreducible inguinal mass requires immediate surgical exploration. Rupture and thrombosis of the varicose round ligament may occur and give an intense painful groin swelling mimicking a strangulated inguinal hernia [1, 8–10]. In these circumstances, emergency surgical exploration is recommended, first of all to rule out a strangulated hernia, and secondly to reduce pain or discomfort caused by the inguinal mass [9]. Persistence and discomfort of varicosities of the round ligament can also be a reason for surgical treatment when spontaneous resolution does not occur postnatally [7].

By increasing awareness of RLV as part of the differential diagnosis of an inguinal mass during pregnancy, by highlighting the importance of duplex sonography examination, and by discussing all therapeutic options, we hope this condition will be recognized earlier and treated optimally.

References

1. Tomkinson JS, Winterton WR (1955) Varicoceles of the round ligament in pregnancy, simulating inguinal herniae. *Br Med J* 1:889–890
2. Cheng D, Lam H, Lam C (1997) Round ligament varices in pregnancy mimicking inguinal hernia: an ultrasound diagnosis. *Ultrasound Obstet Gynecol* 9:198–199
3. Guillem P, Bounoua F, Duval G (2001) Round ligament varicosities mimicking inguinal hernia: a diagnostic challenge during pregnancy. *Acta Chir Belg* 101:310–311
4. Chi C, Taylor A, Munjuluri N, Abdul-Kadir R (2005) A diagnostic dilemma: round ligament varicosities in pregnancy. *Acta Obstet Gynecol Scand* 84:1126–1127
5. Pilkington SA, Rees M, Jones O, Green I (2004) Ultrasound diagnosis of round ligament varicosities mimicking inguinal hernias in pregnancy. *Ann R Coll Surg Engl* 86:400
6. Egan JJ (1967) Varicocele of the round ligament. *J Ir Med Assoc* 60:472–473
7. Nguyen QH, Gruenewald SM (2007) Doppler sonography in the diagnosis of round ligament varicosities during pregnancy. *J Clin Ultrasound* doi:10.1002/jcu.20399.
8. Al-Qudah MS (1993) Postpartum pain due to thrombosed varicose veins of the round ligament of the uterus. *Postgrad Med J* 69:820–821
9. Buxton N, Boulougouris P, Pai KP, Morgan RH, Menon V (1994) Immediate post partum thrombosis of the veins of the round ligament imitating an irreducible inguinal hernia. *Acta Obstet Gynecol Scand* 73:514–515
10. Blanda F (1969) Rupture of varicose veins of the round ligament in pregnancy, simulating a strangulated hernia. *Minerva Ginecol* 21:48–50
11. Minchin E (1970) Varicose vein incompetence through the round ligaments. *Med J Aust* 2:177–179
12. Barber HRK, Garber EA (1974) Editorial comments on Kessler HJ. In: Barber HRK, Garber EA (eds) *Hernias in pregnancy. Surgical disease in pregnancy*. WB Saunders, Philadelphia, p 165
13. Carpentier PH, Maricq HR, Biro C, Ponçot-Makinen CO, Franco A (2004) Prevalence, risk factors, and clinical patterns of chronic venous disorders of lower limbs: a population-based study in France. *J Vasc Surg* 40:650–659
14. Callam MJ (1994) Epidemiology of varicose veins. *Br J Surg* 81:167–173
15. van der Plas LG, van Vliet A, Bousema MT, Sanders CJ, Mali WP (2005) Women with pelvic complaints and atypical varicose veins, varicose veins of the vulva and insufficiency of the pelvic veins; treatment with embolisation. *Ned Tijdschr Geneesk* 149:1364–1365
16. Frede TE (1984) Ultrasonic visualisation of varicosities in the female genital tract. *J Ultrasound Med* 3:365–369