

University of Groningen

Are eponyms used correctly or not?

Somford, Matthijs Paul; Nieuwe Weme, Rebecca A; van Dijk, Cornelis Niek; IJpma, Frank Fa; Eygendaal, Denise

Published in:
Evidence-Based Medicine

DOI:
[10.1136/ebmed-2016-110453](https://doi.org/10.1136/ebmed-2016-110453)

IMPORTANT NOTE: You are advised to consult the publisher's version (publisher's PDF) if you wish to cite from it. Please check the document version below.

Document Version
Publisher's PDF, also known as Version of record

Publication date:
2016

[Link to publication in University of Groningen/UMCG research database](#)

Citation for published version (APA):

Somford, M. P., Nieuwe Weme, R. A., van Dijk, C. N., IJpma, F. F., & Eygendaal, D. (2016). Are eponyms used correctly or not? A literature review with a focus on shoulder and elbow surgery. *Evidence-Based Medicine*, 21(5), 163-171. <https://doi.org/10.1136/ebmed-2016-110453>

Copyright

Other than for strictly personal use, it is not permitted to download or to forward/distribute the text or part of it without the consent of the author(s) and/or copyright holder(s), unless the work is under an open content license (like Creative Commons).

The publication may also be distributed here under the terms of Article 25fa of the Dutch Copyright Act, indicated by the "Taverne" license. More information can be found on the University of Groningen website: <https://www.rug.nl/library/open-access/self-archiving-pure/taverne-amendment>.

Take-down policy

If you believe that this document breaches copyright please contact us providing details, and we will remove access to the work immediately and investigate your claim.

Downloaded from the University of Groningen/UMCG research database (Pure): <http://www.rug.nl/research/portal>. For technical reasons the number of authors shown on this cover page is limited to 10 maximum.



Are eponyms used correctly or not? A literature review with a focus on shoulder and elbow surgery

Matthijs Paul Somford,¹ Rebecca A Nieuwe Weme,² Cornelis Niek van Dijk,³ Frank FA Ijpma,⁴ Denise Eygendaal⁵

10.1136/ebmed-2016-110453

¹Department of Orthopaedic Surgery, Ziekenhuis Rijnstate, Arnhem, Gelderland, The Netherlands

²Department of General surgery, Isala Clinics, Zwolle, The Netherlands

³Department of Orthopedic surgery, AMC Ziekenhuis, Amsterdam, The Netherlands

⁴Department of Surgery, University Medical Center Groningen, Groningen, The Netherlands

⁵Department of Orthopedic surgery, Amphia Ziekenhuis, Breda, North Brabant, The Netherlands

Correspondence to:

Dr Matthijs Paul Somford, Department of Orthopaedic Surgery, Ziekenhuis Rijnstate, Arnhem, Gelderland 9728 NT, The Netherlands; mp_somford@hotmail.com

Abstract

Background Eponymous terms are used frequently in daily patient care and scientific literature. They remind us of our predecessors in surgery. It is debatable whether eponymous terms are reliable in case of information transfer. The aim of our study was to investigate whether the original meaning of eponymous terms in shoulder and elbow surgery has been preserved in its use in contemporary literature.

Objective To evaluate whether eponymous terms were used correctly, we analysed the use of frequently encountered eponymous terms from January to December 2014.

Study selection By means of a PubMed search, articles with eponymous terms were identified and analysed for the way an eponymous term was used, and we compared it with the original description. The original description was traced back to the index publication. The use of the eponymous term was scored as similar, divergent or undefined. In the search for eponymous terms, we included those eponymous terms that were used more than 10 times in the English, German and Dutch literature of 2014. 6 eponymous terms were eligible for analysis: Bankart lesion, Bristow-Latarjet procedure, Essex-Lopresti injury of the forearm, Galeazzi fracture, Hill-Sachs lesion and Monteggia fracture.

Findings We analysed 96 articles with the listed eponymous terms, of which 27 (28%) were scored divergent, 32 (33%) undefined and 37 (39%) similar. Bristow-Latarjet scored lowest, with 0% descriptions similar to the original, meaning that all articles had an undefined or divergent eponym, and Essex-Lopresti scored highest with 82% similarity.

Conclusions Eponymous terms in shoulder and elbow trauma and surgery are used inadequately and inconsistently. The use of eponymous terms probably cannot be avoided, but since the majority of eponymous terms are not used properly and understanding of its meaning and content varies from surgeon to surgeon, we should be keen on explaining the meaning of eponymous terms when using them.

Introduction

When the name of an inventor or discoverer is used to describe a condition, procedure or fracture it is called an eponymous term and the namegiver becomes an eponym. Eponymous terms recognise some of the pioneers in the field. In contrast with an anatomical or developmental description, the original meaning of an eponymous term may have been lost over time. New insights in pathology, pathoanatomy and trauma mechanisms can make the use of historical eponymous terms inappropriate. Adaptations of the original

meaning might develop over time and may lead to improper use and understanding of eponymous term. With time, insights into and development of new techniques for diagnosis and operative care change. This can result in modification of eponymous terms.

New nomenclature may even become more appropriate than the historical eponymous term. We are all aware of the need to speak the same language in order to avoid misinterpretation and errors. It is under debate whether eponymous terms contribute to avoid confusion. Misspelling of an eponymous term may make publications on a subject untraceable. This is especially the case with foreign names or words that are used in the English-language literature and vice versa.

With our current research, we tried to establish whether eponymous terms are still used in current literature and whether their original meaning was used.

Materials and methods

To establish whether eponymous terms are correctly used in current literature, 12 common eponymous terms for traumatic conditions of shoulder and elbow were selected (table 1) on a consensus basis by a committee of experts in the field of upper extremity injuries. A PubMed search was conducted to find articles that used the eponymous terms. The search was limited to journal publication dates between 1 January 2014 and 1 January 2015. Possibly misspelled eponymous terms were included in the search, as were eponymous terms with 10 or more hits. This resulted in six eponymous terms that were eligible for our study. Languages were limited to English, German and Dutch. Systematic literature reviews were excluded. Current concept articles were not excluded.

For the six selected eponymous terms, the original description was traced by means of historical research. The search was conducted by backtracking references up to the original description or analysis of textbooks written by the person whose eponymous term is discussed. After identifying the index publication, the sentence or passage on which the eponymous term is based was carefully identified and used to compare it with the current articles.

On identification, the articles were analysed for the description of the eponymous term itself and then compared with the description in the original publication. This was done by three authors. When the authors were not unanimous, consensus was met after discussion on the score given. If the description in current articles did not meet the original one, the article was scored as 'divergent'; if there was no clear description of the eponymous term, it was scored as 'undefined'. If the description was the same as the original manuscript, it was scored 'similar'. In case that the authors chose to

use a modification of the eponymous term but stated the original meaning in their material and methods, the article was scored as 'similar' too. No analysis was done to ascertain the quality of research or to interpret the outcomes of the articles. The six eponymous terms selected are (table 1 and figure 1) as follows:

- ▶ Bankart (also Bankert) lesion, excluding 'Bankart procedure' and 'bony Bankart'
- ▶ Bristow-Latarjet (also Laterjet) procedure
- ▶ Essex-Lopresti injury of the forearm
- ▶ Galeazzi (also Galeazi) fracture
- ▶ Hill-Sachs lesion, excluding reverse Hill-Sachs
- ▶ Monteggia (also Montegia) fracture

From the original publications, these eponymous terms are defined as follows:

- ▶ The *Bankart lesion* (Arthur Sidney Blundell Bankart, 1879–1951) is a detachment of the glenoid ligament from the anterior margin of the glenoid cavity after anterior glenohumeral injury.¹ It should be noted that 'bony Bankart' is an interesting term, as Bankart wrote explicitly that he never had seen recurrent dislocation after glenoid fracture or bony abnormality.¹ Therefore the 'bony Bankart' is excluded from our analysis.
- ▶ The *Bristow-Latarjet procedure* (Walter Rowley Bristow, 1882–1947, and Michel Latarjet, 1919–1999) is a difficult eponymous term, since it comprises two surgical procedures that are very much alike but not the same. The distinctive similarity between the Bristow and Latarjet procedures is the use of the coracoid for anterior shoulder stabilisation. Bristow used only the tip of the coracoid and fixed the conjoined tendon to a slit in the subscapular muscle with sutures, as described by Helfet in 1958.² Latarjet used the whole coracoid and fixed it with one screw, and raved the anterior shoulder capsule, as he described in 1958.³ Only stating 'coracoid transposition' is not specific enough to establish the exact technique used, so the articles using this description were scored as 'undefined'.
- ▶ The *Essex-Lopresti injury* (Peter Gordon Essex-Lopresti, 1915–1951) of the forearm was described in 1951 as a comminuted radial head

fracture with dislocation of the distal radioulnar joint and disruption of the interosseous membrane.⁴

- ▶ *Galeazzi* (Riccardo Galeazzi, 1891–1961) in his original articles from 1934 and 1935 described a fracture of the radius with dislocation of the distal radioulnar joint.^{5 6} This fracture came to bear his name.
- ▶ *Hill and Sachs* (Harold Arthur Hill, 1901–1973, and Maurice David Sachs 1909–1987) described in 1940 a distinctive defect in the humeral head after anterior shoulder dislocation. It is a compression fracture that shows four specific characteristics radiologically: (1) It is at the posterolateral location of the humeral head; only very large defects extend into the greater tuberosity. (2) In external rotation the defect is subtle and often overlooked. (3) The indentation is best seen with the arm in internal rotation and presents as a dense line of 'condensation'. (4) An avulsed fragment from the humerus is practically never present; there may be a small chip from the inferior portion of the glenoid rim.⁷ Since Hill and/or Sachs did not describe the reversed type of this lesion, articles on this subject were excluded.
- ▶ *Monteggia* (Giovanni Battista Monteggia, 1762–1815) described in 1814 a fracture of the proximal third of the ulna combined with an anterior dislocation of the radial head at the proximal radioulnar joint.⁸ A fracture at any site of the ulna with any kind of proximal radial dislocation was described by Hamilton and Malgaigne, but the majority of these fractures are not by definition a Monteggia fracture.⁹

Results

Bankart lesion

Initial search with the keywords 'Bankart lesion' and 'Bankert lesion' produced 40 hits in PubMed, and after exclusion of abstract and full text, 24 were included for final analysis (graph 1).^{10–33} The excluded articles were in a different language (two Spanish, one Czech), reported on Bankart repair (3) or bony Bankart lesions (6) or were systematic reviews (4). Nine (37%) articles did not clearly define a Bankart lesion. Four (17%) descriptions were divergent, and the remaining 11 (46%) had a description similar to the original one (table 2).

Bristow-Latarjet procedure

Initial search with the keywords 'Bristow-Latarjet procedure' and 'Bristow-Latarjet procedure' produced 11 hits in PubMed, and after exclusion of abstract and full text, 8 remained for final analysis (graph 1).^{28 34–40} The excluded articles were systematic reviews. Two (25%) articles did not clearly define a Bristow-Latarjet procedure. Six (75%) descriptions were divergent and none had a description similar to the original one (table 3).

Essex-Lopresti injury of the forearm

Initial search with the keywords 'Essex-Lopresti injury of the forearm' produced 12 hits in PubMed, and after exclusion of abstract and full text, 11 remained for final analysis (graph 1).^{41–51} The excluded article was a letter to the editor. One (9%) article did not clearly define an Essex-Lopresti injury. One (9%) description was divergent, and the remaining nine (82%) had a description similar to the original one (table 4).

Table 1 Search results

Eponym/PubMed search term	PubMed hits in 2014
Bankart (Bankert) lesion	40
Bristow-Latarjet (Laterjet) procedure	11
Essex-Lopresti forearm injury	12
Eden-Hybbinette (Hybinette) procedure	1
Galeazzi (Galeazi) fracture	11
Hill-Sachs lesion	31
Kaplan approach elbow	1
Kocher incision elbow	1
Lewis-Holstein fracture	0
Monteggia (Montegia) fracture	23
Perthes shoulder	0
Volkman contracture forearm	4

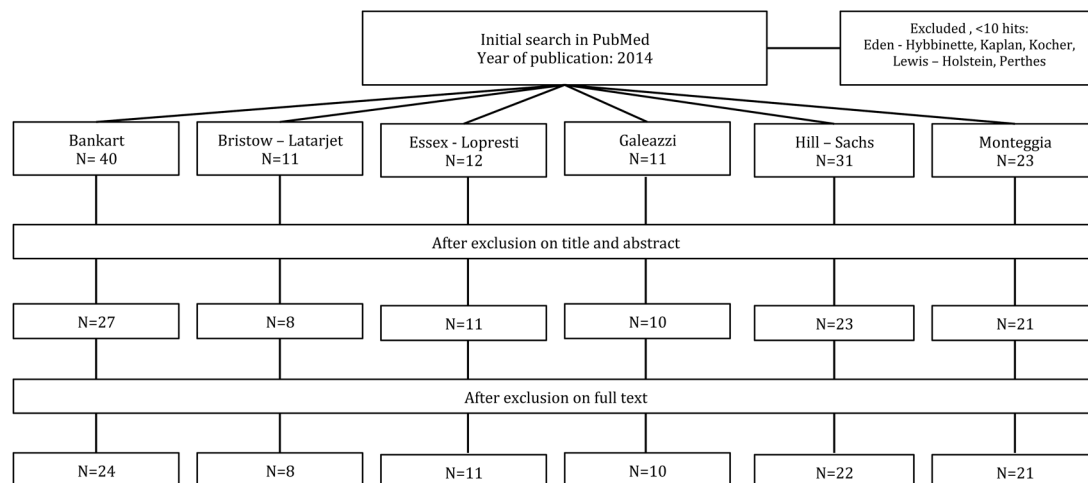


Figure 1 Flowchart depicting the process of article selection.

Table 2 Bankart (Bankert) lesion (articles used after exclusion criteria: 24)

First author	Journal	Description of eponym (s/d)
Armangil ¹⁰	<i>Acta Orthop Traumatol Turc</i>	Glenoid labrum tear (d)
Forsythe ¹¹	<i>Arthroscopy</i>	Undefined
Burt ¹²	<i>Arthrosc Tech</i>	Undefined
Kephart ¹³	<i>J Shoulder Elbow Surg</i>	Undefined
Shields ¹⁴	<i>Am J Sports Med</i>	Undefined
Ozaki ¹⁵	<i>Am J Sports Med</i>	Undefined
Belangero ¹⁶	<i>Rev Bras Ortop</i>	Undefined
Burks ¹⁷	<i>Arthroscopy</i>	Undefined
Dumont ¹⁸	<i>Clin Sports Med</i>	Detachment of the anteroinferior labrum (s)
Bernhardson ¹⁹	<i>Am J Sports Med</i>	Anterior labral injury with an avulsed labrum and a ruptured periosteum(s)
Larribe ²⁰	<i>Semin Musculoskelet Radiol</i>	Injury of the anteroinferior attachment of the labrum to the glenoid rim (s)
Yamamoto ²¹	<i>Am J Sports Med</i>	Labral tissue dissected from the anterior glenoid rim from the 12 o'clock to 6 o'clock position (s)
Guermazi ²²	<i>Eur J Radiol</i>	Detached labroligamentous complex from the anterior glenoid (s)
Edmonds ²³	<i>J Child Orthop</i>	Anteroinferior (3–6 o'clock) labral tears (s)
Zhu ²⁴	<i>Eur J Ortho Surg Traumatol</i>	Fibrocartilage tear of the anteroinferior edge of the glenoid, periosteum displaced along the front of the scapular neck (d) (this a Perthes lesion)
Argintar ²⁵	<i>Knee Surg Sports Traumatol Arthrosc</i>	Labrum detachment of the glenoid rim from 2–6 o'clock (s)
Wolf ²⁶	<i>J Shoulder Elbow Surg</i>	Undefined
Grimberg ²⁷	<i>Knee Surg Sports Traumatol Arthrosc</i>	Lesion from the 3–6 o'clock position (s)
Streubel ²⁸	<i>J Am Acad Orthop Surg</i>	Anteroinferior detachment of the glenoid labrum; this can be either a soft-tissue or a bony avulsion (d)
Witney-Lagen ²⁹	<i>J Shoulder Elbow Surg</i>	Undefined
Moran ³⁰	<i>Arthrosc Tech</i>	Anteroinferior capsulolabral detachment (s)
Horst ³¹	<i>Br J Radiol</i>	Labrum or glenoid damage (d)
Guity ³²	<i>Med J Islam Repub Iran</i>	Anteroinferior glenoid soft tissue detachment (s)
Tudisco ³³	<i>Open Orthop J</i>	Detachment of anterior labrum (s)

d, divergent; s, similar.

Galeazzi fracture

Initial search with the keywords ‘Galeazzi fracture’ and ‘Galeazi fracture’ produced 11 hits in PubMed, and after exclusion of abstract and full text, 10 remained for final analysis (graph 1).^{52–61} The excluded article was in a different language (French). Four (40%) articles did not clearly define a Galeazzi fracture. One (10%) description

was divergent, and the remaining five (50%) had a description similar to the original one (table 5).

Hill-Sachs lesion

Initial search with the keywords ‘Hill-Sachs lesion’ produced 31 hits in PubMed, and after exclusion on

Table 3 Bristow-Latarjet (Laterjet) procedure (articles used after exclusion criteria: 8)

First author	Journal	Description of eponym (s/d)
Sakeb ³⁴	<i>Mymensingh Med J</i>	Open coracoid bone transfer (d)
Nourissat ³⁵	<i>Orthop Traumatol Surg Res</i>	Transferring the coracoid process, lying down or standing on the anteroinferior aspect of the glenoid, fixed with 1 screw (d)
Giles ³⁶	<i>J Bone Joint Surg Am</i>	The Bristow procedure transfers only the tip of the coracoid, fixed with a screw. The Latarjet procedure transfers the entire horizontal pillar, fixed with 2 screws (d)
Boileau ³⁷	<i>Clin Orthop Relat Res</i>	Coracoid bone block is fixed either in the standing position with 1 screw (Bristow procedure) or in the lying position with 2 screws (Latarjet procedure) (d)
Sastre ³⁸	<i>Knee Surg Sports Traumatol Arthrosc</i>	Undefined
Streubel ²⁸	<i>J Am Acad Orthop Surg</i>	Latarjet: Coracoid is osteotomised at its base and transferred so that its longitudinal axis is oriented parallel to the face of the glenoid (fixation not stated) (d) Bristow: undefined (Total scored as undefined)
de Figueireido ³⁹	<i>BMJ Case Rep</i>	Technique with grafts that are removed from the coracoid process and fixed in the anterior margin of the glenoid with 2 screws (d)
Willems ⁴⁰	<i>Curr Rev Musculoskelet Med</i>	Undefined

d, divergent; s, similar.

Table 4 Essex-Lopresti injury of the forearm (articles used after exclusion criteria: 11)

First author	Journal	Description of eponym (s/d)
Martínez Vílén ⁴¹	<i>Chir Main</i>	Longitudinal forearm instability due to loss of humeroradial support, with proximal radial migration and ulnar impaction syndrome (d)
Grassmann ⁴²	<i>Bone Joint J</i>	Fracture of the radial head with shortening of the radius, disruption of the interosseous membrane and dislocation of the distal radioulnar joint (s)
Erickson ⁴³	<i>Pol Orthop Traumatol</i>	Combined radial head fracture, distal radioulnar joint dislocation/subluxation, and longitudinal tear of the forearm interosseous membrane (s)
Baghdadi ⁴⁴	<i>Clin Orthop Relat Res</i>	Undefined
Venouziou ⁴⁵	<i>J Shoulder Elbow Surg</i>	Radial head fracture, interosseous membrane rupture, and distal radioulnar joint disruption (s)
Elamrani ⁴⁶	<i>Surg Radiol Anat</i>	Radial head fracture (generally comminuted); DRU joint dislocation and tear of all the radioulnar ligaments, including the antebrachial interosseous membrane (s)
Wegmann ⁴⁷	<i>Acta Orthop</i>	Fracture of the radial head, rupture of the interosseous membrane and disruption of the distal radioulnar joint (s)
McGinley ⁴⁸	<i>Hand (N Y)</i>	Comminuted radial head fracture associated with longitudinal forearm instability (s)
Brin ⁴⁹	<i>Tech Hand Up Extrem Surg</i>	Fracture of the radial head, rupture of the interosseous membrane and dislocation of the distal radioulnar joint (s)
Hernández-Cortés ⁵⁰	<i>Acta Orthop Traumatol Turc</i>	Injury disrupting the radial head, interosseous membrane and distal radioulnar joint (s)
Loeffler ⁵¹	<i>J Hand Surg Am</i>	Radial head fracture, interosseous membrane rupture and distal radioulnar joint disruption (s)

d, divergent; s, similar.

Table 5 Galeazzi (Galeazi) fracture (articles used after exclusion criteria: 10)

First author	Journal	Description of eponym (s/d)
Gould ⁵²	<i>J Hand Surg Eur</i>	Complete palmar displacement of the distal radial epiphysis and greenstick fracture of the distal ulna (d)
Köse ⁵³	<i>Arch Orthop Trauma Surg</i>	Undefined
Saka ⁵⁴	<i>Eur J Orthop Surg Traumatol</i>	Undefined
Sabat ⁵⁵	<i>Indian J Orthop</i>	Undefined
Nagy ⁵⁶	<i>BMJ Case Rep</i>	Distal radial fracture with volar ulnar dislocation (s)
Fillingham ⁵⁷	<i>Pol Orthop Traumatol</i>	Fracture of the radial shaft with dislocation of the distal radioulnar joint (s)
Takemoto ⁵⁸	<i>J Orthop Traumatol</i>	Fractures of the radial shaft with concomitant distal radioulnar joint dislocation (s)
Little ⁵⁹	<i>Radiographics</i>	Distal radial fractures at any level with associated dislocation of the distal radioulnar joint, resulting in ulnar luxation (s)
Fayaz ⁶⁰	<i>Handchir Mikrochir Plast Chir</i>	Fracture of the middle to distal third of the radius, associated with DRUJ dislocation and/or instability (s)
Saka ⁶¹	<i>Injury</i>	Undefined

d, divergent; DRUJ, distal radial ulnar joints; s, similar.

Table 6 Hill-Sachs lesion (articles used after exclusion criteria: 22)

First author	Journal	Description of eponym (s/d)
Ozaki ¹⁵	<i>Am J Sports Med</i>	Notch located at the posterolateral aspect of the humeral head (s)
Burks ¹⁷	<i>Arthroscopy</i>	Undefined
Patel ⁶²	<i>Orthop Clin North Am</i>	Compression fracture of the posterolateral aspect of the humeral head (s)
Zhu ²⁴	<i>Eur J Orthop Surg Traumatol</i>	Posterolateral humeral head compression fracture (s)
Argintar ²⁵	<i>Knee Surg Sports Traumatol Arthrosc</i>	Bony defect between posterior edge of the bicipital groove and the plane between the inferior margin of the infraspinatus tendon and the superior margin of the teres minor (s)
Gyftopoulos ⁶³	<i>Am J Roentgenol</i>	Impaction of the posterosuperior margin of the humeral head (s)
Omori ⁶⁴	<i>Am J Sports Med</i>	Undefined
Wolf ²⁶	<i>J Shoulder Elbow Surg</i>	Bone lesions of the posterior humeral head (s)
Agneskirchner ⁶⁵	<i>Oper Orthop Traumatol</i>	Humeral bone loss (d)
Grimberg ²⁷	<i>Knee Surg Sports Traumatol Arthrosc</i>	Osseous defects at the humeral head level (d)
Streubel ²⁸	<i>J Am Acad Orthop Surg</i>	Posteromedial impaction of the humeral head (d)
McCabe ⁶⁶	<i>Arthroscopy</i>	Undefined
Chan ⁶⁷	<i>J Surg Orthop Adv</i>	Undefined
Mohtadi ⁶⁸	<i>J Bone Joint Surg Am</i>	Undefined
Aslani ⁶⁹	<i>Arch Bone Jt Surg</i>	Bone defect in the posterolateral side of the humeral head (s)
Di Giacomo ⁷⁰	<i>Curr Rev Musculoskelet Med</i>	Bone loss of the proximal humerus (d)
Witney-Lagen ²⁹	<i>J Shoulder Elbow Surg</i>	Undefined
Magee ⁷¹	<i>Skeletal Radiol</i>	Undefined
Omi ⁷²	<i>Arthroscopy</i>	Posterolateral humeral head defects (s)
Horst ³¹	<i>Br J Radiol</i>	Impression fracture on the posterior humeral head (s)
Di Giacomo ⁷³	<i>Arthroscopy</i>	Bone loss of the proximal humerus (d)
Guity ³²	<i>Med J Islam Repub Iran</i>	Compression fracture of the posterolateral side of the humeral head (s)

d, divergent; s, similar.

abstract and full text, 22 remained for final analysis (graph 1).^{15 17 24–29 31 32 62–73} The excluded articles were in a different language (two Spanish, one Czech), reported on reverse Hill-Sachs lesions (3), or were systematic reviews (3). In total, 7 (32%) articles did not clearly define a Hill-Sachs lesion. A total of 5 (23%) descriptions were divergent, and the remaining 10 (45%) had a description similar to the original one (table 6).

Monteggia fracture

Initial search with the keywords 'Monteggia fracture' and 'Montegia fracture' produced 23 hits in PubMed, and after exclusion of abstract and full text, 21 remained for final analysis (graph 1).^{53 74–93} The excluded articles were in a different language (two Chinese). In total, 11 (52%) articles did not clearly define a Monteggia fracture. A total of 5 (24%) descriptions were divergent, and the remaining 5 (24%) had a description similar to the original one (table 7).

In total, 96 articles were analysed, of which 27 (28%) were scored divergent, 32 (33%) undefined and 37 (39%) similar.

Discussion

Although our series are small, it is the first time that the use of eponymous terms is studied in this manner. We limited our search to the year 2014 since our goal is to get a contemporary idea of the use of eponyms and we did not have the intention to do a thorough historical analysis of past use of the chosen eponymous terms. The major finding of our analysis is that the majority of

eponymous terms are not used as originally described (61%). There was a large variety in the results, but a 100% match between the original description of the eponymous term and the meaning of the same eponymous term in our study period was not found. For the Bristow-Latarjet procedure none of the recently used eponyms were in concordance with the original. The reason that 75% of the recent descriptions diverged from the original one is because of the complex nature of this eponymous term, which encompasses two techniques. By stating this in the Materials and Methods section and by referring to the used technique, it is possible to still use the eponymous. A similar description can thus be named, although using only one or maybe a variation of the technique.

The use of eponymous terms in orthopaedic surgery is a well-known mirror of our professional past. Eponymous terms commemorate the pioneers that shaped our profession the way it is practiced today, although it is possible that the eponym is not the one that first described the condition that came to bear his name. This is known as Nonoriginal Malappropriate Eponymous Nomenclature (NOMEN).⁹⁴ However, in the years following the initial description of certain conditions or surgical techniques, advancing insights changed classifications of diagnoses/pathologies and treatment algorithms. The original description might therefore no longer be appropriate. Often an addition of a 'variant' or 'modification' to the eponymous term is used to show that its meaning has been changed. This is in concordance with Ravitch's statement on eponyms that: '1) The

Table 7 Monteggia fracture (articles used after exclusion criteria: 21)

First author	Journal	Description of eponym (s/d)
Kozin ⁷⁴	<i>Instr Course Lect</i>	Undefined
Bor ⁷⁵	<i>J Pediatr Orthop</i>	Undefined
Andjelković ⁷⁶	<i>Srp Arh Celok Lek</i>	Fracture of the proximal third of the ulna with anterior dislocation of the radial head (s)
Ramirez ⁷⁷	<i>J Pediatr Orthop</i>	Undefined
Delpont ⁷⁸	<i>Orthop Traumatol Surg Res</i>	Undefined
Köse ⁵³	<i>Arch Orthop Trauma Surg</i>	Undefined
Mellema ⁷⁹	<i>J Hand Surg Am</i>	Undefined
Ray ⁸⁰	<i>J Pediatr Orthop B</i>	Radial head dislocation with plastic deformity of the ulna (d)
Ha ⁸¹	<i>BMC Res Notes</i>	Fracture of the proximal third of the ulna with associated anterior radial head dislocation (s)
Rehim ⁸²	<i>J Hand Surg Am</i>	Fracture of the shaft of the ulna accompanied by anterior dislocation of the radial head (d)
Kim ⁸³	<i>J Pediatr Orthop B</i>	Anterior dislocation of the radial head with plastic deformation of the ulna (d)
Little ⁸⁴	<i>Orthop Clin North Am</i>	Fracture of the proximal ulna with dislocation of the radial head (s)
Datta ⁸⁵	<i>J Clin Diagn Res</i>	Undefined
Williams ⁸⁶	<i>BMC Res Notes</i>	Undefined
Laratta ⁸⁷	<i>J Orthop Traumatol</i>	Elbow dislocation with concurrent radial and ulnar shaft fracture with distal radioulnar joint disruption (d)
Otsuka ⁸⁸	<i>J Pediatr Orthop B</i>	Undefined
Hagedorn ⁸⁹	<i>J Hand Surg Am</i>	Undefined
Segaren ⁹⁰	<i>Case Rep Surg</i>	Undefined
Beutel ⁹¹	<i>Int J Surg Case Rep</i>	Fracture of the proximal ulna with associated radial head dislocation (s)
Agrawal ⁹²	<i>J Pediatr Orthop B</i>	Fracture of the proximal ulna associated with anterior dislocation of the radial head (s)
Chagou ⁹³	<i>Pan Afr Med J</i>	Ulnar fracture and radial head dislocation (d)

d, divergent; s, similar.

man so honoured was not the first to describe the disease, operation or instrument; 2) He misunderstood the situation; 3) He is generally misquoted; and 4) 1, 2 and 3 are simultaneously true'.⁹⁵ This can add complexity to the scientific comparison and discussion. It is important to determine whether the definition is similar when talking, reading or writing about a condition or surgical technique. It has been shown that it might not be the case when using eponymous terms.⁹⁶

The origin of eponymous terms is diverse; it varies from citing the first or most well-known author of the original description in an article⁹⁷ or book⁹⁸ to using it to honour the person we learnt from.² Sometimes the original author himself dedicates the finding to his own name.⁹⁹ Independently of origin, eponymous terms are and will remain part of our daily routine.

Eponymous term divergence may be due to a lack of specificity in the description given in the current literature. It would take a larger group with focus on one single eponymous term to investigate this. When a new description appeared for the analysed eponymous terms, our results did not show it as being used by all the authors. Divergent descriptions can be ascribed to a variety of reasons (all tables).

The group that kept the eponymous term undefined poses difficulties. This would only be a theoretical problem if all the other descriptions were similar to the original ones, and (although scientifically it is not appropriate) we could assume that the undefined eponymous term is used similarly to the original

description. As this is not the case, we cannot be sure that the articles that did not define the meaning of the eponymous term used it correctly. This makes the research results hard to interpret and apply in our daily practice.

Systematic reviews were excluded, because they report on other (older) articles and do not necessarily use the eponymous term as a distinctive marker themselves. Although excluded for this reason, the article by Trivedi *et al*¹⁰⁰ is an interesting example of erroneous use of eponymous terms, since it states that a Bankart lesion is defined as glenoid bone loss. Their recommendations should be carefully interpreted, as a search for Bankart lesions for that review will mostly result in articles reporting on labral tears; hence, the definitive article selection should be corrected for this. It probably means that over time adaptation of the Bankart lesion has occurred. In the past, bony avulsion was referred to as a 'bony Bankart' and over time the condition was attributed to Bankart.

A limitation to our study is that we chose a time span of 1 year to search our articles in. We feel though that this results in enough articles we could analyse to answer our research question for this study. Since it was the first time this kind of study was performed, we chose to keep the limit to this time span as a form of pilot. Further studies could direct their search on a limited amount of eponymous terms from the first time they are described up until today to obtain a clear understanding of the use of the eponymous term over time.

Another limit is that the study is restricted to elbow and shoulder surgery; therefore, it might not be applicable to other specialties. The found literature on the debate, whether or not eponyms should be used, is from all kinds of specialties, so the issue seems applicable to general medicine. To research all fields of medicine in one study would be better but unrealistic in our view, since there are more than 20 000 medical eponyms.^{101 102}

We recommend describing the lesion in relation to the local (patho)anatomy or trauma mechanism since it is less prone to misinterpretation. When an eponymous structure, lesion or therapy is used, the Materials and Methods section should specify the used anatomical/pathological meaning of the eponymous term. A reference to the original description or the description used should also be given. When the description diverges from the original, it should be stated in what way the eponymous term is being used.

Conclusion

Eponymous terms in shoulder and elbow trauma and surgery are used inadequately and inconsistently. The use of eponymous terms probably cannot be avoided in scientific literature and in daily patient care, but it should be regarded with care.^{103 104} This, since the majority of eponymous terms are not used according to their original description and understanding of their meaning, differs among medics and researchers. Since eponymous terms are hard to abolish in our daily practice and an explanation on their meaning will not always be given, we propose that when used in the scientific literature, the original description or current use should be clarified. The Materials and Methods section of each article should explicitly specify the supposed meaning of the used eponymous term. Only then can we interpret the results correctly.

Contributors MPS contributed to study design, literature search, data collection, data analysis, data interpretation and manuscript writing. RANW contributed to study design, data collection, data interpretation, figures/tables preparation and correction of manuscript. CNvD contributed to writing and correction of manuscript. FFAI contributed to data interpretation, writing and correction of manuscript. DE contributed to study design, data interpretation, writing and correction of manuscript.

Competing interests None declared.

Provenance and peer review Not commissioned; externally peer reviewed.

References

- Bankart AS. Recurrent or habitual dislocation of the shoulder-joint. *Br Med J* 1923;2:1132–3.
- Helfet AJ. Coracoid transplantation for recurring dislocation of the shoulder. *J Bone Joint Surg Br* 1958;40-B:198–202.
- Latarjet M. [Technic of coracoid preglenoid arthroereisis in the treatment of recurrent dislocation of the shoulder]. *Lyon Chir* 1958;54:604–7.
- Essex-lopresti P. Fractures of the radial head with distal radio-ulnar dislocation; report of two cases. *J Bone Joint Surg Br* 1951;33B:244–7.
- Galeazzi R. Über ein besonderes Syndrom bei Verletzungen im Bereich der Unterarmknochen. *Arch Orthop Unfall-Chir* 1935;35:557–62.
- Galeazzi R. Di una particolare sindrome traumatica dello scheletro dell'avambraccio. *Atti Mem della Soc Lomb Chir* 1934;2:663–6.
- Hill H, Sachs M. The grooved defect of the humeral head: a frequently unrecognized complication of dislocations of the shoulder joint. *Radiology* 1940;35:690–700.
- Monteggia GB. Lussazioni della ossa delle estremita superiori. In: Monteggia GB, ed. *Istituzioni Chirurgiches*. Milan: Maspero, 1814:131–3.
- Bado JL. The Monteggia lesion. *Clin Orthop Relat Res*;50:71–86.
- Armangil M, Basat HÇ, Akan B, et al. Arthroscopic stabilization of anterior shoulder instability using a single anterior portal. *Acta Orthop Traumatol Turc* 2015;49:6–12.
- Forsythe B, Frank RM, Ahmed M, et al. Identification and treatment of existing copathology in anterior shoulder instability repair. *Arthroscopy* 2015;31:154–66.
- Burt DM. Arthroscopic repair of inferior labrum from anterior to posterior lesions associated with multidirectional instability of the shoulder. *Arthrosc Tech* 2014;3:e727–30.
- Kephart CJ, Abdulian MH, McGarry MH, et al. Biomechanical analysis of the modified Bristow procedure for anterior shoulder instability: is the bone block necessary? *J Shoulder Elbow Surg* 2014;23:1792–9.
- Shields E, Mirabelli M, Amsdell S, et al. Functional and imaging outcomes of arthroscopic simultaneous rotator cuff repair and Bankart repair after shoulder dislocations. *Am J Sports Med* 2014;42:2614–20.
- Ozaki R, Nakagawa S, Mizuno N, et al. Hill-Sachs lesions in shoulders with traumatic anterior instability: evaluation using computed tomography with 3-dimensional reconstruction. *Am J Sports Med* 2014;42:2597–605.
- Belangero PS, Leal MF, de Castro Pochini A, et al. Profile of collagen gene expression in the glenohumeral capsule of patients with traumatic anterior instability of the shoulder. *Rev Bras Ortop* 2014;49:642–6.
- Burks RT, Presson AP, Weng HY. An analysis of technical aspects of the arthroscopic Bankart procedure as performed in the United States. *Arthroscopy* 2014;30:1246–53.
- Dumont GD, Golijanin P, Provencher MT. Shoulder instability in the military. *Clin Sports Med* 2014;33:707–20.
- Bernhardson AS, Bailey JR, Solomon DJ, et al. Glenoid bone loss in the setting of an anterior labroligamentous periosteal sleeve avulsion tear. *Am J Sports Med* 2014;42:2136–40.
- Larribe M, Laurent PE, Acid S, et al. Anterior shoulder instability: the role of advanced shoulder imaging in preoperative planning. *Semin Musculoskelet Radiol* 2014;18:398–403.
- Yamamoto A, Massimini DF, DiStefano J, et al. Glenohumeral contact pressure with simulated anterior labral and osseous defects in cadaveric shoulders before and after soft tissue repair. *Am J Sports Med* 2014;42:1947–54.
- Guermazi A, Jomaah N, Hayashi D, et al. MR arthrography of the shoulder: optimizing pulse sequence protocols for the evaluation of cartilage and labrum. *Eur J Radiol* 2014;83:1421–8.
- Edmonds EW, Roocroft JH, Parikh SN. Spectrum of operative childhood intra-articular shoulder pathology. *J Child Orthop* 2014;8:337–40.
- Zhu W, Lu W, Zhang L, et al. Arthroscopic findings in the recurrent anterior instability of the shoulder. *Eur J Orthop Surg Traumatol* 2014;24:699–705.

25. Argintar E, Heckmann N, Wang L, *et al.* The biomechanical effect of shoulder remplissage combined with Bankart repair for the treatment of engaging Hill-Sachs lesions. *Knee Surg Sports Traumatol Arthrosc.* 2016;24:585–92.
26. Wolf EM, Arianjam A. Hill-Sachs remplissage, an arthroscopic solution for the engaging Hill-Sachs lesion: 2- to 10-year follow-up and incidence of recurrence. *J Shoulder Elbow Surg* 2014;23:814–20.
27. Grimberg J, Diop A, Ghosn RB, *et al.* Bankart repair versus Bankart repair plus remplissage: an in vitro biomechanical comparative study. *Knee Surg Sports Traumatol Arthrosc* 2016;24:374–80.
28. Streubel PN, Krych AJ, Simone JP, *et al.* Anterior glenohumeral instability: a pathology-based surgical treatment strategy. *J Am Acad Orthop Surg* 2014;22:283–94.
29. Witney-Lagen C, Perera N, Rubin S, *et al.* Fewer anchors achieves successful arthroscopic shoulder stabilization surgery: 114 patients with 4 years of follow-up. *J Shoulder Elbow Surg* 2014;23:382–7.
30. Moran CJ, Fabricant PD, Kang R, *et al.* Arthroscopic double-row anterior stabilization and Bankart repair for the 'high-risk' athlete. *Arthrosc Tech* 2014;3:e65–71.
31. Horst K, Von Harten R, Weber C, *et al.* Assessment of coincidence and defect sizes in Bankart and Hill-Sachs lesions after anterior shoulder dislocation: a radiological study. *Br J Radiol* 2014;87:20130673.
32. Guity MR, Akhlaghpour S, Yousefian R. Determination of prevalence of glenoid bony lesions after recurrent anterior shoulder dislocation using the 3-D CT scan. *Med J Islam Repub Iran* 2014;28:20.
33. Tudisco C, Bisicchia S, Savarese E, *et al.* '8 plate': an alternative device to fix highly recurrent traumatic anterior gleno-humeral instability in patients with severe impairment of the anterior capsule. *Open Orthop J* 2014;8:457–61.
34. Sakeb N, Islam MA, Jannat SN. Outcome of modified Bristow-Latarjet procedure in post-traumatic recurrent anterior shoulder dislocation in young population. *Mymensingh Med J* 2015;24:74–83.
35. Nourissat G, Delaroché C, Bouillet B, *et al.* Optimization of bone-block positioning in the Bristow-Latarjet procedure: a biomechanical study. *Orthop Traumatol Surg Res* 2014;100:509–13.
36. Giles JW, Degen RM, Johnson JA, *et al.* The Bristow and Latarjet procedures: why these techniques should not be considered synonymous. *J Bone Joint Surg Am* 2014;96:1340–8.
37. Boileau P, Thélou CÉ, Mercier N, *et al.* Arthroscopic Bristow-Latarjet combined with Bankart repair restores shoulder stability in patients with glenoid bone loss. *Clin Orthop Relat Res* 2014;472:2413–24.
38. Sastre S, Peidro L, Méndez A, *et al.* Suprascapular nerve palsy after arthroscopic Latarjet procedure: a case report and review of literature. *Knee Surg Sports Traumatol Arthrosc* 2016;24:601–3.
39. de Figueiredo EA, Belangero PS, Ejnisman B, *et al.* Complex shoulder injuries in sports. *BMJ Case Rep* 2014;2014:pii: bcr2014203661.
40. Willems WJ. Reconstruction of glenoid bone defects in shoulder instability with autologous bone. *Curr Rev Musculoskelet Med* 2014;7:12–5.
41. Martínez Villén G, García Martínez B, Aso Vizán A. Total distal radioulnar joint prosthesis as salvage surgery in multioperated patients. *Chir Main* 2014;33:390–5.
42. Grassmann JP, Hakimi M, Gehrman S V, *et al.* The treatment of the acute Essex-Lopresti injury. *Bone Joint J* 2014;96-B:1385–91.
43. Erickson BJ, Fillingham YA, Cvetanovich GL, *et al.* A rare case of an Essex-Lopresti injury secondary to a gunshot wound. *Polish Orthop Traumatol* 2014;79:97–101.
44. Baghdadi YMK, Morrey BF, Sanchez-Sotelo J. Anconeus interposition arthroplasty: mid- to long-term results. *Clin Orthop Relat Res* 2014;472:2151–61.
45. Venouziou AI, Papatheodorou LK, Weiser RW, *et al.* Chronic Essex-Lopresti injuries: an alternative treatment method. *J Shoulder Elbow Surg* 2014;23:861–6.
46. Elamrani D, Aumar A, Wavreille G, *et al.* Comparative morphometry of the antebachial and crural interosseous membranes: preliminary study for the use of the crural interosseous membrane in the surgical repair of the antebachial interosseous membrane tears. *Surg Radiol Anat* 2014;36:333–9.
47. Wegmann K, Engel K, Burkhart KJ, *et al.* Sequence of the Essex-Lopresti lesion—a high-speed video documentation and kinematic analysis. *Acta Orthop* 2014;85:177–80.
48. McGinley JC, Gold G, Cheung E, *et al.* MRI detection of forearm soft tissue injuries with radial head fractures. *Hand (N Y)* 2014;9:87–92.
49. Brin YS, Palmanovich E, Bivas A, *et al.* Treating acute Essex-Lopresti injury with the TightRope device: a case study. *Tech Hand Up Extrem Surg* 2014;18:51–5.
50. Hernández-Cortés P, Gómez-Sánchez R, Pajares-López M, *et al.* Sauvé-Kapandji and reverse Sauvé-Kapandji procedures for treating chronic longitudinal radioulnar dissociation with capitellum fracture. *Acta Orthop Traumatol Turc* 2014;48:593–7.
51. Loeffler BJ, Green JB, Zelouf DS. Forearm instability. *J Hand Surg Am* 2014;39:156–67.
52. Gould FJ, Broome GHH. Extensor tendon entrapment after a Galeazzi-type paediatric fracture. *J Hand Surg Eur Vol* 2015;40:323–4.
53. Köse A, Aydın A, Ezirmik N, *et al.* Alternative treatment of forearm double fractures: new design intramedullary nail. *Arch Orthop Trauma Surg* 2014;134:1387–96.
54. Saka G, Saglam N, Kurtulmus T, *et al.* Treatment of isolated diaphyseal fractures of the radius with an intramedullary nail in adults. *Eur J Orthop Surg Traumatol* 2014;24:1085–93.
55. Sabat D, Dabas V, Dhal A. Late extensor pollicis longus rupture following plate fixation in Galeazzi fracture dislocation. *Indian J Orthop* 2014;48:426–8.
56. Nagy MT, Ghosh S, Shah B, *et al.* Delayed rupture of flexor tendons in zone V complicated by neuritis 18 years following Galeazzi fracture-dislocation. *BMJ Case Rep* 2014;2014:pii: bcr2013010188.
57. Fillingham Y, Hellman M, Haughom B, *et al.* Report of Galeazzi fracture resulting from a ballistic injury. *Polish Orthop Traumatol* 2014;79:5–9.
58. Takemoto R, Sugi M, Immerman I, *et al.* Ulnar variance as a predictor of persistent instability following Galeazzi fracture-dislocations. *J Orthop Traumatol* 2014;15:41–6.
59. Little JT, Kliksky NB, Chaturvedi A, *et al.* Pediatric distal forearm and wrist injury: an imaging review. *Radiographics* 2014;34:472–90.
60. Fayaz HC, Jupiter JB. Galeazzi fractures: our modified classification and treatment regimen. *Handchirurgie Mikrochirurgie Plast Chir* 2014;46:31–3.
61. Saka G, Saglam N, Kurtulmus T, *et al.* New interlocking intramedullary radius and ulna nails for treating forearm diaphyseal fractures in adults: a retrospective study. *Injury* 2014;45(Suppl 1):S16–23.
62. Patel RM, Amin NH, Lynch TS, *et al.* Management of bone loss in glenohumeral instability. *Orthop Clin North Am* 2014;45:523–39.
63. Gyftopoulos S, Albert M, Recht MP. Osseous injuries associated with anterior shoulder instability: what the radiologist should know. *AJR Am J Roentgenol* 2014;202: W541–50.

64. Omori Y, Yamamoto N, Koishi H, *et al.* Measurement of the glenoid track in vivo as investigated by 3-dimensional motion analysis using open MRI. *Am J Sports Med* 2014;42:1290–5.
65. Agneskirchner JD, Lafosse L. [Transfer of the coracoid process in recurrent anterior instability of the shoulder joint. The arthroscopic Latarjet procedure]. *Oper Orthop Traumatol* 2014;26:296–306.
66. McCabe MP, Weinberg D, Field LD, *et al.* Primary versus revision arthroscopic reconstruction with remplissage for shoulder instability with moderate bone loss. *Arthroscopy* 2014;30:444–50.
67. Chan CM, Farmer KW. Technique using bone wax to aid in fashioning grafts for osteochondral allografting of bony defects of humeral head. *J Surg Orthop Adv* 2014;23:49–51.
68. Mohtadi NGH, Chan DS, Hollinshead RM, *et al.* A randomized clinical trial comparing open and arthroscopic stabilization for recurrent traumatic anterior shoulder instability: two-year follow-up with disease-specific quality-of-life outcomes. *J Bone Joint Surg Am* 2014;96:353–60.
69. Aslani H, Zafarani Z, Ebrahimpour A, *et al.* Early clinical results of arthroscopic remplissage in patients with anterior shoulder instability with engaging Hill-Sachs lesion in Iran. *Arch Bone Jt Surg* 2014;2:43–6.
70. Di Giacomo G, De Vita A, Costantini A, *et al.* Management of humeral head deficiencies and glenoid track. *Curr Rev Musculoskelet Med* 2014;7:6–11.
71. Magee T. Prevalence of HAGL lesions and associated abnormalities on shoulder MR examination. *Skeletal Radiol* 2014;43:307–13.
72. Omi R, Hooke AW, Zhao KD, *et al.* The effect of the remplissage procedure on shoulder range of motion: a cadaveric study. *Arthroscopy* 2014;30:178–87.
73. Di Giacomo G, Itoi E, Burkhart SS. Evolving concept of bipolar bone loss and The Hill-Sachs lesion: from 'engaging/non-engaging' lesion to 'on-track/off-track' lesion. *Arthroscopy* 2014;30:90–8.
74. Kozin SH, Abzug JM, Safier S, *et al.* Complications of pediatric elbow dislocations and Monteggia fracture-dislocations. *Instr Course Lect* 2015;64:493–8.
75. Bor N, Rubin G, Rozen N, *et al.* Chronic anterior Monteggia lesions in children: report of 4 cases treated with closed reduction by ulnar osteotomy and external fixation. *J Pediatr Orthop* 2015;35:7–10.
76. Anđjelković S, Vučković Č, Milutinović S, *et al.* Giovanni Battista Monteggia (1762–1815). *Srp Arh Celok Lek* 2015;143:105–7.
77. Ramirez RN, Ryan DD, Williams J, *et al.* A line drawn along the radial shaft misses the capitellum in 16% of radiographs of normal elbows. *J Pediatr Orthop* 2014;34:763–7.
78. Delpont M, Jouve J-L, Sales de Gauzy J, *et al.* Proximal ulnar osteotomy in the treatment of neglected childhood Monteggia lesion. *Orthop Traumatol Surg Res* 2014;100:803–7.
79. Mellema JJ, Doornberg JN, Dyer GSM, *et al.* Distribution of coronoid fracture lines by specific patterns of traumatic elbow instability. *J Hand Surg Am* 2014;39:2041–6.
80. Ray R, Gaston M. Treatment of late-presenting Monteggia variant with an isolated, simple flexion ulnar osteotomy. *J Pediatr Orthop B* 2014;23:472–6.
81. Ha T, Grant S, Huntley JS. Monteggia type IV fracture in a child with radial head dislocation irreducible by closed means: a case report. *BMC Res Notes* 2014;7:539.
82. Rehim SA, Maynard MA, Sebastin SJ, *et al.* Monteggia fracture dislocations: a historical review. *J Hand Surg Am* 2014;39:1384–94.
83. Kim YS, Lee HM, Kim JP, *et al.* Unusual presentation of a type I Monteggia equivalent lesion: simultaneous medial humeral condyle fracture with ipsilateral anterior dislocation of the radial head and acute plastic bowing of the ulna. *J Pediatr Orthop B* 2014;23:383–8.
84. Little KJ. Elbow fractures and dislocations. *Orthop Clin North Am* 2014;45:327–40.
85. Datta T, Chatterjee N, Pal AK, *et al.* Evaluation of outcome of corrective ulnar osteotomy with bone grafting and annular ligament reconstruction in neglected Monteggia fracture dislocation in children. *J Clin Diagn Res* 2014;8:LC01–4.
86. Williams HLM, Madhusudhan TR, Sinha A. Type III Monteggia injury with ipsilateral type II Salter Harris injury of the distal radius and ulna in a child: a case report. *BMC Res Notes* 2014;7:156.
87. Laratta JL, Yoon RS, Frank MA, *et al.* Divergent elbow dislocation with radial shaft fracture, distal ulnar deformation, and distal radioulnar joint instability: an unclassifiable Monteggia variant. *J Orthop Traumatol* 2014;15:63–7.
88. Otsuka J, Horii E, Koh S, *et al.* Severe forearm deformity and instability after Monteggia fracture-dislocation: a case report. *J Pediatr Orthop B* 2014;23:168–71.
89. Hagedorn JM, Reichel LM. Posterior interosseous nerve entrapment following Monteggia fracture dislocation. *J Hand Surg Am* 2014;39:400–2.
90. Segaren N, Abdul-Jabar HB, Segaren N, *et al.* Medial radial head dislocation associated with a proximal olecranon fracture: a Bado type v? *Case Rep Surg* 2014;2014:723756.
91. Beutel BG, Klifto CS, Chu A. Percutaneous reduction and flexible intramedullary nailing for Monteggia fracture in a skeletally mature patient. *Int J Surg Case Rep* 2014;5:1261–4.
92. Agrawal Y, Fernandes JA. Type II Monteggia injury in a toddler: an unusual presentation. *J Pediatr Orthop B* 2014;23:100–2.
93. Chagou A, Rhanim A, Berrada MS. The Monteggia fracture: series of 20 cases. *Pan Afr Med J* 2014;19:51.
94. Aresti N, Ramachandran M. Nonoriginal Malappropriate Eponymous Nomenclature: examples relevant to paediatric orthopaedics. *J Pediatr Orthop B* 2012;21:606–10.
95. Ravitch MM. Dupuytren's invention of the Mikulicz enterotomy with a note on eponyms. *Perspect Biol Med* 1979;22:170–84.
96. Waseem M, Khan M, Hussain N, *et al.* Eponyms: errors in clinical practice and scientific writing. *Acta Orthop Belg* 2005;71:1–8.
97. Hybbinette S. De la transplantation d'un fragment osseux pour remédier aux luxations récidivantes de l'épaule; constatations et résultats opératoires. *Acta Chir Scand* 1932;71:411–45.
98. Hoffa A. *Lehrbuch der Frakturen und Luxationen*. 4th edn. Stuttgart: Ferdinand Enke Verlag, 1904.
99. Kim S-H, Ha K-I, Yoo JC, *et al.* Kim's lesion: an incomplete and concealed avulsion of the posteroinferior labrum in posterior or multidirectional posteroinferior instability of the shoulder. *Arthrosc J Arthrosc Relat Surg* 2004;20:712–20.
100. Trivedi S, Pomerantz ML, Gross D, *et al.* Shoulder instability in the setting of bipolar (glenoid and humeral head) bone loss: the glenoid track concept. *Clin Orthop Relat Res* 2014;472:2352–62.
101. Garfield E. What's in a name? The eponymic route to immortality. *Essays an Inf Sci* 1983;6:384–95.
102. Baskaran LNGM, Greco PJ, Kaelber DC. Case report medical eponyms: an applied clinical informatics opportunity. *Appl Clin Inform* 2012;3:349–55.
103. Woywodt A, Matteson E. Should eponyms be abandoned? Yes. *BMJ* 2007;335:424–424.
104. Whitworth JA. Should eponyms be abandoned? No. *BMJ* 2007;335:425.