

University of Groningen

Neuroanatomy of auditory verbal hallucinations in schizophrenia

Modinos, Gemma; Costafreda, Sergi G.; van Tol, Marie-Jose; McGuire, Philip K.; Aleman, Andre; Allen, Paul

Published in:
Cortex

DOI:
[10.1016/j.cortex.2012.01.009](https://doi.org/10.1016/j.cortex.2012.01.009)

IMPORTANT NOTE: You are advised to consult the publisher's version (publisher's PDF) if you wish to cite from it. Please check the document version below.

Document Version
Publisher's PDF, also known as Version of record

Publication date:
2013

[Link to publication in University of Groningen/UMCG research database](#)

Citation for published version (APA):

Modinos, G., Costafreda, S. G., van Tol, M.-J., McGuire, P. K., Aleman, A., & Allen, P. (2013). Neuroanatomy of auditory verbal hallucinations in schizophrenia: A quantitative meta-analysis of voxel-based morphometry studies. *Cortex*, 49(4), 1046-1055. <https://doi.org/10.1016/j.cortex.2012.01.009>

Copyright

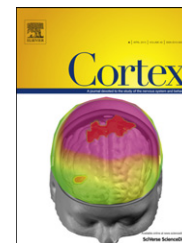Other than for strictly personal use, it is not permitted to download or to forward/distribute the text or part of it without the consent of the author(s) and/or copyright holder(s), unless the work is under an open content license (like Creative Commons).

The publication may also be distributed here under the terms of Article 25fa of the Dutch Copyright Act, indicated by the "Taverne" license. More information can be found on the University of Groningen website: <https://www.rug.nl/library/open-access/self-archiving-pure/taverne-amendment>.

Take-down policy

If you believe that this document breaches copyright please contact us providing details, and we will remove access to the work immediately and investigate your claim.

Downloaded from the University of Groningen/UMCG research database (Pure): <http://www.rug.nl/research/portal>. For technical reasons the number of authors shown on this cover page is limited to 10 maximum.



Research report

Neuroanatomy of auditory verbal hallucinations in schizophrenia: A quantitative meta-analysis of voxel-based morphometry studies

Gemma Modinos^{a,*}, Sergi G. Costafreda^a, Marie-José van Tol^b, Philip K. McGuire^a, André Aleman^b and Paul Allen^a

^aDepartment of Psychosis Studies, Institute of Psychiatry, King's College London, London, United Kingdom

^bDepartment of Neuroscience, University of Groningen, BCN Neuroimaging Center, Groningen, The Netherlands

ARTICLE INFO

Article history:

Received 27 August 2011

Reviewed 14 November 2011

Revised 1 December 2011

Accepted 23 January 2012

Action editor Gereon Fink

Published online 1 February 2012

Keywords:

Schizophrenia

Structural MRI

Psychosis

Grey matter volume

Meta-analysis

ABSTRACT

Introduction: Voxel-based morphometry (VBM) studies demonstrate grey matter volume (GMV) deficits in schizophrenia. This method is also applied for detecting associations between specific psychotic symptoms and brain structure, such as auditory verbal hallucinations (AVHs). However, due to differing methodological approaches, the available findings are inconsistent and difficult to integrate.

Methods: We used a novel voxel-based meta-analytical method to provide a robust quantitative review of neuroanatomical abnormalities specifically associated with the hallucinatory phenomenon in the schizophrenic brain. We reviewed all VBM studies of AVHs in schizophrenia published until July 2011 ($n = 9$). A total of 438 patients with a diagnosis of schizophrenia were included (307 with AVHs). Using a random-effects parametric voxel-based meta-analysis, coordinates of 83 foci reported as significant in the source studies were extracted and computed to estimate the brain locations most consistently associated with AVHs.

Results: Severity of AVHs was significantly associated with GMV reductions in the left ($p = .022$) and marginally with the right ($p = .062$) superior temporal gyri (STGs, including Heschl's gyri) across studies examining correlations with AVHs severity in patients ($n = 8$). Analysis of studies categorically comparing patients with and without AVHs did not reveal any significant findings, possibly due to the small number of studies using this approach ($n = 3$).

Conclusions: This meta-analysis implicates bilateral STG (including Heschl's gyri) as key areas of structural pathology in AVHs in schizophrenia. These findings support a model postulating that aberrations within neural systems involved at different levels of language processing are critical to AVHs in schizophrenia.

© 2012 Elsevier Ltd. All rights reserved.

1. Introduction

Schizophrenia is a severe and disabling mental illness involving chronic or recurrent psychosis and long-term deterioration in

functional capacity. Auditory verbal hallucinations (AVHs) are the most common psychotic symptom, affecting about 60–80% of patients with schizophrenia (Andreasen and Flaum, 1991). AVHs are defined as auditory perceptions (most typically,

* Corresponding author. Institute of Psychiatry (PO67), King's College London, 16 De Crespigny Park, London SE5 8AF, United Kingdom.

E-mail address: gemma.modinos@kcl.ac.uk (G. Modinos).

0010-9452/\$ – see front matter © 2012 Elsevier Ltd. All rights reserved.

doi:10.1016/j.cortex.2012.01.009

“voices”) in the absence of external stimulation, and in patients with schizophrenia the content of AVHs is usually derogatory and distressing (Nayani and David, 1996). Furthermore, in about 25% of patients AVHs are medication-resistant and chronic (Shergill et al., 1998) and severely impair patients’ functioning and quality of life (Hoffman, 2008).

In the last two decades, the development of neuroimaging techniques has allowed the investigation of putative abnormalities in the function, morphology and connectivity of the brains of schizophrenia patients suffering from AVHs. A recent comprehensive review of structural and functional imaging studies in patients with AVHs concluded that dysfunction in secondary (and occasionally primary) cortices in the temporal lobes is linked to the emergence of AVHs (Allen et al., 2008). In addition, non-sensory regions in prefrontal, premotor, cingulate, subcortical and cerebellar regions were also identified. A more recent meta-analysis based on functional imaging studies of patients who were experiencing AVHs during scanning highlighted aberrant activations in frontal, temporal and hippocampal regions (Jardri et al., 2011). Within the published studies examining the anatomical correlates of AVHs a range of inconsistencies is evident (with some studies highlighting associations with different non-sensory regions, e.g., Gaser et al. (2004), pointing to the right inferior frontal area, while others do not, hence evidencing significant disparity as to which regions are putatively involved) and, to date, no meta-analysis has been conducted.

Early region of interest (ROI) studies investigating putative morphological changes in patients with schizophrenia showed that AVHs were associated with volume reductions in the superior temporal gyrus (STG) and enlarged lateral ventricles (Barta et al., 1990; Flaum et al., 1995). More recently, ROI studies have reported associations between severity of AVHs and volume reductions in the left Heschl’s gyrus (primary auditory cortex) (Sumich et al., 2005), and in the left anterior STG and middle temporal gyrus (MTG) (Onitsuka et al., 2004). A review of ROI studies of the STG in schizophrenia highlighted its critical involvement in the disorder, most commonly characterised by volume reductions (Sun et al., 2009). This review also showed a link between pathophysiological changes in the STG and the development of hallucinations in patients with schizophrenia, especially in the left side. A limitation of these ROI studies is that they used manual or semi-automated methods to measure the volumes of brain regions defined *a priori* as being “abnormal,” hence preventing the exploration of other potentially implicated brain regions.

Fully-automated whole-brain voxel-based morphometry (VBM) methods (Mechelli et al., 2005) overcome some of the limitations of the ROI approach, and provide a powerful tool which is unbiased in its segmentation process to examine the neural substrates of psychiatric disorders and their symptomatological expressions. In their review of the literature on VBM in schizophrenia, Honea et al. (2005) reported the left STG and medial temporal lobe as key regions of structural pathology in patients relative to healthy subjects. More recently, Bora et al. (2011) provided a quantitative review of VBM studies of grey and white matter volume and concluded that schizophrenia is characterised by bilateral anterior

cortical, limbic and subcortical grey matter abnormalities, and white matter changes in regions that include tracts connecting these structures within and between hemispheres. However, in these previous meta-analyses the relative associations with specific symptoms were not considered. VBM has been effective in revealing morphologic abnormalities in schizophrenia according to symptom profile (Koutsouleris et al., 2008; Lui et al., 2009) and there have been a number of studies using VBM to examine structural abnormalities in patients who experience AVHs, either by examining the presence (comparing patients with schizophrenia with AVHs vs patients without AVHs) and/or the severity of AVHs (relationship between GMV and AVHs severity). Unfortunately, recent applications of these novel methods are often limited by relatively small sample sizes, resulting in insufficient statistical power and increased risk of false-positive results.

Newly developed voxel-based meta-analytical methods have the potential to quantify the reproducibility of neuroimaging findings and to generate insights difficult to observe in isolated studies. In this context, what follows is a systematic literature search of papers published to date that report specific effects of AVHs on brain structure in patients with schizophrenia using VBM. The studies identified in the literature search were pooled using a novel parametric voxelwise meta-analysis method (Costafreda et al., 2009) to identify the neuroanatomical locations that are most consistently implicated in the AVHs phenomenon across studies. This method allowed performing a random-effects meta-analysis of published studies, with sample size weighting, and ensuring stringent false-positive control (Family-Wise Error rate correction - FWE).

2. Methods

2.1. Literature selection, data collection, and preparation

Our aim was to identify all studies fulfilling the following criteria: (1) structural magnetic resonance imaging (MRI) studies of the AVHs phenomenon, (2) investigating differences in whole-brain grey matter, (3) reporting analyses pertaining to the presence or the severity of AVHs in patients with schizophrenia, and (4) using automated VBM analysis following the general steps of normalisation, segmentation, smoothing and statistical analysis described in the early literature on the method (Ashburner and Friston, 2000; Good et al., 2001). We conducted a systematic literature search of PubMed, Science-Direct, and Scopus databases to identify relevant studies published up until July 2011 (Fig. 1). The following key words were employed: “schizophrenia”, “hallucination”, plus “morphometry”, “voxel-based”, or “voxelwise”. In addition, we also conducted manual searches of the reference sections of the obtained articles. A total of 28 studies were initially identified; however some of these articles did not meet the inclusion criteria upon detailed examination and were excluded. This was the case for systematic reviews (Begré and Koenig, 2008) and articles not including original data (Gaser et al., 1999), studies exploring AVHs in people outside of the schizophrenia spectrum (Stanfield et al., 2009) or in high-risk populations (Spencer et al., 2007), studies

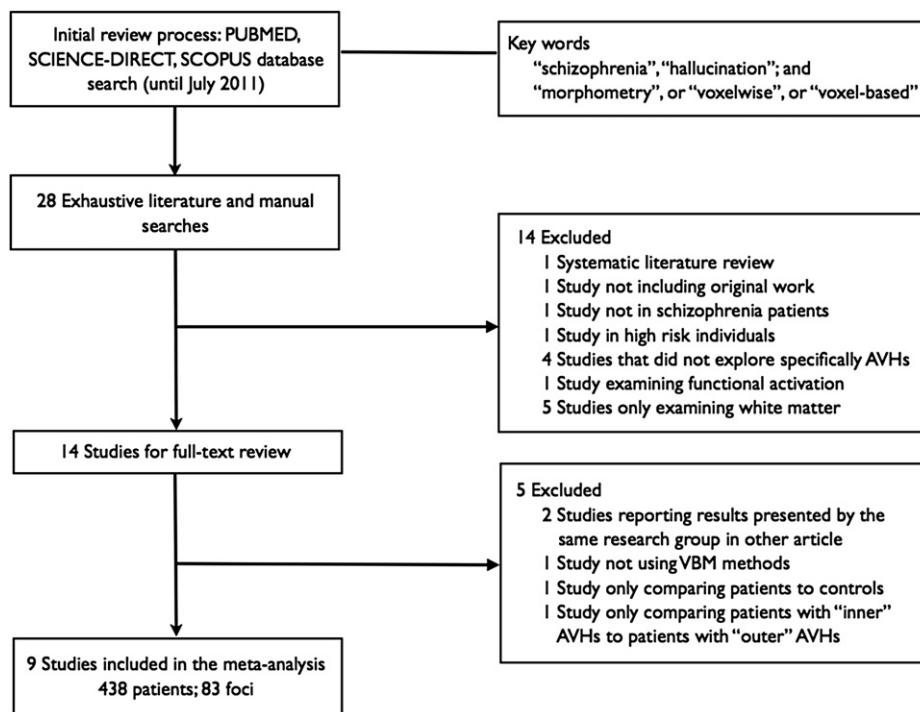


Fig. 1 – Flow diagram of study inclusion.

Legend: AVHs = Auditory verbal hallucinations; SCZ = Schizophrenia.

using VBM in schizophrenia though not specifically examining AVHs (Henze et al., 2011; Nenadic et al., 2010a; Spaniel et al., 2011; Wright et al., 1995), studies measuring brain activation (Parellada et al., 2008), and studies uniquely exploring white matter structure (Ashtari et al., 2007; Hubl et al., 2004; Seok et al., 2007; Shergill et al., 2007; Szeszko et al., 2008). Additional exclusions were made of studies reporting results presented by the same research group in another article (Aguilar et al., 2008; Hugdahl et al., 2007), studies not using VBM methods (Kleinschmidt et al., 1994), studies only presenting results from the comparison between schizophrenia patients with AVHs and healthy controls (Martí-Bonmatí et al., 2007), and studies only comparing patients with “inner” AVHs to patients with “outer” AVHs (Plaze et al., 2011). When necessary, the corresponding authors of the selected papers were contacted by e-mail requesting clarification on methodology or results.

Thus, the final analysis comprised nine studies in total. The characteristics of each included study are shown in Table 1. Eight of these studies (total n of patients with schizophrenia = 322) reported correlations between GMV and the severity of AVHs determined by symptom rating scales (García-Martí et al., 2008; Gaser et al., 2004; Modinos et al., 2009; Neckelmann et al., 2006; Nenadic et al., 2010b; O’Daly et al., 2007; Plaze et al., 2006; van Tol et al., submitted for publication). Three of these studies reported a categorical comparison of GMV between patients with AVHs and without AVHs (Gaser et al., 2004; Shapleske et al., 2002; van Tol et al., submitted for publication) (total n of patients with schizophrenia = 135 with AVHs, 131 without AVHs). Van Tol et al. included the sample of Modinos et al. (2009) for group

analysis ($n = 26$), but excluded these subjects for their correlation analysis in order to avoid overlapping datasets. The van Tol et al. dataset was identified as it is from one of our research groups (University of Groningen), and was included following the meta-analysis’ goal to include all relevant studies in this particular topic, as in previous meta-analysis of neuroimaging data (Radua et al., 2010). In addition, we are members of the International Consortium for Hallucination Research (Waters et al., 2012) and, to the best of our knowledge, no other unpublished datasets of these characteristics were available for inclusion. In the original studies, patients in the hallucinating group were defined by having treatment-resistant AVHs (five studies: García-Martí et al., 2008; Modinos et al., 2009; O’Daly et al., 2007; Plaze et al., 2006; van Tol et al., submitted for publication), or lifetime experience of AVHs (four studies: Neckelmann et al., 2006; Nenadic et al., 2010b; Gaser et al., 2004; Shapleske et al., 2002). None of the studies mentioned whether patients with AVHs experienced acute hallucinations during scanning. Thus, grey matter abnormalities associated with AVHs were examined independently of whether subjects were hallucinating during scanning, which nevertheless would not be expected to affect grey matter volume (GMV) measurements.

For each study, we identified the regions that were reported as significantly associated with AVHs either by correlations between regional volumes and symptom severity within a patient group (21 foci), or through direct group comparison between patients with and without AVHs (38 foci). Of note, VBM data are variably referred to as density, concentration, or volume. Consistent with a previous meta-analysis of VBM studies in schizophrenia (Honea et al., 2005),

Table 1 – Characteristics of the nine VBM studies included in the meta-analysis.

Study	Subjects	MRI Scanner	Software	Type of experiment	Measure of AVHs
van Tol et al., submitted for publication	109 schizophrenia patients (65 with AVHs; 44 no AVHs)	3-T scanner	Statistical parametric mapping (SPM) 5	Comparison patients with AVHs versus no AVHs;	PANSS
Nenadic et al., 2010b	99 schizophrenia patients (38 with AVHs; 61 no AVHs)	1.5-T scanner	SPM 2	Correlation GMV with severity of AVHs	SAPS
Modinos et al., 2009	26 schizophrenia patients with AVHs	3-T scanner	SPM 5	Correlation GMV with severity of AVHs	AHRS
García-Martí et al., 2008	18 schizophrenia patients with AVHs; 19 HC	1.5-T scanner	SPM 2	Correlation GMV with severity of AVHs	PSYRATS; BPRS
O'Daly et al., 2007	28 schizophrenia patients with AVHs; 32 HC	1.5-T scanner		Correlation GMV with severity of AVHs	PANSS; PSRS
Neckelmann et al., 2006	12 schizophrenia patients with AVHs; 12 HC	1.5-T scanner	SPM 99	Correlation GMV with severity of AVHs	BPRS
Plaze et al., 2006	15 schizophrenia patients with AVHs	1.5-T scanner	SPM 99	Correlation GMV with severity of AVHs	PSYRATS; SAPS
Gaser et al., 2004	85 schizophrenia patients (29 with AVHs, 56 no AVHs)	1.5-T scanner	SPM 99	Comparison patients with AVHs versus no AVHs; Correlation GMV with severity of AVHs	SAPS
Shapleske et al., 2002	72 schizophrenia patients (41 with AVHs, 31 no AVHs); 32 HC	1.5-T scanner	SPM 99	Comparison patients with AVHs versus no AVHs	SAPS

AHRS = Auditory hallucinations rating scale; BPRS = Brief psychiatric rating scale; HC = Healthy controls; mm = Millimetres; PANSS = Positive and negative syndrome scale; PSYRATS = Psychotic symptom rating scales; SAPS = Scale for the assessment of positive symptoms.

the term “volume” will be used hereafter to describe the results, for ease of description. MOOSE and PRISMA guidelines for meta-analyses of observational studies were followed (Moher et al., 2009; Stroup et al., 2000).

2.2. Meta-analysis procedure

Regional differences in GMV in relation to AVHs were analysed using Parametric Voxel-based Meta-analysis (PVM), a novel voxel-based meta-analytic approach described in detail elsewhere (Costafreda et al., 2009) and briefly summarised here. In this method, the value of each voxel in the meta-analysis summary map reflects the proportion of studies reporting a significant effect within a specified local neighbourhood. This map is thresholded by testing whether voxel scores could have been expected had the peaks showing significant effects been generated at random locations. In common with other coordinate-based meta-analysis methods, such as Activation Likelihood Estimation (ALE, Turkeltaub et al., 2002), PVM aims to detect ‘signal’ regions, with scores that are unlikely to arise under such null hypothesis. As an advantage over other methods, however, PVM provides an intuitive statistic that quantifies the level of agreement across studies in an interpretable way, namely the percentage of studies with at least one finding within radial distance of a point of interest. The method is applicable to both fixed-effects (in which each study is considered as deriving from the same generating process) and random-effects (in which the process varies across studies) meta-analysis. The PVM approach ensures stringent type I error control and leads to increased power and substantial gains in computational time relative to existing simulation-based alternatives.

In this case, the 83 foci of interest from the included studies were extracted to a flat text table, and imported into R statistical software (R Development Core Team, 2005, <http://www.R-project.org>). We used a brain mask obtained from the FMRIB Software Library (avg152T1_brain_mask, with 258,370 intracerebral voxels) to define the intracerebral space. Peaks reported in Talairach space were converted to the Montreal Neurological Institute (MNI) space using non-linear transformations (Brett et al., 2002). We used $\rho = 10$ mm to generate the summary map, and therefore the value at each voxel of this summary map represents the proportion of studies, with sample size weighting, reporting at least one significant peak within a local neighbourhood of size 10 mm. We then applied the PVM analytical approach to compute the uncorrected voxel-level p -value of observing a degree of concordance across studies as high as that generated by the experimental results. To correct for multiple comparisons, we employed a cluster-level approach whereby the proportion map was first thresholded at $p < .001$ (uncorrected) to reveal a number of clusters surviving this initial threshold, and we then employed 5000 permutations to compute the probability of obtaining clusters of such magnitude, under the null hypothesis that activations had in fact been generated at random locations. Such cluster-level tests offer a powerful approach to FWE correction (Hayasaka and Nichols, 2003). Given that structural abnormalities in relation to AVHs in schizophrenia had been studied with two

different types of experimental design, we decided to analyse them separately: (1) studies correlating severity of AVHs with GMV within a schizophrenia sample; (2) studies comparing GMV between schizophrenia patients with AVHs and patients without AVHs. Anatomical labelling of significant findings in the meta-analysis was conducted according to the Automatic Anatomical Labelling (AAL) template (Tzourio-Mazoyer et al., 2002).

3. Results

Patients included in the original studies had a diagnosis of schizophrenia according to DSM-III-R, DSM-IV, or DSM-IV-R criteria. Some studies included patients based on the presence of (lifetime or treatment-resistant) AVHs, whilst others included both patients with and patients without a history of

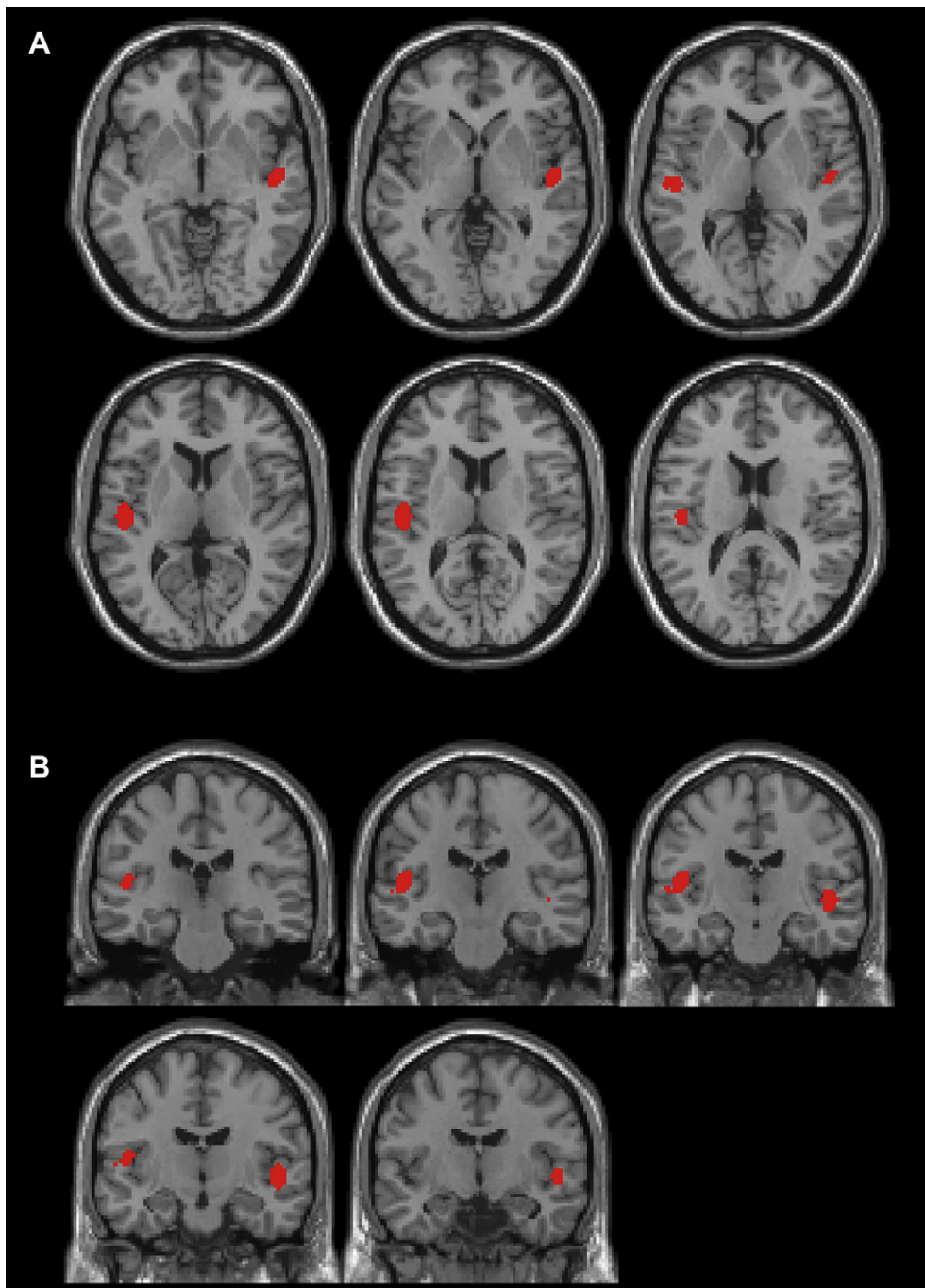


Fig. 2 – Results of the random-effects meta-analysis of VBM studies in patients with schizophrenia and AVHs (Cluster-level test: left STG $p = .022$, right STG $p = .062$, FWE).

Legend: The statistic depicted here is the proportion of studies reporting at least one significant peak within a local neighbourhood of size $\rho = 10$ mm, in axial [Panel A, $z = (-4, 0, 4, 8, 12, 16)$] and coronal views [Panel B, $z = (-24, -20, -16, -12, -8)$].

Table 2 – Summary of significant findings of grey matter abnormalities associated with AVHs in schizophrenia in VBM studies published to July 2011.

Cluster	Anatomical label	MNI coordinates			Size in voxels	Size in mm ³	p value
		x	y	z			
1	Left STG	–52	–18	2	210	1680	.022
	Left rolandic operculum	–44	–22	12			
	Left Heschl's gyrus	–46	–14	6			
2	Right Heschl's gyrus	50	–14	6	156	1248	.062
	Right STG	46	–16	–8			
	Right MTG	50	–14	–10			

The coordinates refer to the voxel with maximum score.

AVHs (see Table 1 for details). Two studies included male participants only (García-Martí et al., 2008; Shapleske et al., 2002); and one study included only right-handed patients with French as maternal language (Plaze et al., 2006). All studies but Shapleske et al. (2002) mentioned including patients who were receiving antipsychotic treatment (except two patients in O'Daly et al., 2007), although only two studies (Modinos et al., 2009; Plaze et al., 2006) provided data on mean chlorpromazine equivalents per day (mg). In terms of exclusion criteria, the original studies stated: history of head trauma, history of neurological disorders, present or past criteria for drug or alcohol abuse, and contraindication for MRI scanning (including metal implants, and claustrophobia). Two studies additionally excluded patients suffering from hearing impairment (García-Martí et al., 2008; O'Daly et al., 2007).

3.1. Regional grey matter abnormalities associated with the severity of AVHs

Two significant clusters emerged from the meta-analysis when pooling effects from the eight studies correlating GMV with severity of AVHs ($p < .05$ corrected). The largest significant cluster in which studies concurred in reporting significant GMV reductions included the left STG and primary auditory cortex or Heschl's gyrus (maximum concordance across studies at $x = -52, y = -18, z = 2$; with a weighted proportion of 48.6% of the studies reporting an effect within 10 mm of this maximum). Concordance was also found for GMV reductions at a trend level in a second, right-sided cluster including the right STG and Heschl's gyrus, where the level of agreement across studies reached 34.2% (Fig. 2, Table 2).

AVHs were not significantly associated with GMV increases across studies.

3.2. Regional grey matter abnormalities associated with the presence of AVHs

Combining the results from studies comparing GMV between schizophrenia patients with AVHs and patients without AVHs revealed no statistically significant effects. However, only three studies to date have conducted this type of analysis.

4. Discussion and conclusion

Our meta-analytic procedure identified structural abnormalities in specific brain areas in patients with schizophrenia who

suffer from AVHs. Across all studies investigating regional grey matter correlates of the severity of AVHs, this meta-analysis identified a large cluster in the left STG (including Heschl's gyrus) showing reduced GMV associated with greater AVHs severity. The same temporal lobe regions in the right hemisphere also showed an association between reduced GMV and greater AVH severity, albeit at a strong trend level. When we compared patients with and without AVHs no brain areas of concordance across studies were identified that highlighted structural correlates of the presence rather than the severity of AVHs. This is most likely due to the small number of studies ($n = 3$) which report this contrast, consequently limiting the power of a meta-analytic approach to yield statistically significant results across studies.

Superior temporal areas are central to language perception and processing. The left STG includes the primary and association auditory cortices and has been repeatedly implicated in the aetiology of AVHs (Allen et al., 2008). The right STG is also involved in auditory and language processing, particularly of the emotional and prosodic aspect of speech stimuli (Downar et al., 2000). Left superior temporal areas are known to be involved in 'speech' perception, i.e., the comprehension of the phonological and semantic characteristics of speech content. However, the association between right temporal lobe regions and AVHs severity is particularly interesting given these regions' involvement in the processing of prosody and emotional salience and the often derogatory nature of AVHs (Nayani and David, 1996). From a structural neuro-imaging perspective, it has been suggested that volume reductions in left-hemisphere auditory and speech perception areas may lead to a failure to inhibit and correctly attribute internal speech, as proposed in the verbal self-monitoring hypothesis of AVHs (Frith and Done, 1998). Interestingly, the STGs consistently show abnormal functional activation while patients are experiencing AVHs (Jardri et al., 2011), although it should be noted that this area is also widely implicated in patients regardless of symptoms (Honea et al., 2005). A volumetric abnormality, with the neurons in this area being reduced in number and/or spacing or having reduced connectivity, could be thought of as rendering the critical auditory and speech perception areas dysfunctional, which would block the normal attribution of internal speech. This aligns well with a recent comprehensive review of structural and functional MRI studies on brain connectivity which evidenced that the symptoms attributed to schizophrenia, such as AVHs, are associated with connectivity reductions across

all stages of the disorder and regardless of the neuroimaging methodology employed (Pettersson-Yeo et al., 2011). Future studies using multimodal imaging data should allow a close investigation of the possible relationship between STG structure and function with regard to AVHs in schizophrenia (Casanova et al., 2007).

Nevertheless, of the six ROI studies published to date in patients with schizophrenia and AVHs (Barta et al., 1990; Flaum et al., 1995; Sumich et al., 2005; Onitsuka et al., 2004; Shin et al., 2005; Hubl et al., 2010), four reported volumetric decreases in sensory regions, coinciding in the STG. The directionality of the results is also consistent with earlier lesion studies that report tissue loss in sensory regions in neurological patients (Braun et al., 2003). Thus, the results of the present meta-analysis of VBM studies are largely consistent with lesion and ROI studies, demonstrating a relationship between AVHs and volumetric decrements in modality-specific superior temporal areas including primary and secondary cortices subserving language perception and emotional processes. Of note, a recently published voxel-based meta-analysis of 896 individuals at very high risk of psychosis (Fusar-Poli et al., 2011) revealed GMV reductions in the right STG and other regions. Moreover, this region was related to subjects with later transition to psychosis. Thus, a future direction involves investigating STG abnormalities as correlates of vulnerability to psychosis in individuals at high risk for the disorder. In addition, based on our specific focus on patients with schizophrenia we decided to exclude studies on subjects with AVH outside the schizophrenia spectrum (i.e., bipolar patients and high-risk individuals), but future studies in these populations will inform whether similar VBM deviations can also be detected and are therefore truly an association of AVHs, or whether they are related to schizophrenia in general.

Our technique was unable to detect effects in other regions that have previously been associated with AVHs by single VBM studies. These include: the left insula (Shapleske et al., 2002); the thalamus and cerebellum (Neckelmann et al., 2006); the left postcentral and left posterior cingulate gyri (Nenadic et al., 2010b); and the left inferior frontal gyrus (Modinos et al., 2009). One study (Gaser et al., 2004) implied reduced GMV in the right middle/inferior frontal gyri to be associated with severity of hallucinations in 29 patients with schizophrenia. This region is the homotope of Broca's region in the left hemisphere, and a structural deficit could be argued to affect the inhibitory callosal connections, thus leading to overactivation of Broca's area. Our meta-analysis did not confirm this finding or those in other studies reporting effects outside the temporal cortices, however, suggesting that these may not be robust characteristics of grey matter abnormalities associated with AVHs. More studies using VBM in schizophrenia patients with AVHs are needed to inform the consistency of findings in these other regions. Furthermore, hallucination severity has been shown to influence the pattern of structural covariance between the left STG and MTG and the right inferior frontal gyrus, hippocampus, and the insula bilaterally, although only one study to date has included this type of analysis (Modinos et al., 2009).

As 25% of schizophrenia patients' AVHs are unresponsive to antipsychotic treatment (Shergill et al., 1998), a more

precise characterisation of the underlying pathophysiology, as reported here, may lead to more effective treatments. For instance, Transcranial Magnetic Stimulation (TMS) is a non-invasive technique that enables safe, relatively painless focal brain stimulation in humans. Several studies have reported that application of low frequency rTMS over the left temporo-parietal cortex in patients suffering from AVHs leads to an amelioration of symptoms, lasting for several weeks following treatment cessation (Chibbaro et al., 2005; d'Alfonso et al., 2002; Hoffman et al., 2003, 2005; Lee et al., 2005; Poulet et al., 2005; although see Slotema et al., 2011, for negative results). This was supported by two recently published meta-analyses that confirmed the superiority of rTMS over placebo in reducing medication-resistant AVHs (Aleman et al., 2007; Freitas et al., 2009). rTMS has also been applied with additional targeting of the right hemisphere region by a previous study (Vercammen et al., 2009), and although it did not contribute significantly towards clinically observable symptom reduction, patients in that trial did appear to be less affectively engaged by their AVHs. Thus, evidence from previous neuroimaging studies together with the present meta-analysis points to potential bilateral temporal cortex involvement in the genesis and severity of AVHs (Lennox et al., 1999, 2000; Shergill et al., 2000; Vercammen et al., 2009).

There are several limitations to this study. Only a modest number of articles could be included in the meta-analysis, which may have limited the statistical power to detect more subtle effects of AVHs on brain morphology. The goal of the present study was however to clearly define the spatial localisations of the most frequently replicated sites of GMV abnormalities in patients with schizophrenia and AVHs rather than to estimate their magnitudes. There were two studies that may have had a partially overlapping sample (Gaser et al., 2004; Nenadic et al., 2010b). However, from the description of the sample sizes it was not possible for us to determine the extent of the overlap. As these were two separate publications, with differing results, we chose to include both studies in the meta-analysis. In addition, recent studies (Ho et al., 2011) and systematic reviews (Navari and Dazzan, 2009; Smieskova et al., 2009) on the effects of antipsychotics on the human brain concluded that antipsychotics might contribute to structural changes observed in psychosis. Whilst the present meta-analysis could not address potential medication effects in the individual studies, future studies using VBM to investigate AVHs in psychosis examining medication effects should shed light on this possibility. It is worth mentioning that a previous study reported, although not in medicated patients with schizophrenia but in unmedicated adolescent males at increased risk of psychosis due to intellectual disability, an association between hallucinations and grey matter density in the STG GMD (Spencer et al., 2007). False negatives due to limited power are also likely to be very common in neuroimaging, as discussed in detail in Costafreda (2009). The main reason for this limited power is the relatively low number of subjects common in MRI research, combined with the requirement that any finding survives strict multiple comparison correction. Additionally, the inclusion of psychiatric populations is also likely to result in high between-subject variance, further reducing statistical power to detect potential effects. Effect size meta-analysis as employed in

most fields of research (Whitehead, 2002) is able to compensate for these problems through the pooling of significant and subsignificant (i.e., negative) results in a summary effect size, which has increased precision over the original studies. Unfortunately, neuroimaging studies rarely report subsignificant findings, and therefore it is not possible to add non-significant findings across studies to decide whether the pooled outcome does, in fact, reach significance. In other words, meta-analysis of coordinate-based data currently cannot aggregate power across studies and thus cannot remediate the false-negative problem, although more powerful approaches could remediate these issues (Salimi-Khorshidi et al., 2009).

Finally, the disparity of methods used across studies to determine presence and/or severity of AVHs needs to be discussed, which may influence the interpretation of the observed volumetric findings. The majority of studies correlating GMV with severity of AVHs used clinician-based scales, although these were fairly heterogeneous between studies (see Table 1), and with the exception of one study that used a self-report questionnaire (and reported results in the opposite direction, i.e., GMV increases) (Modinos et al., 2009). The three studies that included a non-hallucinator group for comparison each used a different method, i.e., score of zero on SAPS (Gaser et al., 2004), score of <2 on the SAPS (Shapleske et al., 2002), or score of <2 on the P3 item of the PANSS (van Tol et al., submitted for publication). Amidst the five studies that selected patients with schizophrenia based on their history of persistent auditory hallucinations, the time period of “persistence” varied from 1 week (Shapleske et al., 2002) to 1 year (García-Martí et al., 2008) before scanning. Nevertheless, the results of this meta-analysis should be interpreted as the neural correlates of severity of AVHs most consistently reported across studies that have primarily examined patients with “state” hallucinations. A future direction involves the assessment of a more general tendency to hallucinate using e.g., the CASH interview, tapping into lifetime severity of AVH (Andreasen et al., 1992). Despite these shortcomings, our data provide strong evidence for GMV deficits in brain areas involved at different levels of complexity in the neural architecture of language processing in schizophrenia patients with AVHs. In addition, this study was based on an unbiased inclusion of studies even if their results were negative (i.e., when no significant effects were found, e.g., van Tol et al., submitted for publication), with the use of a novel voxelwise meta-analytic method.

To conclude, regional grey matter reductions in the left and right STG, including the primary auditory cortices, are the most consistently reported findings in patients with schizophrenia and AVHs. These findings traverse methodological boundaries as have been reported also by studies using stereological analysis methods. Furthermore, the results are also consistent with lesion studies which reported that the lesion is almost always in the brain region of the sensory modality of the hallucination (Braun et al., 2003). Future studies should aim at the integration of imaging data from different modalities (functional, structural, neurochemical), with large enough samples (including patients with and without hallucinations), in order to illuminate the mechanisms by which the human brain is capable of generating an AVH.

REFERENCES

- Aguilar EJ, Sanjuan J, García-Martí G, Lull JJ, and Robles M. MR and genetics in schizophrenia: Focus on auditory hallucinations. *European Journal of Radiology*, 67(3): 434–439, 2008.
- Aleman A, Sommer IE, and Kahn RS. Efficacy of slow repetitive transcranial magnetic stimulation in the treatment of resistant auditory hallucinations in schizophrenia: A meta-analysis. *Journal of Clinical Psychiatry*, 68(3): 416–421, 2007.
- Allen P, Larøi F, McGuire PK, and Aleman A. The hallucinating brain: A review of structural and functional neuroimaging studies of hallucinations. *Neuroscience and Biobehavioral Reviews*, 32(1): 175–191, 2008.
- Andreasen NC and Flaum M. Schizophrenia: The characteristic symptoms. *Schizophrenia Bulletin*, 17(1): 27–49, 1991.
- Andreasen NC, Flaum M, and Arndt S. The Comprehensive Assessment of Symptoms and History (CASH). An instrument for assessing diagnosis and psychopathology. *Archives of General Psychiatry*, 49(8): 615–623, 1992.
- Ashburner J and Friston KJ. Voxel-based morphometry—the methods. *NeuroImage*, 11(6 Pt 1): 805–821, 2000.
- Ashtari M, Cottone J, Ardekani BA, Cervellione K, Szeszko PR, Wu J, et al. Disruption of white matter integrity in the inferior longitudinal fasciculus in adolescents with schizophrenia as revealed by fiber tractography. *Archives of General Psychiatry*, 64(11): 1270–1280, 2007.
- Barta PE, Pearlson GD, Powers RE, Richards SS, and Tune LE. Auditory hallucinations and smaller superior temporal gyral volume in schizophrenia. *American Journal of Psychiatry*, 147(11): 1457–1462, 1990.
- Begré S and Koenig T. Cerebral disconnectivity: An early event in schizophrenia. *Neuroscientist*, 14(1): 19–45, 2008.
- Bora E, Fornito A, Radua J, Walterfang M, Seal M, Wood SJ, et al. Neuroanatomical abnormalities in schizophrenia: A multimodal voxelwise meta-analysis and meta-regression analysis. *Schizophrenia Research*, 127(1–3): 46–57, 2011.
- Braun CM, Dumont M, Duval J, Hamel-Hebert I, and Godbout L. Brain modules of hallucination: An analysis of multiple patients with brain lesions. *Journal of Psychiatry and Neuroscience*, 28(6): 432–449, 2003.
- Brett M, Johnsrude IS, and Owen AM. The problem of functional localization in the human brain. *Nature Reviews. Neuroscience*, 3(3): 243–249, 2002.
- Casanova R, Srikanth R, Baer A, Laurienti PJ, Burdette JH, Hayasaka S, et al. Biological parametric mapping: A statistical toolbox for multimodality brain image analysis. *NeuroImage*, 34(1): 137–143, 2007.
- Chibbaro G, Daniele M, Alagona G, Di PC, Cannavo M, Rapisarda V, et al. Repetitive transcranial magnetic stimulation in schizophrenic patients reporting auditory hallucinations. *Neuroscience Letters*, 383(1–2): 54–57, 2005.
- Costafreda SG. Pooling fMRI data: Meta-analysis, mega-analysis and multi-center studies. *Frontiers in Neuroinformatics*, 3: 33, 2009.
- Costafreda SG, David AS, and Brammer MJ. A parametric approach to voxel-based meta-analysis. *NeuroImage*, 46(1): 115–122, 2009.
- d’Alfonso AA, Aleman A, Kessels RP, Schouten EA, Postma A, van Der Linden JA, et al. Transcranial magnetic stimulation of left auditory cortex in patients with schizophrenia: Effects on hallucinations and neurocognition. *Journal of Neuropsychiatry and Clinical Neuroscience*, 14(1): 77–79, 2002.
- Downar J, Crawley AP, Mikulis DJ, and Davis KD. A multimodal cortical network for the detection of changes in the sensory environment. *Nature Neuroscience*, 3(3): 277–283, 2000.
- Flaum M, O’Leary DS, Swayze 2nd VW, Miller DD, Arndt S, and Andreasen NC. Symptom dimensions and brain morphology

- in schizophrenia and related psychotic disorders. *Journal of Psychiatric Research*, 29(4): 261–276, 1995.
- Freitas C, Fregni F, and Pascual-Leone A. Meta-analysis of the effects of repetitive transcranial magnetic stimulation (rTMS) on negative and positive symptoms in schizophrenia. *Schizophrenia Research*, 108(1–3): 11–24, 2009.
- Frith CD and Done DJ. Towards a neuropsychology of schizophrenia. *British Journal of Psychiatry*, 153: 437–443, 1998.
- Fusar-Poli P, Borgwardt S, Crescini A, Deste G, Kempton MJ, Lawrie S, et al. Neuroanatomy of vulnerability to psychosis: A voxel-based meta-analysis. *Neuroscience and Biobehavioral Reviews*, 35(5): 1175–1185, 2011.
- García-Martí G, Aguilar EJ, Lull JJ, Martí-Bonmatí L, Escartí MJ, Manjón JV, et al. Schizophrenia with auditory hallucinations: A voxel-based morphometry study. *Progress in Neuropsychopharmacology & Biological Psychiatry*, 32(1): 72–80, 2008.
- Gaser C, Nenadic I, Volz HP, Büchel C, and Sauer H. Neuroanatomy of “hearing voices”: A frontotemporal brain structural abnormality associated with auditory hallucinations in schizophrenia. *Cerebral Cortex*, 14(1): 91–96, 2004.
- Gaser C, Volz HP, and Sauer H. Deformation based morphometry of auditory hallucinations in schizophrenia. *NeuroImage*, 9(6 Pt 2): s618, 1999.
- Good CD, Johnsrude IS, Ashburner J, Henson RN, Friston KJ, and Frackowiak RS. A voxel-based morphometric study of ageing in 465 normal adult human brains. *NeuroImage*, 14(1 Pt 1): 21–36, 2001.
- Hayasaka S and Nichols TE. Validating cluster size inference: Random field and permutation methods. *NeuroImage*, 20(4): 2343–2356, 2003.
- Henze R, Brunner R, Thiemann U, Parzer P, Richterich A, Essig M, et al. Grey matter alterations in first-admission adolescents with schizophrenia. *Journal of Neuroimaging*, 21(3): 241–246, 2011.
- Ho BC, Andreasen NC, Ziebell S, Pierson R, and Magnotta V. Long-term antipsychotic treatment and brain volumes: A longitudinal study of first-episode schizophrenia. *Archives of General Psychiatry*, 68(2): 128–137, 2011.
- Hoffman RE. Auditory/Verbal hallucinations, speech perception neurocircuitry, and the social deafferentation hypothesis. *Clinical EEG and Neuroscience*, 39(2): 87–90, 2008.
- Hoffman RE, Gueorguieva R, Hawkins KA, Varanko M, Boutros NN, Wu YT, et al. Temporoparietal transcranial magnetic stimulation for auditory hallucinations: Safety, efficacy and moderators in a fifty patient sample. *Biological Psychiatry*, 58(2): 97–104, 2005.
- Hoffman RE, Hawkins KA, Gueorguieva R, Boutros NN, Rachid F, Carroll K, et al. Transcranial magnetic stimulation of left temporoparietal cortex and medication-resistant auditory hallucinations. *Archives of General Psychiatry*, 60(1): 46–59, 2003.
- Honea R, Crow TJ, Passingham D, and Mackay CE. Regional deficits in brain volume in schizophrenia: A meta-analysis of voxel-based morphometry studies. *American Journal of Psychiatry*, 162(12): 2233–2245, 2005.
- Hubl D, Dougoud-Chauvin V, Zeller M, Federspiel A, Boesch C, Strik W, et al. Structural analysis of Heschl’s gyrus in schizophrenia patients with auditory hallucinations. *Neuropsychobiology*, 61(1): 1–9, 2010.
- Hubl D, Koenig T, Strik W, Federspiel A, Kreis R, Boesch C, et al. Pathways that make voices: White matter changes in auditory hallucinations. *Archives of General Psychiatry*, 61(1): 658–668, 2004.
- Hugdahl K, Løberg EM, Specht K, Steen VM, van Wageningen H, and Jørgensen HA. Auditory hallucinations in schizophrenia: The role of cognitive, brain structural and genetic disturbances in the left temporal lobe. *Frontiers in Human Neuroscience*, 1: 6, 2007.
- Jardri R, Pouchet A, Pins D, and Thomas P. Cortical activations during auditory verbal hallucinations in schizophrenia: A coordinate-based meta-analysis. *American Journal of Psychiatry*, 168(1): 73–81, 2011.
- Kleinschmidt A, Falkai P, Huang Y, Schneider T, Furst G, and Steinmetz H. In vivo morphometry of planum temporale asymmetry in first-episode schizophrenia. *Schizophrenia Research*, 12(1): 9–18, 1994.
- Koutsouleris N, Gaser C, Jäger M, Bottlender R, Frodl T, Holzinger S, et al. Structural correlates of psychopathological symptom dimensions in schizophrenia: A voxel-based morphometric study. *NeuroImage*, 39(4): 1600–1612, 2008.
- Lee SH, Kim W, Chung YC, Jung KH, Bahk WM, Jun TY, et al. A double blind study showing that two weeks of daily repetitive TMS over the left or right temporoparietal cortex reduces symptoms in patients with schizophrenia who are having treatment-refractory auditory hallucinations. *Neuroscience Letters*, 376(3): 177–181, 2005.
- Lennox BR, Park SB, Jones PB, and Morris PG. Spatial and temporal mapping of neural activity associated with auditory hallucinations. *Lancet*, 353(9153): 644, 1999.
- Lennox BR, Park SB, Medley I, Morris PG, and Jones PB. The functional anatomy of auditory hallucinations in schizophrenia. *Psychiatry Research*, 100(1): 13–20, 2000.
- Lui S, Deng W, Huang X, Jiang L, Ma X, Chen H, et al. Association of cerebral deficits with clinical symptoms in antipsychotic-naïve first-episode schizophrenia: An optimized voxel-based morphometry and resting state functional connectivity study. *American Journal of Psychiatry*, 166(2): 196–205, 2009.
- Martí-Bonmatí L, Lull JJ, García-Martí G, Aguilar EJ, Moratal-Pérez D, Poyatos C, et al. Chronic auditory hallucinations in schizophrenic patients: MR analysis of the coincidence between functional and morphologic abnormalities. *Radiology*, 244(2): 549–556, 2007.
- Mechelli A, Price CJ, Friston KJ, and Ashburner J. Voxel-based morphometry of the human brain: Methods and applications. *Current Medical Imaging Reviews*, 1(2): 105–113, 2005.
- Modinos G, Vercammen A, Mechelli A, Kneegting H, McGuire PK, and Aleman A. Structural covariance in the hallucinating brain: A voxel-based morphometry study. *Journal of Psychiatry and Neuroscience*, 34(6): 465–469, 2009.
- Moher D, Liberati A, Tetzlaff J, Altman DG, and PRISMA Group. Preferred reporting items for systematic reviews and meta-analyses: The PRISMA statement. *BMJ (Clinical Research Ed.)*, 339: b2535, 2009.
- Navari S and Dazzan P. Do antipsychotic drugs affect brain structure? A systematic and critical review of MRI findings. *Psychological Medicine*, 39(11): 1763–1777, 2009.
- Nayani TH and David AS. The auditory hallucination: A phenomenological survey. *Psychological Medicine*, 26(1): 177–189, 1996.
- Neckelmann G, Specht K, Lund A, Ersland L, Smievoll AI, Neckelmann D, et al. Mr morphometry analysis of grey matter volume reduction in schizophrenia: Association with hallucinations. *International Journal of Neuroscience*, 116(1): 9–23, 2006.
- Nenadic I, Sauer H, and Gaser C. Distinct pattern of brain structural deficits in subsyndromes of schizophrenia delineated by psychopathology. *NeuroImage*, 49(2): 1153–1160, 2010a.
- Nenadic I, Smesny S, Schlösser RG, Sauer H, and Gaser C. Auditory hallucinations and brain structure in schizophrenia: Voxel-based morphometric study. *British Journal of Psychiatry*, 196(5): 412–413, 2010b.
- O’Daly OG, Frangou S, Chitnis X, and Shergill SS. Brain structural changes in schizophrenia patients with persistent hallucinations. *Psychiatry Research*, 156(1): 15–21, 2007.
- Onitsuka T, Shenton ME, Salisbury DF, Dickey CC, Kasai K, Toner SK, et al. Middle and inferior temporal gyrus grey matter volume

- abnormalities in chronic schizophrenia: An MRI study. *American Journal of Psychiatry*, 161(9): 1603–1611, 2004.
- Parellada E, Lomena F, Font M, Pareto D, Gutierrez F, Simo M, et al. Fluorodeoxyglucose-PET study in first-episode schizophrenic patients during the hallucinatory state, after remission and during linguistic-auditory activation. *Nuclear Medicine Communications*, 29(10): 894–900, 2008.
- Pettersson-Yeo W, Allen P, Benetti S, McGuire P, and Mechelli A. Dysconnectivity in schizophrenia: Where are we now? *Neuroscience and Biobehavioral Reviews*, 35(5): 1110–1124, 2011.
- Plaze M, Bartrés-Faz D, Martinot JL, Januel D, Bellivier F, De Beaurepaire R, et al. Left superior temporal gyrus activation during sentence perception negatively correlates with auditory hallucination severity in schizophrenia patients. *Schizophrenia Research*, 87(1–3): 109–115, 2006.
- Plaze M, Paillère-Martinot ML, Penttilä J, Januel D, de Beaurepaire R, Bellivier F, et al. “Where do auditory hallucinations come from?” – a brain morphometry study of schizophrenia patients with inner or outer space hallucinations. *Schizophrenia Bulletin*, 37(1): 212–221, 2011.
- Poulet E, Brunelin J, Bediou B, Bation R, Forgeard L, Dalery J, et al. Slow transcranial magnetic stimulation can rapidly reduce resistant auditory hallucinations in schizophrenia. *Biological Psychiatry*, 57(2): 188–191, 2005.
- Radua J, van den Heuvel OA, Surguladze S, and Mataix-Cols D. Meta-analytical comparison of voxel-based morphometry studies in obsessive-compulsive disorder vs other anxiety disorders. *Archives of General Psychiatry*, 67(7): 701–711, 2010.
- R Development Core Team R: *A Language and Environment for Statistical Computing*. Vienna, Austria: R Foundation for Statistical Computing, 2005.
- Salimi-Khorshidi G, Smith SM, Keltner JR, Wager TD, and Nichols TE. Meta-analysis of neuroimaging data: A comparison of image-based and coordinate-based pooling of studies. *NeuroImage*, 45(3): 810–823, 2009.
- Seok JH, Park HJ, Chun JW, Lee SK, Cho HS, Kwon JS, et al. White matter abnormalities associated with auditory hallucinations in schizophrenia: A combined study of voxel-based analyses of diffusion tensor imaging and structural magnetic resonance imaging. *Psychiatry Research*, 156(2): 93–104, 2007.
- Shapleske J, Rossell SL, Chitnis XA, Suckling J, Simmons A, Bullmore ET, et al. A computational morphometric MRI study of schizophrenia: Effects of hallucinations. *Cerebral Cortex*, 12(12): 1331–1341, 2002.
- Shergill SS, Brammer MJ, Williams SC, Murray RM, and McGuire PK. Mapping auditory hallucinations in schizophrenia using functional magnetic resonance imaging. *Archives of General Psychiatry*, 57(11): 1033–1038, 2000.
- Shergill SS, Kanaan RA, Chitnis XA, O’Daly O, Jones DK, Frangou S, et al. A diffusion tensor imaging study of fasciculi in schizophrenia. *American Journal of Psychiatry*, 164(3): 467–473, 2007.
- Shergill SS, Murray RM, and McGuire PK. Auditory hallucinations: A review of psychological treatments. *Schizophrenia Research*, 32(3): 137–150, 1998.
- Shin SE, Lee JS, Kang MH, Kim CE, Bae JN, and Jung G. Segmented volumes of cerebrum and cerebellum in first episode schizophrenia with auditory hallucinations. *Psychiatry Research*, 138(1): 33–42, 2005.
- Slotema CW, Blom JD, de Weijer AD, Diederer KM, Goekoop R, Looijestijn J, et al. Can low-frequency repetitive transcranial magnetic stimulation really relieve medication-resistant auditory verbal hallucinations? Negative results from a large randomized controlled trial. *Biological Psychiatry*, 69(5): 450–456, 2011.
- Smieskova R, Fusar-Poli P, Allen P, Bendfeldt K, Stieglitz RD, Drewe J, et al. The effects of antipsychotics on the brain: What have we learnt from structural imaging of schizophrenia? – a systematic review. *Current Pharmaceutical Design*, 15(22): 2535–2549, 2009.
- Spaniel F, Horáček J, Tintèra J, Ibrahim I, Novák T, Cermák J, et al. Genetic variation in FOXP2 alters grey matter concentrations in schizophrenia patients. *Neuroscience Letters*, 493(3): 131–135, 2011.
- Spencer MD, Moorhead TW, McIntosh AM, Stanfield AC, Muir WJ, Hoare P, et al. Grey matter correlates of early psychotic symptoms in adolescents at enhanced risk of psychosis: A voxel-based study. *NeuroImage*, 35(3): 1181–1191, 2007.
- Stanfield AC, Moorhead TW, Job DE, McKirdy J, Sussmann JE, Hall J, et al. Structural abnormalities of ventrolateral and orbitofrontal cortex in patients with familial bipolar disorder. *Bipolar Disorders*, 11(2): 135–144, 2009.
- Stroup DF, Berlin JA, Morton SC, Olkin I, Williamson GD, Rennie D, et al. Meta-analysis of observational studies in epidemiology: A proposal for reporting. Meta-analysis of Observational Studies in Epidemiology (MOOSE) group. *JAMA: the Journal of the American Medical Association*, 283(15): 2008–2012, 2000.
- Sumich A, Chitnis XA, Fannon DG, O’Ceallaigh S, Doku VC, Faldrowicz A, et al. Unreality symptoms and volumetric measures of Heschl’s gyrus and planum temporal in first-episode psychosis. *Biological Psychiatry*, 57(8): 947–950, 2005.
- Sun J, Maller JJ, Guo L, and Fitzgerald PB. Superior temporal gyrus volume change in schizophrenia: A review on region of interest volumetric studies. *Brain Research Reviews*, 61(1): 14–32, 2009.
- Szeszko PR, Robinson DG, Ashtari M, Vogel J, Betensky J, Sevy S, et al. Clinical and neuropsychological correlates of white matter abnormalities in recent onset schizophrenia. *Neuropsychopharmacology*, 33(5): 976–984, 2008.
- Turkeltaub PE, Eden GF, Jones KM, and Zeffiro TA. Meta-analysis of the functional neuroanatomy of single-word reading: Method and validation. *NeuroImage*, 16(3 Pt 1): 765–780, 2002.
- Tzourio-Mazoyer N, Landeau B, Papathanassiou D, Crivello F, Etard O, Delcroix N, et al. Automated anatomical labeling of activations in SPM using a macroscopic anatomical parcellation of the MNI MRI single-subject brain. *NeuroImage*, 15(1): 273–289, 2002.
- Vercammen A, Knegtering H, Bruggeman R, Westenbroek HM, Jenner JA, Slooff CJ, et al. Effects of bilateral repetitive transcranial magnetic stimulation on treatment resistant auditory-verbal hallucinations in schizophrenia: A randomized controlled trial. *Schizophrenia Research*, 114(1–3): 172–179, 2009.
- van Tol MJ, Modinos G, Bruggeman R, Knegtering H, and Aleman A. Voxel based grey and white matter morphometry correlates of auditory verbal hallucinations in the corpus callosum and primary language processing areas, submitted for publication.
- Waters F, Aleman A, Fernyhough C, and Allen P. Report on the inaugural meeting of the International Consortium on Hallucination Research: A clinical and research update and 16 consensus-set goals for future research. *Schizophrenia Bulletin*, 2012 Jan 5. [Epub ahead of print].
- Whitehead A. *In Meta-analysis of Controlled Clinical Trials. Statistics in Practice*. Chichester, England: Wiley, 2002. Chapter 1. pp. 1–10.
- Wright IC, McGuire PK, Poline JB, Traverso JM, Murray RM, Frith CD, et al. A voxel-based method for the statistical analysis of grey and white matter density applied to schizophrenia. *NeuroImage*, 2(4): 244–252, 1995.