

University of Groningen

Role of baseline nodule density and changes in density and nodule features in the discrimination between benign and malignant solid indeterminate pulmonary nodules

Xu, D.M.; van Klaveren, R.J.; de Bock, G.H.; Leusveld, A.L.M.; Dorrius, M.D.; Zhao, Y.; Wang, Y.; de Koning, H.J.; Scholten, E.T.; Verschakelen, J.

Published in:
European Journal of Radiology

DOI:
[10.1016/j.ejrad.2008.02.022](https://doi.org/10.1016/j.ejrad.2008.02.022)

IMPORTANT NOTE: You are advised to consult the publisher's version (publisher's PDF) if you wish to cite from it. Please check the document version below.

Document Version
Publisher's PDF, also known as Version of record

Publication date:
2009

[Link to publication in University of Groningen/UMCG research database](#)

Citation for published version (APA):

Xu, D. M., van Klaveren, R. J., de Bock, G. H., Leusveld, A. L. M., Dorrius, M. D., Zhao, Y., Wang, Y., de Koning, H. J., Scholten, E. T., Verschakelen, J., Prokop, M., & Oudkerk, M. (2009). Role of baseline nodule density and changes in density and nodule features in the discrimination between benign and malignant solid indeterminate pulmonary nodules. *European Journal of Radiology*, 70(3), 492-498. <https://doi.org/10.1016/j.ejrad.2008.02.022>

Copyright

Other than for strictly personal use, it is not permitted to download or to forward/distribute the text or part of it without the consent of the author(s) and/or copyright holder(s), unless the work is under an open content license (like Creative Commons).

The publication may also be distributed here under the terms of Article 25fa of the Dutch Copyright Act, indicated by the "Taverne" license. More information can be found on the University of Groningen website: <https://www.rug.nl/library/open-access/self-archiving-pure/taverne-amendment>.

Take-down policy

If you believe that this document breaches copyright please contact us providing details, and we will remove access to the work immediately and investigate your claim.

Downloaded from the University of Groningen/UMCG research database (Pure): <http://www.rug.nl/research/portal>. For technical reasons the number of authors shown on this cover page is limited to 10 maximum.

Role of baseline nodule density and changes in density and nodule features in the discrimination between benign and malignant solid indeterminate pulmonary nodules

Dong Ming Xu^{a,*}, Rob J. van Klaveren^b, Geertruida H. de Bock^c, Anne L.M. Leusveld^d,
Monique D. Dorrius^d, Yingru Zhao^d, Ying Wang^d, Harry J. de Koning^e,
Ernst T. Scholten^f, Johnny Verschakelen^g,
Mathias Prokop^h, Matthijs Oudkerk^d

^a Department of Diagnostic and Interventional Radiology, Shanghai Sixth People's Hospital, Shanghai Jiao Tong University, 600 Yi Shan Road, PO Box 200233, Shanghai, China

^b Department of Pulmonology, Erasmus Medical Center, Rotterdam, The Netherlands

^c Department of Epidemiology, University Medical Center Groningen, University of Groningen, The Netherlands

^d Department of Radiology, University Medical Center Groningen, The Netherlands

^e Department of Public Health, Erasmus Medical Center, Rotterdam, The Netherlands

^f Department of Radiology, Kennemer Gasthuis, Haarlem, The Netherlands

^g Department of Radiology, University Hospital Gasthuisberg, Leuven, Belgium

^h Department of Radiology, University Medical Center Utrecht, Utrecht, The Netherlands

Received 5 October 2007; received in revised form 20 January 2008; accepted 22 February 2008

Abstract

Purpose: To retrospectively evaluate whether baseline nodule density or changes in density or nodule features could be used to discriminate between benign and malignant solid indeterminate nodules.

Materials and methods: Solid indeterminate nodules between 50 and 500 mm³ (4.6–9.8 mm) were assessed at 3 and 12 months after baseline lung cancer screening (NELSON study). Nodules were classified based on morphology (spherical or non-spherical), shape (round, polygonal or irregular) and margin (smooth, lobulated, spiculated or irregular). The mean CT density of the nodule was automatically generated in Hounsfield units (HU) by the Lungcare[®] software.

Results: From April 2004 to July 2006, 7310 participants underwent baseline screening. In 312 participants 372 solid purely intra-parenchymal nodules were found. Of them, 16 (4%) were malignant. Benign nodules were 82.8 mm³ (5.4 mm) and malignant nodules 274.5 mm³ (8.1 mm) ($p=0.000$). Baseline CT density for benign nodules was 42.7 HU and for malignant nodules -2.2 HU ($p=ns$). The median change in density for benign nodules was -0.1 HU and for malignant nodules 12.8 HU ($p<0.05$). Compared to benign nodules, malignant nodules were more often non-spherical, irregular, lobulated or spiculated at baseline, 3-month and 1-year follow-up ($p<0.0001$). In the majority of the benign and malignant nodules there was no change in morphology, shape and margin during 1 year of follow-up ($p=ns$).

Conclusion: Baseline nodule density and changes in nodule features cannot be used to discriminate between benign and malignant solid indeterminate pulmonary nodules, but an increase in density is suggestive for malignancy and requires a shorter follow-up or a biopsy.

© 2008 Elsevier Ireland Ltd. All rights reserved.

Keywords: CT screening; Lung cancer; Attenuation; Indeterminate nodules

1. Introduction

Lung cancer is today the most frequent cause of cancer deaths in the world [1]. It currently accounts for approximately 5% of all deaths in most developed countries and, as such, constitutes a major public health problem [2]. The overall 5-year survival rate

* Corresponding author. Tel.: +86 2164369181; fax: +86 2164701361.
E-mail address: dongming1996@hotmail.com (D.M. Xu).

of lung cancer patients is only 14%, and remained at this level for the past two decades. However, when lung cancer is found at the early stage I or II, 5-year survival rates can be as high as 60–70% [3]. The rapid development of Multi-Detector Computed Tomography (MDCT) technology and Computer-Aided Diagnosis (CAD) systems has led to a revival of interest in lung cancer screening. The concept of CT screening for lung cancer is based on the hypothesis that with an increase in the proportion of tumors detected at an early stage [4] and a corresponding reduction of advanced stage disease, a reduction of lung cancer mortality can be achieved. From lung cancer screening trials we know that 55–85% of screening detected lung cancer cases are at an early stage [5], but whether this will result in a stage shift or a lung cancer mortality reduction is yet unknown [6], and can only be answered by randomised lung cancer screening trials.

Aside from the primary research question whether lung cancer screening is effective or not, the optimal management of CT detected pulmonary nodules is also of major clinical relevance. CT screening reveals small sub-centimetre nodules in 60–90% of screening participants and the differentiation between benign and malignant nodules is complicated [7,8]. Management of these nodules should focus on rapid identification of malignant nodules to make curative treatment possible, while avoiding needle biopsies and surgical resections for benign lesions. It is well known that size is an important discriminator: nodules less than 3 mm in diameter only have a 0.2% chance of being malignant, but for nodules between 4 and 7 mm it is already 0.9%, between 8 and 20 mm 18% and above 20 mm 50% [9]. Based on these data, the Fleischner Society [9] has issued recommendations for periodic follow-up scanning depending on the initial size of the nodule and patient characteristics. In addition to size, nodule consistency (i.e. solid, partial-solid, non-solid) and nodule growth are also predictors for malignancy [9–11]. However, benign lesions may grow as well [11], and two-dimensional measurements have proven to be unreliable in detecting growth in small non-calcified nodules [12]. Therefore, additional nodule characteristics are needed to come to a better identification of malignant pulmonary nodules.

It has been demonstrated for non-solid and partial-solid nodules, usually representing bronchiolo-alveolar cell carcinomas (BAC) and adenocarcinomas, that during the malignant transformation nodule attenuation increase due to invasive growth, alveolar collapse and fibrotic reactions [13]. It could be hypothesised that during the evolution of small solid pulmonary nodules a similar change in nodule density might take place, which could help in the discrimination between benign and malignant solid pulmonary nodules. Unknown is also if in the natural history of malignant solid pulmonary nodules the external features might change from spherical, round and smooth to non-spherical, irregular, lobulated and spiculated.

Purpose of our study was to evaluate whether nodule density or changes in nodule density, morphology, shape and margin during 1 year of follow-up in indeterminate solid pulmonary nodules between 50 and 500 mm³ detected at baseline screening for lung cancer could be used as parameters to discriminate between benign and malignant nodules.

2. Materials and methods

2.1. Study participants

The subjects of this study were participants of the Dutch–Belgian randomised trial for lung cancer screening (NELSON) who underwent baseline screening for lung cancer by low-dose MDCT. Participants were between 50 and 75 years of age and were recruited via population registries through mail. They had to be current or former smokers with a smoking history of >15 cigarettes/day for >25 years or >10 cigarettes/day for >30 years. People who had had a pneumonectomy or with a history of breast cancer, melanoma or hypernephroma were excluded. People with a history of other types of cancer were only eligible if curatively treated at least 5 years ago without signs of recurrence at the time of inclusion. The NELSON study was approved by the Medical Ethical Committees of all institutions and all subjects provided their written informed consent. For the present study all participants with indeterminate solid nodules, defined as nodules with a volume between 50 and 500 mm³ (corresponding to 4.6–9.8 mm in diameter), detected at baseline screening were selected. These subjects underwent a follow-up CT scan at 3 and 12 months to evaluate whether nodule density or changes in nodule density, morphology, shape and margin could be used as parameters to discriminate between benign and malignant nodules.

2.2. Data acquisition

At all four screening sites 16-detector MDCT scanners were used (Mx8000 IDT or Brilliance 16P, Philips Medical Systems, Cleveland, OH, USA, or Sensation-16, Siemens Medical Solutions, Forchheim, Germany). Scanning of the entire chest was performed in caudo-cranial direction. Scan data were obtained in spiral mode, with 16 mm × 0.75 mm collimation and 1.5 pitch. No contrast was used. Low-dose settings were applied depending on body weight (<50 kg, 50–80 kg and >80 kg), the kVp settings were 80–90, 120 and 140 kVp, respectively, to achieve a Computed Tomography Dose Index Volume (CTDI_{vol}) of approximately 0.8 mGy, 1.6 mGy and 3.2 mGy, respectively. The mAs settings were adjusted accordingly, depending on the machine used. To minimise breathing artefacts, scans were performed at suspended maximal inspiration after appropriate instruction of the subjects. Data were reconstructed at 1.0 mm slice thickness, with 0.7 mm reconstruction increment. Repeat scans were performed with the same technical parameters as used for the baseline scans in low-dose setting.

2.3. Image analysis

All CT images were read twice independently. First readings were done by a radiologist with an experience in reading thoracic CT scans varying from 1 year to more than 20 years. Second readings were done by radiologists with 6 years of experience. In case of a discrepancy between the

first and second reader, a third radiologist with more than 15 years of experience in thoracic CT made the final decision. The Syngo Lungcare[®] (Leonardo[®] workstation, Somaris/5 VB 10A, Siemens Medical Solutions, Erlangen, Germany) software package designed to aid radiologists in diagnosing pulmonary nodules was used in addition to visual readings. Baseline and follow-up images were reviewed and displayed simultaneously on one workstation. All images were interpreted both at lung window and mediastinal settings.

2.4. Nodule features

Non-calcified solid nodules detected at baseline screening were classified into four different categories based on size and benign characteristics [14]. Nodules with volumes between 50 and 500 mm³ (corresponding to 4.6–9.8 mm in diameter) were defined as indeterminate nodules. These nodules were further classified based on morphology (spherical or non-spherical), shape (round/oval, polygonal or irregular) [15] and margin (smooth, lobulated, spiculated or irregular) [16]. The mean CT density of all voxels within the outer margin of the nodule was automatically generated in Hounsfield units (HU) by Lungcare[®] software, instead of specifying a region of interest (ROI) for density measurement. In case of inappropriate segmentation, the radiologist was able to enter manual measurements as well, which then overruled the automatically generated density and volume as described earlier [14]. A nodule was defined as spherical if the maximal diameter was less than twice the minimal diameter of the nodule, otherwise non-spherical. A nodule was polygonal when the entire lesion surface was surrounded by concave margins [17]. Spiculation was defined as the presence of strands extending from the nodule margin into the lung parenchyma without reaching the pleural surface [18]. Lobulation was defined as an abrupt bulging of the lesion contour [19]. Because all indeterminate nodules received a follow-up scan at 3 months and 1 year according to the NELSON trial protocol [14], three time points were available for analysis in all nodules except for the nodules that appeared to be malignant at 3 months.

2.5. Study endpoints

A participant with a nodule showing significant growth at 3-month or 1-year follow-up was referred to a pulmonologist for work-up and final pathological diagnosis [14]. Nodules were classified as benign or malignant based on histological examination of a trans-thoracic needle biopsy or examination of surgical specimens. Nodules were also classified as benign if the Volume Doubling Time (VDT) was >600 days or if the volume decreased or the nodule resolved at 1-year follow-up.

2.6. Statistical analysis

The Mann–Whitney *U*-test was used for comparisons of volume, density and the volume, density change over time between

benign and malignant nodules. For benign and malignant nodules with 1-year follow-up scan, the change in attenuation was defined as the density at year one minus the density at the 3-month repeat scan. For malignant nodules diagnosed at 3-month follow-up, the attenuation change (CT density change) was defined as the density at 3 months minus the density at baseline scan. Changes in morphology, shape and margin between baseline, 3-month and 1-year follow-up were compared by χ^2 -test, both for benign and malignant nodules. *P*-values <0.05 were considered statistically significant. All statistical analyses were performed by SPSS version 14.0.

3. Results

From April 2004 to July 2006, 7310 participants underwent baseline screening. The mean age of the participants was 63 years (± 5 years), 95% were males, 5% females. In 312 participants 372 solid purely intra-parenchymal nodules with a volume between 50 and 500 mm³ were found. The distribution in morphology, shape and margin at baseline, 3-month and 1-year follow-up is presented in Table 1. Of the 372 nodules, 16 (4%) turned out to be malignant and 356 (96%) were benign. Ten cases of lung cancer (nos. 1–10) were diagnosed at 3-month and 6 cancer cases (nos. 11–16) at 1-year follow-up. These 6 malignant nodules did not show growth at 3-month follow-up. Among these 16 lung cancer cases, there were 8 adenocarcinomas, 5 squamous cell carcinomas, 2 large cell carcinomas and 1 neuroendocrine carcinoma (Table 2). The median volume of all the nodules at baseline was 84.9 mm³ (range 50.3–498.0 mm³, corresponding diameter 5.5 mm). For benign nodules the median volume was 82.8 mm³ (range 50.3–491.0 mm³, corresponding diameter 5.4 mm) and

Table 1
Distribution of morphology, shape and margin in 372 solid indeterminate pulmonary nodules detected at baseline, 3-month and 1-year follow-up scan

	Indeterminate nodules		
	Baseline (%)	3-month FU (%)	1-year FU (%)
Morphology			
Spherical	338 (91)	336 (90)	329 (91)
Non-spherical	34 (9)	36 (10)	33 (9)
Shape			
Polygonal	42 (11)	41 (11)	42 (12)
Round	285 (77)	285 (77)	279 (77)
Irregular	45 (12)	46 (12)	41 (11)
Margin			
Smooth	260 (70)	274 (74)	251 (69)
Lobulated	74 (20)	57 (15)	76 (21)
Spiculated	38 (10)	41 (11)	35 (10)
Total	372	372	362 ^a

FU, follow-up.

^a At 1-year FU, there were 362 nodules instead of 372 nodules, since 10 nodules were diagnosed as lung cancer at 3-month FU.

Table 2
CT density, morphology, shape and margin changes over time in 16 malignant solid indeterminate nodules

No.	Scan time	Volume (mm ³) (diameter, mm)	Density (HU)	Morphology	Shape	Margin	Histology
1	Baseline	446.6 (9.5)	67.2	Spherical	Round	Lobulated	Squamous cell carcinoma
	3 months	1102.0 (12.8)	37.7	Spherical	Round	Spiculated	
2	Baseline	249.8 (7.8)	57.5	Spherical	Irregular	Spiculated	Squamous cell carcinoma
	3 months	362.2 (8.8)	28.7	Spherical	Irregular	Spiculated	
3	Baseline	262.9 (7.9)	-2.6	Non-spherical	Irregular	Spiculated	Adenocarcinoma
	3 months	1132 (12.9)	-14.6	Non-spherical	Irregular	Spiculated	
4	Baseline	458.7 (9.6)	48.4	Spherical	Round	Lobulated	Adenocarcinoma
	3 months	601.4 (10.4)	46.9	Spherical	Round	Lobulated	
5	Baseline	124.8 (6.2)	75.0	Spherical	Round	Lobulated	Adenocarcinoma
	3 months	337.6 (8.6)	73.8	Spherical	Round	Lobulated	
6	Baseline	64.4 (5.0)	21.4	Spherical	Round	Lobulated	Squamous cell carcinoma
	3 months	87.6 (5.5)	34.6	Spherical	Round	Lobulated	
7	Baseline	279.4 (8.1)	-20.1	Non-spherical	Irregular	Spiculated	Adenocarcinoma
	3 months	460.5 (9.6)	-6.8	Non-spherical	Irregular	Spiculated	
8	Baseline	308.8 (8.4)	-41.8	Non-spherical	Irregular	Spiculated	Neuroendocrine Carcinoma
	3 months	774.3 (11.4)	-13.3	Non-spherical	Irregular	Spiculated	
9	Baseline	302.5 (8.3)	-57.6	Spherical	Round	Lobulated	Squamous cell carcinoma
	3 months	575.6 (10.3)	-14.6	Spherical	Round	Lobulated	
10	Baseline	121.8 (6.1)	-1.8	Non-spherical	Irregular	Lobulated	Large cell Carcinoma
	3 months	1223 (13.3)	43.3	Non-spherical	Irregular	Lobulated	
11	Baseline	346.3 (8.7)	-128	Non-spherical	Irregular	Spiculated	Adenocarcinoma
	3 months	160.7 (6.7)	-77.7	Non-spherical	Irregular	Spiculated	
	One year	780.3 (11.4)	-38.1	Non-spherical	Irregular	Spiculated	
12	Baseline	498.0 (9.8)	-13.0	Non-spherical	Irregular	Lobulated	Large cell Carcinoma
	3 months	450.2 (9.5)	-13.0	Non-spherical	Irregular	Lobulated	
	1 year	698.2 (11.0)	16.4	Non-spherical	Irregular	Lobulated	
13	Baseline	242.2 (7.7)	-57.3	Spherical	Irregular	Spiculated	Adenocarcinoma
	3 months	282.3 (8.1)	-57.1	Spherical	Irregular	Spiculated	
	1 year	496.5 (9.8)	-32.9	Spherical	Irregular	Spiculated	
14	Baseline	269.5 (8.0)	24.9	Non-spherical	Irregular	Spiculated	Adenocarcinoma
	3 months	252.0 (7.8)	10.8	Non-spherical	Irregular	Spiculated	
	1 year	483.5 (9.7)	23.1	Non-spherical	Irregular	Spiculated	
15	Baseline	382.7 (9.0)	-14.8	Non-spherical	Irregular	Lobulated	Squamous cell carcinoma
	3 months	281.0 (8.1)	-22.5	Non-spherical	Irregular	Lobulated	
	1 year	1765 (15.0)	-23.5	Non-spherical	Irregular	Lobulated	
16	Baseline	227.7 (7.6)	56.7	Non-spherical	Irregular	Spiculated	Adenocarcinoma
	3 months	275.4 (8.1)	29.3	Non-spherical	Irregular	Spiculated	
	1 year	448.0 (9.5)	37.8	Non-spherical	Irregular	Spiculated	

for malignant nodules 274.5 mm³ (range 64.4–498.0 mm³, corresponding diameter 8.1 mm) ($p=0.000$). The median volume change over time for benign nodules was 1.7 mm³ (range -2220.4 to 950.5 mm³, corresponding diameter 1.5 mm) and for malignant nodules 231.5 mm³ (range 23.2–1483.5 mm³, corresponding diameter 7.6 mm) ($p=0.000$).

Compared to benign nodules, malignant nodules were more often non-spherical, irregular, lobulated or spiculated at baseline, 3-month and 1-year follow-up ($p<0.0001$). In 356 benign nodules, 99% had no change in morphology and shape, and in 86% of them no change in margin during 1 year of follow-up. Of the 16 malignant nodules, 15 nodules had no margin

change, and all these malignant nodules had no change in morphology or shape at 3 months or 1 year of follow-up. There was no significant difference of morphology, shape and margin change between benign and malignant nodules during follow-up scan ($p=ns$) (Table 3).

Baseline median CT density for all nodules was 41.6 HU (range -195.0 to 192.1 HU), for benign nodules 42.7 HU (range -195.1 to 192.1 HU) and for malignant nodules -2.2 HU (range -127.5 to 75.0 HU) ($p=ns$). The median change in density for benign nodules was -0.1 HU (range -93.1 to 175.2 HU) and 12.8 HU (range -29.5 to 45.1 HU) for malignant nodules ($p<0.05$) (Fig. 1).

Table 3
Distribution of morphology, shape and margin change in 372 solid indeterminate pulmonary nodules at 3-month or 1-year follow-up scan between benign and malignant nodules

	Morphology		Shape		Margin	
	No change	Change	No change	Change	No change	Change
Benign (356)	353 (99)	3 (1)	351 (99)	5 (1)	305 (86)	51 (14)
Malignant (16)	16 (100)	0 (0)*	16 (100)	0 (0)*	15 (94)	1 (6)*
Total	369	3	367	5	320	52

* $p > 0.05$ (χ^2 -test).

4. Discussion

The management algorithm of pulmonary nodules found at baseline scans is based on size and the consistency of the nodules (solid, partial-solid or non-solid). According to our NELSON protocol, a non-calcified nodule with a volume between 50 and 500 mm³ was classified as indeterminate because of its intermediate cancer risk. They required an additional repeat scan 3–4 months later to assess growth and to get additional information regarding the nature of these nodules [14]. In approximately 20% of participants of the NELSON trial, at least one indeterminate nodule was detected, making this type of nodule rather common. Because the clinical importance of providing an optimal nodule management algorithm for indeterminate pulmonary nodules is high, we decided to focus on this type of nodule to investigate if changes in nodule attenuation, shape, morphology or margin were associated with malignancy.

First of all we observed in our series that the malignant nodules tended to have a lower mean density than the benign nodules, without reaching statistical significance. This might be explained by the inclusion of air, an air bronchogram or regressive changes such as necrosis or hemorrhage within the tumor. These findings are consistent with the results of studies performed in usually larger SPNs [20–23]. Therefore, nodule density cannot be used in clinical practice to discriminate

between malignant and benign nodules because of the wide overlap observed in our series as well as by others in larger solitary pulmonary nodules [20,21,24].

The second observation was that malignant solid nodules showed a significant increase in density at 3-month or 1-year follow-up. This observation could be used to recommend a shorter follow-up (i.e. after 6 or 9 months) or to biopsy this type of nodules because of an increased cancer risk. Although no serial pathological specimens are available in this study and no pathological–radiological correlate can be provided, the observed increase in density might be reflecting the evolution of small adenocarcinomas described by Noguchi et al. [25]. In the transition from atypical adenomatous hyperplasia (AAH) to bronchiolo-alveolar cell carcinoma (BAC), adenocarcinoma with BAC features and invasive adenocarcinoma, there was a decrease in alveolar and lepidic growth pattern and an increase in invasive growth and fibrosis formation. On the other hand, according to the results of the present study, benign lesions did not show this change in nodule density over time, but instead showed large individual increases or decreases. Since there was no pathological material available from these benign nodules it can only be speculated what the underlying cause might be, including the spontaneous resolution of infectious lesions or local mucus impaction. Lymph nodes are less likely to be involved since the indeterminate nodules selected were situated within the lung parenchyma, while lymph nodes usually are located in the close vicinity of the broncho-vascular tree, the subpleural area or area attached to fissures [26,27].

The third observation in our series is that malignant indeterminate solid nodules are already from the beginning larger and more often non-spherical, irregular, lobulated or spiculated than benign lesions, suggesting that the malignant features are not acquired in the course of their natural history.

So far, only the investigators of the Mayo Clinic lung cancer CT screening trial described in detail the changes in attenuation and margin in 48 lung cancer cases in which more than one CT examination was available [28]. Nodule attenuation was, in contrast to our study, not measured but the nodules were only visually classified as solid, partial-solid and non-solid. In 44% (21/48) of the cases the attenuation changed: in 57% it increased (from non-solid to partial-solid or solid), in 24% it decreased and in the remaining 19% it was variable. In 42% (20/48) the margin of the nodule changed: in 80% it became more irregular or spiculated, in 15% smoother and the margin was variable in 5%. As these changes in attenuation and margin were lim-

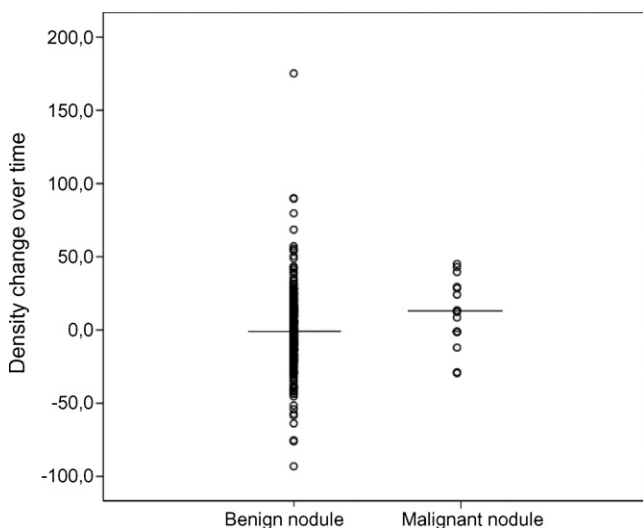


Fig. 1. Attenuation changes (Hounsfield units) in 356 benign and 16 malignant solid indeterminate pulmonary nodules at 3-month or 1-year follow-up.

ited to malignant nodules only in their study, no conclusion can be drawn with regard to the value of density and margin changes in the discrimination between benign and malignant nodules.

Although our study represents, to our knowledge one of the largest prospective series of CT screening-detected solid and purely intra-parenchymal indeterminate nodules in which retrospectively the changes in attenuation, morphology, shape and margin have been evaluated, our study is limited by the relatively small numbers of lung cancer cases. Another limitation of our study is that in the majority of the benign nodules no histological or cytological diagnosis of the lesion could be obtained despite intensive work-up by the pulmonologist including bronchoscopy, brush and washing. Usually, the nodule could not be reached by trans-thoracic needle biopsy or video-assisted thoracoscopy because of their location or small size. If no pathological confirmation was obtained a nodule was only classified as benign if the VDT was >600 days or if the volume decreased at 1 year of follow-up. As our study had only a 1-year follow-up period, some of these nodules may turn out to be cancer in a later stage although this probability is rather low [29]. The third limitation is that we do not have information on the repeatability and reproducibility of the nodule density measurements. Therefore, the observed nodule density changes could also be a result of the variability in nodule density measurements. However, as this potential variability applies both for benign and malignant nodules, it will not change the conclusions of our study.

In conclusion, baseline nodule density and changes in nodule features cannot be used to discriminate between benign and malignant solid indeterminate pulmonary nodules, but an increase in density is suggestive for malignancy and requires a shorter follow-up or a biopsy.

Conflict of interest

Not reported.

Acknowledgements

We would like to thank Peter Paul Taverne, Prof. Dr. Kris Nackaerts, Estelle J.K. Noach, Wim Tukker and Peter van Ooijen for their efforts concerning data collection and management, providing us the population data from the central NELSON databases, English editing of the manuscript, data archiving and transferring.

References

- [1] Pasic A, Postmus PE, Sutedja TG. What is early lung cancer? A review of the literature. *Lung Cancer* September 2004;45(3):267–77.
- [2] Manser RL, Irving LB, Byrnes G, Abramson MJ, Stone CA, Campbell DA. Screening for lung cancer: a systematic review and meta-analysis of controlled trials. *Thorax* September 2003;58(9):784–9.
- [3] Beadsmoore CJ, Screaton NJ. Classification, staging and prognosis of lung cancer. *Eur J Radiol* 2003;45(1):8–17.
- [4] Henschke CI, Yankelevitz DF, Libby DM, Pasmantier MW, Smith JP, Miettinen OS. Survival of patients with stage I lung cancer detected on CT screening. *N Engl J Med* 2006;355(17):1763–71.
- [5] Mulshine JL, Sullivan DC. Lung cancer screening. *N Engl J Med* 2005;352(26):2714–20.
- [6] Bach PB, Jett JR, Pastorino U, Tockman MS, Swensen SJ, Begg CB. Computed tomography screening and lung cancer outcomes. *JAMA* 2007;297(9):953–61.
- [7] Gohagan J, Marcus P, Fagerstrom R, Pinsky P, Kramer B, Prorok P. Baseline findings of a randomized feasibility trial of lung cancer screening with spiral CT scan vs chest radiograph: the Lung Screening Study of the National Cancer Institute. *Chest* 2004;126(1):114–21.
- [8] Henschke CI, McCauley DI, Yankelevitz DF, et al. Early Lung Cancer Action Project: overall design and findings from baseline screening. *Lancet* 1999;354(9173):99–105.
- [9] MacMahon H, Austin JH, Gamsu G, et al. Guidelines for management of small pulmonary nodules detected on CT scans: a statement from the Fleischner Society. *Radiology* 2005;237(2):395–400.
- [10] Henschke CI, Yankelevitz DF, Mirtcheva R, McGuinness G, McCauley D, Miettinen OS. CT screening for lung cancer: frequency and significance of part-solid and nonsolid nodules. *AJR Am J Roentgenol* 2002;178(5):1053–7.
- [11] Winer-Muram HT. The solitary pulmonary nodule. *Radiology* 2006;239(1):34–49.
- [12] Revel MP, Bissery A, Bienvenu M, Aycard L, Lefort C, Frija G. Are two-dimensional CT measurements of small noncalcified pulmonary nodules reliable? *Radiology* 2004;231(2):453–8.
- [13] Park CM, Goo JM, Lee HJ, Lee CH, Chun EJ, Im JG. Nodular ground-glass opacity at thin-section CT: histologic correlation and evaluation of change at follow-up. *Radiographics* 2007;27(2):391–408.
- [14] Xu DM, Gietema H, de Koning H, et al. Nodule management protocol of the NELSON randomised lung cancer screening trial. *Lung Cancer* 2006;54(2):177–84.
- [15] Matsuoka S, Kurihara Y, Yagihashi K, Niimi H, Nakajima Y. Peripheral solitary pulmonary nodule: CT findings in patients with pulmonary emphysema. *Radiology* 2005;235(1):266–73.
- [16] Gurney JW. Determining the likelihood of malignancy in solitary pulmonary nodules with Bayesian analysis. Part I. Theory. *Radiology* 1993;186(2):405–13.
- [17] Takashima S, Sone S, Li F, Maruyama Y, Hasegawa M, Kadoya M. Indeterminate solitary pulmonary nodules revealed at population-based CT screening of the lung: using first follow-up diagnostic CT to differentiate benign and malignant lesions. *AJR Am J Roentgenol* 2003;180(5):1255–63.
- [18] Takashima S, Sone S, Li F, et al. Small solitary pulmonary nodules (< or =1 cm) detected at population-based CT screening for lung cancer: reliable high-resolution CT features of benign lesions. *AJR Am J Roentgenol* 2003;180(4):955–64.
- [19] Takashima S, Maruyama Y, Hasegawa M, et al. CT findings and progression of small peripheral lung neoplasms having a replacement growth pattern. *AJR Am J Roentgenol* 2003;180(3):817–26.
- [20] Seemann MD, Staebler A, Beinert T, et al. Usefulness of morphological characteristics for the differentiation of benign from malignant solitary pulmonary lesions using HRCT. *Eur Radiol* 1999;9(3):409–17.
- [21] Seemann MD, Seemann O, Luboldt W, et al. Differentiation of malignant from benign solitary pulmonary lesions using chest radiography, spiral CT and HRCT. *Lung Cancer* 2000;29(2):105–24.
- [22] Wang JC, Sone S, Feng L, et al. Rapidly growing small peripheral lung cancers detected by screening CT: correlation between radiological appearance and pathological features. *Br J Radiol* 2000;73(873):930–7.
- [23] Yang Z, Sone S, Takashima S, Li F, Honda T, Yamada T. Small peripheral carcinomas of the lung: thin-section CT and pathologic correlation. *Eur Radiol* 1999;9(9):1819–25.
- [24] Xu DM, van Klaveren R, de Bock GH, et al. *Eur J Radiol* 2007 October 5 [Epub ahead of print].
- [25] Noguchi M, Morikawa A, Kawasaki M, et al. Small adenocarcinoma of the lung: histologic characteristics and prognosis. *Cancer* 1995;75(12):2844–52.

- [26] Hyodo T, Kanazawa S, Dendo S, et al. Intrapulmonary lymph nodes: thin-section CT findings, pathological findings, and CT differential diagnosis from pulmonary metastatic nodules. *Acta Med Okayama* 2004 October;58(5):235–40.
- [27] Oshiro Y, Kusumoto M, Moriyama N, et al. Intrapulmonary lymph nodes: thin-section CT features of 19 nodules. *J Comput Assist Tomogr* 2002;26(4):553–7.
- [28] Lindell RM, Hartman TE, Swensen SJ, et al. Five-year lung cancer screening experience: CT appearance, growth rate, location, and histologic features of 61 lung cancers. *Radiology* 2007;242(2):555–62.
- [29] Revel MP, Merlin A, Peyrard S, et al. Software volumetric evaluation of doubling times for differentiating benign versus malignant pulmonary nodules. *AJR Am J Roentgenol* 2006;187(1):135–42.