

## University of Groningen

### Drug coated balloon supported Supera stent versus Supera stent in intermediate and long-segment lesions of the superficial femoral artery

RAPID trial investigators; de Boer, Sanne W; de Vries, Jean-Paul; Werson, Debora A; Fioole, Bram; Vroegindewij, Dammis; Vos, Jan A; van den Heuvel, Daniel

*Published in:*  
Journal of Cardiovascular Surgery

*DOI:*  
[10.23736/S0021-9509.19.11109-3](https://doi.org/10.23736/S0021-9509.19.11109-3)

**IMPORTANT NOTE: You are advised to consult the publisher's version (publisher's PDF) if you wish to cite from it. Please check the document version below.**

*Document Version*  
Publisher's PDF, also known as Version of record

*Publication date:*  
2019

[Link to publication in University of Groningen/UMCG research database](#)

*Citation for published version (APA):*

RAPID trial investigators, de Boer, S. W., de Vries, J.-P., Werson, D. A., Fioole, B., Vroegindewij, D., Vos, J. A., & van den Heuvel, D. (2019). Drug coated balloon supported Supera stent versus Supera stent in intermediate and long-segment lesions of the superficial femoral artery: 2-year results of the RAPID trial. *Journal of Cardiovascular Surgery*, 60(5), 679-685. <https://doi.org/10.23736/S0021-9509.19.11109-3>

#### Copyright

Other than for strictly personal use, it is not permitted to download or to forward/distribute the text or part of it without the consent of the author(s) and/or copyright holder(s), unless the work is under an open content license (like Creative Commons).

The publication may also be distributed here under the terms of Article 25fa of the Dutch Copyright Act, indicated by the "Taverne" license. More information can be found on the University of Groningen website: <https://www.rug.nl/library/open-access/self-archiving-pure/taverne-amendment>.

#### Take-down policy

If you believe that this document breaches copyright please contact us providing details, and we will remove access to the work immediately and investigate your claim.

*Downloaded from the University of Groningen/UMCG research database (Pure): <http://www.rug.nl/research/portal>. For technical reasons the number of authors shown on this cover page is limited to 10 maximum.*

## ORIGINAL ARTICLE

## RECENT DEVELOPMENTS IN THE MANAGEMENT OF CRITICAL LIMB ISCHEMIA

# Drug coated balloon supported Supera stent *versus* Supera stent in intermediate and long-segment lesions of the superficial femoral artery: 2-year results of the RAPID Trial

Sanne W. de BOER <sup>1,2,3 \*</sup>, Jean-Paul P. M. de VRIES <sup>4,5</sup>, Debora A. WERSON <sup>4</sup>, Bram FIOOLE <sup>6</sup>, Dammis VROEGINDEWEIJ <sup>7</sup>, Jan A. VOS <sup>1</sup>, Daniel van den HEUVEL <sup>1</sup> on behalf of the RAPID trial investigators ‡

<sup>1</sup>Department of Radiology, St. Antonius Hospital, Nieuwegein, the Netherlands; <sup>2</sup>Department of Radiology, Maastricht University Medical Center, Maastricht, the Netherlands; <sup>3</sup>CARIM School for Cardiovascular Diseases, University of Maastricht, Maastricht, the Netherlands; <sup>4</sup>Department of Vascular Surgery, St. Antonius Hospital, Nieuwegein, the Netherlands; <sup>5</sup>Department of Vascular Surgery, University Medical Center Groningen, Groningen, the Netherlands; <sup>6</sup>Department of Vascular Surgery, Maasstad Hospital, Rotterdam, the Netherlands; <sup>7</sup>Department of Radiology, Maasstad Hospital, Rotterdam, the Netherlands

‡Members are listed at the end of the paper

\*Corresponding author: Sanne W. de Boer, Department of Radiology, St. Antonius Hospital, Nieuwegein, the Netherlands. E-mail: [s.deboer@mumc.nl](mailto:s.deboer@mumc.nl)

## ABSTRACT

**BACKGROUND:** Endovascular treatment of occlusive disease of the superficial femoral artery (SFA) has evolved from plain old balloon angioplasty (POBA) through primary stenting strategy to drug eluting technology-based approach. The RAPID Trial investigates the added value of drug coated balloons (DCB, Legflow) in a primary stenting strategy (Supera stent) for intermediate (5-15 cm) and long segment (>15 cm) SFA lesions.

**METHODS:** In this multicenter, patient-blinded trial, 160 patients with intermittent claudication, ischemic rest pain, or tissue loss due to intermediate or long SFA lesions were randomized (1:1) between Supera + DCB and Supera. Primary endpoint was primary patency at 2 years, defined as freedom from restenosis on duplex ultrasound (peak systolic velocity ratio <2.4).

**RESULTS:** At 2 years, primary patency was 55.1% (95% CI: 43.1-67.1%) in the Supera + DCB group *versus* 48.3% (95% CI: 35.6-61.0%) in the Supera group (P=0.957). Per protocol analysis showed a primary patency rate of 60.9% (95% CI: 48.6-73.2%) in the Supera + DCB group *versus* 49.8% (95% CI: 36.9-62.7%) in the Supera group (P=0.469). The overall mortality rate was 5% in both groups (P=0.975). Sustained functional improvement was similar in both groups.

**CONCLUSIONS:** The 2-year results in the current trial of a primary Supera stenting strategy are consistent with other trials reporting on treatment of intermediate and long SFA lesions. A DCB supported Supera stent strategy did not improve patency rate compared to a Supera stent only strategy.

(Cite this article as: de Boer SW, de Vries JPPM, Werson DA, Fioole B, Vroegindeweij D, Vos JA, *et al.*; RAPID trial investigators. Drug coated balloon supported Supera stent *versus* Supera stent in intermediate and long-segment lesions of the superficial femoral artery: 2-year results of the RAPID Trial. *J Cardiovasc Surg* 2019;60:679-85. DOI: 10.23736/S0021-9509.19.11109-3)

**KEY WORDS:** Femoral artery; Peripheral arterial disease; Angioplasty, balloon; Stents.

Endovascular repair for peripheral arterial occlusive disease (PAOD) in the superficial femoral artery (SFA) has gained widespread acceptance and has become the primary treatment method for all lesions regardless of lesion length and complexity.<sup>1-3</sup> This has largely been driven by

technical advancements enabling successful crossing and opening of the lesion and with increasing patency rates by the use of drug eluting technology and third generation stents. For short and intermediate SFA lesions, there is evidence that supports a “leave nothing behind” strategy.<sup>4</sup>

However, robust evidence for optimal treatment of long-segment SFA lesions, especially regarding chronic total occlusions (CTO), is still lacking. The RAPID Trial aimed to investigate the added value of a drug coated balloon (DCB) (Legflow, Cardionovum GmbH, Bonn, Germany) in a primary stenting strategy with the Supera stent (Abbott Laboratories, Abbott Park, IL, USA) in intermediate (5-15 cm) and long (>15 cm) SFA lesions. The short-term results of the RAPID Trial showed that there were no significant differences between the Supera + DCB and Supera group with respect to efficacy, mortality and other safety endpoints.<sup>5</sup> In the current report, the 2-year results of the RAPID Trial are presented.

### Materials and methods

The study protocol has been published in full prior to commencement of this trial.<sup>5,6</sup> The study design was approved by the principal ethics committee (Verenigde Commissies Mensgebonden Onderzoek, chair dr. V.H.M. Deneer, 27-04-2012) and by each site's institutional review board or ethics committee under number NL39391.100.12 and trial identifier ISRCTN47846578. All patients provided written informed consent.

#### Study design

The RAPID Trial is a prospective, multicenter, patient-blind randomized trial, including intermediate (5-15 cm) and long (>15 cm) lesions of the SFA. 160 patients were randomized in a 1:1 fashion to an intervention group which is primary Supera stenting supported with a Legflow DCB or a control group consisting of Supera stenting only.

#### Patient population

Patients had to be  $\geq 18$  years, suffering from symptomatic peripheral arterial occlusive disease (PAOD Rutherford 2-6) and presenting with de novo SFA lesions with a length of  $\geq 50$  mm, ostial lesions being admissible. Important exclusion criteria were life expectancy <1 year, obstruction caused by thrombosis, aneurysmal disease, acute obstruction and dissection.

#### Study endpoints

The primary end-point was primary patency, which was defined as the absence of binary restenosis (peak systolic velocity ratio (PSVR)  $\geq 2.4$  on duplex ultrasound (DUS) or >50% stenosis on digital subtraction angiography [DSA]) at 2 years. Follow-up visits were at 1 month, 6 months, 1

year and 2 years with DUS, Ankle Brachial Index (ABI) and toe pressure measurements.

Secondary end-points were: freedom from clinically driven target-lesion revascularization (CD-TLR), secondary patency and sustained functional outcomes such as Rutherford class, ABI and toe pressure measurements<sup>6</sup> and primary sustained clinical improvement (defined as an upward shift of at least one category per Rutherford classification at 2 years compared to baseline and without the need for reintervention).

Safety end-points were freedom of periprocedural deaths (PPD), major adverse limb events (MALE) and freedom from all-cause mortality at 2 years.

#### Statistical analysis

The RAPID Trial was powered to demonstrate a 25% reduction in restenosis rate in favor of the Supera + DCB group. 160 lesions were necessary to reach a statistical power of 80% with  $\alpha=0.05$ .

Continuous data are presented as means  $\pm$  standard deviation; categorical data are provided as counts (percentage).  $\chi^2$  or Fisher Exact Test (when appropriate) were used to compare categorical variables. Continuous variables were compared using Student's *t*-tests for independent samples. Kaplan-Meier (KM) estimates were used comparing patency, freedom from CD-TLR, and safety outcomes; log-rank test was used to evaluate group differences. Survival estimates are given with a 95% confidence interval (CI). Unadjusted and adjusted crude effect analyses were performed by using the Cox proportional hazards model. All data were analyzed using SPSS software (version 24.0 for Windows; IBM Corporation, Armonk, NY, USA).

## Results

### Baseline and procedural characteristics

The RAPID Trial included 160 patients randomized to treatment with Supera + DCB (N.=80) and Supera (N.=80). Seven patients in the Supera + DCB group were not included in the per protocol analysis. Five patients due to geographic miss and two patients due to stent related technical failures. Three patients in the Supera group were not included in the per protocol analysis due to stent related technical failures (Figure 1).

Demographics, comorbidities, and lesion characteristics were similar between the Supera + DCB and Supera groups and have been published before.<sup>5</sup> Mean lesion length was 15.8 $\pm$ 7.4 cm (range 5.0-33.0 cm) in the Su-

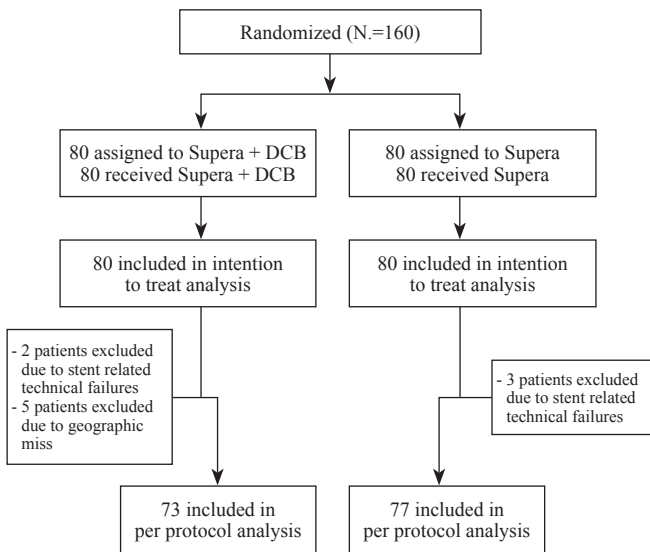


Figure 1.—Patient inclusion in the trial. DCB, drug-coated balloon.

pera + DCB group and 15.9±7.6 cm (range 5.0-35.0 cm) in the Supera group (P=0.926). In the Supera + DCB group 76.3% of lesions were total occlusions vs. 70.0% in the Supera group (P=0.713). Ostial involvement was present in 25% of the lesions in both groups (P=1.000). In addition, over a third of the lesions (38.8% in the Supera + DCB group vs. 36.3% in the Supera group (P=0.984) had bilateral calcifications according to the Peripheral Arterial Scoring System (PACCS).<sup>7</sup>

Efficacy outcomes through 2 years

In the intention to treat analysis, the KM estimate of primary patency rate at 2 years was 55.1% (95% CI: 43.1-67.1%) in the Supera + DCB group versus 48.3% (95% CI: 35.6-61.0%) in the Supera group (P=0.957) (Figure 2A). Unadjusted crude effect hazard ratio for using a DCB was 0.987 (95% CI: 0.607-1.605; P=0.957). When adjusted for baseline and lesions characteristics crude effect hazard ratio for using a DCB was 0.335 (95% CI: 0.052-2.162; P=0.250).

Per protocol analysis showed a KM estimate of primary patency rate of 60.9% (95% CI: 48.6-73.2%) in the Supera + DCB group versus 49.8% (95% CI: 36.9-62.7%) in the Supera group (P=0.469; Figure 2B). Per protocol KM estimate of secondary patency were 83.1% (95% CI: 73.9-92.3%) vs. 82.3% (95% CI: 72.7-91.9%) (P=0.941) and freedom of CD-TLR 75.4% (95% CI: 64.8-86.0%) vs. 73.0% (95% CI: 62.0-84.0%) (P=0.957) in the Supera + DCB group and Supera group, respectively (Figure 3A, B).

Safety outcomes at 2 years

KM estimates of freedom from MALE and PPD at 2 years were 68.5% (95% CI: 57.7-79.3%) in the Supera + DCB group vs. 75.2% (95% CI: 64.8-85.6%) (P=0.224) in the Supera group. KM estimate of freedom from all-cause mortality was 92.8% (95% CI: 85.9-99.7%) (N=4) in the Supera + DCB vs. 93.7% (95% CI: 87.6-99.8%) (N=4) (P=0.975) in Supera group. There were seven deaths in

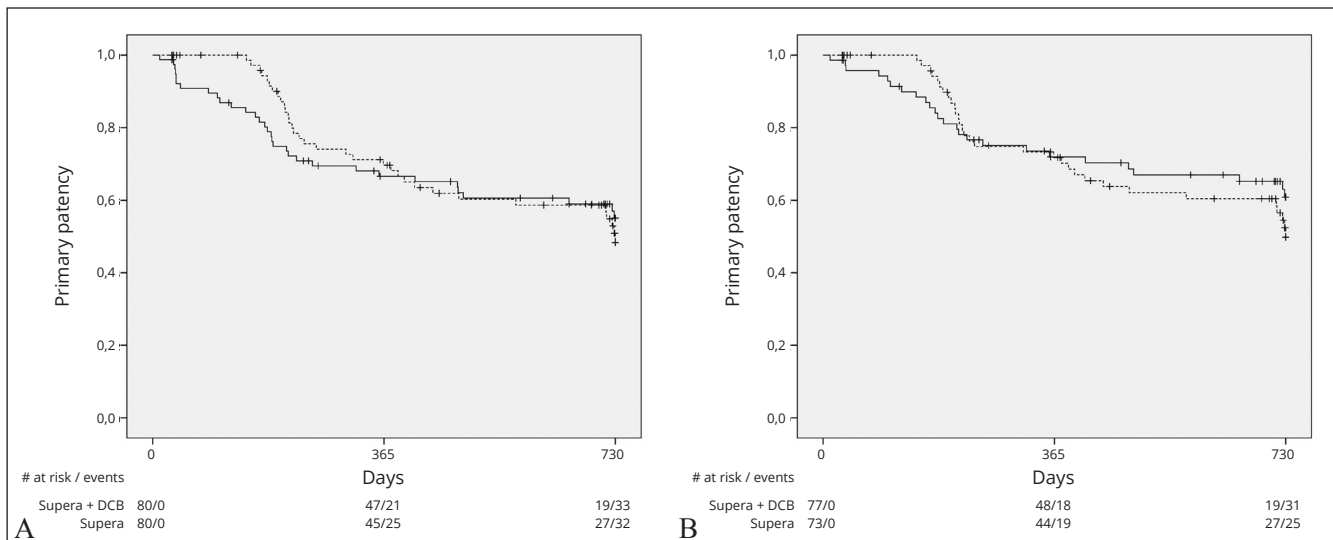


Figure 2.—A) Kaplan Meier (KM) estimates of primary patency (intention to treat analysis; P=0.957); B) KM estimates of primary patency (per protocol analysis; P=0.469). Solid line represents the Supera + drug-coated balloon group, dotted line represents the Supera group.

This document is protected by international copyright laws. No additional reproduction is authorized. It is permitted for personal use to download and save only one file and print only one copy of this Article. It is not permitted to make additional copies (either sporadically or systematically, either printed or electronic) of the Article for any purpose. It is not permitted to distribute the electronic copy of the article through online internet and/or intranet file sharing systems, electronic mailing or any other means which may allow access to the Article. The use of all or any part of the Article for any Commercial Use is not permitted. The production of derivative works from the Article is not permitted. It is not permitted to remove, cover, overlay, obscure, block, or change any copyright notices or terms of use which the Publisher may post on the Article. It is not permitted to frame or use framing techniques to enclose any trademark, logo, or other proprietary information of the Publisher.

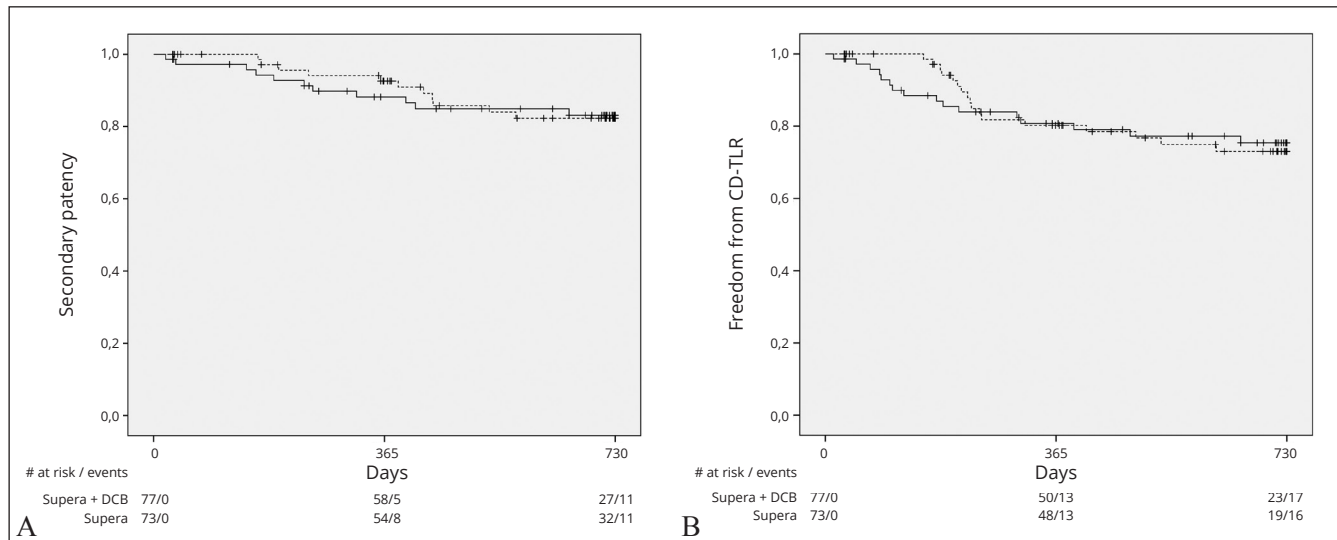


Figure 3.—A) Kaplan Meier (KM) estimates of secondary patency (per protocol analysis; P=0.941); B) KM estimates of freedom of clinically driven target lesion revascularization (CD-TLR) (per protocol analysis; P=0.957). Solid line represents the Supera + drug-coated balloon group, dotted line represents the Supera group.

total, which accounted for eight events, as one of these patients was included in the trial with both legs (both in the Supera + DCB group). Causes of death in the Supera + DCB group were; cardiac arrest (9 months), abdominal sepsis (24 months) and 1 death due to unknown causes (accounted for 2 events at 14 and 17 months), in the Supera group there were 3 deaths due to unknown causes (7, 12 and 22 months) and 1 due to lung cancer (11 months).

### Functional outcomes

Both groups showed sustained improvement compared to baseline regarding Rutherford classification, ABI and toe pressures (Table I). There were no statistically significant differences between the groups, except for ABI improvement in rest after 1 month.

The KM estimate of the primary sustained clinical improvement was 62.6% (95% CI: 49.5-75.7%) in the Supera + DCB group and 58.5% (95% CI: 45.6-71.4%) in the Supera group (P=0.581).

### Discussion

The RAPID Trial is the first multicenter randomized controlled trial to compare a primary Supera stenting strategy with or without the support of a DCB in intermediate and long SFA lesions. The 2-year results of this trial show that the use of the Legflow DCB in the SFA is safe, without an increased risk in all-cause mortality. However, there is no

TABLE I.—Changes in Rutherford class, ankle brachial index (ABI) and toe pressures of the study population.

	Supera + DCB	Supera	P
<b>Rutherford class improvement</b>			
Baseline	2.75 (0.97)	2.87 (1.06)	0.492 *
1 month	-2.39 (1.09)	-2.36 (1.18)	0.859 *
6 month	-2.23 (1.11)	-2.10 (1.36)	0.551 *
12 month	-2.36 (1.04)	-2.10 (1.50)	0.227 *
24 month	-2.08 (1.41)	-2.09 (1.43)	0.986 *
<b>ABI</b>			
<b>Rest</b>			
Baseline	0.60 (0.20)	0.61 (0.19)	0.791 *
1 month	0.89 (0.18)	0.97 (0.15)	0.016 *
6 month	0.88 (0.19)	0.90 (0.20)	0.463 *
12 month	0.84 (0.19)	0.91 (0.20)	0.223 *
24 month	0.83 (0.17)	0.85 (0.16)	0.432 *
<b>Postexercise</b>			
Baseline	0.34 (0.18)	0.38 (0.20)	0.442 *
1 month	0.79 (0.26)	0.85 (0.20)	0.276 *
6 month	0.73 (0.27)	0.74 (0.26)	0.864 *
12 month	0.72 (0.22)	0.69 (0.31)	0.558 *
24 month	0.65 (0.27)	0.68 (0.25)	0.647 *
<b>Toe pressure</b>			
<b>Hallux</b>			
Baseline	59 (30.0)	64 (41.2)	0.599 *
1 month	106 (44.6)	111 (37.3)	0.522 *
6 month	95 (34.4)	108 (35.6)	0.070 *
12 month	93 (32.6)	97 (45.9)	0.633 *
24 month	94 (40.0)	90 (36.5)	0.674 *

Continuous data are shown as mean (SD).  
PEB: paclitaxel eluting balloon; ABI: Ankle Brachial Index.  
\*One-way ANOVA.

statistically significant difference in KM estimates of primary patency or in any other of the secondary endpoints such as freedom from CD-TLR between the two groups.

For short (<5 cm) and intermediate (5-15 cm) lesions, adequate vessel preparation and finalizing treatment with a DCB or bail-out stenting in case of flow limiting dissections has been proven to be an effective treatment approach.<sup>8-12</sup> However, treatment of complex and long-segment (>15 cm) SFA lesions remains challenging and although many adopt an endovascular first strategy, it is limited by the occurrence of restenosis and a high need for bailout stenting.

During the design of the study, data on the Supera stent became available with high patency rates at short-term follow-up in short and intermediate SFA lesions.<sup>13</sup> Patency rates seemed higher compared to standard laser-cut nitinol stents and therefore the Supera stent was selected for the trial. Surprisingly, the 2-year RAPID primary patency rates are lower, compared to other reported patency rates of the Supera.<sup>13-16</sup> In comparison, the 12 months results of the SUPERB Trial showed a primary patency of 79%, but included less challenging lesions (mean lesion length 7.8 cm±4.3 cm, 25% CTO's).<sup>15</sup> Freedom from CD-TLR was 84% at 2 years, comparable to the results of the RAPID Trial.

Data on long SFA lesions and Supera stenting is mainly based on several single center retrospective experiences. The results of the Leipzig registry sub cohort of lesions >15 cm with 53% CTOs and 52% of the SFA lesions with moderate or severe calcifications are comparable to RAPID outcomes with a primary patency rate at 2 years of 62%.<sup>14</sup> Brescia *et al.* published their experience with the Supera stent in long SFA lesions. They used only clinical primary stent patency (defined as clinical resolution of

TABLE II.—Overview of reported 2-year primary patency rates, freedom from clinically driven target lesion revascularization (CD-TLR), lesion length and occlusion rate of various trials.

	Lesion length	CTO rate	Primary patency	Freedom from CD-TLR
RAPID	15.8	76.3	60.9	75.4
Zilver-PTX <sup>24</sup>	6.6	32.8	74.8	86.6
ILLUMINATE <sup>25</sup>	7.2	19.2	75.2	88.9
MAJESTIC <sup>22</sup>	7.8	46.0	83.5	92.8
LEVANT I <sup>10</sup>	8.1	42.0	57.0	64.0
IN.PACT SFA <sup>8</sup>	8.9	25.8	78.9	90.9
IN.PACT SFA JAPAN <sup>26</sup>	9.2	16.2	79.8	90.9
IN.PACT Global <sup>27</sup>	12.1	35.5	x	83.3
CONSEQUENT <sup>28</sup>	13.7	23.1	72.3	80.9
ACO-ART I <sup>29</sup>	14.7	57.0	64.6	86.5
REAL-PTX DCB group <sup>30</sup>	15.0	53.3	56.0	80.0
REAL-PTX DES group <sup>30</sup>	15.6	52.0	64.6	80.1

Lesion length in cm; CTO rate, primary patency and freedom from CD-TLR in %. CTO: chronic total occlusions; CD-TLR: clinically driven target lesion revascularization.

symptoms and freedom from secondary interventions and comparable to freedom from CD-TLR) to determine efficacy. Mean lesion length was 24.0 cm (range 3-51 cm), clinical primary stent patency was 83.1% at 2 years, similar to freedom from CD-TLR rates in the RAPID Trial.<sup>17</sup>

The idea to support the Supera with a DCB comes from data available from studies demonstrating an added benefit of drug coated technology in preventing restenosis.<sup>8, 10-12, 18-23</sup> The 2-year results of the RAPID Trial are consistent with other trials reporting on intermediate and long SFA lesions (Table II, Figure 4, 5).<sup>8, 10, 22, 24-30</sup> Both primary patency rate and freedom from CD-TLR decline with increasing lesion length, higher CTO rate and longer follow-up.

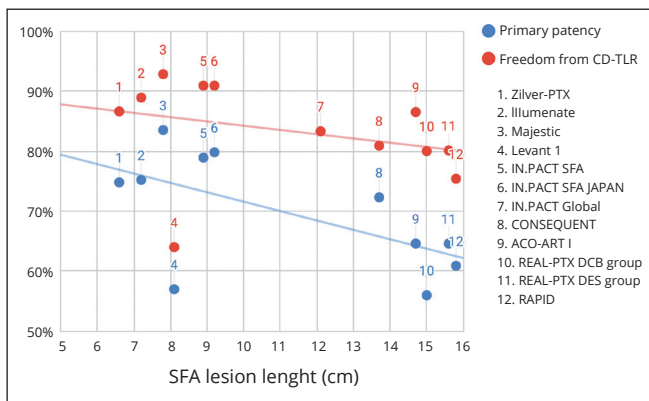


Figure 4.—Overview of 2-year primary patency and freedom from clinically driven target lesion revascularization (CD-TLR) versus lesion length reported by various trials.

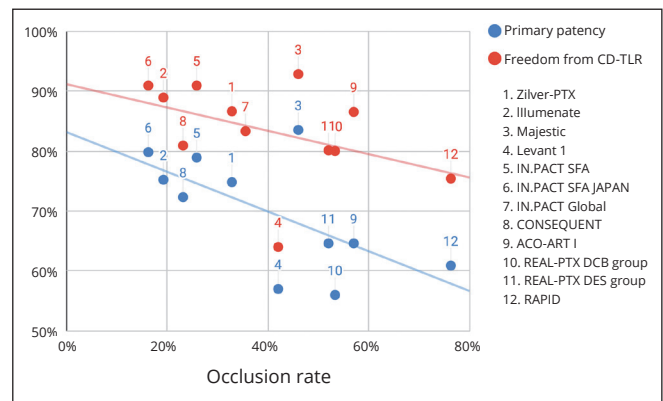


Figure 5.—Overview of 2-year primary patency and freedom from clinically driven target lesion revascularization (CD-TLR) versus percentage of occluded lesions reported by various trials.

Recently, there has been much debate regarding the safety of paclitaxel eluting balloons.<sup>31</sup> The RAPID Trial did not show a significant difference in any of the safety outcomes at 2 years, including all-cause mortality. This data is in line with recently presented 5-years data from the Acoart I Trial<sup>32</sup> and a patient-level meta-analysis of the IN.PACT Admiral DCB (Medtronic, Dublin, Ireland).<sup>33</sup>

### Limitations of the study

The power analysis for this trial was calculated on data from early generation laser-cut nitinol stent studies showing a restenosis rate of almost 50% at 2 years.<sup>34</sup> Since the reported restenosis rate of the Supera stent is <50%, in combination with the reported technical failures, this assumption might have resulted in an underpowered study population.

A second limitation is that during the design of the study, the distribution of the subjects across the participating centers was not stratified. This resulted in high and low enrolling centers, which could have had an effect on the results. Four out of eight centers included <15 patients.

The trial was not sufficiently powered to perform reliable sub analyses on center effects or extended subgroup analyses.

### Conclusions

The 2-year results of a primary Supera stenting strategy are consistent with other trials reporting on treatment of intermediate and long SFA lesions. The Legflow DCB is safe to use in long SFA lesions, but did not improve patency rates compared to a Supera-only strategy.

### References

1. Norgren L, Hiatt WR, Dormandy JA, Nehler MR, Harris KA, Fowkes FG; TASC II Working Group. Inter-Society Consensus for the Management of Peripheral Arterial Disease (TASC II). *J Vasc Surg* 2007;45(Suppl S):S5–67.
2. Hirsch AT, Haskal ZJ, Hertzner NR, Bakal CW, Creager MA, Halperin JL, *et al.*; American Association for Vascular Surgery/Society for Vascular Surgery; Society for Cardiovascular Angiography and Interventions; Society for Vascular Medicine and Biology; Society of Interventional Radiology; ACC/AHA Task Force on Practice Guidelines. ACC/AHA Guidelines for the Management of Patients with Peripheral Arterial Disease (lower extremity, renal, mesenteric, and abdominal aortic): a collaborative report from the American Associations for Vascular Surgery/Society for Vascular Surgery, Society for Cardiovascular Angiography and Interventions, Society for Vascular Medicine and Biology, Society of Interventional Radiology, and the ACC/AHA Task Force on Practice Guidelines (writing committee to develop guidelines for the management of patients with peripheral arterial disease)—summary of recommendations. *J Vasc Interv Radiol* 2006;17:1383–97, quiz 1398.
3. Tendera M, Aboyans V, Bartelink ML, Baumgartner I, Clément D, Collet JP, *et al.*; European Stroke Organisation; ESC Committee for Practice Guidelines. ESC Guidelines on the diagnosis and treatment of peripheral ar-

tery diseases: Document covering atherosclerotic disease of extracranial carotid and vertebral, mesenteric, renal, upper and lower extremity arteries: the Task Force on the Diagnosis and Treatment of Peripheral Artery Diseases of the European Society of Cardiology (ESC). *Eur Heart J* 2011;32:2851–906.

4. Jens S, Conijn AP, Koelemay MJ, Bipat S, Reekers JA. Randomized trials for endovascular treatment of infrainguinal arterial disease: systematic review and meta-analysis (Part 1: Above the knee). *Eur J Vasc Endovasc Surg* 2014;47:524–35.
5. de Boer SW, van den Heuvel DA, de Vries-Werson DA, Vos JA, Fioole B, Vroegindeweij D, *et al.* Short-term Results of the RAPID Randomized Trial of the Legflow Paclitaxel-Eluting Balloon With Supera Stenting vs Supera Stenting Alone for the Treatment of Intermediate and Long Superficial Femoral Artery Lesions. *J Endovasc Ther* 2017;24:783–92.
6. Karimi A, de Boer SW, van den Heuvel DA, Fioole B, Vroegindeweij D, Heyligers JM, *et al.* Randomized trial of Legflow® paclitaxel eluting balloon and stenting versus standard percutaneous transluminal angioplasty and stenting for the treatment of intermediate and long lesions of the superficial femoral artery (RAPID trial): study protocol for a randomized controlled trial. *Trials* 2013;14:87.
7. Rocha-Singh KJ, Zeller T, Jaff MR. Peripheral arterial calcification: prevalence, mechanism, detection, and clinical implications. *Catheter Cardiovasc Interv* 2014;83:E212–20.
8. Laird JR, Schneider PA, Tepe G, Brodmann M, Zeller T, Metzger C, *et al.*; IN.PACT SFA Trial Investigators. Durability of Treatment Effect Using a Drug-Coated Balloon for Femoropopliteal Lesions: 24-Month Results of IN.PACT SFA. *J Am Coll Cardiol* 2015;66:2329–38.
9. Schroë H, Holden AH, Goueffic Y, Jansen SJ, Peeters P, Keirse K, *et al.* Stellarex drug-coated balloon for treatment of femoropopliteal arterial disease-The ILLUMENATE Global Study: 12-Month results from a prospective, multicenter, single-arm study. *Catheter Cardiovasc Interv* 2018;91:497–504.
10. Scheinert D, Duda S, Zeller T, Krankenberg H, Ricke J, Bosiers M, *et al.* The LEVANT I (Lutonix paclitaxel-coated balloon for the prevention of femoropopliteal restenosis) trial for femoropopliteal revascularization: first-in-human randomized trial of low-dose drug-coated balloon versus uncoated balloon angioplasty. *JACC Cardiovasc Interv* 2014;7:10–9.
11. Tepe G, Schnorr B, Albrecht T, Brechtel K, Claussen CD, Scheller B, *et al.* Angioplasty of femoral-popliteal arteries with drug-coated balloons: 5-year follow-up of the THUNDER trial. *JACC Cardiovasc Interv* 2015;8(1, Part A):102–8.
12. Werk M, Albrecht T, Meyer DR, Ahmed MN, Behne A, Dietz U, *et al.* Paclitaxel-coated balloons reduce restenosis after femoro-popliteal angioplasty: evidence from the randomized PACIFIER trial. *Circ Cardiovasc Interv* 2012;5:831–40.
13. Scheinert D, Grummt L, Piorkowski M, Sax J, Scheinert S, Ulrich M, *et al.* A novel self-expanding interwoven nitinol stent for complex femoropopliteal lesions: 24-month results of the SUPERA SFA registry. *J Endovasc Ther* 2011;18:745–52.
14. Werner M, Paetzold A, Banning-Eichenseer U, Scheinert S, Piorkowski M, Ulrich M, *et al.* Treatment of complex atherosclerotic femoropopliteal artery disease with a self-expanding interwoven nitinol stent: midterm results from the Leipzig SUPERA 500 registry. *EuroIntervention* 2014;10:861–8.
15. Garcia L, Jaff MR, Metzger C, Sedillo G, Pershad A, Zidar F, *et al.*; SUPERB Trial Investigators. Wire-Interwoven Nitinol Stent Outcome in the Superficial Femoral and Proximal Popliteal Arteries: Twelve-Month Results of the SUPERB Trial. *Circ Cardiovasc Interv* 2015;8:8.
16. Myint M, Schouten O, Bourke V, Thomas SD, Lennox AF, Varcoe RL. A Real-World Experience With the Supera Interwoven Nitinol Stent in Femoropopliteal Arteries: Midterm Patency Results and Failure Analysis. *J Endovasc Ther* 2016;23:433–41.
17. Brescia AA, Wickers BM, Correa JC, Smeds MR, Jacobs DL. Stenting of femoropopliteal lesions using interwoven nitinol stents. *J Vasc Surg* 2015;61:1472–8.
18. Werk M, Langner S, Reinkensmeier B, Boettcher HF, Tepe G, Dietz U, *et al.* Inhibition of restenosis in femoropopliteal arteries: paclitaxel-coated versus uncoated balloon: femoral paclitaxel randomized pilot trial. *Circulation* 2008;118:1358–65.

19. Rosenfield K, Jaff MR, White CJ, Rocha-Singh K, Mena-Hurtado C, Metzger DC, *et al.*; LEVANT 2 Investigators. Trial of a Paclitaxel-Coated Balloon for Femoropopliteal Artery Disease. *N Engl J Med* 2015;373:145–53.
20. Dake MD, Ansel GM, Jaff MR, Ohki T, Saxon RR, Smouse HB, *et al.*; Zilver PTX Investigators. Durable Clinical Effectiveness With Paclitaxel-Eluting Stents in the Femoropopliteal Artery: 5-Year Results of the Zilver PTX Randomized Trial. *Circulation* 2016;133:1472–83, discussion 1483.
21. Gray WA, Keirse K, Soga Y, Benko A, Babaev A, Yokoi Y, *et al.*; IMPERIAL investigators. A polymer-coated, paclitaxel-eluting stent (Eluvia) versus a polymer-free, paclitaxel-coated stent (Zilver PTX) for endovascular femoropopliteal intervention (IMPERIAL): a randomised, non-inferiority trial. *Lancet* 2018;392:1541–51.
22. Müller-Hülsbeck S, Keirse K, Zeller T, Schroë H, Diaz-Cartelle J. Long-Term Results from the MAJESTIC Trial of the Eluvia Paclitaxel-Eluting Stent for Femoropopliteal Treatment: 3-Year Follow-up. *Cardiovasc Intervent Radiol* 2017;40:1832–8.
23. Tepe G, Zeller T, Albrecht T, Heller S, Schwarzwälder U, Beregi JP, *et al.* Local delivery of paclitaxel to inhibit restenosis during angioplasty of the leg. *N Engl J Med* 2008;358:689–99.
24. Dake MD, Ansel GM, Jaff MR, Ohki T, Saxon RR, Smouse HB, *et al.*; Zilver PTX Investigators. Sustained safety and effectiveness of paclitaxel-eluting stents for femoropopliteal lesions: 2-year follow-up from the Zilver PTX randomized and single-arm clinical studies. *J Am Coll Cardiol* 2013;61:2417–27.
25. Brodmann M. ILLUMENATE European randomized trial: 2-year results. In: LINC symposium; 2018 [Internet]. Available from: [https://linc2018.cnepdtx.com/media/0935\\_Marianne\\_Brodmann\\_30\\_01\\_2018\\_Room\\_1\\_-\\_Main\\_Arena\\_1.pdf](https://linc2018.cnepdtx.com/media/0935_Marianne_Brodmann_30_01_2018_Room_1_-_Main_Arena_1.pdf) [cited 2019, Sep 26].
26. Iida O, Soga Y, Urasawa K, Saito S, Jaff MR, Wang H, *et al.*; MDT-2113 SFA Japan Investigators. Drug-coated balloon versus uncoated percutaneous transluminal angioplasty for the treatment of atherosclerotic lesions in the superficial femoral and proximal popliteal artery: 2-year results of the MDT-2113 SFA Japan randomized trial. *Catheter Cardiovasc Interv* 2019;93:664–72.
27. Micari A, Brodmann M, Keirse K, Peeters P, Tepe G, Frost M, *et al.*; IN.PACT Global Study Investigators. Drug-Coated Balloon Treatment of Femoropopliteal Lesions for Patients With Intermittent Claudication and Ischemic Rest Pain: 2-Year Results From the IN.PACT Global Study. *JACC Cardiovasc Interv* 2018;11:945–53.
28. Albrecht T, Waliszewski M, Roca C, Redlich U, Tautenhahn J, Pech M, *et al.* Two-Year Clinical Outcomes of the CONSEQUENT Trial: Can Femoropopliteal Lesions be Treated with Sustainable Clinical Results that are Economically Sound? *Cardiovasc Intervent Radiol* 2018;41:1008–14.
29. Xu Y, Jia X, Zhang J, Zhuang B, Fu W, Wu D, *et al.* Drug-Coated Balloon Angioplasty Compared With Uncoated Balloons in the Treatment of 200 Chinese Patients With Severe Femoropopliteal Lesions: 24-Month Results of AcoArt I. *JACC Cardiovasc Interv* 2018;11:2347–53.
30. Bausback Y, Wittig T, Schmidt A, Zeller T, Bosiers M, Peeters P, *et al.* Drug-Eluting Stent Versus Drug-Coated Balloon Revascularization in Patients With Femoropopliteal Arterial Disease. *J Am Coll Cardiol* 2019;73:667–79.
31. Katsanos K, Spiliopoulos S, Kitrou P, Krokidis M, Karnabatidis D. Risk of Death Following Application of Paclitaxel-Coated Balloons and Stents in the Femoropopliteal Artery of the Leg: A Systematic Review and Meta-Analysis of Randomized Controlled Trials. *J Am Heart Assoc* 2018;7:e011245.
32. Wei G. Insight from AcoArt I: 5 Years Follow-up. In: LINC Symposium; 2019 [Internet]. Available from: [https://www.linc-around-the-world.com/fileadmin/images/linc-asia-pacific/pdf-downloads/programme/Insight\\_from\\_AcoArt\\_I-5\\_Year\\_Follow\\_Up.pdf](https://www.linc-around-the-world.com/fileadmin/images/linc-asia-pacific/pdf-downloads/programme/Insight_from_AcoArt_I-5_Year_Follow_Up.pdf) [cited 2019, Sep 26].
33. Schneider PA, Laird JR, Doros G, Gao Q, Ansel G, Brodmann M, *et al.* Mortality Not Correlated With Paclitaxel Exposure: An Independent Patient-Level Meta-Analysis of a Drug-Coated Balloon. *J Am Coll Cardiol* 2019;73:2550–63.
34. Schillinger M, Sabeti S, Dick P, Amighi J, Mlekusch W, Schlager O, *et al.* Sustained benefit at 2 years of primary femoropopliteal stenting compared with balloon angioplasty with optional stenting. *Circulation* 2007;115:2745–9.

**Conflicts of interest.**—The authors certify that there is no conflict of interest with any financial organization regarding the material discussed in the manuscript.

**Funding.**—An unrestricted grant was received from Cardionovum GmbH, Bonn, Germany.

**Authors' contributions.**—All authors were involved in the design of the trial and in the acquisition, analysis and interpretation of data for the work. Sanne W. de Boer and Daniel van den Heuvel drafted the manuscript, which was critically revised by Jean-Paul de Vries and Jan A. Vos on multiple occasions. All authors have approved this manuscript.

**Group name.**—Sanne W. de BOER, Jean-Paul de VRIES, Debora A. WERSON, Bram FIOOLE, Dammis VROEGINDEWEIJ, Jan A. VOS, Daniel van den HEUVEL already listed in the authors' byline also form part of the group name.

Members qualified as contributors include the following: Gerlof P. BOSMA (Department of Radiology, Elisabeth Tweesteden Hospital, Tilburg, the Netherlands); Lee H. BOUWMAN (Department of Vascular Surgery, Zuyderland Medical Centre, Heerlen, the Netherlands); Dittmar BÖCKLER and Dmitriy I. DOVZHANSKIY (Klinik für Gefäßchirurgie und Endovaskuläre Chirurgie, Universitätsklinikum Heidelberg, Heidelberg, Germany); Otto E. ELGERSMA (Department of Radiology, Albert Schweitzer Hospital, Dordrecht, the Netherlands); Jan M. HEYLIERS (Department of Vascular Surgery, Elisabeth Tweesteden Hospital, Tilburg, the Netherlands); Rutger J. HISSINK (Department of Vascular Surgery, Scheper Hospital, Emmen, the Netherlands); Pieter HOOIJBOER (Department of Radiology, Scheper Hospital, Emmen, the Netherlands); Bernart L. de LEEUW (Department of Radiology, Zuyderland Medical Centre, Heerlen, the Netherlands); Rudolf P. TUTEIN NOLTHENIUS (Department of Vascular Surgery, Albert Schweitzer Hospital, Dordrecht, the Netherlands); Ted W. VINK (Department of Radiology, Medical Centre Leeuwarden, Leeuwarden, the Netherlands); Floris A. VOS (Department of Vascular Surgery, Medical Centre Leeuwarden, Leeuwarden, the Netherlands).

**Acknowledgements.**—The authors would like to acknowledge all interventional radiologists, vascular surgeons and physician assistants who participated in this trial:

- Data-safety monitoring board: M.W. de Haan, M.M.J.P. Reijnen, O.M. van Delden.
- Maastad Hospital: E.C. Punt-Terlouw, P.A.H. van Mierlo-van den Broek,
- Albert Schweitzer Hospital: P.H.M. van der Valk, P.J.A. Ophof (†), M.M.A.C. van Doorn, J.A.M. Avontuur, M.T.C. Hoedt, M.A. Lijkwan.
- Elisabeth Tweesteden Hospital: K. van Hees, P.N.M. Lohle, A.J. Smeets, P.W.H.E. Vriens
- Zuyderland Medical Centre: R. Heijboer, A. Krasznai, T. Sigterman, L. Bolt.
- Medical Centre Leeuwarden: A. Jongma, J.A. Dol, D.M. Doorenbos, M.J. Brinckman.
- Scheper Hospital: J. Brakel, J. van der Burgh.
- St. Antonius Hospital: M.J.L. van Strijen, M. van Leersum, H.D.W.M. van de Pavoordt, J. Wille, R.H.J. Kropman, R.H.W. van de Mortel.

Prior publication of study protocol in *Trials* (*Trials*. 2013 Mar 28;14:87. doi: 10.1186/1745-6215-14-87).

Prior publication of short-term results in the *Journal of Endovascular Therapy* (*J EVT* 2017 Dec;24(6):783-792. doi: 10.1177/1526602817725062. Epub 2017 Aug 10).

Article first published online: October 9, 2019. - Manuscript accepted: September 24, 2019. - Manuscript revised: September 24, 2019. - Manuscript received: August 30, 2019.